

Anaesthetic management of a vaginal hysterectomy case with an unanticipated failure of epidural injection due to fused lumbar spine

Sukhminder Jit Singh Bajwa, Sukhwinder Kaur Bajwa¹, Jasbir Kaur, (Brig) Amarjit Singh, Seema Prasad

Departments of Anaesthesiology and Intensive Care, ¹Obstetrics and Gynaecology, Gian Sagar Medical College and Hospital, Ram Nagar, Banur, Punjab, India

ABSTRACT

Epidural anesthesia is one of the easier and safer techniques for lower abdominal surgery. It has a very high success rate in the experienced hands, and failure rates are minimal when it is administered by the experienced anesthesiologists. As it is a blind technique, failures can be encountered even by a senior anesthesiologist in many situations and one must analyze retrospectively the various causes responsible for such failures. We report a case of 45-year-old female, weighing 60 kg, who was scheduled for elective vaginal hysterectomy under regional anesthesia. Initial four to five attempts were unsuccessful in establishing the epidural block as the epidural injection encountered bony resistance each time, but subarachnoid block could be achieved with a 23 G spinal needle in the paramedian site of entry in the third attempt. Postoperatively, lumbar and cervical spine X-rays were done which revealed an isolated lumbar spine bony fusion. She was diagnosed as a rare case of isolated lumbar spine fusion without any involvement of cervical spine, other articular joints or any systemic manifestations of diseases like ankylosing spondylitis.

Key words: Ankylosing spondylitis, epidural anesthesia, fused spine

INTRODUCTION

Epidural anesthesia (EA) is one of the most common and safest techniques of inducing regional anesthesia for the lower abdominal surgery and postoperative pain relief.^[1] The failure rate is minimal in the experienced hands. The level of failure is either at the doctor's end, due to faulty technique or inability in identification of anatomical landmarks, or may be due to some other factors such as obese patient, narrowing of intervertebral spaces, diseases of spine or ankylosis of spine

Address for correspondence: Dr. Sukhminder Jit Singh Bajwa, Department of Anaesthesiology and Intensive Care, Gian Sagar Medical College and Hospital, Ram Nagar, Banur, Punjab, India. E-mail: sukhminder_bajwa2001@yahoo.com

leading to formation of bony column also called "bamboo spine".^[2] We are reporting such a case in which unanticipated and repeated failures occurred in achieving the epidural block, as each time bony resistance was encountered during the administration of epidural injection.

CASE REPORT

A 45-year-old female, weighing 60 kg, reported to the gynecological outpatient department with the chief complaint of "something coming out of the vagina" for the past 3 months. The patient did not elicit any history of fall or trauma. On clinical and systemic examination, she was diagnosed as a case of 2nd degree uterine prolapse with cystocele and was scheduled for elective vaginal hysterectomy.

During the pre-anesthetic check-up, the patient did not give any past history of systemic medical disease, drug allergy, hospitalization, any previous surgery, and as such, her entire medical record was not of much clinical significance. On clinical examination, a regular pulse rate of 76/min and a blood pressure reading of 130/82 mmHg was recorded. No

Access this article online	
Quick Response Code:	Website: www.ijabmr.org
	DOI: 10.4103/2229-516X.81984

abnormality was detected in any of the organ system functions. Airway examination revealed an adequate mouth opening with Mallampatti class of I, normal thyromental distance and normal neck movements. The clinical and biochemical profile revealed hemoglobin level of 12.4 g/dl, normal electrocardiograph and chest X-ray, as well as normal values of all the routine investigations. Local examination of the spine showed no abnormal findings. Consent was taken from the patient, after explaining to her about the regional anesthesia procedure during the check-up.

As a part of premedication, she was prescribed ranitidine 150 mg and alprazolam 0.25 mg tablets, at night and in the morning of the surgery, 2 hours prior to the procedure. In the operation theater, a good peripheral venous access was secured and preloading was carried out with 500 ml of lactated ringer solution. Monitoring devices were attached for the heart rate, electrocardiogram, non-invasive blood pressure and pulse oximetry. All the baseline parameters were observed and recorded. Taking all aseptic precautions, local infiltration of lumbar spine at L4–5 intervertebral space was achieved with 1 ml of 2% lignocaine hydrochloride solution. Lumbar puncture with an 18 G Touhy epidural needle at L4–5 space was performed in the sitting position. Unfortunately, bony resistance was encountered in the next three attempts, both in the midline and paramedian site. Similar failures were encountered at L3–4 and L2–3 intervertebral space, both in the midline as well as the paramedian site, at a depth of 4–4.5 cm from the skin surface. The procedure was performed by a consultant anesthesiologist after the first failed attempt by a senior resident. Fortunately, a successful subarachnoid block was established in the third attempt at L3–4 intervertebral space with a 23 G spinal needle inserted through paramedian entry point. A total of 3.5 ml of “heavy” bupivacaine hydrochloride was injected into subarachnoid space which was admixed with 45 µg of clonidine hydrochloride. Surgical procedure started only when the effect of drug was established up to T-10 dermatome. The entire surgical procedure was uneventful with stable parameters and the procedure lasted for about 2 hours. Postoperatively, X-ray of lumbar and cervical spine was done which revealed fusion of the lumbar spine, and surprisingly, cervical spine was absolutely normal. On thorough investigations, she was diagnosed as a rare case of isolated lumbar spine fusion by the orthopedician without any other articular or extra-articular manifestations to be labeled as ankylosing spondylitis (AS). The postoperative course was uneventful and she was discharged on the 8th postoperative day.

DISCUSSION

The diagnosis of ankylosis of spine is made clinically according

to the set criteria, but still a few patients may not have the relevant clinical features for the precise diagnosis of AS.^[3] One can encounter unanticipated failure during the administration of regional anesthetic techniques in such patients who develop isolated ankylosis without the extra-articular involvement.^[4] All the necessary investigations which were essential for the scheduled surgery had been carried out preoperatively but not even a single laboratory or diagnostic test indicated toward the presence of fusion of the lumbar spine. The postoperative X-ray of spine showed isolated fusion of lumbar spine without the involvement of cervical or thoracic spine [Figure 1]. A typical case of AS involves various articular junctions including atlanto-occipital, cervical spine, temporo-mandibular and crico-arytenoid joints, which confronts the anesthesiologist to an extremely difficult challenge for airway management.^[5,6] The literature is abundant with such reports where the involvement of cervical spine in ankylosis leads to higher rate of on-table mortality and morbidity.^[7] The radiological appearance in case of AS typically reveals a “bamboo spine” which was difficult to ascertain in our patient as the X-ray showed only fusion of lumbar spine and not typically the features of AS, which is mainly due to the bony fusion caused by syndesmophytes.^[8,9]

The disease may involve posterior longitudinal ligament as well as inter-spinous ligament, leading to the formation

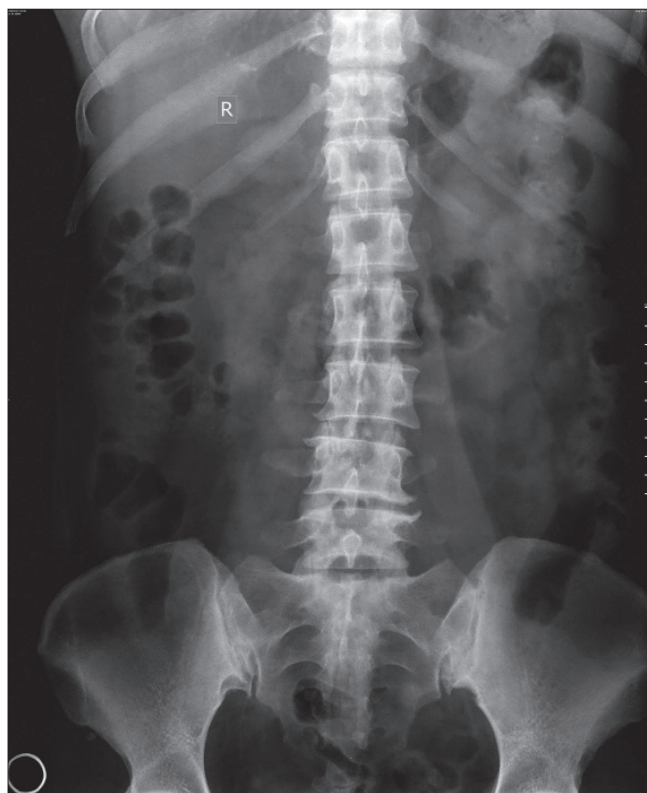


Figure 1: Image showing antero-posterior view of fused lumbar spine

of a complete rigid column, thereby making it difficult to administer regional anesthesia in the midline.^[5] Though there seems to exist a strong association of AS with HLA-B27 in approximately 80–85% of the patients, our patient did not show this correlation.^[9] Even the criteria designed for the identification of AS sometimes do not help in exact formulation of precise diagnosis as it proved to be true in this case also.^[4]

In such unanticipated difficult cases where one continuously encounters bony resistance, the presence of AS should be considered. Although the regional anesthesia technique may be difficult in such cases, the calcification and ossification of ligament flavum is extremely rare. Thus, a paramedian approach should be considered.^[5] As such, before resorting to general anesthesia (GA) due to failed regional technique, airway evaluation and planning management should be carried out by a senior anesthesiologist before proceeding further as GA is associated with more challenging situations with regards to airway management due to possibility of fusion of cervical spines.

REFERENCES

1. Bajwa SJ, Bajwa SK, Kaur J, Singh A, Bakshi G, Singh K, *et al.* Admixture of clonidine and fentanyl to ropivacaine in epidural anesthesia for lower abdominal surgery. *Anesth Essays Res* 2010;4:9-14.
2. Agaram R, Douglas MJ, McTaggart RA, Gunka V. Inadequate pain relief with labor epidurals: A multivariate analysis of associated factors. *Int J Obstet Anesth* 2009;18:10-4.
3. Calin A. Ankylosing Spondylitis. In: Madison PJ, Isenberg DA, Glass DN, editors. *Oxford Textbook of Rheumatology*, Oxford: Oxford University Press 1993; 2:671-83.
4. Sinclair JR, Mason RA. Ankylosing spondylitis. The case for awake intubation. *Anaesthesia* 1984;39:3-11.
5. Wittmann FW, Ring PA. Anaesthesia for hip replacement in ankylosing spondylitis. *J R Soc Med* 1986;79:457-9.
6. Simmons EH. The surgical correction of flexion deformity of cervical spine in ankylosingspondylitis. *Clin Orthop Relat Res* 1972;86:132-43.
7. Benumof JL. Management of the difficult adult airway: With special emphasis on awake tracheal intubation. *Anesthesiology* 1991;75:1087-110.
8. Kumar CM, Mehta M. Ankylosing spondylitis: Lateral approach to spinal anaesthesia for lower limb surgery. *Can J Anaesth* 1995;42:73-6.
9. DeBoard JW, Ghia JN, Guilford WB. Caudal anesthesia in a patient with ankylosingspondylitis for hip surgery. *Anesthesiology* 1981;54:164-6.

How to cite this article: Bajwa SJ, Bajwa SK, Kaur J, Singh A, Prasad S. Anaesthetic management of a vaginal hysterectomy case with an unanticipated failure of epidural injection due to fused lumbar spine. *Int J App Basic Med Res* 2011;1:57-9.

Source of Support: Nil. **Conflict of Interest:** None declared.

Staying in touch with the journal

1) Table of Contents (TOC) email alert

Receive an email alert containing the TOC when a new complete issue of the journal is made available online. To register for TOC alerts go to www.ijabmr.org/signup.asp.

2) RSS feeds

Really Simple Syndication (RSS) helps you to get alerts on new publication right on your desktop without going to the journal's website. You need a software (e.g. RSSReader, Feed Demon, FeedReader, My Yahoo!, NewsGator and NewzCrawler) to get advantage of this tool. RSS feeds can also be read through FireFox or Microsoft Outlook 2007. Once any of these small (and mostly free) software is installed, add www.ijabmr.org/rssfeed.asp as one of the feeds.