

# Contrast-enhanced ultrasound findings of gallbladder adenocarcinoma with sarcomatoid carcinoma accompanied by intrahepatic metastasis

## A case report and literature review

Hong Wang, MD, Wenwu Ling, MD, Yan Luo, MD\*

### Abstract

**Rationale:** Gallbladder adenocarcinoma is the most common subtype of malignant tumor in gallbladder carcinoma; its incidence is quite low. Preoperative diagnosis of gallbladder adenocarcinoma appears to be very difficult because they are normally asymptomatic and are often found incidentally. Adenocarcinoma with sarcomatoid carcinoma of gallbladder is exceedingly rare with no case reported in the literature to date.

**Patient concerns:** A 69-year-old male was referred to our hospital due to right upper quadrant pain. To further diagnosis, he received laboratory tests, gray-scale US, and contrast-enhanced ultrasound (CEUS). In this present study, ethical approval was not necessary, as this article is a case report, which is based on the clinical information of the patient. The patient gave his permission for publication of the case.

**Diagnoses:** Gray-scale abdominal ultrasound image demonstrated a hypoechoic intraluminal mass of gallbladder and a heterogeneous mass at the inferior segment of the right anterior liver lobe. In CEUS, the lesion of gallbladder was hyper-enhanced in the arterial phase, and hypo-enhanced in the later arterial phase. On liver, the hepatic lesion appeared heterogenous mild enhancement in the arterial phase. In portal and parenchymal phase, the hepatic lesion displayed hypo-enhancement, which conformed to the hepatic metastasis.

**Interventions:** The patient received cholecystectomy, right hepatectomy, and lymphadenectomy.

**Outcomes:** He had an uneventful recovery from the procedure.

**Lessons:** We presented a case report with gallbladder adenocarcinoma with sarcomatoid carcinoma accompanied by intrahepatic metastasis, focusing on the ultrasound imaging features of this tumor, especially its enhancement pattern on CEUS. CEUS provided helpful information for diagnosis. Herein, we report the case; and the associated literature is further reviewed.

**Abbreviations:** AFP = alphafetoprotein, CA19-9 = carbohydrate antigen 19-9, CEA = carcinoembryonic antigen, CEUS = contrast-enhanced ultrasound.

**Keywords:** contrast-enhanced ultrasound, gallbladder adenocarcinoma, sarcomatoid carcinoma

## 1. Introduction

The incidence of gallbladder adenocarcinoma is extremely rare. Clinical manifestation and laboratory test are nonspecific for the

diagnosis.<sup>[1,2]</sup> Therefore, imaging finding of this rare tumor is important for its diagnoses. In this paper, we present a case of gallbladder adenocarcinoma with sarcomatoid carcinoma accompanied by intra-hepatic metastasis, with an emphasis on the ultrasound imaging and contrast-enhanced ultrasound (CEUS) finding. The CEUS performance of gallbladder adenocarcinoma in the literature is further reviewed.

Editor: N/A.

HW and WL equally contributed to this study.

The authors have no conflicts of interest to disclose.

Department of Ultrasound, The West China Hospital of Sichuan University, Chengdu, China.

\* Correspondence: Yan Luo, The Department of Ultrasound, The West China Hospital of Sichuan University, No. 37, Guoxue Xiang, Chengdu 610041, China (e-mail: luoyanddoc@163.com).

Copyright © 2018 the Author(s). Published by Wolters Kluwer Health, Inc. This is an open access article distributed under the terms of the Creative Commons Attribution-NonCommercial-ShareAlike 4.0 License, which allows others to remix, tweak, and build upon the work non-commercially, as long as the author is credited and the new creations are licensed under the identical terms.

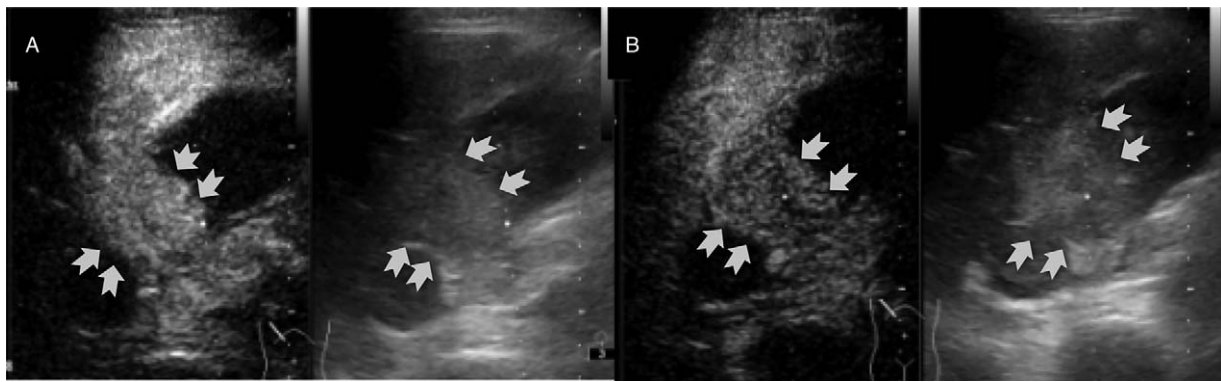
Medicine (2018) 97:21(e10773)

Received: 27 January 2018 / Accepted: 23 April 2018

<http://dx.doi.org/10.1097/MD.00000000000010773>

## 2. Case presentation

A 69-year-old male patient complained about right upper quadrant pain. Laboratory studies revealed almost normal liver function. Carcinoembryonic antigen (CEA) and CA19-9 (carbohydrate antigen 19-9) were within the normal ranges. Alphafetoprotein (AFP) was 386.70 µg/L. He then underwent an abdominal ultrasound examination. Gray-scale ultrasound image demonstrated a solid intraluminal mass of gallbladder. The mass was approximately 3.9 × 3.5 cm in size with an irregular shape and unclear margin. Color Doppler displayed short-linear blood flow signals in the mass. Besides, ultrasound showed a few gallbladder stone. Meanwhile, the tissue mass



**Figure 1.** Serial contrast-enhanced images exhibit hyper-enhancement at 18 seconds after contrast agent injection (A) and the enhancement turns to be hypo-enhancement at 50 seconds after contrast agent injection (B).

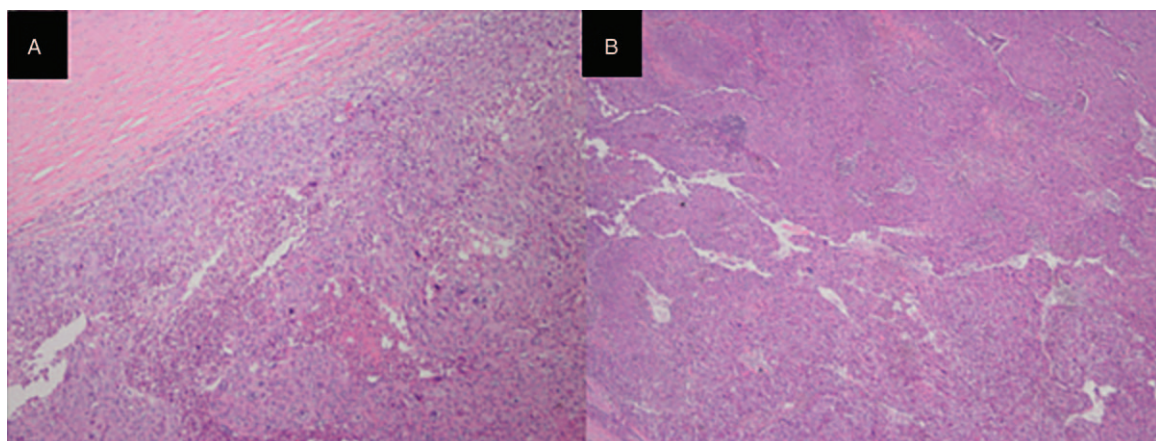
infiltrated the gallbladder wall and the surrounding hepatic parenchyma. Gray-scale ultrasound image demonstrated a heterogeneous mass at the inferior segment of the right anterior liver lobe ( $3.4 \times 1.7$  cm). Color Doppler US showed no flow signals within the liver mass. For further diagnosis, the patient agreed to undergo CEUS. A 1.2 mL contrast agents (SonoVue, Bracco SpA, Milan, Italy) suspension was injected through his cubital vein followed by a 5 mL saline flush. An iU22 ultrasound system (Royal Philips, the Netherlands) equipped with a C5-1 (1–5 MHz) transducer was used only for the examination. The mechanical index setting was 0.05 for CEUS. The depth, gain, and focus are thoroughly adjusted. Taking normal liver parenchyma as a reference, the contrast arrival time to the gallbladder lesion was 15 seconds after administration of the contrast agent, and the lesion was homogeneously hyper-enhanced in the arterial phase. The lesion began to get hypo-enhanced 42 seconds after contrast administration (Fig. 1). At the same time, CEUS showed disruption of the gallbladder wall integrity. On liver, the hepatic lesion appeared heterogenous mild enhancement in the arterial phase. In portal and parenchymal phase, the hepatic lesion displayed hypo-enhancement. The combination of gallbladder lesion enhancement pattern (hyper-enhancement in the early phase with hypo-enhancement in the late phase after contrast agent administration), disruption of the gallbladder wall integrity, and invasion in liver parenchyma (a

rapid washout at CEUS) yield a diagnosis of gallbladder malignant lesion accompanied by intra-hepatic metastasis.

Cholecystectomy, right hepatectomy, and lymphadenectomy were performed to remove the 2 masses. Microscopic examination revealed that the tumor consisted of 2 kinds of components: adenocarcinoma and sarcomatoid carcinoma. Adenocarcinoma accounted for the main structure: neoplastic columnar cells form tubular structures which had a papillary surface and also deeply infiltrated the entire thickness of the wall. These tumor cells were patchy and varied in size, and the nuclear-cytoplasmic ratio increased. Microscopic examination showed intense nuclear pleomorphism, nucleolus, and pathological mitotic figure. Meanwhile, sarcomatoid carcinoma region showed spindle-shaped cells and pleomorphic cells. Cancer tissue extensively infiltrated the muscular layer of the gallbladder wall, and a transition from adenocarcinoma region has been demonstrated (Fig. 2).

The patient had an uneventful recovery from the procedure. As the patient had no other symptoms or signs to indicate extra-manifestations of metastasis, no other imaging was performed.

In this paper, ethical approval was not necessary, as this article is a case report, which is based on the clinical information of the patient. Because our case is not refer to the patient's privacy, informed consent is not necessary, and the patient gave their permission for publication of the case.



**Figure 2.** Microscopically, neoplastic columnar cells form tubular structures and also deeply infiltrate the entire thickness of the wall (A). Hematoxylin-eosin stain ( $\times 100$ ). (B) It showed spindle-shaped cells and pleomorphic cells. Hematoxylin-eosin stain ( $\times 40$ ).

### 3. Discussion

Gallbladder adenocarcinoma is a relatively rare but highly malignant tumor with a dismal prognosis.<sup>[1]</sup> It is usually at an advanced stage when it is firstly detected owing to absence of symptoms at an early stage. Clinically, the infiltration to the gallbladder wall and the adjacent liver tissue is common, thus the surgical treatment usually includes cholecystectomy and partial liver resection. The literature consulted showed that the principal associated risk factor is cholelithiasis. Strong association also has been described with mixed bacterial and *Salmonella* infections, obesity, and porcelain gallbladder.<sup>[3–6]</sup>

Conventional US faces difficulties in determining the nature of some complicated gallbladder diseases. The insufficiency is largely because it has minimal ability in depicting vascularity in gallbladder diseases. Several studies showed that the utilization of CEUS substantially improves sensitivity and specificity for gallbladder lesions.<sup>[2]</sup> Compared with the vascular phases of the liver, only 2 vascular phases of the gallbladder can be followed: arterial phase (10–30 seconds after bolus injection) and late phase (31–180 seconds after contrast injection) because the blood supply of the gallbladder is provided entirely by the cystic artery and not by portal vein branches. The late phase persists for a short time in comparison with that in the liver.<sup>[7]</sup> Enhancement is assessed by comparing the echogenicity of a lesion with the echogenicity of the liver parenchyma. On differentiating malignant from benign gallbladder diseases, CEUS characteristics of gallbladder carcinoma have been described in this literature. Improved gallbladder wall visualization following contrast administration and the malignant feature of late-phase hypovascularity relative to the hepatic parenchyma may provide sharp demarcation of tumor outline.<sup>[8]</sup> Another appearance that can be observed in gallbladder carcinoma is a disruption of the gallbladder wall integrity.<sup>[7]</sup> In recent years, Thereis literature presented that the late phase washout of the contrast agent after administration may be a key for differential diagnosis. Liu et al<sup>[9]</sup> found that malignant gallbladder diseases present a faster washout time (41.4 seconds) than benign diseases (58.2 seconds). Xie et al<sup>[7]</sup> results showed that hyper-enhancement or iso-enhancement in the early phase then fading out to hypo-enhancement within 35 seconds after contrast agent administration was found in the majority of malignant lesions. In the case,

the performance of the gallbladder lesion had a slight difference with the literature. The lesion showed hyper-enhancement in the arterial phase of CEUS and began to be hypo-enhanced 42 seconds after contrast administration, which may be related to the composition of the tumor.

### 4. Conclusion

Gallbladder adenocarcinoma with sarcomatoid carcinoma accompanied by intra-hepatic metastasis is rare and difficult to diagnosis. Destruction of gallbladder wall intactness, the fast washout time on CEUS may provide valuable clues to the diagnosis. However, there is a need for further research on the identification of malignant tumor pathological subtype.

### Author contributions

**Supervision:** Yan Luo.

**Writing – original draft:** Hong Wang.

**Writing – review & editing:** Wenwu Ling.

### References

- [1] Pais-Costa SR, Farah JF, Artigiani-Neto R, et al. Gallbladder adenocarcinoma: evaluation of the prognostic factors in 100 resectable cases in Brazil. *Arq Bras Cir Dig* 2012;25:13–9.
- [2] Wang W, Fei Y, Wang F. Meta-analysis of contrast-enhanced ultrasonography for the detection of gallbladder carcinoma. *Med Ultrason* 2016;18:281–7.
- [3] Goldin RD, Roa JC. Gallbladder cancer: a morphological and molecular update. *Histopathology* 200;55:218–29.
- [4] Larsson SC, Wolk A. Obesity and a risk of gallbladder cancer: a meta-analysis. *Br J Cancer* 2007;96:1457–61.
- [5] Dutta U, Garg PK, Kumar R, et al. Typhoid carriers among patients with gallstones are at increased risk for carcinoma of the gallbladder. *Am J Gastroenterol* 2000;9:784–7.
- [6] Stephen AE, Berger DL. Carcinoma in the porcelain gallbladder: a relationship revisited. *Surgery* 2001;129:699–703.
- [7] Xie XH, Xu HX, Xie XY, et al. Differential diagnosis between benign and malignant gallbladder diseases with real-time contrast-enhanced ultrasound. *Eur Radiol* 2010;20:239–48.
- [8] Xu HX. Contrast-enhanced ultrasound in the biliary system: potential uses and indications. *World J Radiol* 2009;1:37–44.
- [9] Liu LN, Xu HX, Lu MD, et al. Contrast-enhanced ultrasound in the diagnosis of gallbladder diseases: a multi-center experience. *PLoS One* 2012;7:e48371.