

Congenital muscular torticollis: Use of gaze angle and translational deformity in assessment of facial asymmetry

Atul Bhaskar, Harish U¹, Hardik Desai²

ABSTRACT

Background: Assessment of facial asymmetry is challenging in torticollis deformity. Neck tilt in torticollis is associated with deviation of horizontal ocular gaze and translation of neck from the midline. These deviations can be assessed clinically and can be used as surrogate marker for facial asymmetry.

Materials and Methods: Thirty five children with congenital muscular torticollis (CMT) were classified into three grades of severity based on the new clinical score. The parameters included in the scoring system included rotational deficit, side flexion deficit, gaze angle (GA), and translational deformity (TD). Seven children had Grade I (mild), 18 had Grade II (moderate), and 10 had Grade III (severe) CMT. There were 21 girls and 14 boys with a mean age of 8.46 years (range 3–16 years). Twenty two children underwent a bipolar release, and 13 had unipolar surgery. Facial asymmetry (FA) signs were noted and based on GA and TD; all children had a deviation from the neutral angles (GA of 90° and 0 mm translation from the midsterna plumb line were considered neutral angle). The final outcome was based on the modified Cheng and Tang Score.

Results: The mean GA in Grade I, II, and III improved from 81.71 to 90, 72.77 to 89.16, and 66.60 to 88, respectively (Chi-square $P < 0.0001$). The TD improved from 15 mm to 0 mm, 25.83 mm to 3.05 mm, and 36.6 mm to 6 mm in Grade I, II, and III, respectively (Chi-square $P < 0.05$). The rotational and side flexion deficits also improved across all grades of severity but were not statistically significant ($P < 0.911$ and $P < 0.04$). Twenty four children had an excellent outcome with complete correction of their GA and TD. Four children with Grade II CMT and seven children with Grade III who had a residual translation of 5 mm or more and GA less than neutral horizontal had a good outcome. No child had problems with scar cosmesis or prominent lateral bands, and there was no recurrence of deformity at a mean followup of 28 months (range 24–32 months).

Conclusion: The GA and TD can be used to assess FA in torticollis management and significant improvement can be expected even in severe cases.

Key words: Congenital, muscular, torticollis, gaze angle, translational deformity, facial asymmetry

MeSH terms: Neck muscles, congenital, neuromuscular, wryneck, torticollis

INTRODUCTION

Congenital muscular torticollis (CMT) is a benign condition, but if left untreated leads to progressive shortening of the affected sternocleidomastoid muscle (SCM) and the surrounding soft tissues of the

neck.¹⁻⁴ This “wry-neck” deformity occurs due to the peculiar anatomy of the SCM, for example, a right side contracture causes neck tilt on the ipsilateral side and chin rotation to the contralateral side. Long standing or delayed presentation of CMT causes secondary contractures of the platysma muscle, neck muscles and deep fasciae of the neck, resulting in a tilt in ocular gaze, and alteration in facial profile on the affected side.⁵⁻⁷ Delay in the presentation of neglected CMT is not uncommon in the Indian subcontinent.^{8,9} Parents ignore the initial mild neck tilt and seek advice only when the physical deformity is advanced and associated with secondary features

Children Orthopaedic Clinic, ¹Department of Orthopaedics, R N Cooper Hospital, ²Paediatric Orthopaedic Fellow – Children Orthopaedic Clinic, Oshiwara, Mumbai, Maharashtra, India

Address for correspondence: Dr. Atul Bhaskar, Children Orthopaedic Clinic, Mhada, Oshiwara, Andheri, Mumbai - 400 053, Maharashtra, India. E-mail: arb_25@yahoo.com

Access this article online	
Quick Response Code:	Website: www.ijoonline.com
	DOI: 10.4103/ortho.IJOrtho_114_16

This is an open access article distributed under the terms of the Creative Commons Attribution-NonCommercial-ShareAlike 3.0 License, which allows others to remix, tweak, and build upon the work non-commercially, as long as the author is credited and the new creations are licensed under the identical terms.

For reprints contact: reprints@medknow.com

How to cite this article: Bhaskar A, Harish U, Desai H. Congenital muscular torticollis: Use of gaze angle and translational deformity in assessment of facial asymmetry. Indian J Orthop 2017;51:123-30.

such as facial asymmetry (FA) and ocular disturbance. Assessment of FA in CMT has received scant attention although it is one of the chief attributes of neglected CMT. Previous reports in the orthopedic literature have mentioned FA as present or absent without any objective measurement.^{10,11} Some authors have used radiographic parameters such as the Cobb angle or cervico-mandibular angle (CMA) to measure the neck tilt, but plastic and craniofacial surgeons have used complex cephalometric indices before planning reconstructive surgery.¹²⁻¹⁵ These changes in craniofacial deformity parameters are becoming increasingly important in future studies to assess the outcome of surgical treatment of torticollis.^{16,17} One study has reported statistically significant facial changes in CMT compared to normal cohort using the three-dimensional (3D) photogrammetry.¹⁸

The aim of our study was to analyze the results of treatment of CMT in children over 3 years of age with emphasis on FA using a lateral translation (LT) and gaze angle (GA) as simple clinical measurements.

MATERIALS AND METHODS

Thirty five children with CMT were reviewed prospectively between years 2004 and 2013 in the children orthopedic clinic. There were 21 girls and 14 boys in the study. The mean age at presentation for surgery was 8.46 years (range 3.8–16 years). Only children with muscle contracture as the cause of their torticollis were included in the study. Any child with underlying ocular, neurological, and skeletal pathology causing neck deformity was excluded from the study. Plain radiographs of the cervical spine were taken for every child to exclude congenital bony deformities and atlantoaxial pathology.

Preoperative assessment included the age of child at presentation, any previous history of swelling in the neck in infancy, side of involvement, and gender of the child. The degree of neck tilt and range of motion (ROM) of the neck like side flexion and limitation of rotation were recorded. The GA and neck translation in the midcoronal plane was also recorded as a measure of FA. A horizontal gaze (angle = 90°) was recorded as normal, and any deviation of the chin from the midsternal plumb line was recorded as a measure of translation (normal = 0 mm) [Figure 1].

Standardized photography technique for measurement of gaze angle was used. A point-and-shoot Nikon Coolpix camera was used; the camera had a fixed focus, a fixed aperture, and lens with a fixed focal length of 50 mm. The camera was secured and level mounted on a tripod; the tilt and rotate functions of the tripod were disabled. The camera lens was aimed at the patient's shoulder(s) which also determined the camera height. A constant subject-to-lens distance was maintained with a measuring tape. Only available lighting was used in a well lit room usually the clinic. The room's wall doubled as a background; in a few cases, however, the background's color or shade did vary.

An average of three readings were taken on the physical photograph using a hand-held goniometer. The angle measured was further confirmed on the same photograph by using the Measure and Sketch®, version 2.4.2. The translational deformity (TD) was measured clinically on the child using the midsternal plumb line, and a vertical line from the tip of the chin with the shoulder held square. The horizontal deviation of the tip of the chin from the plumb line was recorded as the amount of translation of the neck from the midline. Other characteristics of FA such as malar

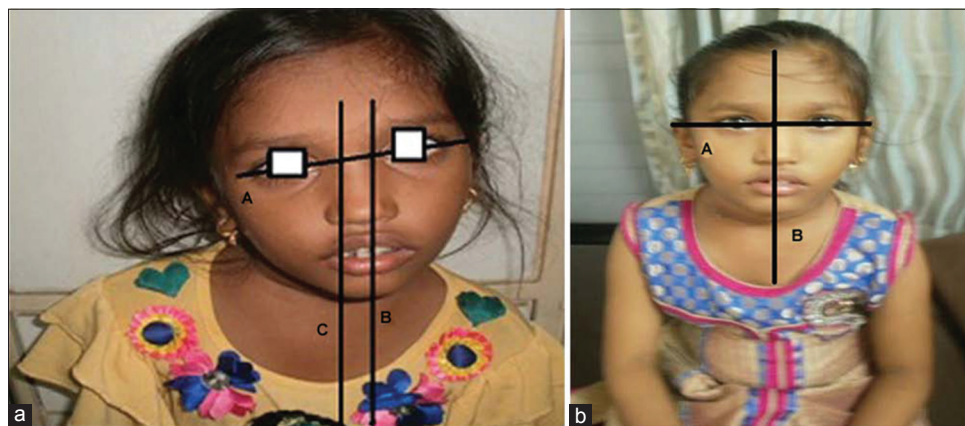

Figure 1: Clinical photograph of 7.8-years-old girl, with right side, Grade II torticollis showing (a) Measurement for gaze angle and translational deformity measurements Line A: Horizontal axis through the outer canthus of both eyes Line B: Vertical line through the tip of the chin Line C: Vertical "Plumb" line through the midsternal point. The angle between Line A and C is a measure of gaze angle in degrees. Line A perpendicular to Plumb Line C is the normal alignment (90°) The horizontal deviation of chin (Line B) from the plumb line (Line C) denotes an amount of translational malalignment. (b) Complete correction of translational deformity from 30 to 0 mm and gaze angle from 75° to horizontal 90° at 16 months followup

prominence, flattening of skull of affected side, and mastoid prominence were also recorded as present or absent.

The torticollis deformity was graded as mild, moderate, and severe based on the above parameters [Table 1].

The authors did not use any radiographic parameter to quantify the severity of torticollis as this would necessitate the use of radiographs in the postoperative followup, exposing the children to unwanted radiation.

Operative procedure

All children underwent soft tissue surgery under general anesthesia with precise neck positioning to allow intraoperative neck maneuvers to assess the completeness of surgical release. The endotracheal tube was well secured to avoid dislodgement during neck movements.

An intrascapular pad was placed to elevate the upper thorax and with neck extension supported on a padded ring. The upper torso was stabilized, and the ipsilateral arm was fixed with micropore tape to depress the shoulder. These steps were taken to make the affected SCM more prominent and accessible to surgery. The neck was aligned with a removable table top so that intraoperative neck maneuvers could be carried out. A standard, transverse supraclavicular incision approximately 4–5 cm in length was made in line with the skin crease. After incising the platysma, the fascial covering over the clavicular and sternal heads was opened, and both the heads of the SCM were exposed. Using a Mixer forceps, the sternal head was elevated and 1–2 cm of the muscle with the fibrotic area was excised. Next, the clavicular origin was dissected free from the underlying fascia and incised along with the deep fascia. In severe cases, the carotid sheath was also opened, and the omohyoid muscle was also incised. Next, the end of the table was detached with the assistant surgeon supporting the head and neck to perform intraoperative rotational and translational maneuvers. Any additional taut fascial or muscular bands on palpation were incised taking care of the supraclavicular nerves. After the surgery, the skin was approximated with absorbable sutures and a customized cervical collar with overcorrection was fitted to the child.

Table 1: Classification of torticollis

	Gaze Angle (degrees)	Translational deformity (millimeter, mm)	Rotational deficit (degrees)
Grade I			
Mild	80-90	<15	<15
Grade II			
Moderate	70-79	15-30	15-30
Grade III			
Severe	<70	>30	>30

The postoperative protocol involved an aggressive active and passive physiotherapy program after 1 week. The therapy duration was a minimum 45 min including passive rotation, specific LT, and lateral flexion exercises to stretch completely the released tissue. The collar was kept for 12 h each day for 6 weeks, and 6 h each day for further 6 weeks.

Side-to-side neck movements called Greeva Bheda, (Greeva = neck, Bheda = movement, in Sanskrit language) is an integral part of classical Indian dance form called Bharatanatyam.¹⁹ This specific movement was incorporated into the physiotherapy regime to improve translational malalignment and neck ROM in our patients.

At followup, the child was assessed for wound healing, passive ROM of neck, LT, GA, and lateral column of the neck. At final assessment, we used the Cheng and Tang system with modification,²⁰ including GA and LT for obtaining final outcome.

The results were graded as excellent, good, fair, and poor based on subjective and objective criteria.

RESULTS

The mean followup period was 28 months (range 24–32 months) after the initial surgery. There were 7 children with mild torticollis (Grade I), 18 with moderate (Grade II), and 10 with severe torticollis (Grade III). The mean age in the three groups was 6.11 years (range 3.8–8.2 years), 8.53 years (range 4.4–13 years), and 10.81 years (range 5.2–16 years), respectively.

The mean preoperative translational malalignment was 15 mm (range 10–20 mm) in Grade I, 26.38 mm (range 15–40 mm) in Grade II, and 35 mm (range 30–40 mm) in Grade III torticollis, and the mean GA measurements in three grades were 81.17° (range 80–84°), 72.77° (range 70–79°), and 65.6° (range 60–69°) respectively.

The rotational deficit in mild torticollis was <15° and in severe torticollis was more than 30°. In moderate torticollis, three children had rotational deficit of more than 30°, one had deficit of <15°, and the remaining 14 children had rotational deficit between 15° and 30°. For lateral flexion, the mean deficit was 12.85° (range 10–15°) in Grade I, 20.55° (range 15–30°) in Grade II, and 26° (range 20–40°) in Grade III [Table 2].

FA signs (difference in size of malar eminence, flattening of occiput, mastoid prominence, recessed eyebrow, and zygoma) were present in all children with severe

Table 2: Patient demographic in three groups

	No	Age	GA	TD	RD	SF
Grade I	7	6.11 (3.8-8.3)	81.17 (80-84)	15 (10-15)	8.85 (8-12)	12.85 (10-15)
Grade II	18	8.53 (4.4-13)	72.77 (70-79)	25.83 (15-30)	24.55 (16-34)	20.55 (15-30)
Grade III	10	10.81 (5.2-16)	65.60 (60-79)	36.6 (30-40)	35.3 (33-40)	26 (20-40)

No=Number of children, Age=Mean age in years, GA=Gaze Angle in Degrees, TD=Translational Deformity in millimeter (mm), RD=Rotational Deficit, SF=Side Flexion Deficit

Table 3: Scoring of results following surgery for torticollis (modified Cheng and Tang Score)

Results	Excellent	Good	Fair	Poor
Rotational Deficit (0)	<10	11-15	16-30	>30
Lateral Flexion Deficit (0)	<10	11-15	16-30	>30
Lateral Translation (mm)	<5mm	6-10	11-20	>20
Gaze Angle (0)	90	85-89	75-84	<75
Scar	None	Mild	Moderate	Severe
Subjective Assessment (cosmetic & functional)	Excellent	Good	Fair	Poor
Craniofacial Asymmetry	None	Mild	Moderate	Severe

torticollis ($n = 10$) and moderate torticollis ($n = 18$) and were present in three cases in mild torticollis. However, as per GA and translational measurements, all children had a deviation from the neutral score.

Children were assessed at 6 week's, 3 month's, and at 6 month's intervals until final followup. The orthotic collar was discontinued after 3 months. The postoperative results at final followup based on the modified Cheng and Teng^{20,21} system are given in Table 3.

In Grade I, all seven children had residual rotation and flexion deficit of $<5^\circ$, no residual LT and the GA of 90° horizontal or normal. Three of the seven children who had signs of FA improved at final followup.

In Grade II, the residual rotation deficit was $<10^\circ$ for all children and the mean lateral flexion deficit was 4.56° (range $0-9.8^\circ$). The mean residual translation was 3.05 mm (range $0-10$ mm), and the residual GA was 89.16° (range $85-90^\circ$). FA improvement was seen in 14 children with the exception of four children who had LT of 10 mm and 5 mm, respectively, and $<90^\circ$ of GA.

In Grade III, the rotational deficit was $<10^\circ$ and the residual flexion deficit was 6.17° (range $0^\circ-14^\circ$). The mean residual translation was 6 mm (range $0-10$ mm), and the mean GA was 88° (range $85-90^\circ$). Seven of the ten children in this group had persistent signs of FA.

Inferential statistics was done by using Epi Info 7.1.1.14. (US Dept of Health and Human Services, Atlanta, USA) For all statistical tests, $P < 0.05$ was considered as statistically significant. The results for continuous variables were given as mean \pm standard deviation and as proportions and percentages wherever relevant.

There was a significant improvement in GA and translational deformity in all three groups [Table 4].

All children had a cosmetic scar except one child in Grade III who developed a hypertrophic scar during followup. There were no wound infections or recurrence of deformity requiring any further surgery. Persistent lateral bands were seen in five children, two in Group II, and three in Group III.

In the final analysis, 11 (31.42%) of the 35 children at final followup had FA as measured by residual translation deformity and $<90^\circ$ of GA. Thus, in mild grade (Grade I), all children had excellent results, in moderate deformity (Grade II), there were 14 children with an excellent outcome and 4 with a good outcome and in severe torticollis (Grade III), 3 children had excellent results, and 7 were graded as good. No child had poor or fair results, indicating that surgical correction is warranted even in older children to improve their GA and LT [Table 5].

DISCUSSION

The exact timing for surgical intervention in late presenting CMT is unclear.^{1,21-24} The successful outcome depends on several factors: Age at presentation, degree of fixed deformity, FA, and postoperative compliance with physiotherapy. Some authors advise early surgery before age four; others recommend surgery after 8 years as the postoperative bracing compliance is better in older children.^{10,12,25-27}

In the Indian context, parents delay correction of progressive deformity due to a variety of reasons; fear of surgery being the foremost. This is reflected in the higher mean age in this series; there were only seven cases with mild torticollis deformity. Many parents seek help from traditional healers and bone setters in the hope of avoiding any corrective surgery. Surgical opinion is considered only when the neck deformity is severe and starts to cause significant head tilt impacting the cosmetic appearance of the face. When parents do consent for surgical intervention, their expectations include complete correction of FA along with the neck deformity. It is unclear when the FA sets in an untreated case of CMT, but early intervention gives the best chance for complete restoration of facial incongruity.^{21,22,28} In this study too, all children with mild deformity (Group I) had complete resolution of their FA. A recent metaanalysis

Table 4: Comparative analysis of gaze angle, translational deformity, rotational deficit and lateral flexion deficit in three groups

	Pre-operative	Post-operative	Pre-operative	Post-operative
	Mean gaze angle (in degrees)		Translational deformity (mm)	
Grade I	81.17 (80-84)	90	15 (10-20)	0
Grade II	72.77 (70-79)	89.16 (85-90)	25.83 (15-30)	3.05 (0-10)
Grade III	65.6 (60-79)	88 (85-90)	36.6 (30-40)	6 (0-10)
	Rotational deficit (in degrees)		Lateral flexion deficit (in degrees)	
Grade I	8.85 (8-12)	<5	12.85 (10-15)	<5
Grade II	24.55 (16-34)	5-10	20.55 (15-30)	4.56 (0-9.8)
Grade III	35.3 (33-40)	5-10	26 (20-40)	6.17 (0-14)

Table 5: Final result in three groups of patients with torticollis

	No	GA	TD	RD	Result
Grade I	7	90	0	<5	7 E
Grade II	18	89.16 (85-90)	3.5 (0-10)	5-10	14 E, 4 G
Grade III	10	88 (85-90)	6 (0-10)	5-10	3 E, 7 G

No=No of children in each group, GA=Gaze angle in Degrees (90degrees=Normal, horizontal gaze), TD=Translational Deformity in millimeters (mm), RD=Rotational Deficit in Degrees, Result: E=Excellent, G=Good (Modified Cheng and Tang Score)

reviewed 12 studies with satisfactory and successful correction, even in children older than 15 years. Both ROM and skeletal deformities showed improvement using cervicomandibular and Cobb angle.¹⁷

There is no standard classification to grade severity of torticollis. Cheng and Teng in their landmark paper of 84 children with CMT classified them into four age groups for the purpose of assessment (age groups <1 year, 1–3 years, 3–10 years and older than 10 years) and used passive limitation of neck rotation to grade the severity of the deformity into four groups: Rotation Group I had no (0°) deficit, followed by 15° increments in the other three groups. The most severe rotation Group IV had rotation deficit greater than 30°. At final assessment, 92.5% of children were in rotation Group I, after a mean interval of 5 years. The authors described signs for cranio FA and also noted head tilt (mild, moderate, and severe) but without any objective measure. Lee *et al.*, too, used a subjective classification of head tilt (none, mild, moderate, and severe) as a part of their scoring system for outcome assessment and reported successful results in children below 12 years of age.⁷

Canale *et al.* in their long term followup study of CMT with 57 children categorized the children in three age groups (<1 year, 1–10 years, and >10 years) at the time surgery. They also used 30° loss of rotation as their indication for surgery. Final assessment in their series was based on improvement in neck function and craniofacial cosmesis. All 57 children had little functional abnormality, but 31% who had persistent head tilt had noticeable cosmetic deformity. Poor results were seen in children who had an established

FA and severe restriction of neck motion regardless of the type of treatment.¹⁰

No study to date has looked at the same pre- and postoperative criteria for both assessment and outcome. We have attempted to close that gap by having a clinical score using the same parameters at initial review and final assessment. Although, in this study, the mean age in Grade III torticollis was higher, even children <8 years had a significant neck tilt and translation as measured by the GA and TD. Thus, age-based classification to determine the outcome of treatment is unreliable. Instead of age-based classification, we have incorporated GA and LT along with rotational deficit and side flexion deficit to categorize the severity of Torticollis. We did not use any radiographic parameter such as Cobb angle or CMA as this measures only a 3D deformity that too in the one plane and requires serial radiographs. Moreover, the other limitations of both computed tomography (CT) and radiographic measurements are that they only measure craniofacial deformity but not true facial topographic asymmetry and are also operator dependent.

While the orthopedic intervention is mainly directed toward the neck deformity, the resulting improvement in facial appearance accounts for both patient and parents satisfaction. This objective analysis of FA analysis has been receiving recent attention as imaging modalities and software programs have improved to assess facial profile. Lee *et al.* analyzed the changes in cephalometric parameters in two groups of children who underwent surgery before 5 years or after 5 years. Lee *et al.* concluded that preoperative craniofacial asymmetry as measured by “transverse calvarial asymmetry” and “transverse skull-base asymmetry” was more severe in children older than 5 years, and the results were superior if sternocleidomastoid release was performed before 5 years.⁷ However, these assessments require radiographs in the followup period and measure only bony contours as opposed to soft tissue asymmetry. They further concluded that the postoperative improvements in cephalometric parameters are more rapid in the 1st year than during the 2nd year.

Preoperative assessment with 3D-CT scanning and 3D photogrammetry of various components of facial symmetry is routinely done before any craniofacial, orthodontic, and cosmetic reconstructive procedure. According to Severt and Proffit, minor FA can be observed even in normal appearing individuals and in most cases the left side appeared larger than right. The frequencies of facial laterality are 5%, 36%, and 74% in the upper, middle, and lower thirds of the face.²⁹

Chew reported asymmetry in 35.8% of 212 patients with dentofacial deformities, majority of cases being in patients with class III occlusal deformity. Among the patients reporting for orthodontic treatment, the most common asymmetry trait observed is mandibular midline deviation from the facial midline occurring in 62% of patients.³⁰

Baratta *et al.*¹⁸ used 3D photogrammetry to quantify facial surface asymmetry in patients with CMT and compare such patients with age-matched controls. The asymmetry resulting from torticollis was given a numeric value known as the root mean square deviation. This value was calculated for the upper, middle, and lower facial thirds as defined by the facial landmarks shown to isolate region with the greatest asymmetry. Baratta *et al.* concluded that torticollis cases had statistically significant greater whole face, upper third, and middle third FA than age-matched controls ($P < 0.05$). As imaging techniques and portability of devices improve, FA assessment tools may get increasingly relevant in future to grade the results of surgical intervention.

Clinical measurement, though “error prone” can serially and objectively assess the deformity using inexpensive tools which can be used in the clinical setting. GA is measured on standardized photographs using the midsternal longitudinal plumb line and the second transverse line traversing through the outer canthus of the eyes. The acute angle formed between these two lines reflects the amount of fixed neck tilt. Normal angle is 90°, i.e., the gaze is neutral or horizontal in unaffected children. This Frankfort horizontal line is well described in the ophthalmological literature and the position of eyes in the frontal plane is held tightly, with few degrees of variation.^{31,32} The second parameter assessed was the horizontal translation or deviation of chin from the midsternal plumb line just as lateral deviation is measured in idiopathic scoliosis from the central plumb line. This parameter is measured clinically and an average of three readings is considered for final calculation.

Sudesh *et al.* reported in children over 10 years of age (age groups 10–19) in the Indian subcontinent a total of 14 cases with CMT treated with a bipolar release. All children received head-halter traction for 3 weeks in the postoperative period and then intermittently for further

3 weeks at night only. Although these authors commented on the improvement in both head-tilt and chin deviation in their final followup, only head-tilt was included as a part of the final analysis.⁸ Shim and Jang reviewed 47 patients with CMT and classified them into two groups, those aged between 1 and 4 years (Group I) and those between 5 and 16 years (Group II). Although excellent results were seen in 33 children while 14 had good outcome, correction of craniofacial asymmetry as measured by CMA was excellent only in 22 children. Thus, Shim and Jang suggest that surgery for CMT may be delayed until children can comply with rigorous postoperative rehabilitation protocol.¹² Moreover, complete restoration of FA is not always possible and parents of older children must be counseled accordingly before embarking on surgical intervention.^{10,15,17,33,34}

In this study, 24 children (65.17%), who had complete correction of their GA and TD, were perceived as having satisfactory outcome by their parents. In 11 children (31.42%), who had incomplete restoration of their GA and persistent translation of 5 mm, were perceived as having less satisfactory outcome [Figure 2a and b].

Although restricted neck movement is one of the features of torticollis, children though seldom complain of loss of neck motion. It has been our observation that although there was improvement in both rotational and lateral flexion deficit in all children, neither the children nor their parents were much concerned about their neck motion. In some cases, parents were advised by school authorities to seek ophthalmological opinion for their children due to a persistent neck-tilt posture.³⁵ Thus, correction of GA and neck deviation in the postoperative phase elicited a more satisfactory response from the parents.

Wirth *et al.* had in fact proposed a bipolar release in all children between 3 and 5 years of age with persistent neck deformity.²⁶ However, in our study, 22 children underwent a bipolar release, ten cases had Grade III torticollis, and 12 children had Grade II torticollis. The decision to perform unipolar or bipolar release was based on intraoperative neck maneuvers until full correction of neck deformity and translation was achieved. The authors of this study feel that incorporating these two measurements of GA and TD give us an objective measure to rate asymmetry [Figure 3a-c].

There are potential limitations in this study. This is a single surgeon series, with potential for selection bias. Measurements for GA, TD, and ROM were done manually, so there is a risk of error. No inter-rater and intra-rater reliability testing were done for these measurements. Two orthopedic registrars who were involved in the study took three separate readings, and the average was recorded

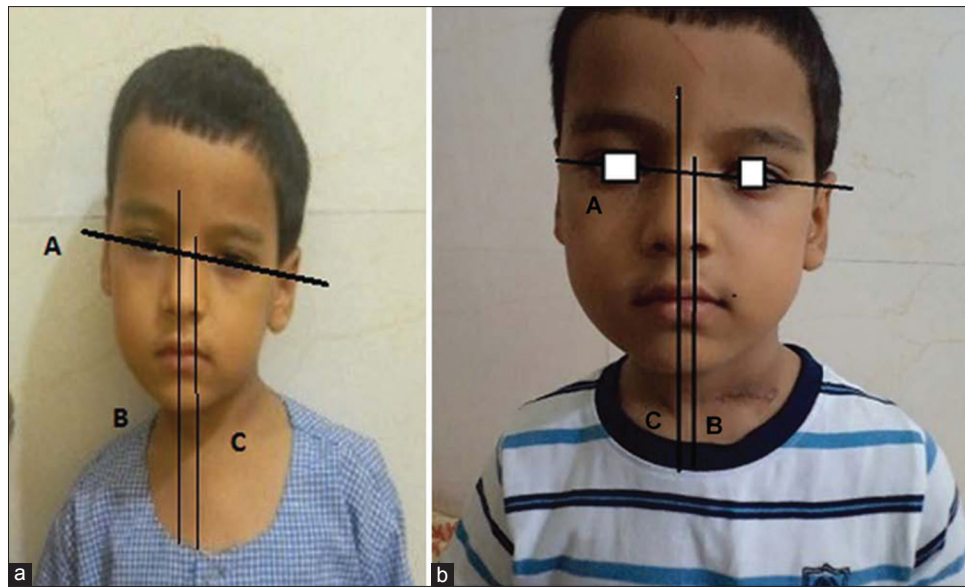

Figure 2: Clinical photograph of a boy, 7.6 years old with Grade II torticollis showing (a) The preoperative gaze angle was 75° and the translational deformity was 30 mm with rotational deficit of 20° . (b) Postoperative photograph at 22 months followup with residual translational deformity of 5 mm and gaze angle of 85° . He has terminal 5° loss of rotation. This was classified as a good result




Figure 3: Clinical photograph of 13.4 year old girl with Grade III torticollis showing (a) The preoperative gaze angle was 65° , translational deformity was 40 mm. (b) Taut band of sternocleidomastoid seen with left side rotation. The rotational deficit was 40° (c) Postoperative photograph at 24 months followup after a bipolar release. The gaze angle was restored to normal and the translational deformity was 5 mm with mild facial asymmetry. She had an excellent outcome on modified Cheng and Tang score

as the final value. However, these simple assessments measured serially on the patient pre and post-treatment helps to determine the efficacy of surgical correction.

In future, better understanding of this 3D deformity using specialized imaging techniques and measurements can render assessments more objective and reproducible and hopefully may improve treatment outcomes.^{6,14,36}

Declaration of patient consent

The authors certify that they have obtained all appropriate patient consent forms. In the form the patient(s) has/have given his/her/their consent for his/her/their images and other clinical information to be reported in the journal. The patients understand that their names and initials will not be published and due efforts will be made to conceal their identity, but anonymity cannot be guaranteed.

Acknowledgment

We would like to acknowledge Dr. Imtiaz Ahmed, MBBS. MD. MIPHA, for his help with the statistics.

Financial support and sponsorship

Nil.

Conflicts of interest

There are no conflicts of interest.

REFERENCES

1. Ling CM, Low YS. Sternomastoid tumor and muscular torticollis. *Clin Orthop Relat Res* 1972;86:144-50.
2. Davids JR, Wenger DR, Mubarak SJ. Congenital muscular torticollis: Sequela of intrauterine or perinatal compartment syndrome. *J Pediatr Orthop* 1993;13:141-7.

3. Tang S, Liu Z, Quan X, Qin J, Zhang D. Sternocleidomastoid pseudotumor of infants and congenital muscular torticollis: Fine-structure research. *J Pediatr Orthop* 1998;18:214-8.
4. Hulbert KF. Congenital torticollis. *J Bone Joint Surg* 1960;32-B: 50-9.
5. Hollier L, Kim J, Grayson BH, McCarthy JG. Congenital muscular torticollis and the associated craniofacial changes. *Plast Reconstr Surg* 2000;105:827-35.
6. Yu CC, Wong FH, Lo LJ, Chen YR. Craniofacial deformity in patients with uncorrected congenital muscular torticollis: An assessment from three-dimensional computed tomography imaging. *Plast Reconstr Surg* 2004;113:24-33.
7. Lee JK, Moon HJ, Park MS, Yoo WJ, Choi IH, Cho TJ. Change of craniofacial deformity after sternocleidomastoid muscle release in pediatric patients with congenital muscular torticollis. *J Bone Joint Surg Am* 2012;94:e93.
8. Sudesh P, Bali K, Mootha AK, Dhillon MS. Results of bipolar release in the treatment of congenital muscular torticollis in patients older than 10 years of age. *J Child Orthop* 2010;4:227-32.
9. Patwardhan S, Shyam AK, Sancheti P, Arora P, Nagda T, Naik P. Adult presentation of congenital muscular torticollis: A series of 12 patients treated with a bipolar release of sternocleidomastoid and Z-lengthening. *J Bone Joint Surg Br* 2011;93:828-32.
10. Canale ST, Griffin DW, Hubbard CN. Congenital muscular torticollis. A long term followup. *J Bone Joint Surg Am* 1982;64:810-6.
11. Shim JS, Noh KC, Park SJ. Treatment of congenital muscular torticollis in patients older than 8 years. *J Pediatr Orthop* 2004;24:683-8.
12. Shim JS, Jang HP. Operative treatment of congenital torticollis. *J Bone Joint Surg Br* 2008;90:934-9.
13. Karmel-Ross K. Torticollis: Differential Diagnosis, Assessment and Treatment, Surgical Management and Bracing. Binghamton, New York: Haworth Press; 1997.
14. Ferguson JW. Cephalometric interpretation and assessment of facial asymmetry secondary to congenital torticollis. The significance of cranial base reference lines. *Int J Oral Maxillofac Surg* 1993;22:7-10.
15. Arslan H, Gündüz S, Subasi M, Kesemenli C, Necmioglu S. Frontal cephalometric analysis in the evaluation of facial asymmetry in torticollis, and outcomes of bipolar release in patients over 6 years of age. *Arch Orthop Trauma Surg* 2002;122:489-93.
16. Seo SJ, Kim JH, Joh YH, Park DH, Lee IJ, Lim H, *et al.* Change of facial asymmetry in patients with congenital muscular torticollis after surgical release. *J Craniofac Surg* 2016;27:64-9.
17. Kim HJ, Ahn HS, Yim SY. Effectiveness of surgical treatment for neglected congenital muscular torticollis: A systematic review and meta-analysis. *Plast Reconstr Surg* 2015;136:67e-77e.
18. Baratta VM, Linden AE, Byrne M, Klinge PM, Sullivan SR, Taylor HO. A Quantitative Analysis of Facial Asymmetry in Congenital Muscular Torticollis (CMT) Using Three-Dimensional Photogrammetry. *JCFS*; 2013.
19. Neck Movement or GreevaBheda in bharatanatyam link. Available from: <http://www.dancesinthefarsouth.weebly.com/information/bhedas>. onlinebharatanatyam.com/2010/02/12/greeva-bheda-or-neck-movements Feb 2012. [Last accessed on 2016 Aug 10].
20. Cheng JC, Tang SP. Outcome of surgical treatment of congenital muscular torticollis. *Clin Orthop Relat Res* 1999;362:190-200.
21. Cheng JC, Tang SP, Chen TM, Wong MW, Wong EM. The clinical presentation and outcome of treatment of congenital muscular torticollis in infants – A study of 1,086 cases. *J Pediatr Surg* 2000;35:1091-6.
22. Cheng JC, Wong MW, Tang SP, Chen TM, Shum SL, Wong EM. Clinical determinants of the outcome of manual stretching in the treatment of congenital muscular torticollis in infants. A prospective study of eight hundred and twenty-one cases. *J Bone Joint Surg Am* 2001;83-A: 679-87.
23. Minamitani K, Inoue A, Okuno T. Results of surgical treatment of muscular torticollis for patients greater than 6 years of age. *J Pediatr Orthop* 1990;10:754-9.
24. Ippolito E, Tudisco C. Idiopathic muscular torticollis in adults. Results of open sternocleidomastoid tenotomy. *Arch Orthop Trauma Surg* 1986;105:49-54.
25. Ling CM. The influence of age on the results of open sternomastoid tenotomy in muscular torticollis. *Clin Orthop Relat Res* 1976;86:142-8.
26. Wirth CJ, Hagen FW, Wuelker N, Siebert WE. Biterminal tenotomy for the treatment of congenital muscular torticollis. Long term results. *J Bone Joint Surg Am* 1992;74:427-34.
27. Lee EH, Kang YK, Bose K. Surgical correction of muscular torticollis in the older child. *J Pediatr Orthop* 1986;6:585-9.
28. Coventry MB, Harris LE. Congenital muscular torticollis in infancy; some observations regarding treatment. *J Bone Joint Surg Am* 1959;41-A: 815-22.
29. Severt TR, Proffit WR. The prevalence of facial asymmetry in the dentofacial deformities population at the University of North Carolina. *Int J Adult Orthodon Orthognath Surg* 1997;12:171-6.
30. Chew MT. Soft and hard tissue changes after bimaxillary surgery in Chinese Class III patients. *Angle Orthod* 2005;75:959-63.
31. Maheshwari S, Verma SK, Gaur A, Dhiman S. Diagnosis and management of facial asymmetries. *J Orthod Res* 2015;3:81-7.
32. Ercan I, Ozdemir ST, Etoz A, Sigirli D, Tubbs RS, Loukas M, *et al.* Facial asymmetry in young healthy subjects evaluated by statistical shape analysis. *J Anat* 2008;213:663-9.
33. Emery C. The determinants of treatment duration for congenital muscular torticollis. *Phys Ther* 1994;74:921-9.
34. Do TT. Congenital muscular torticollis: Current concepts and review of treatment. *Curr Opin Pediatr* 2006;18:26-9.
35. Williams CR, O'Flynn E, Clarke NM, Morris RJ. Torticollis secondary to ocular pathology. *J Bone Joint Surg Br* 1996;78:620-4.
36. Kim JW, Kim SH, Yim SY. Quantitative analysis of magnetic resonance imaging of the neck and its usefulness in management of congenital muscular torticollis. *Ann Rehabil Med* 2015;39:294-302.