



**Original Article**

## **Transient Elastography (TE) is a Useful Tool for Assessing the Response of Liver Iron Chelation in Sickle Cell Disease Patients**

Sophia Delicou<sup>1</sup>, Konstantinos Maragos<sup>1</sup>, Maria Tambaki<sup>2</sup>, Dimitrios Kountouras<sup>2</sup> and John Koskinas<sup>2</sup>.

<sup>1</sup>Thalassemia and Sickle Cell Department, Hippocratio General Hospital Athens.

<sup>2</sup>Second Academic Department of Medicine, School of Medicine, National and Kapodistrian University of Athens, Hippokratio General Hospital Athens.

**Competing interests:** The authors have declared that no competing interests exist.

**Abstract.** Sickle cell disease patients often need regular blood transfusions to improve both the quality of life and survival from the veno-occlusive complications of the disease. Deferasirox, a convenient long acting oral agent, has recently been introduced in clinical practice with promising efficacy.

This study aims to evaluate the association of liver stiffness and possible fibrosis with iron deposition and confirm the use of elastography as a validated test of responding to chelation with low cost and easy access.

15 patients with sickle cell disease and systemic or occasional transfusions were evaluated with MRI, transient elastography and biochemistry, for liver iron(LIC) and liver stiffness(LSM) before onset and one year after taking Deferasirox. All patients completed the study.

Our results showed improvement in hepatic iron and hepatic stiffness after chelation therapy; Furthermore ALT, AST, LDH and ferritin levels have improved after 12 months of therapy with deferasirox. During the study no serious adverse events were encountered indicating the safety of the drug.

Transient liver elastography findings correlate with serum ferritin and LIC in patients with sickle cell disease and it is a useful tool for assessing the response of liver iron chelation therapy.

**Keywords:** Sickle cell disease, Iron chelation, Transient elastography, Transfusion, Iron overload.

**Citation:** Delicou S., Maragos K., Tambaki M., Kountouras D., Koskinas J. Transient elastography (TE) is a useful tool for assessing the response of liver iron chelation in sickle cell disease patients. *Mediterr J Hematol Infect Dis* 2018, 10(1): e2018049, DOI: <http://dx.doi.org/10.4084/MJHID.2018.049>

**Published:** September 1, 2018

**Received:** April 24, 2018

**Accepted:** August 6, 2018

This is an Open Access article distributed under the terms of the Creative Commons Attribution License (<https://creativecommons.org/licenses/by-nc/4.0/>), which permits unrestricted use, distribution, and reproduction in any medium, provided the original work is properly cited.

Correspondence to: Sophia Delicou – MD, Hematologist, Thalassemia and Sickle Cell Department, Hippocratio General Hospital Athens. Address:114 Leof. Vasilissis Sofias, Athens 115 27. E-mail: [sophiadelicou@hippocratio.gr](mailto:sophiadelicou@hippocratio.gr)

**Introduction.** Chronic transfusion therapy is being used more frequently to prevent and treat the complications of sickle cell disease. Previous studies have shown that the iron overload that results from such therapy in other patient populations is associated with significant morbidity and mortality.<sup>1</sup> Deferoxamine has been the standard drug for iron chelation therapy over the past four decades. However, its major

disadvantage is non-compliance of patients, because it needs an 8- to 12-hr parenteral administration since it has a short half-life and a very poor oral bioavailability. Deferiprone was the first extensively studied oral chelating agent in the early 2000s for patients who were unable to use deferoxamine effectively or safely. Although deferiprone-treated patients had good compliance in thalassemic patients, some serious side effects

such as neutropenia and agranulocytosis were reported that limited its use in sickle cell disease patients especially in combination with hydroxyurea.<sup>2,3</sup>

A more convenient oral iron chelator, deferasirox, has recently become available showing promising efficacy. Many studies have shown that deferasirox has an acceptable profile of safety and tolerability in thalassemic patients.<sup>2,4,5</sup>

Liver iron concentration has been regarded as the reference standard for estimating body iron load in thalassemic patients and has been shown to predict total body iron stores accurately. In sickle cell anemia, the liver is one of the target organs of the disease itself, except the transfusional iron overload. The term "sickle cell hepatopathy" has sometimes been used to reflect the overlapping acute and chronic causes of liver dysfunction in these patients. Studies in patients that have been hospitalized due to an acute vasoocclusive crisis have estimated the frequency of liver involvement ranging from 10% to 39% and an autopsy study of sickle cell patients has revealed the presence of hepatic infarction in 34% of patients.<sup>6,7</sup>

Prior studies have based on data from hereditary hemochromatosis and thalassemia major showing that elevated hepatic iron content determined by liver biopsy and imaging techniques over 7 mg/g liver dry weight is a risk factor for hepatic fibrosis. Therefore this value has been used as a guide to start chelation therapy.<sup>4,5,7,8</sup>

Transient elastography and has been extensively validated in chronic liver diseases and is currently used for detection and staging of liver fibrosis.

In the last few years, liver stiffness measurement (LSM) by transient elastography (TE) has been shown to be closely related to the degree of hepatic fibrosis assessed by biopsy in thalassemic patients.<sup>9,10</sup>

However, hepatic involvement has been shown to affect liver stiffness in patients with sickle cell disease during acute vaso-occlusive crisis measured with transient elastography.<sup>11</sup>

The study aimed to evaluate the role of elastography (Liver Stiffness Measurement, LSM, kPascals, FibroScan, Echosens, Paris, France) in patients with SCD and explore possible correlations with clinical and laboratory characteristics, mainly those associated with iron overload.

## Materials and Methods.

*Study Design and Patient Population.* Patients maintained on transfusion therapy either currently, or previously, were screened for eligibility between April 2014 and April 2015.

Fifteen patients with SCD who are followed-up in the Thalassemia and Sickle Cell Unit of Hippokrateion General Hospital in Athens, Greece were enrolled in the study. All patients completed the study.

Five patients had HbS/HbS, and thirteen had HbS/beta-thal; their median age was 45,8 years (range: 19–75 years). Seven patients were males and eight females.

Patients received regular blood transfusions or had sporadically transfused with at least 20 units of packed red blood cells during the last five years. Exchange or simple transfusions were allowed. Transfused red cells were negative for hemoglobin S, phenotypically matched and depleted of leukocytes and were delivered in a volume of approximately 10 to 15 ml per kilogram of packed cells per transfusion. The goal of the transfusion protocol for all patients was to maintain their hemoglobin S (HbS) percentage at or below 50% and the pre-hemoglobin and post-hemoglobin greater than 9 g/dL and less than 12 g/dL, respectively.

The initial dose of DFX was calculated based on the patient's body weight (10-40 mg/kg/day). The 20-mg/kg dose was considered appropriate for patients requiring reduction of a moderate iron burden, and a higher dose of 30-40 mg/kg was felt to be appropriate for patients with high iron burdens requiring major reduction of excess iron. Lower doses of 10-mg/kg were selected for maintenance use in patients with lower LIC values. DFX was taken daily every morning 30 minutes before breakfast, dispersed in a glass of water. Prior chelation therapy was permitted but was not mandatory. The serum ferritin level for entry into the study was  $\geq 500$   $\mu\text{g/l}$ .

Patients eligible for entry into the study had performed MRI using a multi-gradient recalled echo (MGRE) sequence which allowed the determination of liver T2\*, a relaxation time constant sensitive to the presence of liver iron, inversely proportional to liver LIC (Liver Iron Concentration).

They also had performed Liver stiffness measurement (LSM) using transient elastography (Fibroscan). A pulse-echo ultrasound acquisition is

used to follow the propagation of the shear wave and to measure its velocity, which is directly related to tissue stiffness and the severity of liver fibrosis.

The patients were evaluated at the enrollment and at the end of the study. Laboratory assessments were performed at least monthly and included complete blood counts with differential counts; Alanine Transaminase [ALT], Aspartate Transaminase [AST] Lactate Dehydrogenase [LDH] and ferritin. The concentrations of high sensitive C-reactive protein were also evaluated.

Urinary testing performed on random collections included determination of creatinine, total protein, and albumin. Physical examinations, electrocardiograms (ECGs), audiometry and ophthalmological tests were performed at baseline. The study duration was 52 weeks (12 months).

Patients were excluded if they had a serum creatinine above the upper limit of normal if they had significant proteinuria or if they had active or chronic hepatitis B or C. Other exclusion criteria were second and third atrioventricular block, QT interval prolongation, or therapy with digoxin or similar medications. Treatment with  $\beta$ -blockers or angiotensin-converting enzyme inhibitors was permitted. Patients with chelation therapy-associated ocular toxicity were excluded. No one patient had clinical or imaging findings suggesting the presence of liver cirrhosis at baseline or at the end of the study.

*Statistical analysis.* Data are reported as mean  $\pm$  SD. Comparisons among groups were made using one-way analysis of variation (ANOVA) analyses, where  $P < 0.05$  was considered statistically significant.

Post hoc tests were Student's t-test for paired variables and Wilcoxon nonparametric test. All P values are two-sided and considered significant with  $P \leq 0.05$ . The Pearson's correlation coefficient  $r$  with p-value is used to measure the strength of a linear association between Ferritin, LIC biochemistry and Fibroscan and hs-CRP variables. Statistical analyses were performed using MedCalc for Windows, version 15.0 (MedCalc Software, Ostend, Belgium).

**Results.** The study completed 15 patients. Summary of the parameters and evaluated values at baseline and at the end of the study are given in **table 1**.

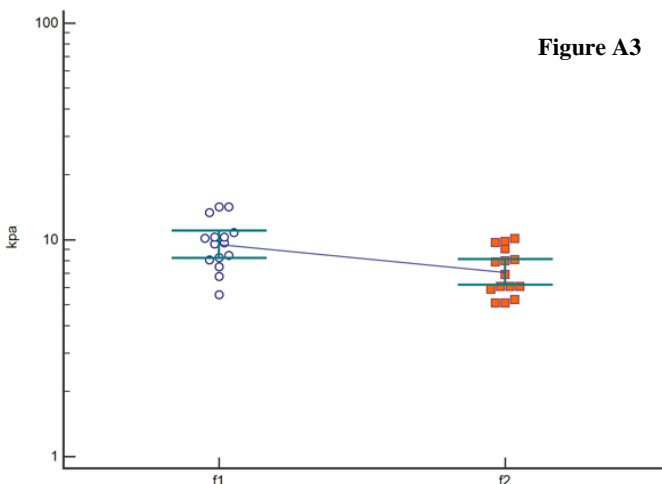
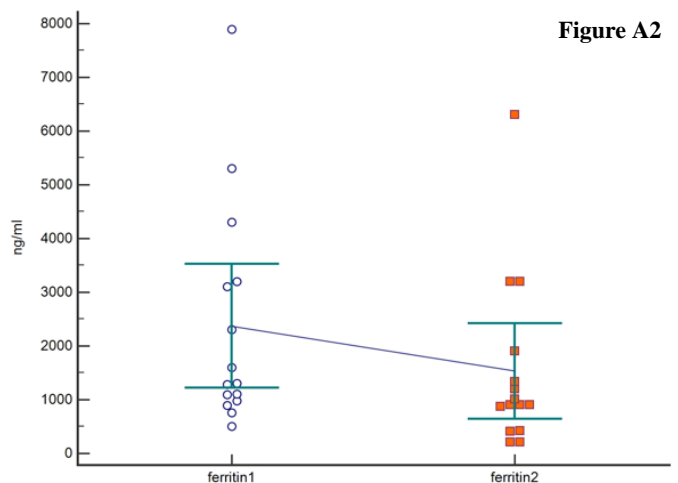
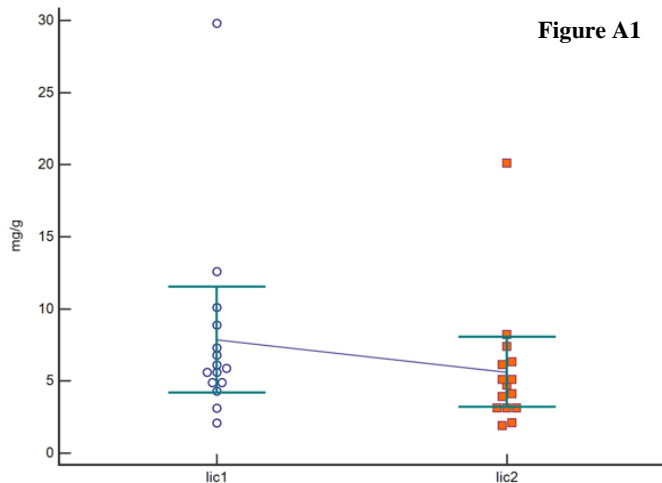
After 12 months (52 weeks) of deferasirox therapy, a significant improvement in LIC from 7.86 to 5.62 mg range:3.1-20.1 mg Fe/g dry weight  $p=0.043$  was found (**Figure A1**), followed by significant improvement of serum ferritin mean from 2373.33 to 1532 ng/ml range: 210-6300,  $p=0.002$  (**Figure A2**).

The above findings were followed by an improvement in liver stiffness from 9.7 kPa to 6.7 kPa range:5.1-10.1,  $p=0.001$  (**Figure A3**). A significant improvement in AST, ALT, and LDH at 52 weeks was also noted. There was no significant difference in hs-CRP and serum creatinine from baseline to end of the study.

A significant correlation ( $r_1$ : pre-treatment,  $r_2$ : after treatment) between ferritin levels and LIC ( $r_1=0.862$  and  $r_2=0.9298$ ) and between ferritin and LSM ( $r_1=0.6905$   $r_2=0.7936$ ) was found respectively. Furthermore, the correlation between LIC and LSM was statistically significant at baseline ( $r_1=0.6344$ ) and at the end of the study ( $r_2=0.6075$ ). No correlations were found between the other parameters (**Table 2**).

**Table 1.** Summary of the parameters and evaluated values at baseline and at the end of the study.

Parameter	Baseline n=15	Range	End of study n=15	Range	P $\leq 0.05$
Fibroscan (kPa)	9.7	5.6-14.2 ( $\pm 2.56$ )	6.9	5.1- 10.1 ( $\pm 1.78$ )	<b>0.001</b>
LIC mg Fe/g dw	7.86	4.1- 29.8( $\pm 1.7$ )	5.62	3.1-20.1 ( $\pm 1.13$ )	<b>0.043</b>
Ferritin ng/ml	2373.33	510-7890( $\pm 536.1$ )	1532	210-6300( $\pm 416.6$ )	<b>0.002</b>
CRP mg/lt	2.7	2.2- 3.2 ( $\pm 0.24$ )	2.5	2.0-3.03( $\pm 0.24$ )	0.25
AST IU/L	64.5	55.9-73.1 ( $\pm 4.0$ )	45	39-51.5 ( $\pm 2.9$ )	<b>0.002</b>
ALT IU/L	48	45-110 ( $\pm 5.8$ )	34.8	32.6-70 ( $\pm 2.6$ )	<b>0.010</b>
LDH IU/L	416	210-710 ( $\pm 43.9$ )	240	140-310( $\pm 54.3$ )	<b>0.0010</b>
Creatinine mg/dl	0.8	0.6-1,5 ( $\pm 0.02$ )	0.9	0.7-1.5 ( $\pm 0.2$ )	0.094



**Figure A1.** Comparison of LIC in patients with Sickle Cell Disease who had received chelation therapy for 12 months revealed significant improvement (lic1: pre-treatment, lic2: end of study).

**Figure A2.** Comparison of ferritin in patients with Sickle Cell Disease who had received chelation therapy for 12 months revealed significant improvement (ferritin1: pre-treatment, ferritin2: end of the study).

**Figure A3.** Comparison of LSM in patients with Sickle Cell Disease who had received chelation therapy for 12 months revealed significant improvement (f1: pre-treatment, f2: end of the study).

**Table 2.** Correlations between all parameters.

Parameters	Baseline	P<0.05	End of study	P<0.05
Ferritin/LIC	$R_1=0.862$	$< 0.00001$	$R_2=0.9298$	$< 0.00001$
Ferritin/LSM	$R_1=0.6905$	$0.0044$	$R_2=0.7936$	$0.0004$
LIC/LSM	$R_1=0.6344$	$0.0111$	$R_2=0.6075$	$0.0163$
AST/ferritin	$R_1=0.3642$	$0.1820$	$R_2=0.3995$	$0.1401$
ALT/ferritin	$R_1=0.5050$	$0.0549$	$R_2=0.4872$	$0.0655$
AST/LSM	$R_1=0.5393$	$0.080$	$R_2=0.4451$	$0.0964$
AST/LIC	$R_1=0.1089$	$0.6994$	$R_2=0.273$	$0.3246$
ALT/LSM	$R_1=0.4622$	$0.0828$	$R_2=0.4409$	$0.1000$
ALT/LIC	$R_1=0.3184$	$0.2475$	$R_2=0.3742$	$0.1694$
LDH/LSM	$R_1=0.2376$	$0.3938$	$R_2=0.2304$	$0.4087$
LDH/LIC	$R_1=-0.035$	$0.9009$	$R_2=-0.013$	$0.9607$
Ferritin/CRP	$R_1=-0.1223$	$0.6642$	$R_2=-0.01139$	$0.9679$

**Safety and tolerability.** During the study 39 Adverse Events were reported. The most common AEs reported were abdominal pain 41% (7/39), diarrhea 38,5% (15/39), nausea 10,3% (4/39), and nasopharyngitis 7,7% (3/39). Nausea and abdominal pain were reported on the same day in those patients. Sickle cell painful crisis 2,6%

(1/39) was managed at home. No serious AEs were experienced during the study.

Serum creatinine levels were mostly stable during the study. Calculated creatinine clearance with Cockcroft and Gault formula remained stable during deferasirox treatment. Eight patients who received concomitant hydroxycarbamide during

the study remained relatively stable in the liver and renal function.

**Discussion.** Transfusion therapy is a key intervention in decreasing morbidity and mortality in patients with sickle cell disease. Transfusions and/or exchange transfusions first demonstrated their effectiveness in reducing recurrent strokes in SCD. Transfusions have also proved to be effective prophylaxis in high risk patients for the first stroke and in other complications such as acute chest syndrome.<sup>12,13</sup>

The severity and mechanism of body iron overload in SCD is completely different compared to the iron overload that occurs in thalassemia major. Transfusion-acquired iron overload in the heart is rare in sickle cell disease, probably because iron released by transfusion and haemolysis is efficiently handled by the effective erythropoiesis of sickle cell disease, but not as well by the ineffective erythropoiesis in thalassaemia.<sup>2,14,15</sup>

Sickle cell disease is also associated with a chronic inflammatory state and increased haemolytic status related to vasocclusive crisis.

Consequently, guidelines such as those in the UK currently recommend initiating iron chelation therapy in patients with SCD once LIC increases to  $\geq 7$  mg Fe/g dry weight if serum ferritin steady-state levels are  $>1000$   $\mu\text{g/l}$ , or at least 20 top-up transfusions.<sup>16</sup>

The gold standard for assessing liver iron stores is the hepatic iron content determined by liver biopsy, but this technique is limited because it is invasive and carries a risk of complications. Noninvasive methods including blood tests and imaging techniques have been evaluated and considered in greater detail.<sup>17,18,19</sup>

Studies of liver biopsies in patients with SCD have linked transfusional iron load with LIC, fibrosis, and cirrhosis. If transfusion is given without chelation, portal fibrosis can develop as early as two years after transfusion. With sequential biopsies, increased fibrosis was found in 1/3 of patients with LIC values  $> 9$  mg/g dry weight and in direct proportion to the LIC.<sup>20,16</sup>

TE is an ultrasound-based tool for measuring liver stiffness as a surrogate of fibrosis that is widely used due to its high accuracy for the diagnosis of fibrosis stage.<sup>21,22</sup>

Liver stiffness also correlates with cirrhosis complications including variceal hemorrhage,

ascites, and hepatocellular carcinoma (HCC). The iron effect in the pathogenesis of fibrosis due to increased oxidative stress and other pathological modes of action of HCV, ethanol, and steatosis, lead to mitochondrial dysfunction and hepatocyte apoptosis.<sup>23</sup> Hepatocellular carcinoma following liver cirrhosis as a complication of chronic hepatitis C and iron overload has been reported in thalassemia patients.<sup>24,25</sup> Cirrhosis, is the strongest and the most common known risk factor for HCC, is frequently found in thalassaemia patients as it has been described from the Italian Registry.<sup>24,25,26,27</sup>

In Drasar's research paper (2016) have shown that transfusion and markers of iron overload were weakly but significantly correlated with T.E and enhanced liver fibrosis score (ELF) using standard markers of liver function.<sup>21</sup>

In our study LIC, LSM and serum ferritin level were significantly reduced after 12 months of deferasirox treatment indicating that over 12 months, deferasirox significantly reduced liver iron burden in these iron-overloaded patients with SCD.

Also, ALT, AST, and LDH levels significantly decreased after 12 months of therapy suggestive an improvement of liver inflammation. Furthermore, ferritin and LIC significantly correlate with hepatic stiffness before and after deferasirox administration suggesting that reduction of iron in the liver leads to stiffness improvement. Our results are in agreement with Deugnier (2011) and Adams (2011) that deferasirox can lead to regression of fibrosis, improving liver stiffness and correlating with iron removed.<sup>28,29</sup>

Adequate chelation therapy is mandatory to prevent liver disease progression in sickle cell disease patients.

Additionally both AST and ALT showed significant improvement over the course of the study but showed no correlation with liver stiffness. Although transaminases are markers of inflammatory liver reaction and is well established that high levels influence the elastographic findings, the absence of correlation in our study is due to mildly increased levels of transaminases at the onset of the study.

Hs-CRP remained stable from the beginning to the end of the study, and show no correlation with ferritin or other parameters.



In addition, studies of deferasirox in patients with thalassemia provided evidence of significant reduction in hepatic fibrosis irrespective of hepatic iron concentration or HCV prevalence. Our results clearly demonstrate that the observed improvement of hepatic stiffness is mainly associated with the reduction of hepatic iron and not by the improvement of inflammatory status.<sup>30,31</sup>

Patients with the sickle cell disease are at risk for significant hepatic complications, and better definitions and markers could be utilized to understand the pathophysiology of hepatic involvement. Taken together, these results suggest that TE is a useful and less expensive than the MRI tool to identify the stage of stiffness/fibrosis in patients with SCD at steady state and to monitor the efficacy of chelation therapy.

## References:

1. Chaturvedi Shruti, and Michael R. DeBaun. Evolution of sickle cell disease from a life - threatening disease of children to a chronic disease of adults: The last 40 years. *American Journal of Hematology* 91.1 (2016): 5-14. <https://doi.org/10.1002/ajh.24235> PMID:26547630
2. Porter John and Maciej Garbowski. Consequences and management of iron overload in sickle cell disease. *ASH Education Program Book* 2013.1 (2013): 447-456. <https://doi.org/10.1182/asheducation-2013.1.447>
3. Lucania Gaetano et al. "Chelation treatment in sickle - cell - anaemia: much ado about nothing?." *British Journal of Haematology* 154.5 (2011): 545-555. <https://doi.org/10.1111/j.1365-2141.2011.08769.x> PMID:21707578
4. Cappellini Maria Domenica et al. Tailoring iron chelation by iron intake and serum ferritin: the prospective EPIC study of deferasirox in 1744 patients with transfusion-dependent anemias. *Haematologica* 95.4 (2010): 557-566.
5. Vichinsky Elliott et al. Long - term safety and efficacy of deferasirox (Exjade®) for up to 5 years in transfusional iron - overloaded patients with sickle cell disease. *British Journal of Haematology* 154.3 (2011): 387-397. <https://doi.org/10.1111/j.1365-2141.2011.08720.x> PMID:21592110 PMCid:PMC3170481
6. Ebert Ellen C., Michael Nagar and Klaus D. Hagspiel. Gastrointestinal and hepatic complications of sickle cell disease. *Clinical Gastroenterology and Hepatology* 8.6 (2010): 483-489. <https://doi.org/10.1016/j.cgh.2010.02.016> PMID:20215064
7. Karam Lina B. et al. Liver biopsy results in patients with sickle cell disease on chronic transfusions: poor correlation with ferritin levels. *Pediatric Blood & Cancer* 50.1 (2008): 62-65. <https://doi.org/10.1002/pbc.21215> PMID:17457853
8. Brittenham Gary M. Iron-chelating therapy for transfusional iron overload. *New England Journal of Medicine* 364.2 (2011): 146-156. <https://doi.org/10.1056/NEJMc1004810> PMID:21226580 PMCid:PMC3078566
9. Stebbing Justin et al. A meta-analysis of transient elastography for the detection of hepatic fibrosis. *Journal of Clinical Gastroenterology* 44.3 (2010): 214-219. <https://doi.org/10.1097/MCG.0b013e3181b4af1f> PMID:19745758
10. Fraquelli Mirella et al. Transient elastography in the assessment of liver fibrosis in adult thalassemia patients. *American Journal of Hematology* 85.8 (2010): 564-568. <https://doi.org/10.1002/ajh.21752> PMID:20658587
11. Koh Christopher et al. Liver stiffness increases acutely during sickle cell vaso - occlusive crisis. *American Journal of Hematology* 88.11 (2013): E250-E254. <https://doi.org/10.1002/ajh.23552> PMID:23828202 PMCid:PMC3808506
12. Smith - Whitley Kim and Alexis A. Thompson. Indications and complications of transfusions in sickle cell disease. *Pediatric Blood & Cancer* 59.2 (2012): 358-364. <https://doi.org/10.1002/pbc.24179> PMID:22566388
13. Chou Stella T. Transfusion therapy for sickle cell disease: a balancing act. *ASH Education Program Book* 2013.1 (2013): 439-446. <https://doi.org/10.1182/asheducation-2013.1.439>
14. Walter Patrick B., Paul Hartz, and Elliott Vichinsky. Iron metabolism and iron chelation in sickle cell disease. *Acta Haematologica* 122.2-3 (2009): 174-183.
15. Marsella Maria and Caterina Borgna-Pignatti. Transfusional iron overload and iron chelation therapy in thalassemia major and sickle cell disease. *Hematology/Oncology Clinics* 28.4 (2014): 703-727.
16. Sickle Cell Society. Standards for the clinical care of adults with sickle cell disease in the UK. *Sickle Cell Society*, 2008.
17. Castera Laurent. Noninvasive assessment of liver fibrosis. *Digestive Diseases* 33.4 (2015): 498-503. <https://doi.org/10.1159/000374097> PMID:26159265
18. Patel Keyur, Pierre Bedossa and Laurent Castera. Diagnosis of liver fibrosis: present and future. *Seminars in Liver Disease*. Vol. 35. No. 02. Thieme Medical Publishers, 2015.
19. Ou George et al. Utility of Transient Elastography in Estimating Hepatic Iron Concentration in Comparison to Magnetic Resonance Imaging in Patients Who are Transfusion-Dependent: A Canadian Center Experience. *Hemoglobin* 41.1 (2017): 21-25. <https://doi.org/10.1080/03630269.2017.1307763> PMID:28532285
20. Hoffbrand, A. Victor, Ali Taher and Maria Domenica Cappellini. How I treat transfusional iron overload. *Blood* (2012): <https://doi.org/10.1182/blood-2012-05-370098> .
21. Drasar Emma et al. Interim assessment of liver damage in patients with sickle cell disease using new non - invasive techniques. *British Journal of Haematology* 176.4 (2017): 643-650. <https://doi.org/10.1111/bjh.14462> PMID:27984631 PMCid:PMC5303160
22. Voskaridou Ersi et al. Liver transient elastography (FibroScan) correlates with liver iron concentration and reflects liver fibrosis in patients with sickle cell disease. *Blood* 2010 116:1646.
23. Philippe Marie A., Richard G. Ruddell, and Grant A. Ramm. Role of iron in hepatic fibrosis: one piece in the puzzle. *World Journal of Gastroenterology*: WJG 13.35 (2007): 4746.
24. Kountouras Dimitrios et al. Liver disease in adult transfusion - dependent beta - thalassaemic patients: investigating the role of iron overload and chronic HCV infection. *Liver International* 33.3 (2013): 420-427. <https://doi.org/10.1111/liv.12095> PMID:23402611
25. Maakaron Joseph E. et al. Hepatocellular carcinoma in hepatitis-negative patients with thalassemia intermedia: a closer look at the role of siderosis. *Annals of Hepatology* 12.1 (2013): 142-146. PMID:23293206
26. Restivo Pantalone Gaetano et al. Hepatocellular carcinoma in patients

- with thalassaemia syndromes: clinical characteristics and outcome in a long term single centre experience. *British Journal of Haematology* 150.2 (2010): 245-247.
27. Borgna - Pignatti Caterina, et al. Hepatocellular carcinoma in thalassaemia: an update of the Italian Registry. *British Journal of Haematology* 167.1 (2014): 121-126. <https://doi.org/10.1111/bjh.13009> PMID:24992281
28. Deugnier Yves et al. Improvement in liver pathology of patients with  $\beta$ -thalassemia treated with deferasirox for at least 3 years. *Gastroenterology* 141.4 (2011): 1202-1211. <https://doi.org/10.1053/j.gastro.2011.06.065> PMID:21741344
29. Adams Paul C. Chelation therapy for secondary iron overload: is the primary effect less iron or less liver fibrosis?. *Gastroenterology* 141.4 (2011): 1142-1143. <https://doi.org/10.1053/j.gastro.2011.08.022> PMID:21871454
30. Angelucci E. et al. Iron Chelation Therapy with Deferasirox (Exjade®, ICL670) or Deferoxamine Is Effective in Reducing Iron Overload in Patients with Advanced Fibrosis and Cirrhosis. *Blood* 2005 106:2696.
31. Deugnier Y. et al. 189 Effect of Iron Chelation Therapy with Deferasirox (EXJADE®, ICL670) or Deferoxamine on Hepatocellular Inflammation and Liver Function in Patients with Transfusiondependent Anemia. *Journal of Hepatology* 48 (2008): S79-S80. [https://doi.org/10.1016/S0168-8278\(08\)60191-9](https://doi.org/10.1016/S0168-8278(08)60191-9)