

OPEN ACCESS

Full open access to this and thousands of other papers at <http://www.la-press.com>.

Acute Aortic Valve Rupture From Infective Endocarditis After Transrectal Prostate Biopsy: A Call to Revise the AHA Guidelines for Prevention of Infective Endocarditis

Julia Ansari^{1,2}, Gurkaran Singh Garcha^{1,2}, Henry Huang^{1,2}, Faisal G. Bakaeen¹⁻³, Salim S. Virani¹⁻³ and Hani Jneid^{1,2}

¹Division of Cardiothoracic Surgery, Michael E. DeBakey Department of Surgery, Baylor College of Medicine, Houston, Texas. ²Division of Cardiothoracic Surgery, Michael E. DeBakey Veterans Affairs Medical Center, Houston, Texas.

³Department of Cardiovascular Surgery, Texas Heart Institute at St. Luke's Episcopal Hospital, Houston, Texas. Corresponding author email: jneid@bcm.edu

Abstract: We describe the case of a 63-year-old man with a known murmur who presented with a 4-month history of intermittent fever and a progressive reduction in energy level after a transrectal prostate biopsy (TRPB). He subsequently presented with acute heart failure secondary to aortic valve cusp rupture caused by endocarditis and underwent urgent aortic valve surgery. The 2008 American College of Cardiology/American Heart Association Guideline update on infective endocarditis has narrowed the use of antibiotic prophylaxis before most accepted dental procedures and continues to recommend against prophylaxis before genitourinary or gastrointestinal procedures. In contrast, the American Urological Association recommends the use of fluoroquinolones for the prevention of transrectal ultrasound-derived infectious complications. Notably, TRPB is associated with a high frequency of bacteremia and bacteriuria. In our case, an antibiotic course before the procedure and a more meticulous medical work-up after febrile illness might have mitigated the patient's catastrophic medical presentation.

Keywords: endocarditis, bacteremia, vegetation, aortic regurgitation, murmur

Clinical Medicine Insights: Case Reports 2013;6 29–33

doi: [10.4137/CCRep.S10503](https://doi.org/10.4137/CCRep.S10503)

This article is available from <http://www.la-press.com>.

© the author(s), publisher and licensee Libertas Academica Ltd.

This is an open access article. Unrestricted non-commercial use is permitted provided the original work is properly cited.



Introduction

Infective endocarditis is an infection caused by any microbe that enters the bloodstream and forms a nidus at one or more locations in the endocardium (within the heart chamber walls, vessels, congenital defects, and valves). Previously, patients with any congenital heart defect were advised to take antibiotics an hour before dental procedures or procedures involving the mouth or throat, or gastrointestinal (GI), genital, or urinary tracts.¹ However, in 2007, the American Heart Association modified these recommendations to limit prophylaxis with antibiotics to a very high-risk patient population. In 2008, the committee revised the guidelines with recommendations for prophylactic antibiotics for prevention of endocarditis. The current recommendations are as follows:

1. Infective endocarditis prophylaxis for dental procedures is reasonable only for patients with underlying cardiac conditions associated with the highest risk of adverse outcome from infective endocarditis.
2. For patients with these underlying cardiac conditions, prophylaxis is reasonable for all dental procedures that involve the manipulation of gingival tissue or the periapical region of the teeth, or the perforation of oral mucosa.
3. Prophylaxis is not recommended solely on the basis of an increased lifetime risk of infective endocarditis.
4. Administration of antibiotics solely to prevent endocarditis is not recommended for patients who undergo a genitourinary (GU) or GI tract procedure.²

The rationale for these recommendations was that most bacteremia episodes are caused by bacteria associated with daily activity rather than a procedure. Therefore, prophylaxis was thought to be preventive only in a small number of cases. It was also thought that the side effects of antibiotics outweighed their benefits.² This report describes a patient for whom antibiotics were not required by the current guidelines, and whose post-procedural infection led to significant morbidity.

Case Presentation

A 63-year-old man presented to our tertiary care center with a 2-day history of acute-onset shortness

of breath. The patient was originally treated for community-acquired pneumonia and non-ST-elevation myocardial infarction (NSTEMI) at another facility and was transferred to our institution for cardiac catheterization. The patient's significant medical history included a murmur since childhood, hypertension, hyperlipidemia, and adenocarcinoma of the prostate that was diagnosed after a transrectal prostate biopsy (TRPB) for an asymptomatic, elevated prostate-specific antigen (PSA) level (5.2 $\mu\text{g/L}$) 23 months before presentation. The patient did not have any risk factors for endocarditis, such as indwelling catheters or prostheses, a history of intravenous drug use, or a pacemaker or defibrillator. Following his urologist's instructions, he took ciprofloxacin the evening before and on the day of his first biopsy for the prevention of bacterial complications. In addition, he was instructed to go to the emergency department (ED) if he developed a fever higher than 101 °F.

After his cancer was diagnosed, the patient underwent bone scan imaging, which showed no evidence of distant metastasis. He thereafter decided to undergo active surveillance as his mode of treatment and had his second biopsy 4 months before his acute illness. He did not take ciprofloxacin the day before or the day of the procedure. He reported that his repeat biopsy was a painful, bloody procedure, unlike the first one.

On the eighth day after the procedure, the patient developed a fever of 101 °F. He contacted his primary care physician, who advised him to go to the ED; however, he was reluctant to do so and instead received an outpatient, 10-day course of ciprofloxacin. He continued to work as a tennis player but had intermittent fever and fatigue and felt a progressive and significant decrease in his energy level. Two days before his presentation, he developed acute-onset shortness of breath and a fever of 103 °F. He was taken by his family to another institution, where community-acquired pneumonia was diagnosed and an antibiotic course was started. He had elevated cardiac biomarkers and received an initial diagnosis of NSTEMI, for which he was transferred to our facility for coronary angiography. His physical examination at our hospital was notable for acute respiratory distress and an inability to lay supine because of marked orthopnea. He was also diaphoretic, tachypneic, and tachycardic.

Upon the patient's arrival at the ED, his temperature was 97 °F, blood pressure was 95/50 mmHg,



pulse was 110 bpm, and respiration rate was 40. However, before the patient received antibiotics and fluid at the other hospital, his temperature and blood pressure had been 102 °F and 105/36 mmHg, and outpatient notes listed his blood pressure as 120–130/80–90 mmHg. The apical impulse was displaced down and to the left. The first heart sound was barely audible. The second heart sound was pronounced, along with an S3 gallop. An early, soft mid-diastolic rumble was heard at the apex. Jugular venous distension could not be assessed because the patient could not lie supine.

His lung auscultation revealed bilateral crackles and diminished air entry in the lower lung fields. His white cell count was normal, with no evidence of a left-side shift. The only notable results of his blood tests were elevated levels of troponin (3.5 ng/mL; normal: 0–0.1 ng/mL) and brain natriuretic peptide (744 pg/mL; normal: <100 pg/mL). He had no evidence of bacteriuria on urine analysis. His chest radiograph showed prominent interstitial markings consistent with interstitial edema and mild cardiomegaly. An urgent 2-dimensional transthoracic echocardiogram was obtained in the ED and showed a ruptured left coronary cusp that was freely mobile and that prolapsed into the left ventricular cavity in diastole, resulting in severe aortic regurgitation.

The measurements showed a normal left ventricle size of 4.6 cm. The jet width in the left ventricle outflow tract (LVOT) color flow covered 100% of the outflow (mild: <25%, moderate: 25%–65%, severe: >65%). The aortic insufficiency jet density was dense, with a pressure half-time of 195 ms (mild: >500 ms, moderate: 200–500 ms, severe: <200 ms). There was holodiastolic aortic flow reversal in the descending aorta. The regurgitant volume was 75 mL/beat (mild: <30 mL/beat, moderate: 33–59 mL/beat, severe: >60 mL/beat), the regurgitant fraction was 66% (mild: <30%, moderate: 30%–49%, severe: ≥50%), and the effective regurgitant orifice area was 1.07 cm² (mild: <0.10 cm², moderate: 0.10–0.29 cm², severe: ≥0.30 cm²). The LVOT was 2.3 cm, the LVOT time velocity index (TVI) was 27.6 cm, the mitral valve diameter was 3.5 cm, the mitral valve inflow TVI was 19.7 cm, and the aortic insufficiency TVI was 70 cm. Because of the patient's unstable condition and need for urgent surgery, more quantitative images specific to the

proximal isovelocity surface area and vena contracta jet were not obtained.³

The patient was immediately given intravenous furosemide and urgently taken to the cardiac catheterization laboratory, where a diagnostic angiogram showed normal coronary arteries. An aortogram revealed mild dilatation of the aortic root and significant aortic regurgitation.

The diagnosis of infective endocarditis and acute valvular rupture prompted urgent cardiac surgical consultation and transfer to the operating room. An intraoperative transesophageal echocardiogram confirmed the presence of a ruptured left coronary leaflet (Figs. 1 and 2).

The main intraoperative finding was a bicuspid aortic valve with a pocket of purulence on the right side of the fused noncoronary leaflet. The left leaflet was perforated and completely disrupted. There was a paravalvular abscess extending toward the interventricular septum. Intraoperative gram stain showed gram-positive cocci in pairs, later identified as *Enterococcus faecalis*, which was consistent with the patient's 4/4 positive blood cultures. He underwent an aortic valve replacement with a 25-mm Perimount bioprosthetic valve (Edwards Lifesciences, Irvine, California).

The patient's postoperative recovery was complicated by transient complete heart block that necessitated transapical pacing and that resolved after 3 days of antibiotic therapy. The pathology report regarding the aortic valve showed neutrophilic infiltration of the tissue with fibrotic segments.

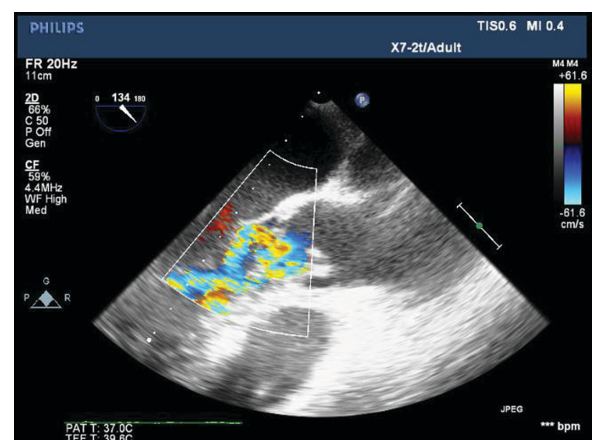


Figure 1. Intraoperative echocardiogram at 134 degrees showing the ruptured non-coronary cusp with color flow showing a significant aortic regurgitant jet.

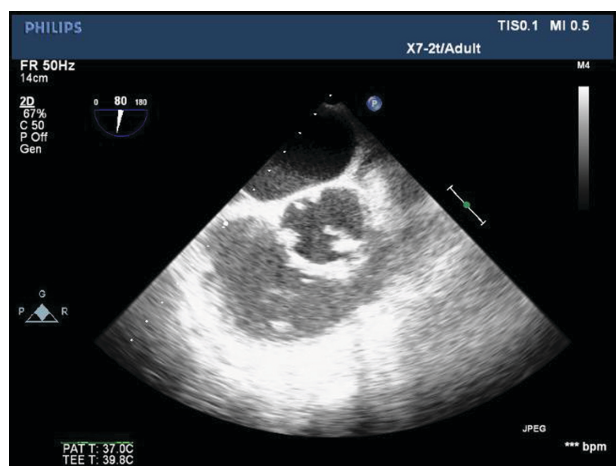


Figure 2. Intraoperative echocardiogram in the parasternal short axis view at 80 degrees, showing the ruptured non-coronary cusp.

Discussion

Infective endocarditis is a life-threatening infection with an incidence of 10,000 to 20,000 new cases per year worldwide. Mortality rates of 20% to 30% have been reported for native valve and prosthetic valve endocarditis.^{4,5} Before the American Heart Association (AHA) guideline revision was published in 2007 and updated in 2008, antibiotic prophylaxis was recommended for various dental and some non-dental procedures with the aim of decreasing the incidence of this deadly disease. However, the current revision recommends antibiotic prophylaxis only for dental procedures that involve manipulation of the gingival tissues or periapical tissue of the teeth or perforation of the mucosa in patients with high-risk cardiac conditions. These conditions include prosthetic heart valves, a history of endocarditis, congenital heart disease (ie, unrepaired cyanotic congenital heart disease, including palliative shunts and conduits; closure of a congenital heart defect with prosthetic material or device within the previous 6 months; and residual defect adjacent to repaired congenital heart defects), and valvulopathy after heart transplantation. Having a heart murmur alone is not considered to warrant antibiotic prophylaxis. In addition, antibiotic prophylaxis has no role in preventing endocarditis during GI or GU tract procedures according to the current guidelines.¹

The rationale for these guidelines is partly based on the observation that transient bacteremia that results from normal activities, such as daily trauma to the mucosa from brushing teeth and chewing food, may

play a more significant role in the development of infectious endocarditis than a single episode of bacteremia from a dental procedure.¹ The reported incidence of bacteremia during dental interventions ranges from 10% to 100%, and with daily brushing and flossing, from 20% to 68%.⁶ Most cases of endocarditis are not caused by dental procedures, and rates of 4% to 7.5% have been reported after dental procedures.⁷ Hence, the 2007 guidelines questioned the benefits of antibiotic prophylaxis, considering the risk of adverse drug effects and resistance and given the uncertainty of its usefulness for preventing endocarditis.

Transrectal prostate biopsy is considered a safe procedure for diagnosing prostate cancer. Rates of bacteremia as high as 16% have been reported in patients who undergo this procedure.^{5,6} To the best of our knowledge, there is only 1 other reported case of endocarditis after transrectal prostate biopsy.⁷ The 2011 American Urological Association's best practice policy statement recommends the use of prophylactic antibiotics in all patients (declaring fluoroquinolones the most suitable antibiotic for prophylaxis) before TRPB for the prevention of all infectious complications (class Ib recommendation).⁸ However, many groups, including the AHA, do not recommend prophylactic antibiotic use solely for the prevention of endocarditis related to GU or GI procedures.² This may be because of the lack of reports linking endocarditis to these procedures.

There is, however, evidence that antibiotic prophylaxis reduces the rates of bacteriuria, febrile genitourinary infection, and sepsis after transrectal ultrasound-guided biopsy to less than 5%.⁹ Currently, most urologists prescribe a single dose of fluoroquinolones before the procedure and 24 hours after the procedure. However, longer regimens (>4 days) should be individualized in high-risk patients (ie, patients with diabetes, concomitant steroid consumption, immunodeficiency, pre-existing bacteriuria, a history of prostatitis, or an enlarged prostate > 75 cc).⁴ Our patient had a known history of heart murmur and was found to have a bicuspid aortic valve. Even though this congenital defect could have affected his valve anatomy, creating a high-velocity jet that would promote the adhesion of blood-borne pathogens to the damaged site, the current guidelines still do not consider bicuspid aortic valve a high-risk congenital defect that warrants preoperative antibiotic prophylaxis, even before dental procedures.



Unfortunately, a prospective randomized clinical trial large enough to prove that antibiotic prophylaxis for dental, GU, and GI procedures benefits patients is unlikely to be feasible. Therefore, we recommend establishing a registry site where similar cases can be reported in an effort to better define the role of antibiotics in future guidelines. The new US Preventive Services Task Force 2012 recommendation against PSA-based screening for prostate cancer (grade D) may make TRBP-related infection less of an issue.¹⁰ New evidence from a randomized trial of PSA-based cancer screening showed that a third of the men who had prostate biopsy experienced pain, fever, bleeding, infection, or transient urinary tract difficulties that they considered a moderate or major problem.¹¹ The vast majority of randomized trials suggest an increased risk with the use of the PSA test to screen for prostate cancer, at least in part because of biopsy-related complications and the risk of overdiagnosis and unnecessary treatment.¹⁰

In conclusion, after undergoing a TRPB procedure, our patient contracted infective endocarditis that led to a catastrophic medical presentation. We believe that an antibiotic course before the TRPB procedure and a more meticulous medical work-up after the onset of febrile illness might have mitigated the patient's condition.

Acknowledgments

We would like to thank the Veterans Affairs Echocardiography Laboratory for providing vital images. Stephen N. Palmer, PhD, ELS, and Diana Kirkland, BA, contributed to the editing of the manuscript.

Funding

Author(s) disclose no funding sources.

Author Contributions

JA and HJ treated the patient and suggested writing this case report. JA and GG collected data and images and wrote the first draft of the report. JA made critical revisions, and all authors (JA, GG, HH, FB, SV, and HJ) reviewed and approved the final manuscript.

Competing Interests

Author(s) disclose no potential conflicts of interest.

Disclosures and Ethics

The authors report no conflicts of interest. As a requirement of publication author(s) have provided

to the publisher signed confirmation of compliance with legal and ethical obligations including but not limited to the following: authorship and contributorship, conflicts of interest, privacy and confidentiality and (where applicable) protection of human and animal research subjects. The authors have read and confirmed their agreement with the ICMJE authorship and conflict of interest criteria. The authors have also confirmed that this article is unique and not under consideration or published in any other publication, and that they have permission from rights holders to reproduce any copyrighted material. The external blind peer reviewers report no conflicts of interest.

References

1. Bonow RO, Carabello BA, Chatterjee K, et al. ACC/AHA 2006 guidelines for the management of patients with valvular heart disease: a report of the American College of Cardiology/American Heart Association Task Force on Practice Guidelines (Writing Committee to Revise the 1998 Guidelines for the Management of Patients With Valvular Heart Disease) developed in collaboration with the Society of Cardiovascular Anesthesiologists endorsed by the Society for Cardiovascular Angiography and Interventions and the Society of Thoracic Surgeons. *J Am Coll Cardiol*. 2006;48:e1-148.
2. Nishimura RA, Carabello BA, Faxon DP, et al. ACC/AHA 2008 Guideline update on valvular heart disease: focused update on infective endocarditis: a report of the American College of Cardiology/American Heart Association Task Force on Practice Guidelines endorsed by the Society of Cardiovascular Anesthesiologists, Society for Cardiovascular Angiography and Interventions, and Society of Thoracic Surgeons. *J Am Coll Cardiol*. 2008;52:676-85.
3. Zoghbi WA, Enriquez-Sarano M, Foster E, et al. Recommendations for evaluation of the severity of native valvular regurgitation with two-dimensional and Doppler echocardiography. *J Am Soc Echocardiogr*. 2003;16:777-802.
4. Hill EE, Herjigs P, Claus P, Vanderschueren S, Herregods MC, Peetermans WE. Infective endocarditis: changing epidemiology and predictors of 6-month mortality: a prospective cohort study. *Eur Heart J*. 2007;28:196-203.
5. Wang A, Athan E, Pappas PA, Fowler VG Jr, et al. Contemporary clinical profile and outcome of prosthetic valve endocarditis. *JAMA*. 2007;297:1354-61.
6. Wilson W, Taubert KA, Gewitz M, et al. Prevention of infective endocarditis: guidelines from the American Heart Association: a guideline from the American Heart Association Rheumatic Fever, Endocarditis, and Kawasaki Disease Committee, Council on Cardiovascular Disease in the Young, and the Council on Clinical Cardiology, Council on Cardiovascular Surgery and Anesthesia, and the Quality of Care and Outcomes Research Interdisciplinary Working Group. *Circulation*. 2007;116:1736-54.
7. Gendron R, Grenier D, Maheu-Robert L. The oral cavity as a reservoir of bacterial pathogens for focal infections. *Microbes Infect*. 2000;2:897-906.
8. Pierce D, Calkins BC, Thornton K. Infectious endocarditis: diagnosis and treatment. *Am Fam Physician*. 2012;85:981-6.
9. Lindert KA, Kabalin JN, Terris MK. Bacteremia and bacteriuria after transrectal ultrasound guided prostate biopsy. *J Urol*. 2000;164:76-80.
10. Roblot F, Le MG, Irani J, et al. Infective endocarditis after transrectal prostatic biopsy. *Scand J Infect Dis*. 2002;34:131.
11. Wolf JS Jr, Bennett CJ, Dmochowski RR, et al. Best practice policy statement on urologic surgery antimicrobial prophylaxis. *J Urol*. 2008;179(4):1379-90.