




Genitourinary/Gynecologic Cancer

End-of-Treatment FDG PET-CT (EOT-PET) in Patients with Post-Chemotherapy Masses for Seminoma: Can We Avoid Further Intervention?

Anjana Joel¹  Ashish Singh¹ Julie Hepzibah² Antony Devasia³ Santosh Kumar³
 Birla Roy Gnanamuthu⁴ Anuradha Chandramohan⁵ Arun Jacob Philip George³ Nirmal Thampi John³
 Bijesh Yadav⁶ Ajoy Oommen John¹ Josh Thomas Georgy¹ Subhashini John⁷ Raju Titus Chacko¹

¹ Department of Medical Oncology, Christian Medical College (CMC), Vellore, Tamil Nadu, India; ² Department of Nuclear Medicine, Christian Medical College (CMC), Vellore, Tamil Nadu, India;

³ Department of Urology, Christian Medical College (CMC), Vellore, Tamil Nadu, India; ⁴ Department of Thoracic Surgery, Christian Medical College (CMC), Vellore, Tamil Nadu, India; ⁵ Department of Radiology, Christian Medical College (CMC), Vellore, Tamil Nadu, India; ⁶ Department of Biostatistics, Christian Medical College (CMC), Vellore, Tamil Nadu, India; ⁷ Department of Radiotherapy, Christian Medical College (CMC), Vellore, Tamil Nadu, India

Address for correspondence Anjana Joel, MD, DM, Department of Medical Oncology Christian Medical College and Hospital, Vellore, Tamil Nadu, India (e-mail: anjanajoel@gmail.com).

South Asian J Cancer 2022;11(4):315–321.

Abstract



Anjana Joel

Keywords

- ▶ seminoma
- ▶ PET-CT
- ▶ germ cell tumor
- ▶ post-chemotherapy residual masses

Context Patients with seminoma present with advanced disease. End-of-treatment (EOT) positron emission tomography-computed tomography (PET-CT) is done to assess response and direct management of post-chemotherapy residual masses.

Purpose This article assesses the utility of EOT PET-CT in the management of post-chemotherapy residual lymph nodal masses seminoma.

Materials and Methods We analyzed all patients with seminoma who underwent an EOT PET-CT from January 2015 to January 2020 at our center and calculated the positive predictive value (PPV) and negative predictive value (NPV) of EOT PET-CT in the entire cohort of patients and among subgroups.

Results A total of 34 male patients underwent EOT PET-CT. Fourteen (41.2%) were stratified as good risk and 20 (58.8%) as intermediate risk. The median follow-up was 23 months (interquartile range: 9.75–53 months). In 23 patients there were residual masses of size more than 3 cm at the EOT PET scan. EOT PET was positive as per the SEMPET criteria in 18 (78%) out of 23 patients. None underwent retroperitoneal lymph node dissection. All four who underwent image-guided biopsy, showed only necrosis on pathology. One patient with positive mediastinal node (standardized uptake value 13.6) had granulomatous inflammation. There was no relapse or progression during this period of follow-up. The NPV for EOT PET-CT for the entire cohort, > 3 cm, and > 6 weeks cutoff were 100%, respectively. The PPV for EOT PET-CT for the entire cohort, > 3 cm residual mass, and > 6 weeks cutoff were 8.7, 11.11, and 6.67%, respectively.

DOI <https://doi.org/10.1055/s-0041-1735480> ISSN 2278-330X

How to cite this article: Joel A, Singh A, Hepzibah J, et al. End-of-Treatment FDG PET-CT (EOT-PET) in Patients with Post-Chemotherapy Masses for Seminoma: Can We Avoid Further Intervention?. South Asian J Cancer 2022;11(4):315–321.

© 2022. MedIntel Services Pvt Ltd. All rights reserved.

This is an open access article published by Thieme under the terms of the Creative Commons Attribution-NonDerivative-NonCommercial-License, permitting copying and reproduction so long as the original work is given appropriate credit. Contents may not be used for commercial purposes, or adapted, remixed, transformed or built upon. (<https://creativecommons.org/licenses/by-nc-nd/4.0/>)

Thieme Medical and Scientific Publishers Pvt. Ltd., A-12, 2nd Floor, Sector 2, Noida-201301 UP, India

Conclusion EOT PET-CT has a low PPV and high NPV in predicting viable tumor in post-chemotherapy residual masses among patients with seminomatous germ cell tumors. If required, EOT PET positivity can be confirmed by a biopsy or reassessed with a repeat PET-CT imaging to document persistent disease prior to further intervention.

Introduction

Seminoma accounts for 50% of all testicular and 30% of mediastinal germ cell tumors (GCTs). Most seminomatous testicular GCTs present early and only 20 to 30% develop metastatic disease involving the lymph nodes; with chemotherapy alone resulting in excellent cure rates.^{1,2} Residual nodal masses are seen in 60 to 80% of patients following the standard three to four cycles of cisplatin-based chemotherapy.^{3,4} The therapeutic approaches adopted currently for managing post-chemotherapy residual masses include surveillance,^{5,6} radiotherapy (RT), or retroperitoneal lymph node dissection (RPLND).⁷

Among patients with residual masses > 3 cm, there is controversy on the optimal treatment approach. While some centers recommended surveillance for all post-chemotherapy nodal masses irrespective of size, others recommended RPLND for all masses > 3 cm in size. This is based on the rationale that 20 to 30% of these masses contain viable residual tumor and 10% of all patients with advanced seminoma experience relapse.⁷⁻⁹ Excision of these masses during RPLND is a technical surgical challenge due to desmoplastic reaction and fibrosis, which is often associated with incomplete resections in addition to morbidity and worsening quality of life.^{7,8} Also, complete surgical resection is feasible in only 60 to 74% of patients after chemotherapy.^{3,8} Postoperative complications are also higher among patients undergoing post-chemotherapy RPLND.¹⁰ The SEMPET trial which was based on the hypothesis that fluorodeoxyglucose (FDG) positron emission tomography (PET) avidity may help differentiate viable tumor from necrosis, demonstrated that among patients with post-chemo masses > 3 cm, end-of-treatment (EOT) PET-computed tomography (CT) showed a negative predictive value (NPV) of 96% and a positive predictive value (PPV) of 100%.¹¹ Following this, PET-CT-guided decision making became standard for patients with residual masses > 3 cm in size; and non-FDG avid residual masses > 3 cm in size were kept on follow-up.

In comparison to Western data, higher proportion of Indian patients present with bulky retroperitoneal nodal masses (65%) and “intermediate risk” disease of 35 to 66% (with nonregional nodal or visceral metastases).^{12,13} A PPV of 72% and NPV of 90% for EOT PET-CT among 47 patients with seminomatous GCTs has been shown in Indian patients.¹⁴

We studied the role of EOT FDG PET-CT among our patients with seminomatous GCTs of the testis and mediastinum.

Materials and Methods

Patient Selection

This analysis was conducted at a tertiary level teaching hospital in South India. We studied consecutive adult

patients (age > 16 years) with seminomatous GCTs diagnosed and treated in our center from January 2015 to January 2020 who underwent an EOT PET-CT following first-line chemotherapy. We excluded patients with primary tumors containing nonseminomatous elements on histopathology, those with elevated serum alpha-fetoprotein (AFP) at any time point, no residual disease on PET-CT, and patients partially treated elsewhere.

Baseline Characteristics

The following information at diagnosis was collected: demographics, tumor markers, that is, serum AFP, β -human chorionic gonadotropin, and lactate dehydrogenase, and radiological information. EOT PET-CT was done after completion of chemotherapy. The time duration from the date of the last chemotherapy to the date of EOT PET-CT was noted. Similar to prior published data, we used a cutoff of 6 weeks from the last chemotherapy cycle to study the effect of chemotherapy on the PET-CT imaging findings before and after chemotherapy.¹⁵

Follow-Up

Patient follow-up was collected from the medical records and updated by telephonic interview. The last date of outpatient visit was taken as date of last follow-up among patients who were not contactable by telephone.

Treatment Details

The details of initial chemotherapy regimens and radiological response (pre- and post-chemotherapy tumor markers and imaging) were collected. Patients were grouped into two based on the size of the residual mass (< 3 cm and \geq 3 cm) and the time interval between the last cycle of chemotherapy and date of PET-CT (< 6 weeks and \geq 6 weeks).

EOT FDG PET-CT: Protocol and Interpretation

PET-CT imaging was performed as per our standard clinical PET-CT protocol; the patients were injected intravenously with 18-F FDG; 3.7 MBq/kg body weight to a maximum dose of 370 MBq after a 4- to 6-hour fasting period while ensuring a blood glucose level less than 150 mg/dL. Imaging was performed with an integrated PET-CT system (Siemens Biograph True Point 6). After 45 to 60 minutes of uptake period at rest, images were acquired at 2 minutes per bed position. The PET scan was acquired together with the CT scan. CT scan was used for attenuation correction and anatomical localization.

Transaxial, coronal, and sagittal PET images were reviewed concurrently with fused PET-contrast CT images and standardized uptake values (SUVs) were calculated wherever applicable. SUV reported were maximum values

within each region of interest, expressed in g/mL. A cutoff of above 2.5 was considered as significant. The visual evaluation was performed in direct comparison to automatically coregistered slices of PET-CT images. All initially involved sites were checked for tumor residuals with increased FDG-uptake and the region with the highest residual FDG-uptake was identified. The interpretation of the EOT PET-CT was done as per the SEMPET trial protocol with visual interpretation as positive or negative.^{11,16} SUV-based interpretation was not performed due to lack of supporting data.

The post-chemotherapy treatment course was noted: surveillance, RPLND, image-guided biopsy, RT, or salvage chemotherapy. Positive PET scans were rated true positive (TP) if they fulfilled either of the following criteria: (1) offered RT based on PET positivity, (2) viable tumor found histologically on image-guided biopsy or RPLND, and (3) if there was clinical or radiological progression on CT during follow-up. All other positive PET scans were rated false positive (FP). Similarly, negative PET scans were rated as true negative if there was necrosis or fibrosis in the RPLND specimen and/or no clinical or radiological signs of disease progression during the follow-up

period. Negative PET scans with viable tumor in the resected residual lesion and/or clinical or radiological progression were rated false negative.^{15,16}

Survival Outcomes

Relapse-free survival was calculated from the day of the PET-CT study to either the date of the last follow-up visit or to the date of relapse. Overall survival was calculated as the time from the date of diagnosis till the date of late follow-up or death.

Statistical Analysis

Data analysis was performed using SPSS Version 23.

Results

→ Fig. 1 summarizes the patients included in the study. From January 2015 to 2020, 43 patients with GCTs underwent EOT PET-CT. Nine patients were excluded from the analysis; those who underwent PET-CT more than 3 months following the last chemotherapy ($n=3$) and those with no residual lesion on the PET-CT ($n=6$). Thus, 34 patients with

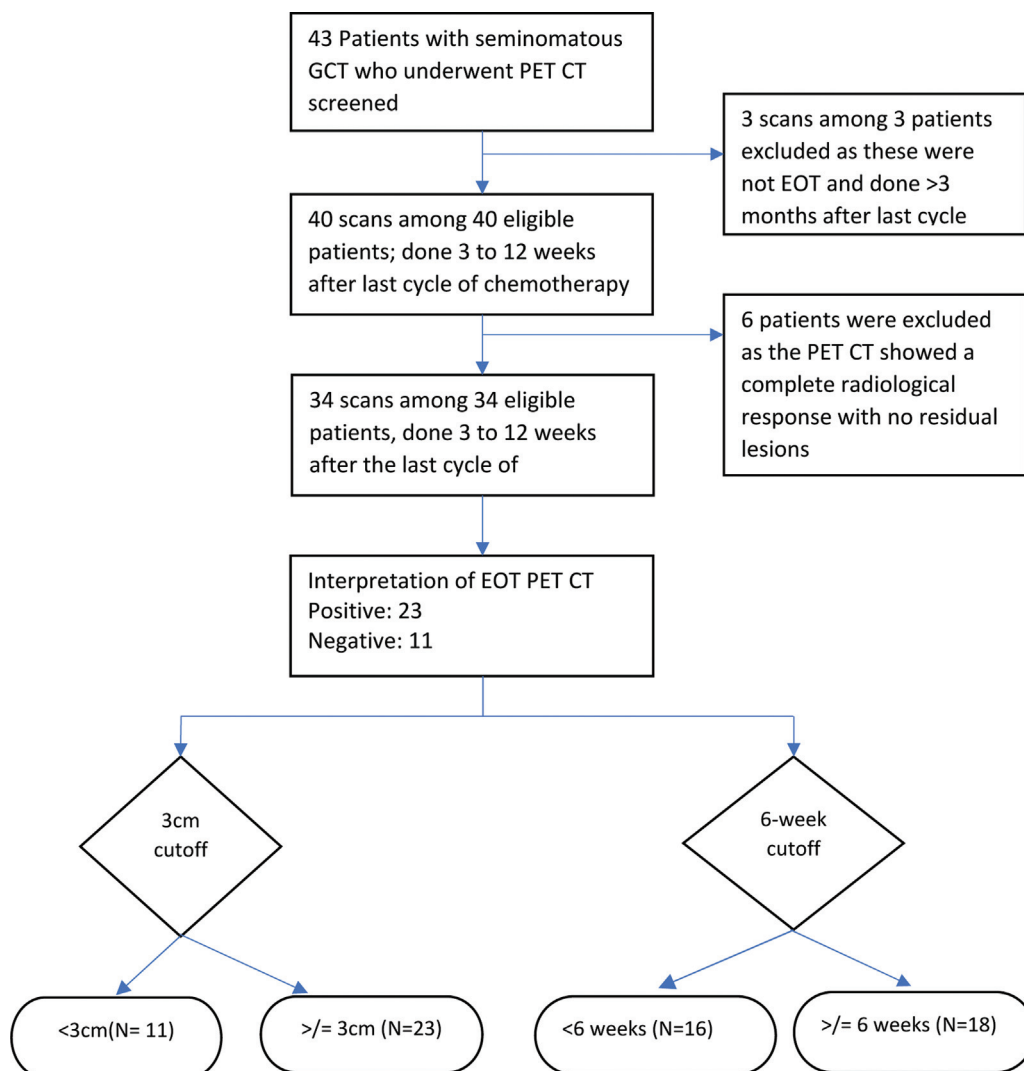


Fig. 1 STROBE diagram for study population (STROBE, Strengthening the Reporting of Observational Studies in Epidemiology).

seminomatous GCTs were evaluated with median follow-up duration of 23 months (interquartile range: 9.75–53 months)

Patient Characteristics

The baseline characteristics of the patients are summarized in **Table 1**. All patients were male; with majority (73.5%) having testicular primaries. The overall median size of the retroperitoneal nodal mass for gonadal primary/mediastinal mass for primary mediastinal GCT (at diagnosis) was 11.4 cm (range, 1.6–25 cm). Among the 25 patients with testicular GCT, 17 (68%) had stage III disease and 8 (32%) had stage II disease. Twenty (58.8%) belonged to the International Germ Cell Cancer Collaborative Group “intermediate risk” group and rest (41.2%, $n = 14$) to “good risk.”

The median time interval from the last chemotherapy to EOT PET-CT was 6 weeks (3–12 weeks). Sixteen (47.1%) patients underwent an EOT PET-CT < 6 weeks from the last chemotherapy (range: 3–5 weeks) and the rest underwent EOT PET-CT \geq 6 weeks from the last chemotherapy (range: 6–12 weeks). The median size of the residual mass (retroperitoneal nodal/mediastinal mass) post-chemotherapy was 3.9 cm (range: 1.1–11.6 cm).

Chemotherapy Details

Twenty-nine patients (85.3%) received three cycles of bleomycin, etoposide, and cisplatin, four (11.8%) received four cycles etoposide and cisplatin, and one (2.9%) received carboplatin-based chemotherapy for four cycles.

Patient Course after PET-CT

Twenty-three patients (67.6%) had a positive EOT PET-CT based on the SEMPET visual criteria. Among these, two received consolidation RT and hence were termed as TP. Both had prior scrotal violation with residual RPLN 3.6 cm (SUV 3.6) and 5.3 cm (SUV 3.6), respectively. Twenty-one patients were followed up (clinical and radiological), with no evidence of relapse and were termed as FP. None received salvage chemotherapy or underwent RPLND.

Among the four who underwent image-guided biopsy, no viable tumor was detected. One patient with a positive EOT PET (new-onset FDG avid mediastinal lymph node; SUV 16), underwent endobronchial ultrasound fine-needle aspiration cytology from mediastinal lymph node that showed granulomatous inflammation suggestive of tuberculosis. He was initiated on antituberculous therapy and repeat PET-CT after 4 months showed regression of the node.

Efficacy of EOT PET-CT

Among the entire cohort, sensitivity, specificity, NPV, and PPV of EOT PET-CT were 100, 34.38, 100, and 8.7%, respectively. In the 23 patients who had residual masses \geq 3 cm on imaging, the sensitivity, specificity, NPV, and PPV were 100, 23.8, 100, and 11.1%, respectively (**Table 2**). Eighteen patients underwent an EOT PET-CT on or after the 6-week cutoff; fourteen (77.78%) had a positive EOT PET-CT. Among 16 patients who underwent EOT PET before the 6-week cutoff, 9 (56%) had a positive EOT PET-CT (**Table 3**). When a SUV cutoff of \geq 4 was

Table 1 Baseline characteristics ($n = 34$)

	N (%)
Median age in years (range)	35 (16–54)
Gender	
• Male	34 (100)
Site of primary	
• Gonadal	25 (73.5)
• Retroperitoneal	0 (0)
• Mediastinal	9 (26.5)
Median size of retroperitoneal nodal/mediastinal mass at baseline in cm (range)	11.4 (1.6–25)
Median baseline AFP (IU/mL)	1.7 (0.6–2.6)
Median baseline HCG (m-IU/mL)	26.96 (0.5–859)
Median baseline LDH (U/L)	1,378 (411.5–15,500)
Stage (gonadal primary only; $N = 25$)	
• I	8 (32)
• II	17 (68)
IGCCCG risk stratification at baseline	
• Good	14 (41.2)
• Intermediate	20 (58.8)
Line of treatment	
• First line	35 (100)
Chemotherapy regimen	
• BEP X3	29 (85.3)
• EP X4	4 (11.8)
• Carboplatin based	1 (2.9)
Median residual lesion size on EOT PET-CT (in cm)	3.9 (1.1–11.6)
Median EOT LDH (U/mL)	425 (284–927)
Median time interval between date of last chemotherapy and EOT PET-CT	6 (3–12)
Adequacy of EOT PET-CT timing	
< 6 wk	16 (47.1)
\geq 6 wk	18 (52.9)
Median follow-up	23 mo
Median PFS	19 mo

Abbreviations: AFP, alpha-fetoprotein; BEP, bleomycin, etoposide, and cisplatin; CT, computed tomography; EOT, end-of-treatment; EP, etoposide and cisplatin; HCG, human chorionic gonadotropin; IGCCCG, International Germ Cell Cancer Collaborative Group; LDH, lactate dehydrogenase; PET, positron emission tomography; PFS, progression-free survival.

applied, the EOT PET-CT was interpreted as positive in only 6 out of 34 patients (17.6%).

Clinical Course after EOT PET-CT

Among 23 patients with positive EOT PET-CT, 10 underwent subsequent PET-CT at various intervals. This showed either

Table 2 Overall PET-CT (discrimination of residual tumor size, < or \geq 3 cm) results

	N	Mode	TN	FN	TP	FP	NPV (%)	PPV (%)
All patients	34	PET	11	0	2	21	100	8.7
Residual mass \geq 3 cm	23	PET	5	0	2	16	100	11.11

Abbreviations: CT, computed tomography; FN, false negative; FP, false positive; NPV, negative predictive value; PET, positron emission tomography; PPV, positive predictive value; TN, true negative; TP, true positive.

Table 3 Overall EOT-PET discrimination of residual tumor size based on timing of scan (< 6 weeks and \geq 6 weeks) results

	N	TN	FN	TP	FP	NPV (%)	PPV (%)
< 6 wk	16	0	8	1	7	100	12.51
\geq 6 wk	18	0	3	1	14	100	6.67

Abbreviations: EOT, end-of-treatment; FN, false negative; FP, false positive; NPV, negative predictive value; PET, positron emission tomography; PPV, positive predictive value; TN, true negative; TP, true positive.

decrease in size of the mass or decrease in SUV in six of these patients. CT imaging on follow-up showed decrease in size of the residual lesion in 11 patients and 2 patients did not undergo subsequent CT/PET-CT.

Discussion

We evaluated the utility of EOT PET-CT in the management of post-chemotherapy residual masses, among patients with seminomatous GCTs. Though the SEMPET trial was the first to demonstrate a PPV of 100% for masses greater than 3 cm, subsequent real-world experiences were unable to replicate this finding; with PPVs ranging from 23 to 72% (**Table 4**).^{11,15,16}

A prior real-world analysis among 90 patients with EOT PET positive post-chemo residual masses > 3 cm failed to replicate these values, with PPVs ranging from 22 to 42%; thus, questioning the role of EOT PET-guided treatment among these patients.¹⁵⁻¹⁷ Also, the timing of PET-CT, that is, < 6 versus > 6 weeks after the last dose of chemotherapy, played a role; with the PPV varying from 29 to 19%.¹⁵

In our series, we were able to demonstrate a high NPV of 100% with EOT PET-CT among patients with > 3 cm post-chemotherapy masses (**Table 2**). But the PPV remained low akin to other real-world experiences that have been described. Among 23 patients with positive EOT PET-CTs based on the SEMPET trial interpretation, only 2 were termed as TP, and that too, only because they received consolidation RT. This indicates the need for a more objective interpretation of EOT PET scans; either using an SUV cutoff or scoring systems similar to those being used in Hodgkin's lymphoma.^{6,18,19}

The recommended timing of the EOT PET-CT varies across guidelines and there is an ambiguity associated with the time points involved. The SEMPET trial protocol allowed EOT PET-CT to be done 4 to 12 weeks "after chemotherapy."¹¹ In contrast to earlier studies, we did not detect any reduction in the rates of FP scans based on the cutoff of \geq 6 weeks among our patients (**Table 3**). In low- and middle-income country settings like ours, the higher incidence of chronic infections like tuberculosis may act as confounders and contribute to a false positivity as demonstrated in one of our patients with a FPEOT PET due to tuberculosis involving a mediastinal lymph node. Our median follow-up was 23 months; however, prior data suggest that most relapses occur within a maximum of 129 days after initial PET or resection or biopsy.¹⁵

This retrospective analysis confirms the therapeutic implication of high NPV of EOT PET-CT among patients with seminomatous GCTs. Our experience of a low PPV in contrast with the SEMPET trial is consistent with other real-world reports. Factors playing a role in this include: majority of patients undergoing EOT PET-CT earlier than the cutoff of 6 weeks and the lack of an objective definition of a "positive PET-CT." The major limitations of our study were its retrospective nature, short median follow-up (late relapses can occur with seminomas), inclusion of patients with residual

Table 4 List of studies evaluating role of EOT PET-CT in seminoma

Author	Year	N	First line/ Salvage	> 3 cm	Median time from last chemo	Definition of positive EOT PET-CT	PPV (%)	NPV (%)	PPV > 3 cm (%)	NPV > 3 cm (%)	Median follow-up (mo)
De Santis	2004	56	43/13	19	42 d	Visual	100	96	92	37	34
Bachner	2012	127	125/2	73	56 d	Visual	42	93	50	94	31
Cathomas ^a	2018	90	90/0	90	6.9 wk	Visual	23	X	22	X	29
Sharma	2014	47	NA	NA	NA	Visual interpretation	72	90	X	X	X
Our study	2020	34	34/0	23	42 d	Visual interpretation	8.7	100	11.1	100	23

Abbreviations: CT, computed tomography; EOT, end-of-treatment; NPV, negative predictive value; PET, positron emission tomography; PPV, positive predictive value.

^aAll patients had EOT PET positive residual tumors > 3 cm.

masses < 3 cm in size, and the higher proportion of patients undergoing scanning before the 6-week cutoff.

With the emerging data regarding the role of estimation of serum micro-ribonucleic acid (mi-RNA) 371 in predicting viable tumor among patients with GCTs and residual post-chemotherapy masses, the combination of an EOT PET-CT together with mi-RNA 371 estimation, is likely to outperform either test as an individual entity.²⁰

Conclusion

Interpretation of EOT PET-CT in residual post-chemotherapy masses using the visual interpretation criteria may result in overestimation of residual viable tumor and overtreatment. A negative EOT PET-CT in seminoma with post-chemotherapy masses > 3 cm helps avoid unnecessary RPLND or surgical excision of a residual mediastinal mass. Close follow-up of positive EOT PET-CT among patients with seminoma post-chemo residual masses \geq 3 cm is a safe and feasible option.

Authors' Contributions

Anjana Joel: Conceptualization, methodology, formal analysis, investigation, writing - original draft, and visualization.

Ashish Singh: Conceptualization, methodology, formal analysis, investigation, writing - review and editing, visualization, and supervision.

Julie Hepzibah: Conceptualization, methodology, formal analysis, investigation, writing - review and editing, visualization, project administration, and funding acquisition.

Antony Devasia: Conceptualization, methodology, formal analysis, investigation, writing - review and editing, visualization, and supervision.

Santosh Kumar: Conceptualization, methodology, formal analysis, investigation, writing - review and editing, visualization, and supervision.

Birla Roy Gnanamuthu: Conceptualization, methodology, formal analysis, investigation, writing - review and editing, and visualization.

Anuradha Chandramohan: Conceptualization, methodology, formal analysis, investigation, writing - review and editing, and visualization.

Arun Jacob Philip George: Conceptualization, methodology, formal analysis, investigation, writing - review and editing, and visualization

Nirmal Thampi John: Conceptualization, methodology, formal analysis, investigation, writing - review and editing, and visualization.

Bijesh Yadav: Formal analysis, data curation, and software.

Ajoy Oommen John: Conceptualization, methodology, formal analysis, writing - review and editing, and visualization.

Josh Thomas Georgy: Formal analysis, investigation, writing - original draft, and visualization.

Subhashini John: Formal analysis, investigation, writing - original draft, and visualization.

Raju Titus Chacko: Conceptualization, methodology, formal analysis, investigation, writing - review and editing,

visualization, supervision, project administration, and funding acquisition.

Funding

None.

Conflict of Interest

None declared.

References

- 1 Powles TB, Bhardwa J, Shamash J, Mandalia S, Oliver T. The changing presentation of germ cell tumours of the testis between 1983 and 2002. *BJU Int* 2005;95(09):1197-1200
- 2 Tandstad T, Smaaland R, Solberg A, et al. Management of seminomatous testicular cancer: a binational prospective population-based study from the Swedish Norwegian Testicular Cancer Study Group. *J Clin Oncol* 2011;29(06):719-725
- 3 Flechon A, Bompas E, Biron P, Droz J-P. Management of post-chemotherapy residual masses in advanced seminoma. *J Urol* 2002;168(05):1975-1979
- 4 Ravi R, Ong J, Oliver RT, Badenoch DF, Fowler CG, Hendry WF. The management of residual masses after chemotherapy in metastatic seminoma. *BJU Int* 1999;83(06):649-653
- 5 Schultz SM, Einhorn LH, Conces DJ Jr, Williams SD, Loehrer PJ. Management of postchemotherapy residual mass in patients with advanced seminoma: Indiana University experience. *J Clin Oncol* 1989;7(10):1497-1503
- 6 King J, Adra N, Einhorn LH. Management of residual disease after chemotherapy in germ cell tumors. *Curr Opin Oncol* 2020;32(03):250-255
- 7 Puc HS, Heelan R, Mazumdar M, et al. Management of residual mass in advanced seminoma: results and recommendations from the Memorial Sloan-Kettering Cancer Center. *J Clin Oncol* 1996;14(02):454-460
- 8 Herr HW, Sheinfeld J, Puc HS, et al. Surgery for a post-chemotherapy residual mass in seminoma. *J Urol* 1997;157(03):860-862
- 9 Bilen MA, Hariri H, Leon C, et al. Positive FDG-PET/CT scans of a residual seminoma after chemotherapy and radiotherapy: case report and review of the literature. *Clin Genitourin Cancer* 2014;12(04):e147-e150
- 10 Mosharafa AA, Foster RS, Leibovich BC, Bihrl R, Johnson C, Donohue JP. Is post-chemotherapy resection of seminomatous elements associated with higher acute morbidity? *J Urol* 2003;169(06):2126-2128
- 11 De Santis M, Becherer A, Bokemeyer C, et al. 2-18fluoro-deoxy-D-glucose positron emission tomography is a reliable predictor for viable tumor in postchemotherapy seminoma: an update of the prospective multicentric SEMPET trial. *J Clin Oncol* 2004;22(06):1034-1039
- 12 Saju SV, Radhakrishnan V, Ganesan TS, et al. Factors that impact the outcomes in testicular germ cell tumors in low-middle-income countries. *Med Oncol* 2019;36(03):28
- 13 Joshi A, Zanwar S, Shetty N, et al. Epidemiology of male seminomatous and nonseminomatous germ cell tumors and response to first-line chemotherapy from a tertiary cancer center in India. *Indian J Cancer* 2016;53(02):313-316
- 14 Sharma P, Jain TK, Parida GK, et al. Diagnostic accuracy of integrated (18)F-FDG PET/CT for restaging patients with malignant germ cell tumours. *Br J Radiol* 2014;87(1040):20140263
- 15 Cathomas R, Klingbiel D, Bernard B, et al. Questioning the value of fluorodeoxyglucose positron emission tomography for residual lesions after chemotherapy for metastatic seminoma: results of an International Global Germ Cell Cancer Group Registry. *J Clin Oncol* 2018;36:JCO1800210

- 16 Bachner M, Lorient Y, Gross-Goupil M, et al. 2-18fluoro-deoxy-D-glucose positron emission tomography (FDG-PET) for postchemotherapy seminoma residual lesions: a retrospective validation of the SEMPET trial. *Ann Oncol* 2012;23(01):59–64
- 17 Treglia G, Sadeghi R, Annunziata S, Caldarella C, Bertagna F, Giovannella L. Diagnostic performance of fluorine-18-fluorodeoxyglucose positron emission tomography in the postchemotherapy management of patients with seminoma: systematic review and meta-analysis. *BioMed Res Int* 2014;2014:852681
- 18 Ganjoo KN, Chan RJ, Sharma M, Einhorn LH. Positron emission tomography scans in the evaluation of postchemotherapy residual masses in patients with seminoma. *J Clin Oncol* 1999;17(11):3457–3460
- 19 Cheson BD, Fisher RI, Barrington SF, et al; Alliance, Australasian Leukaemia and Lymphoma Group Eastern Cooperative Oncology Group European Mantle Cell Lymphoma Consortium Italian Lymphoma Foundation European Organisation for Research Treatment of Cancer/Dutch Hemato-Oncology Group Grupo Español de Médula Ósea German High-Grade Lymphoma Study Group German Hodgkin's Study Group Japanese Lymphoma Study Group Lymphoma Study Association NCIC Clinical Trials Group Nordic Lymphoma Study Group Southwest Oncology Group United Kingdom National Cancer Research Institute. Recommendations for initial evaluation, staging, and response assessment of Hodgkin and non-Hodgkin lymphoma: the Lugano classification. *J Clin Oncol* 2014;32(27):3059–3068
- 20 Dieckmann K-P, Radtke A, Geczi L, et al. Serum levels of microRNA-371a-3p (M371 test) as a new biomarker of testicular germ cell tumors: results of a prospective multicentric study. *J Clin Oncol* 2019;37(16):1412–1423