










ORIGINAL RESEARCH

Impact of Impella RP Versus Vasoactive Treatment on Right and Left Ventricular Strain in a Porcine Model of Acute Cardiogenic Shock Induced by Right Coronary Artery Embolization

Peter H. Frederiksen , MD; Jakob Josiassen , MD, PhD; Nanna L. J. Udesen , MD, PhD; Louise Linde, MD; Ole K. Helgestad , MD, PhD; Ann Banke , MD PhD; Lisette O. Jensen, MD, PhD, DMSc; Henrik Schmidt , MD, DMSc; Christian Hassager , MD, DMSc; Hanne B. Ravn , MD, PhD, DMSc*; Jacob E. Møller , MD, PhD, DMSc*

BACKGROUND: The response of the left ventricle to cardiogenic shock (CS) caused by right ventricular (RV) infarction and the effect of treatment with either vasoactive treatment or Impella RP are not well described. We sought to determine RV and left ventricular longitudinal strain (LS) by echocardiography after initiation of either Impella RP or vasoactive treatment for CS induced by right coronary artery embolization.

METHODS AND RESULTS: CS was induced with microsphere embolization in the right coronary artery in 20 pigs. Shock was defined as a reduction in cardiac output of $\geq 50\%$ and/or an $SvO_2 < 30\%$. At the time of CS either Impella RP or vasoactive treatment (norepinephrine and milrinone) was initiated. Echocardiography and conductance measures were obtained at baseline, when CS was present, and 30, 90, and 180 minutes after induction of CS. Of 20 animals, 14 completed the protocol and were treated with either vasoactive treatment ($n=7$) or Impella RP ($n=7$); 6 animals died (3 in each group). In the RV there was a significantly higher LS with the vasoactive treatment compared with Impella RP (-7.6% [4.5] to -6.0% [5.2] vs -4.5% [6.6] to -14.2% [10.6]; $P < 0.006$). Left ventricular LS improved with both treatments compared with shock, but with a larger effect (-9.4% [3.2] to -17.9% [3.6]) on LS with vasoactive treatment than Impella RP (-9.8% [3.1] to -12.3% [4.6]; $P < 0.001$). We found a significant correlation between stroke work and RV LS ($r = -0.60$, $P < 0.001$) and left ventricular LS ($r = -0.62$, $P < 0.001$).

CONCLUSIONS: We found significantly higher hemodynamic effects with vasoactive treatment compared with Impella RP in both the RV and left ventricular but at a cost of increased stroke work.

Key Words: acute heart failure ■ cardiogenic shock ■ percutaneous mechanical circulatory support

Acute myocardial infarction and subsequent cardiogenic shock (CS) attributable to predominantly right ventricular (RV) failure remains a clinical challenge,¹ as symptoms and intensive care treatment differ from CS attributable

to left ventricular (LV) failure. RV failure is characterized by a triad of hypotension, signs of elevated central venous pressure (CVP) and clear lung fields.² Revascularization is recommended by current guidelines³ in all patients with CS following

Correspondence to: Peter H. Frederiksen, MD, Department of Cardiology, Odense University Hospital, J. B. Winslows Vej 4, DK-5000 Odense C, Denmark. Email: peter.hartmund.frederiksen@rsyd.dk

*H.B. Ravn and J.E. Møller contributed equally.

For Sources of Funding and Disclosures, see page 10.

© 2022 The Authors. Published on behalf of the American Heart Association, Inc., by Wiley. This is an open access article under the terms of the [Creative Commons Attribution-NonCommercial-NoDerivs](https://creativecommons.org/licenses/by-nc-nd/4.0/) License, which permits use and distribution in any medium, provided the original work is properly cited, the use is non-commercial and no modifications or adaptations are made.

JAHA is available at: www.ahajournals.org/journal/jaha

CLINICAL PERSPECTIVE

What Is New?

- We found modest correlations with speckle tracking echocardiography, but speckle tracking echocardiography provides information on regional myocardial changes, which cannot be derived from conductance catheter techniques.
- Observations should be further investigated in clinical prospective cohort studies.

What Are the Clinical Implications?

- Vasoactive treatment improved longitudinal strain more than mechanical circulatory support in both the right and left ventricle. Increase in cardiac output was comparable between interventions, but with a higher stroke work with vasoactive treatment.
- In clinical practice, this increase in stroke work should be balanced against unloading and organ perfusion.

Nonstandard Abbreviations and Acronyms

CS	cardiogenic shock
LS	longitudinal strain
CO	cardiac output
TDI	tissue doppler images

acute myocardial infarction, while further treatment options are only supported by low grade evidence. Empirical management consists of maintained RV preload with fluid, alleviation of arrhythmias, reestablishment of atrioventricular synchrony and pacing as appropriate.³ Vasopressors and inotropes such as norepinephrine and milrinone are used to improve blood pressure and cardiac output (CO), but the treatment is a double-edged sword. It increases cardiac output and perfusion pressure, but comes at the cost of increased myocardial energy consumption; risk of arrhythmias; and in more severe heart failure, it may not be sufficient to restore perfusion.^{4,5} The transvalvular axial flow pump Impella RP is an RV percutaneous assist device for RV support, where blood is propelled inside the catheter from the inferior vena cava, bypassing the RV, and delivered into the pulmonary artery (PA). This approach aims at improving LV preload and thereby increasing systemic CO, supporting end organs and at the same time unloading of the RV without increased energy consumption. In feasibility and safety studies, the device has proven efficient in

reducing right-sided filling pressures and increasing CO in CS caused by RV failure.^{6,7}

We recently described changes with both treatments in a porcine model of acute RV infarction with effect monitored using conductance catheters.⁴ Although, invasive conductance catheters are ideal for understanding underlying physiology, they are not well suited for clinical use. In addition, interpretation of pulmonary artery catheter derived variables with partly laminar flow in the pulmonary circulation, which may not be equally divided between pulmonary arteries, as seen with Impella RP, are challenging. In this context, a closer evaluation of echocardiographic changes, during induction of RV CS and therapeutic interventions, is warranted.

The objective of this experimental study was to compare longitudinal function of the right and left ventricle assessed with speckle tracking echocardiography and tissue-Doppler echocardiography, after induction of RV CS and to assess the effects of Impella RP versus vasoactive treatment. Further, we aimed to relate echocardiographic changes with conductance derived measures.

METHODS

The study includes 20 female Danish land race pigs weighing between 75 and 80 kg. The study was approved and conducted in accordance with current guidelines from the Danish Animal Experiments Expectorate (ID number: 2016-15-00951). The data underlying this article will be shared on reasonable request to the corresponding author. A detailed study protocol has previously been published.⁴ Briefly all animals were anesthetized and mechanically ventilated. Instrumentation was done using the Seldinger technique, except for access to the left internal jugular vein where surgical cut down was performed because of small vessel caliber. Vascular sheaths were 6–14 Fr as appropriate. We placed conductance catheters (Ventricath 512 PV Loop Catheter, Millar Inc. TX, USA) under fluoroscopic guidance from the left external jugular vein and the right carotid artery to the right and left ventricle, respectively. For invasive pressure readings, CO and mixed venous saturation (SvO₂), a Swan-Ganz catheter (Edwards Lifesciences Corp. Irvine, CA, USA) was advanced to the PA. Peripheral arterial blood pressure was measured in a 6Fr sheath in the femoral artery. Pulmonary artery pulsatility index (PAPI) was calculated as $PAPI = (\text{systolic PA pressure} - \text{diastolic PA pressure}) / \text{CVP}$.⁸

For induction of CS, a stepwise embolization into the right coronary artery with a 3.5 JL or 4.0 JR guiding catheter (Launcher, Medtronic Inc, MN, USA) was performed with 125 μg of polyvinyl alcohol microspheres

(Contour; Boston Scientific, Marlborough, USA) dissolved in 10 mL saline and 10 mL contrast. Intracoronary injections of 1 mL microsphere solution were done every 3 minutes until CS. CS was defined as a sustained reduction in CO of $\geq 50\%$ and/or a $\geq 50\%$ reduction in SvO₂ compared with baseline or an absolute SvO₂ $\leq 30\%$.

When CS was present interventions were initiated and continued for 180 minutes. The treatment allocation was randomly decided a week before the study date. In the Impella RP group, the device was inserted during fluoroscopic guidance from the left femoral vein and the device started immediately at the time of CS. Performance level was kept at the highest possible output without causing any suction alarms. To assure coronary perfusion norepinephrine infusion was introduced if the mean arterial pressure was < 50 mmHg after initiation of Impella RP. The vasoactive comparator consisted of a continuous infusion of a moderate norepinephrine dose ($0.10 \mu\text{g}/\text{kg}/\text{min}$) for 30 minutes after which a milrinone bolus of $50 \mu\text{g}/\text{kg}$ infused over 10 minutes followed by a continuous milrinone infusion of $0.4 \mu\text{g}/\text{kg}/\text{min}$ for the remaining 140 minutes. After 180 minutes, all interventions were terminated, and the animals were euthanized.

Data Collection

Prespecified in the study protocol, data were acquired at the following time points: baseline, time when CS was present, and after 30, 90, and 180 minutes following initiation of interventions. At each time point, hemodynamic data (mean arterial pressure, PA pressure, CVP, CO, SvO₂ and heart rate) was obtained and an echocardiographic assessment was performed.

Hemodynamic Measurements

Conductance catheters were connected to an MPVS Ultra Pressure-Volume (PV) loop system (Millar Inc., Houston, TX, USA) The PV loop system was connected to a PowerLab 16/35 (ADInstruments, Dunedin, New Zealand) and PV measurements were continuously displayed and stored for subsequent off-line analysis using Labchart Pro (ADInstruments, Dunedin, New Zealand). Volume calibration was performed using an alpha correctional value and with the hypertonic saline method parallel wall conductance was determined.⁴ Following data were recorded: Pressure-volume area (PVA, mmHg \times mL), LV end-diastolic volume (LVEDV, mL), LV end-systolic volume (LVESV, mL), LV stroke work (LVSW, mmHg \times mL), LV output (mL/min), LV end-systolic pressure-volume relationship. When estimating end-systolic pressure-volume relationship and PVA we only determined V₀ with preload reduction at baseline

because of severely compromised hemodynamic at the time of shock, and as inferior vena cava occlusion is not feasible with Impella RP running. Thus, the acquired V₀ was kept constant for single beat estimations of PVA and end-systolic pressure-volume relationship.⁹

Echocardiography

Echocardiography was performed with a Vivid E95 ultrasound system (General Electric, Horten, Norway). All images were analyzed offline with EchoPac (Version 203, General Electric). The ultrasound probe was placed immediately beneath the diaphragm through a subxiphoid midline incision. From this position, modified 4-chamber and 5-chamber view was obtained. Frame rate was kept at a minimum of 60 frames per second. In addition, M-mode recording of lateral tricuspid annulus for measurement of tricuspid annular plane systolic excursion, pulsed wave Doppler recording in the left ventricular outflow tract (LVOT) to measure the LVOT velocity time integral and tissue Doppler images (TDI).

For strain analysis, the region of interest was adjusted to cover the whole myocardium. RV strain analysis was done in the RV lateral free wall. LV longitudinal strain (LS) was obtained from the 4-chamber view and separated in septal and lateral values. For pulsed wave tissue Doppler imaging was obtained with sample volume placed in the lateral and septal mitral annulus and the lateral tricuspid annulus where s' was measured.

For assessment of basal septal movement, we placed a post hoc m-mode line perpendicular to the LV cavity in the modified 4-chamber view. We then measured the movement towards the LV cavity in systole with positive values reflecting an inward movement towards the LV cavity and a negative value reflecting a paradox movement towards the RV cavity in systole.

Statistical Analysis

Data are presented as mean and standard deviation for normally distributed values. For analysis of treatment effect of vasoactive treatment and Impella RP we used a mixed effects model with selected hemodynamic measures as dependent variables. The model was limited to time points after the CS criteria was met and was adjusted for differences at shock, interaction between time and intervention and time included as a categorical variable. The reported *P* value refers to the difference between interventions at 180 minutes. Baseline values were excluded from the analysis. The model used random intercept and independent covariance matrix.

For PAPI, CVP, LV, and RV stroke work we performed the mixed model with bootstrapping (1000

replications). As heart rate was significantly different vasoactive treatment and the Impella RP group, heart rate was added to the model and Akaike information criteria were assessed and the models were tested with the likelihood-ratio test. For correlation analysis between pressure volume loop data and LS we used Spearman and linear regression. The study was powered for a primary end point published by Josiassen et al.¹

We used STATA 17 (StataCorp, College Station, TX, USA) for the analysis and a significance level of $P < 0.05$ was considered significant.

RESULTS

Prespecified criteria for shock were achieved in all 20 animals, [Table 1](#). Six animals died shortly after shock induction because of refractory arrhythmia (3 from each treatment arm). Of the remaining 14 animals, 7 were treated with vasoactive treatment and 7 with Impella RP. RV failure was evident by elevation of CVP and >50% reduction in CO, PAPI, and mixed venous saturation. There were no statistically significant differences between the 2 groups at shock, [Table 1](#). Detailed hemodynamic changes have been published previously.⁴ For CVP we found a mild reduction with initiation of treatments without significant difference over time between interventions. PAPI increased with both interventions from CS, and the difference was not significant ($P = 0.6$). The CO and mixed venous saturation increased with interventions and was significantly lower in the Impella RP group ($P < 0.001$ and $P = 0.004$, respectively).

Echocardiographic Changes

RV LS deteriorated in both groups from baseline to CS, and with vasoactive treatment we found significant improvement in RV LS, whereas Impella RP caused only minor changes, [Table 2](#) and [Figure 1](#) ($P = 0.006$). Both interventions increased RV s', but the improvement was more pronounced with the vasoactive treatment ($P = 0.008$). Tricuspid annular plane systolic excursion increased in the vasoactive group, but not in the Impella RP group ($P = 0.017$). LV LS deteriorated as well from baseline to CS, with concomitantly significant reductions in s' and LVOT velocity time integral, [Table 2](#) and [Figure 2](#). Paradoxical septal motion was observed in the majority of animals, with a shift from an inward systolic motion at baseline, to a paradox systolic movement towards the RV after CS induction ([Table 2](#)). LV LS improved in both groups although to a greater degree in the vasoactive group ($P \leq 0.001$), [Figure 3](#). When dividing LV LS into a septal and lateral wall, the interventions had significantly different impact. In the entire interventricular

septum, myocardial deformation was almost absent and with limited response to both interventions. In contrast, the lateral wall LS was restored back to baseline with Impella RP, and vasoactive treatment induced a hyperdynamic state compared with baseline. Addition of HR to the model did not change results.

Septal TDI s' improved with both treatments, [Table 2](#). There was a 2-fold increase in the septal s' with vasoactive treatment, which was less pronounced with Impella RP, [Table 2](#).

Comparison of Echocardiographic Assessment With Hemodynamics and Pressure Volume Loop Assessment

LVOT velocity time integral values decreased significantly after induction of CS, and both interventions had comparable improvement after 180 minutes. CO and LVOT velocity time integral curves demonstrated similar trends over time with minor deviations, [Figure 4](#). LV end-systolic pressure-volume relationship was significantly higher in the vasoactive group and similar observations were seen in LV medial and lateral s' as well as LV LS total and lateral wall.

With vasoactive treatment we found a significantly higher stroke work compared with Impella RP in the LV ($P = 0.006$) and in the RV ($P = 0.04$). In [Figure 5](#), changes in LV LS and LV SW are displayed as percentage of baseline.

DISCUSSION

CS attributable to right coronary artery embolization caused a significant impairment in longitudinal ventricular function in both ventricles measured with both speckle tracking echocardiography and TDI, along with large reductions in CO and mixed venous saturation. The vasoactive treatment caused higher CO, mixed venous saturation, and a hyperdynamic state in the LV and RV, which was not observed with the Impella RP. In addition to assessment of global ventricular function, speckle tracking echocardiography provided insight in regional function and revealed different impact of the interventions.

Mechanical circulatory support devices are used to restore systemic organ perfusion in CS.¹⁰ Several systems are available, but the loading exerted to the heart differs significantly with the choice of device. When blood is drained from the left atrium or LV and ejected into the systemic circulation, LV volumes, end-diastolic pressure, and wall stress are reduced, leading to a reduction in ventricular workload and myocardial oxygen consumption.^{9,11,12} Although less well investigated, the same is to be expected when using an assist device to the RV. The unchanged RV LS during Impella RP

Table 1. Hemodynamics From Baseline to 180 Minutes

	Baseline		Shock		30 min		90 min		180 min		P value
	Vasoactive treatment n=10	Impella RP n=10	Vasoactive treatment n=10	Impella RP n=10	Vasoactive treatment n=7	Impella RP n=7	Vasoactive treatment n=7	Impella RP n=7	Vasoactive treatment n=7	Impella RP n=7	
Heart rate, bpm	78 (13)	76 (9)	72 (14)	71 (11)	87 (12)	77 (15)	105 (11)	81 (14)	104 (8)	79 (10)	
BP, mmHg	67 (6)	70 (5)	42 (7)	42 (7)	77 (20)	58 (14)	68 (13)	61 (4)	60 (9)	54 (5)	
PA, systolic, mmHg	31 (5)	28 (3)	29 (6)	25 (3)	31 (3)	31 (2)	37 (5)	34 (5)	37 (4)	32 (4)	
PA, diastolic, mmHg	16 (7)	17 (3)	16 (7)	16 (3)	14 (8)	20 (3)	18 (10)	20 (4)	18 (8)	18 (4)	
PA, mean, mmHg	24 (6)	23 (3)	22 (5)	20 (2)	23 (5)	25 (2)	27 (6)	26 (2)	27 (6)	25 (2)	
CVP, mmHg	10 (3)	8 (4)	15 (3)	12 (3)	13 (4)	10 (4)	12 (6)	12 (3)	13 (6)	12 (3)	0.253
Cardiac output, l/min	5.0 (0.7)	5.2 (0.6)	2.9 (0.5)	2.9 (0.5)	4.4 (0.7)	4.1 (0.7)	6.2 (0.9)	4.4 (0.8)	5.9 (1.1)	4.4 (0.9)	0.001
Mixed venous saturation, %	64.9 (13.6)	64.9 (6.1)	33.7 (15.3)	32.1 (9.7)	64.3 (12.3)	52.5 (10.7)	68.3 (10.0)	50.6 (4.8)	65.3 (14.6)	49.8 (12.0)	0.004
LV ESP, mmHg	79 (6.1)	85 (6.7)	56 (5.8)	61 (7.9)	99 (22.8)	77 (6.1)	83 (9.5)	79 (5.5)	81 (8.2)	76 (8.7)	
LV EDP, mmHg	14 (3)	16 (4)	13 (2)	15 (3)	15 (4)	17 (5)	13 (3)	16 (5)	14 (4)	16 (5)	
LV stroke work, mmHg x mL	4550 (696)	4912 (475)	1906 (274)	1973 (421)	4386 (1274)	3376 (516)	4998 (932)	3685 (852)	4691 (891)	3614 (1224)	0.025
RV ESPVR	0.82 (0.16)	0.92 (0.22)	0.56 (0.13)	0.66 (0.16)	1.38 (0.50)	0.82 (0.20)	1.49 (0.42)	0.89 (0.28)	1.21 (0.36)	0.75 (0.17)	
RV ESP, mmHg	28 (3)	27 (3)	31 (5)	29 (4)	35 (9)	33 (8)	32 (4)	31 (6)	33 (4)	32 (6)	
RV EDP, mmHg	14 (3)	13 (3)	16 (4)	15 (3)	17 (3)	15 (6)	15 (2)	14 (6)	15 (3)	14 (5)	
RV stroke work, mmHg x mL	1327 (180)	1356 (166)	708 (97)	791 (183)	955 (214)	826 (173)	1091 (296)	870 (217)	1118 (333)	868 (235)	0.043
RV ESPVR	0.33 (0.15)	0.39 (0.08)	0.23 (0.06)	0.27 (0.13)	0.35 (0.13)	0.43 (0.20)	0.34 (0.14)	0.34 (0.15)	0.31 (0.09)	0.40 (0.33)	
PAPi	1.60 (0.8)	1.66 (1.1)	0.88 (0.4)	0.82 (0.4)	1.47 (0.8)	1.40 (1.1)	2.00 (1.4)	1.41 (1.2)	1.99 (1.4)	1.33 (1.1)	0.595

Data presented as mean (SD). P values from mixed effects models at 180minutes.

BP indicates blood pressure; CVP, central venous pressure; EDP, end diastolic pressure; ESP, end systolic pressure; ESPVR, end-systolic pressure volume relationship; LV, left ventricle; PA, pulmonary artery; PAPi, pulmonary artery pulsatility index; PVA, pressure volume area; and RV, right ventricle.

Table 2. Echocardiographic Findings From Baseline to 180 Minutes

	Baseline		Shock		30 min		90 min		180 min		P value
	Vasoactive treatment	Impella RP	Vasoactive treatment	Impella RP	Vasoactive treatment	Impella RP	Vasoactive treatment	Impella RP	Vasoactive treatment	Impella RP	
LVIDd, cm	4.5 (0.5)	4.6 (0.4)	3.9 (0.6)	4.0 (0.7)	4.3 (0.7)	4.2 (0.9)	4.1 (0.5)	4.2 (0.9)	4.0 (0.6)	4.1 (0.9)	
LVIDs, cm	3.2 (0.6)	3.5 (0.7)	3.4 (0.6)	3.6 (0.5)	3.3 (0.5)	3.2 (0.8)	3.0 (0.4)	3.2 (0.7)	2.9 (0.4)	3.2 (0.5)	
RVIDd, cm	2.5 (0.5)	2.4 (0.5)	2.5 (0.8)	2.9 (0.7)	2.7 (0.4)	2.6 (0.3)	2.7 (0.5)	2.5 (0.6)	2.6 (0.7)	2.8 (0.7)	
RVIDs, cm	1.7 (0.6)	1.9 (0.6)	2.1 (0.8)	2.3 (0.6)	2.1 (0.5)	1.9 (0.4)	2.0 (0.5)	1.7 (0.7)	1.8 (0.7)	1.9 (0.8)	
LV s' septal, cm/s	3.0 (1.9)	3.2 (0.6)	1.6 (0.7)	1.8 (0.6)	4.2 (1.1)	2.7 (0.7)	6.6 (1.5)	2.7 (1.0)	6.7 (2.6)	3.4 (3.0)	0.000
LV s' lat, cm/s	4.8 (1.7)	5.8 (2.2)	5.3 (3.2)	4.7 (2.3)	8.4 (2.7)	5.9 (1.4)	11.7 (1.9)	5.8 (2.1)	12.4 (2.0)	6.2 (1.6)	0.001
LVOT VTI, cm	18.6 (2.1)	18.4 (2.3)	13.2 (4.0)	12.5 (1.8)	15.7 (2.6)	18.1 (3.7)	18.2 (3.5)	18.1 (3.8)	17.4 (3.5)	17.2 (2.0)	0.696
RV s', cm/s	5.5 (1.7)	5.4 (0.9)	3.0 (2.1)	3.1 (1.0)	5.4 (1.8)	4.6 (1.0)	8.2 (3.1)	3.3 (1.3)	7.1 (1.9)	4.6 (1.7)	0.008
TAPSE, mm	14.5 (2.8)	15.5 (4.3)	7.4 (2.2)	9.0 (2.6)	9.7 (3.5)	10.0 (3.2)	10.6 (3.1)	10.4 (4.0)	12.2 (3.1)	8.9 (2.5)	0.017
Septal movement, mm	5.3 (3.4)	4.3 (3.2)	-5.5 (2.8)	-4.5 (6.7)	-2.7 (2.4)	-4.8 (1.0)	-2.7 (3.7)	-4.0 (1.7)	-2.3 (5.1)	-3.6 (2.1)	0.507
RV LS	-17.0% (4.8)	-16.3% (5.1)	-4.5% (6.6)	-7.6% (4.5)	-11.4% (4.9)	-6.4% (6.1)	-12.0% (6.9)	-4.4% (9.0)	-14.2% (10.6)	-6.0% (5.2)	0.006
LV LS total	-15.0% (2.8)	-16.4% (3.0)	-9.4% (3.2)	-9.8% (3.1)	-15.2% (4.1)	-12.6% (3.9)	-15.8% (1.7)	-13.4% (3.1)	-17.9% (3.6)	-12.3% (4.6)	<0.000
LV LS septal	-11.0% (2.3)	-13.3% (3.1)	-2.1% (6.1)	-2.8% (4.7)	-1.8% (3.7)	-3.3% (2.8)	-1.8% (6.7)	-3.9% (1.7)	-2.8% (6.7)	-3.3% (3.0)	0.817
LV LS lateral	-19.6% (5.5)	-19.8% (4.9)	-15.7% (6.6)	-15.1% (4.7)	-24.1% (7.1)	-19.1% (5.9)	-24.8% (3.9)	-19.3% (6.6)	-26.4% (3.3)	-18.7% (7.1)	0.007

Data presented as mean (SD). P values from mixed models at 180 minutes.

LS indicates longitudinal strain; LV, left ventricle; LVIDd, left ventricle internal diameter at end diastole; LVIDs, left ventricle internal diameter at end systole; LVOT, left ventricular outflow tract; RV, right ventricle; RVIDd, right ventricle internal diameter at end diastole; RVIDs, right ventricle internal diameter at end systole; and TAPSE, tricuspid annular plane systolic excursion.

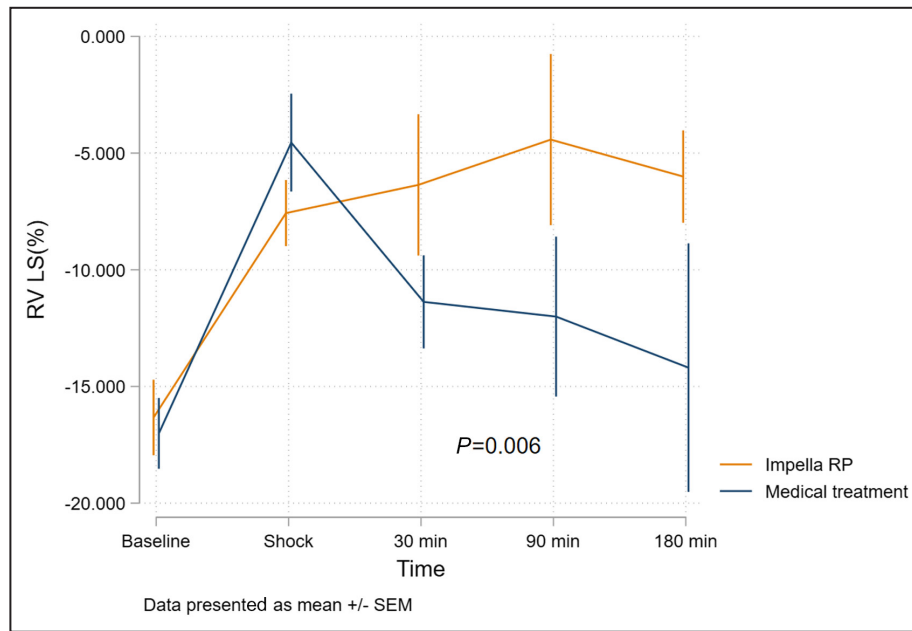


Figure 1. Right ventricular longitudinal strain.

Right ventricular longitudinal strain from baseline to 180 minutes after start of the interventions. Bars represent +/- SEM. *P* value from mixed effects model at 180 minutes. LS indicates longitudinal strain; and RV, right ventricle.

support compared with CS indicate that increased CO was achieved without increased work, but the increase in CO was not enough to restore systemic perfusion in terms of normalization of mixed venous saturation. In comparison, vasoactive treatment improved RV LS, as a sign of increased demand on RV function, but also CO and mixed venous saturation. In the same experimental study, we have previously demonstrated that treatment with the Impella RP provided unloading of the failing RV, while a vasoactive treatment strategy tended to be more efficient in restoring end-organ perfusion, at the cost of increased cardiac work,⁴ despite similar CVP levels over time in the 2 intervention groups. Thus, observations suggest some RV unloading with Impella RP, but to a lesser degree than we and others have demonstrated using left-sided transvalvular flow pumps.^{9,12}

Effect of Vasoactive Treatment and Impella RP on Echocardiographic Findings

Vasoactive treatment improved LS, as a sign of increased demand on RV function, but also CO and mixed venous saturation. This improvement observed in the pharmacological group is intriguing given the extensive embolization of the right coronary artery. In both humans and pigs the right coronary artery will supply a larger part of the RV free wall and much of the inferoposterior portion of the LV free wall and septum.

However, approximately one third of the RV free wall receives coronary blood flow from branches from the left anterior descending coronary artery in pigs.¹³ This could offer an explanation to the increased RV free wall motion with vasoactive treatment especially as the same degree of improvement was not seen in the interventricular septum.

The improvement in the LV was driven by changes in the lateral wall with vasoactive treatment. This is expected as treatment with milrinone increases cardiac contractility in noninfarcted myocardium because of its inotropic properties.^{14,15} Milrinone has a potent vasodilatory effect, which could cause a hyperdynamic effect attributable to a reduced afterload. However, we attempted to balance vasodilatation with the addition of norepinephrine, and mean arterial pressure was significantly higher in the vasoactive treatment arm compared with Impella RP.

Septal Function in Inferior Wall Myocardial Infarction

Interventricular septal function is crucial for the function of both the LV and RV. More than 70 years ago an animal study¹⁶ demonstrated that as long as the septal function remains intact, RV function is preserved, even with extensive RV free wall dysfunction. With CS induction in our study, the basal part of the septum became akinetic, as observed from LS values close to zero, and in most animals,

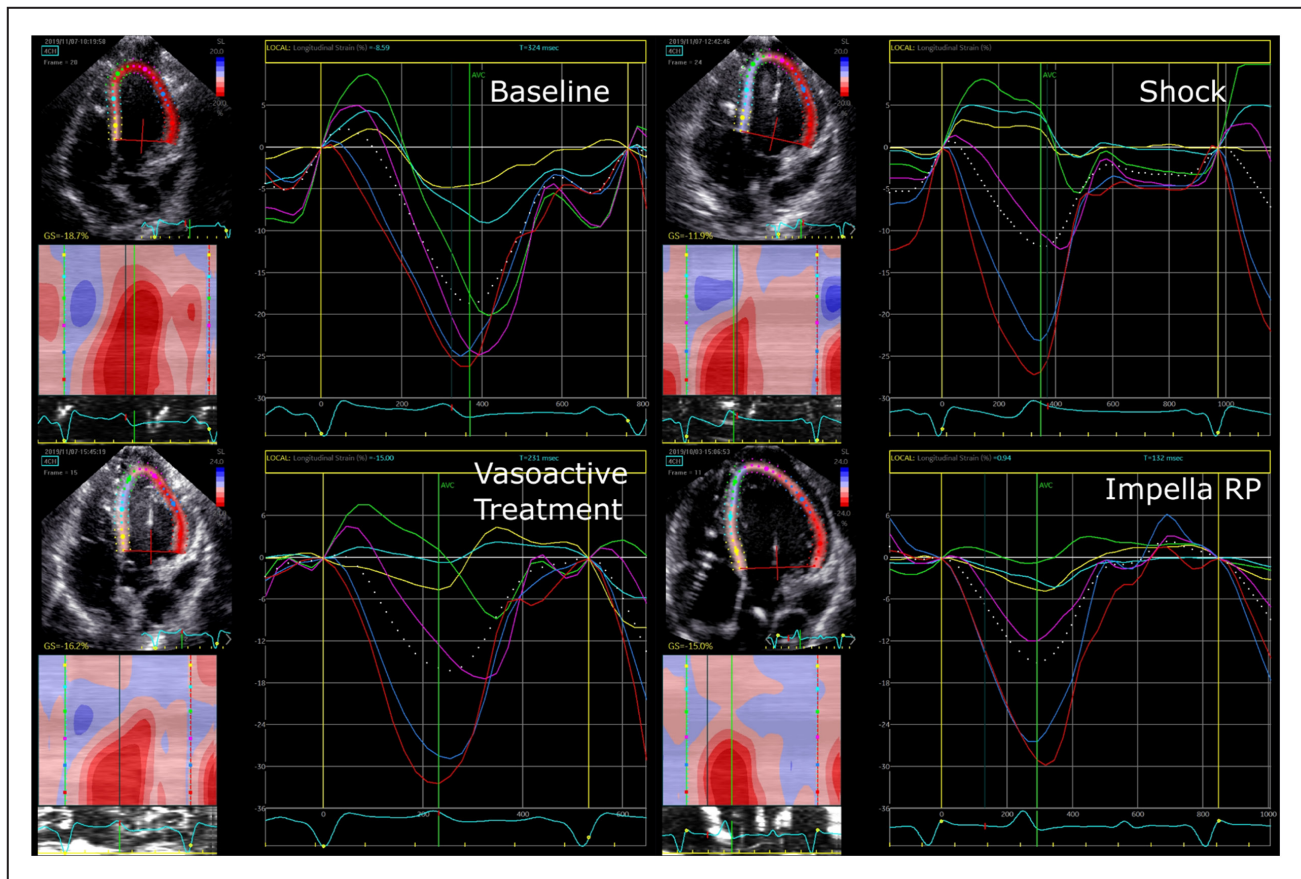


Figure 2. Representative left ventricular longitudinal strain curves from baseline, cardiogenic shock, vasoactive treatment, and Impella RP.

Note the severely reduced function of the septal wall at shock with positive strain values and the lower longitudinal strain values with vasoactive treatment compared with Impella RP.

we saw a paradox systolic movement towards the RV. This implies that both longitudinal and radial function is compromised. As microembolization is thought to cause irreversible obstruction of microcirculation, it was no surprise that none of the treatments improved septal LS. In contrast, we found improvements in both the septal and lateral wall in terms of TDI changes. The discrepancy between the LS and TDI findings can be explained by methodological differences. We hypothesize that LS largely represents changes in single segments opposed to TDI that measures velocity of motion of the myocardium adjacent to the mitral annulus either because of an active contraction or passive motion.

Three decades ago, Laster et al¹⁷ studied dogs with proximal total acute right coronary artery occlusion. In line with our findings, they reported increasing right atrial pressure, decreased RV systolic pressure, unchanged left atrial pressure, and decreased LV systolic pressure. With echocardiography, they found that the interventricular septum bulges paradoxically into the right ventricle in

systole. Within the first week, the paradox movement disappeared, but the segment showed a persistent reduced systolic function. This paradox movement is likely to represent the acute phase of nonreperfused inferior wall myocardial infarction. It is replaced within days with hypokinesia and some recovery of function and is thus not seen in studies where patients are examined days after acute myocardial infarction and have undergone revascularization.^{18,19}

LIMITATIONS

Our study is strengthened by the uniform, standardized, and effective method for inducing CS and comprehensive hemodynamic monitoring. There are, however, some methodological limitations. Because of the probe placement immediately beneath the diaphragm, most images had some degree of foreshortening. This affects the measurements of septal strain in the LV as the distal part of septum is supplied by the left anterior descending and might not

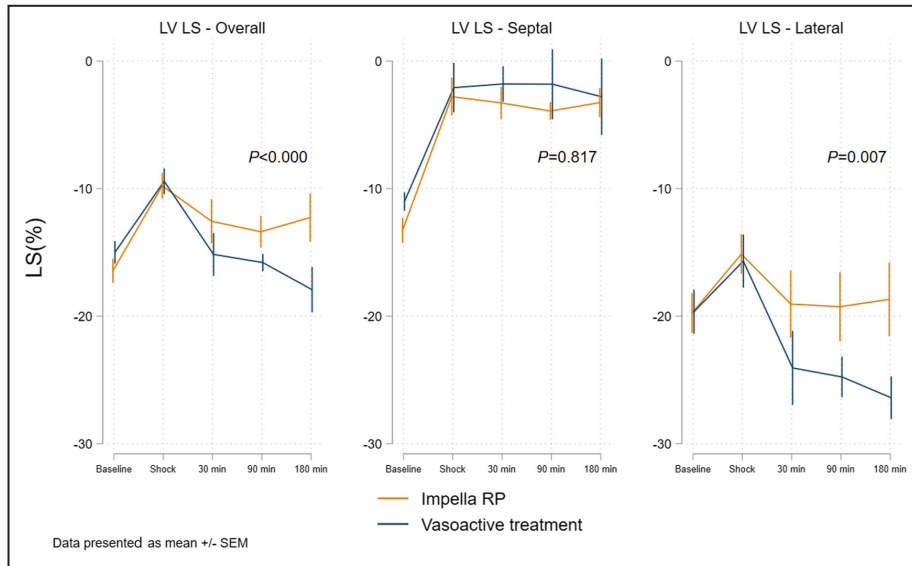


Figure 3. Left ventricular longitudinal strain. Left ventricular longitudinal strain from baseline to 180 minutes after start of the interventions. Left panel: Overall longitudinal strain values from the left ventricle. Middle panel: Left ventricular septal longitudinal strain only. Right panel: Left ventricular lateral wall longitudinal strain only. Bars represent +/- SEM. P value from mixed effects model at 180 minutes. LS indicates longitudinal strain; and LV, left ventricle.

be completely visualized. Attributable to comparison of relative changes by individual interventions, this is not expected to have any major impact. When performing LS measurements on thin-walled structures, like the RV, there is a substantial risk of tracking the

surrounding tissue. For both of the above mentioned limitations the interventions studied had no effect on the limitations, thus any introduced bias will be equal between groups. The timeframe of our study was only 3 hours, which is opposed to clinical practice where

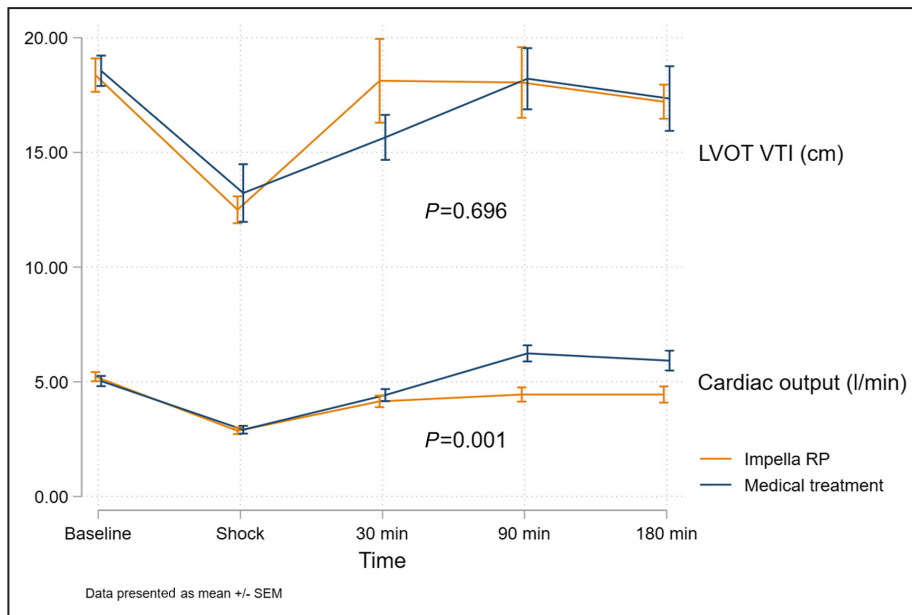


Figure 4. Cardiac output and left ventricular outflow tract velocity time integral. Cardiac output and left ventricular outflow tract velocity time integral from baseline to 180 minutes after start of the interventions. Bars represent +/- SEM. P value from mixed effects model at 180 minutes. LVOT indicates left ventricular outflow tract; and VTI, velocity time integral.

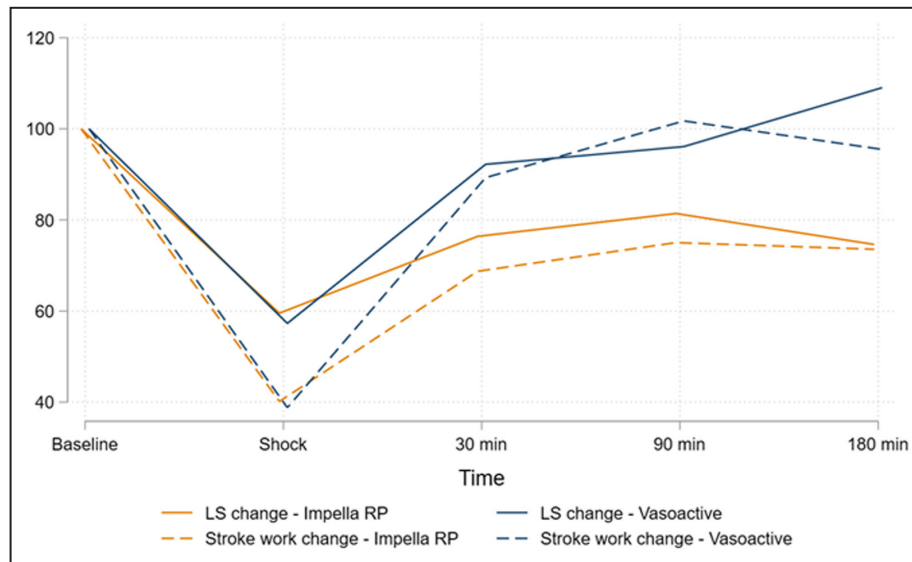


Figure 5. Left ventricular longitudinal strain and stroke work as percentage of baseline. Changes of left ventricular longitudinal strain and stroke work as percentage of baseline from baseline to 180 minutes after start of the interventions. LS indicates longitudinal strain; and LV, left ventricle.

support is used for days. Thus, our findings support only the initial treatment response. Finally, because of the limited number of animals in each intervention group, observational changes may not have reached statistical significance.

CONCLUSIONS

In this model of CS, because of right coronary artery embolization, we found significantly improved LS in the RV with vasoactive treatment compared with Impella RP. Similarly, in the LV the vasoactive treatment had a higher effect and caused a hyperdynamic state in the lateral wall of the LV not seen with Impella RP. These observations most likely reflect an increased stroke work.

ARTICLE INFORMATION

Received August 15, 2022; Revised November 29, 2022; accepted December 6, 2022.

Affiliations

Department of Cardiology, Odense University Hospital, Odense, Denmark (P.H.F., N.L.U., L.L., O.K.H., A.B., L.O.J., J.E.M.); Faculty of Health Sciences, University of Southern Denmark, Odense, Denmark (P.H.F., L.O.J., H.B.R., J.E.M.); Department of Cardiology, Heart Center, Copenhagen University Hospital Rigshospitalet, Copenhagen, Denmark (J.J., C.H., J.E.M.); and Department of Cardiothoracic Anaesthesiology, Odense University Hospital, Odense, Denmark (H.S., H.B.R.).

Sources of Funding

The study was funded by the research grant to Professor Møller. This funding source had no role in the design of this study and had no role during its execution, analyses, interpretation of the data, or decision to submit results.

Disclosures

Professor Møller has received a research grant from Abiomed. The remaining authors have no disclosures to report.

REFERENCES

- Josiassen J, Helgestad OKL, Møller JE, Schmidt H, Jensen LO, Holmvang L, Ravn HB, Hassager C. Cardiogenic shock due to predominantly right ventricular failure complicating acute myocardial infarction. *Eur Heart J Acute Cardiovasc Care*. 2021;10:33–39. doi: 10.1093/ehjacc/zuaa010
- Ibanez B, James S, Agewall S, Antunes MJ, Bucciarelli-Ducci C, Bueno H, Caforio ALP, Crea F, Goudevanos JA, Halvorsen S, et al. 2017 ESC guidelines for the management of acute myocardial infarction in patients presenting with ST-segment elevation. *Eur Heart J*. 2018;39:119–177. doi: 10.1093/eurheartj/ehx393
- McDonagh TA, Metra M, Adamo M, Gardner RS, Baumbach A, Böhm M, Burri H, Butler J, Celutkiene J, Chioncel O, et al. 2021 ESC guidelines for the diagnosis and treatment of acute and chronic heart failure. *Eur Heart J*. 2021;42:3599–3726. doi: 10.1093/eurheartj/ehab368
- Josiassen J, Helgestad OKL, Udesen NLJ, Banke A, Frederiksen PH, Schmidt H, Jensen LO, Hassager C, Møller JE, Ravn HB. Impella RP versus pharmacologic vasoactive treatment in profound cardiogenic shock due to right ventricular failure. *J Cardiovasc Transl Res*. 2021;14:1021–1029. doi: 10.1007/s12265-021-10131-x
- Udesen NLJ, Helgestad OKL, Banke ABS, Frederiksen PH, Josiassen J, Jensen LO, Schmidt H, Edelman ER, Chang BY, Ravn HB, et al. Impact of concomitant vasoactive treatment and mechanical left ventricular unloading in a porcine model of profound cardiogenic shock. *Crit Care*. 2020;24:1–10. doi: 10.1186/s13054-020-2816-8
- Anderson MB, Goldstein J, Milano C, Morris LD, Kormos RL, Bhama J, Kapur NK, Bansal A, Garcia J, Baker JN, et al. Benefits of a novel percutaneous ventricular assist device for right heart failure: the prospective RECOVER RIGHT study of the Impella RP device. *J Hear Lung Transplant*. 2015;34:1549–1560. doi: 10.1016/j.healun.2015.08.018
- Qureshi AM, Turner ME, O'Neill W, Denfield SW, Aghili N, Badiye A, Gandhi R, Tehrani B, Chang G, Oyama JK, et al. Percutaneous Impella RP use for refractory right heart failure in adolescents and young adults—a multicenter U.S. experience. *Catheter Cardiovasc Interv*. 2020;96:376–381. doi: 10.1002/ccd.28830
- Lim HS, Gustafsson F. Pulmonary artery pulsatility index: Physiological basis and clinical application. *Eur J Heart Fail*. 2020;22:32–38. doi: 10.1002/ejhf.1679
- Møller-Helgestad OK, Hyldebrandt JA, Banke A, Rud CS, Udesen NLJ, Linde L, Okkels-Jensen L, Schmidt H, Ravn HB, Møller JE. Impella CP or VA-ECMO in profound cardiogenic shock: left ventricular

- unloading and organ perfusion in a large animal model. *EuroIntervention*. 2019;14:e1585–e1592. doi: [10.4244/EIJ-D-18-00684](https://doi.org/10.4244/EIJ-D-18-00684)
10. Chieffo A, Dudek D, Hassager C, Combes A, Gramagna M, Halvorsen S, Huber K, Kunadian V, Maly J, Møller JE, et al. Joint EAPCI/ACVC expert consensus document on percutaneous ventricular assist devices. *Eur Hear Journal Acute Cardiovasc Care*. 2021;10:570–583. doi: [10.1093/ehjacc/zuab015](https://doi.org/10.1093/ehjacc/zuab015)
 11. Esposito ML, Shah N, Dow S, Kang S, Paruchuri V, Karas RH, Kapur NK. Distinct effects of left or right atrial cannulation on left ventricular hemodynamics in a swine model of acute myocardial injury. *ASAIO J*. 2016;62:671–676. doi: [10.1097/MAT.0000000000000416](https://doi.org/10.1097/MAT.0000000000000416)
 12. Esposito ML, Zhang Y, Qiao X, Reyelt L, Paruchuri V, Schnitzler GR, Morine KJ, Annamalai SK, Bogins C, Natov PS, et al. Left ventricular unloading before reperfusion promotes functional recovery after acute myocardial infarction. *J Am Coll Cardiol*. 2018;72:501–514. doi: [10.1016/j.jacc.2018.05.034](https://doi.org/10.1016/j.jacc.2018.05.034)
 13. Brooks H, Holland R, Al-Sadir J. Right ventricular performance during ischemia: an anatomic and hemodynamic analysis. *Am J Physiol*. 1977;233:H505–H513. doi: [10.1152/ajpheart.1977.233.4.H505](https://doi.org/10.1152/ajpheart.1977.233.4.H505)
 14. Borow KM, Come PC, Neumann A, Baim DS, Braunwald E, Grossman W. Physiologic assessment of the inotropic, vasodilator and afterload reducing effects of milrinone in subjects without cardiac disease. *Am J Cardiol*. 1985;55:1204–1209. doi: [10.1016/0002-9149\(85\)90664-2](https://doi.org/10.1016/0002-9149(85)90664-2)
 15. Cools F, Dhuyvetter D, Vanlommel A, Janssens S, Borghys H, Geys H, Gallacher DJ. A translational assessment of preclinical versus clinical tools for the measurement of cardiac contractility: comparison of LV dP/dtmax with echocardiography in telemetry implanted beagle dogs. *J Pharmacol Toxicol Methods*. 2014;69:17–23. doi: [10.1016/j.vascn.2013.10.003](https://doi.org/10.1016/j.vascn.2013.10.003)
 16. Starr I, Jeffers WA, Meade RH. The absence of conspicuous increments of venous pressure after severe damage to the right ventricle of the dog, with a discussion of the relation between clinical congestive failure and heart disease. *Am Heart J*. 1943;26:291–301. doi: [10.1016/S0002-8703\(43\)90325-4](https://doi.org/10.1016/S0002-8703(43)90325-4)
 17. Laster SB, Shelton TJ, Barzilai B, Goldstein JA. Determinants of the recovery of right ventricular performance following experimental chronic right coronary artery occlusion. *Circulation*. 1993;88:696–708. doi: [10.1161/01.CIR.88.2.696](https://doi.org/10.1161/01.CIR.88.2.696)
 18. Masci PG, Francone M, Desmet W, Ganame J, Todiere G, Donato R, Siciliano V, Carbone I, Mangia M, Strata E, et al. Right ventricular ischemic injury in patients with acute ST-segment elevation myocardial infarction: characterization with cardiovascular magnetic resonance. *Circulation*. 2010;122:1405–1412. doi: [10.1161/CIRCULATIONAHA.110.940254](https://doi.org/10.1161/CIRCULATIONAHA.110.940254)
 19. Huttin O, Lemarié J, Di Meglio M, Girerd N, Mandry D, Moulin F, Lemoine S, Juillière Y, Felblinger J, Marie PY, et al. Assessment of right ventricular functional recovery after acute myocardial infarction by 2D speckle-tracking echocardiography. *Int J Cardiovasc Imaging*. 2015;31:537–545. doi: [10.1007/s10554-014-0585-7](https://doi.org/10.1007/s10554-014-0585-7)