

Recurrent pulmonary embolism related with Paget–Schroetter syndrome: a case report

Yuki Sahashi*, Junko Naito, and Masanori Kawasaki 

Division of Cardiovascular Medicine, Gifu University Hospital, 1-1 Yanagido, Gifu 501-1194, Japan

Received 28 December 2018; first decision 21 March 2019; accepted 21 June 2019; online publish-ahead-of-print 18 July 2019

Background

Paget–Schroetter syndrome (PSS) is an unusual cause of venous thromboembolism, which is frequently misdiagnosed and undiagnosed in clinical settings. Although axillary-subclavian vein thrombosis is related with PSS typically presents in healthy young athletes, it is possible for this phenomenon to occur in various age settings.

Case summary

We present a case of recurrent pulmonary embolism caused by a thrombus in dilated axillary vein related with PSS. A 74-year-old man was referred to our cardiology department for chest discomfort and hypoxaemia. The contrast computed tomography (CT) revealed that he suffered from bilateral pulmonary embolism. However, we could not find the source of embolism despite other examinations such as ultrasonography of the inferior limb deep vein. Three months later, the patient complained of dyspnoea for a second time, and a contrast CT scan was subsequently performed revealing a new pulmonary embolism. Surgical resection of the giant thrombus was performed, resulting in a good clinical course without recurrence.

Discussion

We experienced a case of recurring pulmonary embolism in a patient with undiagnosed PSS, which was related to the active and vigorous movement of the right arm during his working. Although there are various treatments for PSS including anticoagulation, first rib resection, and lifestyle modification, we need to consider what is the best treatment individually.

Keywords

Case report • Pulmonary embolism • Paget–Schroetter syndrome • Thrombosis

Learning points

- Upper extremity deep vein thrombosis should be considered as a source of pulmonary embolism, but can be undiagnosed or misdiagnosed.
- Not only young athletes but also old age athletes and workers have potential to be diagnosed with Paget–Schroetter syndrome.

Introduction

Upper extremity deep vein thrombosis (UEDVT) is known as a rare diagnosis and currently accounts for ~10% of all deep vein thrombosis (DVT) cases.¹ Paget–Schroetter Syndrome (PSS), also known as effort thrombosis, is an unusual, cause of UEDVT and has remained frequently undiagnosed or misdiagnosed. We report a case of PSS, resulting in recurrent pulmonary embolism.

* Corresponding author. Tel: +81 58 230 6523, Fax: +81 58 230 6524, Email: mourinho384@yahoo.co.jp

Handling Editor: Thomas Johnson

Peer-reviewer: A. John Camm

Compliance Editor: Mohammed Majid Akhtar

Supplementary Material Editor: Ross Thompson

© The Author(s) 2019. Published by Oxford University Press on behalf of the European Society of Cardiology.

This is an Open Access article distributed under the terms of the Creative Commons Attribution Non-Commercial License (<http://creativecommons.org/licenses/by-nc/4.0/>), which permits non-commercial re-use, distribution, and reproduction in any medium, provided the original work is properly cited. For commercial re-use, please contact journals.permissions@oup.com

Timeline

Day of admission	A 74-year-old male with no medical histories complained of chest discomfort. A contrast computed tomography (CT) scan revealed bilateral pulmonary embolism. However, the sources of the embolism could not be detected. Alteplase was administered to diminish the size of pulmonary artery thrombus.
During first admission (14 days)	Warfarin was prescribed during the admission period and all PT-INR values during admission were in the target range (PT-INR: 1.6–2.6).
After the discharge of the first admission	Warfarin was prescribed from our hospital. Medication adherence and warfarin-control was satisfactory.
Three months after the first admission	Despite a well-controlled PT-INR, recurrent bilateral pulmonary embolism was observed by contrast CT scan, as well as a giant thrombus located in the right axillary vein.
Second admission and operation	The giant thrombus was identified as the source of recurrent pulmonary embolism and resected surgically.
After surgery	During the follow-up period after surgery, the patient did not complain of any symptom and there was no recurrence of pulmonary embolism.

Case presentation

A 74-year-old man working as a car washer visited our cardiology department for chest discomfort and hypoxaemia. He had no previous medical history and was not taking any medications. On arrival, his temperature was 36.8°C, his blood pressure was 94/76 mmHg, his pulse rate was 117 beats/minute (regular rhythm), his respiratory rate was 24 breaths/minute, and his oxygen saturation was 89% on room air. Despite the presence of hypoxaemia and tachypnoea, we could not detect any other abnormal findings from his physical examination suggesting any disease related to hypoxaemia. Electrocardiogram on admission suggested right ventricular strain pattern with complete right bundle branch block and S1Q3T3 pattern. Echocardiography on admission revealed that remarkably enlarged right ventricular suppressed left ventricular contraction (Figure 1A). Hence a contrast CT scan was performed, revealing bilateral pulmonary embolisms to be the underlying cause of the symptom (Figure 1B). Despite other examinations, such as ultrasonography of the inferior limb deep vein, the source of the thrombosis could not be found. Laboratory findings revealed congenital coagulation

disorders, including protein C/S deficiency, anti-thrombin III deficiency, and anti-phospholipid antibody syndrome to be negative.

After admission, the patient was initially administered systemic thrombolytic therapy with alteplase (1,200,000 unit) and heparin. Contrast CT scan performed 7 days after admission revealed complete disappearance of the thromboembolisms and symptoms were mitigated as well.

Three months later, the patient was referred to our hospital because of recurring chest discomfort. Another contrast CT scan was performed, revealing a new pulmonary embolism despite continuous anticoagulation therapy with warfarin. PT-INR during treatment period was in the standard treatment range [PT-INR (1.6–2.6)] and PT-INR on second admission was 2.1. A giant thrombus (43 × 50 mm) located in the right axillary vein, which we could not find during previous hospitalization, was pointed out (Figure 1C). Vein angiography was also performed, revealing a giant thrombus with no collateral vessels. Since ultrasound echography showed sufficient blood flow around the thrombus, swelling, and pain of his right arm were not observed before the operation.

We were finally able to identify that the source of his recurrent pulmonary embolism was a giant thrombus located in the right dilated axillary vein. Eventually, the huge thrombus was removed surgically (Figure 1D), and the symptoms were subsequently alleviated. Anticoagulation with warfarin was continuously prescribed and chest discomfort completely resolved. The patient retired his job due to this experience and his old age, and reported no post-operative complication during 2 years after the operation.

Discussion

Upper extremity deep vein thrombosis is classified into primary UEDVT and secondary UEDVT; most cases of primary UEDVT are iatrogenic (inserting central venous catheter, pacemaker insertion, and parenteral nutrition) whereas secondary causes are often due to hypercoagulable state and surgeries involving the upper limbs.

Paget–Schroetter syndrome, also referred to as ‘effort thrombosis’, usually occurs in young athletes such as tennis players, judo players, and those who use their dominant hand and arm. Paget–Schroetter syndrome remains a relatively rare condition; it occurs at a rate of 2 per 100,000 people per year.² It is believed that active and sustained movements during sports lead to microtrauma of the endothelium and activation of the coagulation cascade. According to some reports, the anatomical abnormalities involving the thoracic outlet play an important role in the pathogenesis of making microtraumas of endothelium.^{3,4}

The anatomical abnormalities involving the thoracic outlet (cervical rib, congenital bands, hypertrophy of scalenus tendons, and abnormal insertion of the costoclavicular ligament) are important regarding the pathogenesis of effort thrombosis.^{5,6} The narrow costoclavicular space leads to continuous compression of the vein and restricts blood flow, especially when the arm is hyperabducted or externally rotated. Therefore, it is considered that PSS is sequela of thoracic outlet syndrome (TOS).

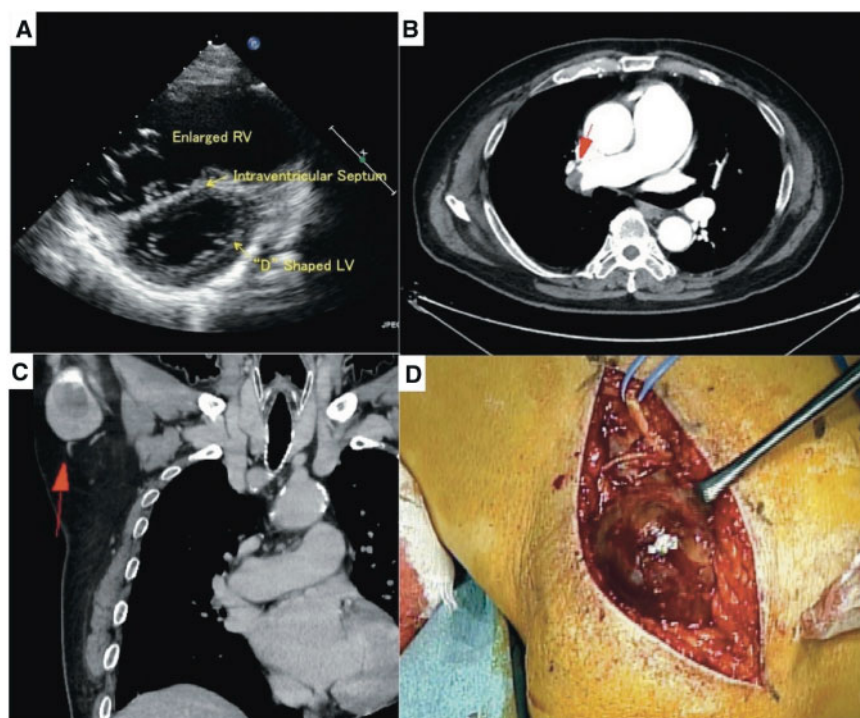


Figure 1 (A) Echocardiography on admission revealed that remarkably enlarged right ventricular suppressed left ventricular contraction. (B) Pulmonary embolism detected by contrast computed tomography scan on admission (arrow). (C) Huge thrombus located in the dilated right axillary vein (arrow). (D) Snap shot during surgery reveals that dark red thrombus existed inside the dilated vein.

Chronic compression of the vein leads to an inflammatory response in the soft tissues surrounding the vein and endothelial micro-trauma. The repetitive endothelial trauma results in intimal hyperplasia, inflammation, and eventually hypercoagulable state. In the present case, it can be considered that vigorous right arm abduction during car washing led to chronic compression of vein.

As there are only few reports mentioning thrombo-embolic pulmonary hypertension induced by UEDVT,⁷ the optimal therapeutic approach has not been well defined. However, since residual deep vein thrombosis will become the cause of recurrent pulmonary embolism, chronic thrombo-embolic pulmonary embolism, and disabling symptoms, aggressive treatment for both DVT and hypoxaemia are necessary. Some authors suggested that the surgical decompression of the thoracic outlet is a necessary part of the treatment since PSS is considered as a sequela of TOS. The removal of the first rib through a transaxillary approach is commonly performed.⁸ However, in the present case, recurrence of PSS was not observed during follow-up period without a surgical decompression of the thoracic outlet.

Conclusion

We reported the case of undiagnosed and repeated pulmonary embolism related with PSS. Not only lower extremity but also upper extremity vein should be considered as the source of embolism of pulmonary embolism.

Lead author biography



Dr Yuki Sahashi began his clinical carrier as a resident doctor at Ichinomiya Municipal hospital in March 2014. After finishing the resident program, he moved to Gifu University Hospital as cardiovascular fellow in 2016. He was awarded

some congress awards, including the Best English Resident Presenter of Japan Cardiovascular Society in 2016, Young Investigator Award of Tokai regional Cardiovascular Interventional Therapeutics in 2018. His clinical interest varies from intravascular imaging, clinical arrhythmia, and education.

Supplementary material

[Supplementary material](#) is available at *European Heart Journal - Case Reports* online.

Slide sets: A fully edited slide set detailing this case and suitable for local presentation is available online as [Supplementary data](#).

Consent: The authors confirm that written consent for submission and publication of this case report including image(s) and associated text has been obtained from the patient in line with COPE guidance.

Conflict of interest: none declared.

References

1. Ijaopo R, Oguntolu V, DCosta D, Garnham A, Hobbs S. A case of Paget-Schroetter syndrome (PSS) in a young judo tutor: a case report. *J Med Case Rep* 2016;**10**:63.
2. Lucia C, Craig PH, Jackson S. Diagnosis of Paget-Schroetter syndrome/primary effort thrombosis in a recreational weight lifter. *Phys Ther* 2017;**97**:13–19.
3. Alla V, Natarajan N, Kaushik M, Warriar R, Nair CK. Paget-Schroetter syndrome: review of pathogenesis and treatment of effort thrombosis. *West J Emerg Med* 2010;**11**:358–362.
4. Illig KA, Doyle AJ. A comprehensive review of Paget-Schroetter syndrome. *J Vasc Surg* 2010;**51**:1538–1547.
5. Zell L, Kindermann W, Marschall F, Scheffler P, Gross J, Buchter A. Paget-Schroetter syndrome in sports activities—case study and literature review. *Angiology* 2001;**52**:337–342.
6. Urschel HC Jr, Patel AN. Surgery remains the most effective treatment for Paget-Schroetter syndrome: 50 years' experience. *Ann Thorac Surg* 2008;**86**:254–260.
7. Isaka N, Yamada N, Araki S, Onishi K, Motoyasu M, Okinaka T, Ito M, Nakano T. Multiple pulmonary emboli with pulmonary hypertension caused by effort thrombosis and effective balloon venoplasty of the subclavian vein. *Jpn Circ J* 2001;**65**:920–922.
8. Rutherford RB. Primary subclavian-axillary vein thrombosis: the relative roles of thrombolysis, percutaneous angioplasty, stents, and surgery. *Semin Vasc Surg* 1998;**11**:91–95.