

## Visceral Debranching Thoracic Endovascular Aneurysm Repair for Chronic Dissecting Thoracoabdominal Aortic Aneurysm

Kwang Jo Cho, M.D., Jong Yoon Park, M.D.

Type II chronic dissecting thoracoabdominal aortic aneurysms are a surgically challenging disease. The conventional thoracoabdominal aortic aneurysm repair technique using cardiopulmonary bypass is a high-risk procedure. However, a recently developed endovascular technique may be an alternative treatment for the disease, but faces the obstacle of lesional restriction. This new technique uses a hybrid strategy to overcome the limits of endovascular thoracoabdominal aortic aneurysm repair. Herein, we report on a successful outcome after performing the hybrid visceral debranching procedure.

Key words: 1. Aortic dissection  
2. Endovascular stent

### CASE REPORT

A 66-year-old man presented complaining of a dull chest pain and dysphagia. He had been diagnosed with a type II chronic dissecting thoracoabdominal aortic aneurysm. Seven years prior, the patient underwent a hemiarch descending aortic replacement with a right subclavian artery bypass due to a ruptured acute type B aortic dissection with anomalous origin of the right subclavian artery from the descending aorta. After the operation, the patient was followed regularly at the outpatient clinic and developed a distal aortic aneurysm from the end of the arch graft to both iliac arteries with a maximal diameter of 6.5 cm at the diaphragm level, which caused the symptom of dysphagia (Fig. 1). We planned to perform a staged debranching endovascular stent-graft repair of the total remaining aorta including both common iliac arteries.

The first operation was the visceral debranching procedure.

Through a midline abdominal incision, the abdominal aorta and its main branches were dissected and exposed, including both iliac arteries, both renal arteries, the superior mesenteric artery, and the celiac trunk. They were replaced with a custom-designed graft made of a 14×7 mm and a 16×8 mm Dacron Y graft (Intervascular, La Ciotat, France) (Fig. 2A). The proximal abdominal aortic anastomosis was made at the true lumen of the infrarenal abdominal aorta after obliterating the pseudolumen, and the other branches were anastomosed end-to-end separately. The total operation time was seven hours and fifteen minutes, and the patient remained in the intensive care unit for four days. The total transfusion required was 17 units of packed cells, 11 units of fresh frozen plasma, and 20 units of platelets.

Two weeks after the first operation, an endovascular procedure was performed. Under local anesthesia, a bilateral inguinal incision was made and the common femoral arteries were exposed. Three differently sized stent grafts were placed

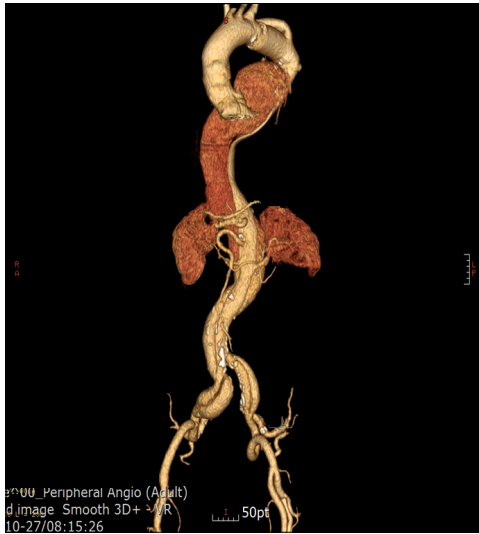Department of Thoracic and Cardiovascular Surgery, Dong-A University College of Medicine

Received: October 7, 2013, Revised: January 1, 2014, Accepted: January 3, 2014, Published online: December 5, 2014

Corresponding author: Kwang Jo Cho, Department of Thoracic and Cardiovascular Surgery, Dong-A University College of Medicine, 32 Daesingongwon-ro, Seo-gu, Busan 602-714, Korea  
(Tel) 82-51-240-2879 (Fax) 82-51-240-2879 (E-mail) kwangjocho@gmail.com

© The Korean Society for Thoracic and Cardiovascular Surgery. 2014. All right reserved.

© This is an open access article distributed under the terms of the Creative Commons Attribution Non-Commercial License (<http://creativecommons.org/licenses/by-nc/3.0>) which permits unrestricted non-commercial use, distribution, and reproduction in any medium, provided the original work is properly cited.



**Fig. 1.** The preoperative angiogram. From the anastomosis at the proximal descending aorta, the aortic dissection was enlarged to include both common iliac arteries.

in the true lumen of the dissected remnant of the thoracoabdominal aorta. The first stent graft was a 40×36 mm tapered monobody with a length of 20 cm, which was inserted into the proximal descending aorta covering the distal anastomosis of the previous aortic arch graft. The second stent graft was a 36×26 mm tapered monobody with a length of 16 cm, which was inserted into the first stent graft with an overlap of 4 cm. Finally, the third stent graft, a 26 mm monobody with a length of 16 cm, was inserted distally to cover the graft of the abdominal aorta. All stent grafts were inserted into the true lumen of the dissecting thoracoabdominal aorta and they covered approximately 40 cm of the length of the aorta.

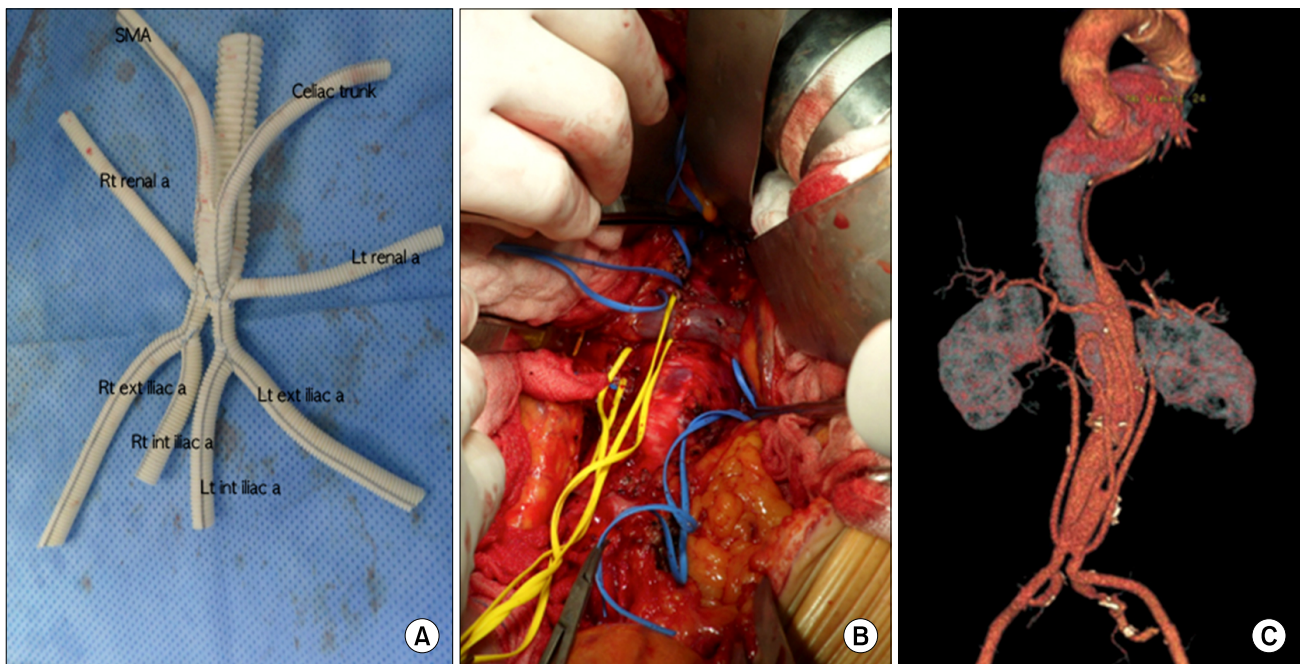
Fourteen days after these procedures, the patient was discharged without any complications. There was a small type II endoleak from the intercostal artery on the immediate postoperative computed tomography (CT) angiography, but subsided by the follow-up CT two months later. The following CT angiography nine months after the operation showed a decreasing aneurysm size without any other abnormal findings (Fig. 3). The patient was followed for one year and ten months and no other problem developed during that period.

## DISCUSSION

Most patients with an untreated thoracoabdominal aortic aneurysm end up dying from its rupture, and mortality risk increases with age. The conventional thoracoabdominal aortic aneurysm repair procedure is a high-risk operation, involving thoracoabdominal exposure, single-lung ventilation, and either partial cardiopulmonary bypass with aortic cross-clamp or full cardiopulmonary bypass with deep hypothermic circulatory arrest. Only a few large-volume surgical centers have reported satisfactory results with such a procedure. A study analyzing 1,010 cases of open thoracoabdominal aortic aneurysm repair performed in low-volume centers (fewer than fifteen cases per year) between 1991 and 2002 found that for elective procedures, the 30-day mortality was 19% and the mortality increased to 31% at one year postoperative [1]. Mortality risk was shown to increase with age, the number of comorbidities, and more extensive aortic involvement.

Recently, endovascular aneurysm repair has been used more frequently for risky thoracoabdominal aortic aneurysms, but this approach is restricted by anatomic limits such as the need to establish a safe landing zone without covering the critical end arteries. To overcome these limits, a hybrid strategy has been developed that involves the extra-anatomic bypass of the visceral vessels (a debranching procedure) with either concurrent or staged exclusion of the aneurysm using endovascular devices (such procedures are known as thoracic endovascular aneurysm repair). This hybrid strategy has the advantage of avoiding the thoracic incision, cardiopulmonary bypass, and aortic cross clamp, thereby potentially decreasing postoperative pain and pulmonary complications, intraoperative hemodynamic changes, and bleeding and organ ischemia involving the spinal cord. During the procedure, the spinal cord collaterals may be perfused in a pulsatile manner, which may protect the spinal cord by opening collateral flow.

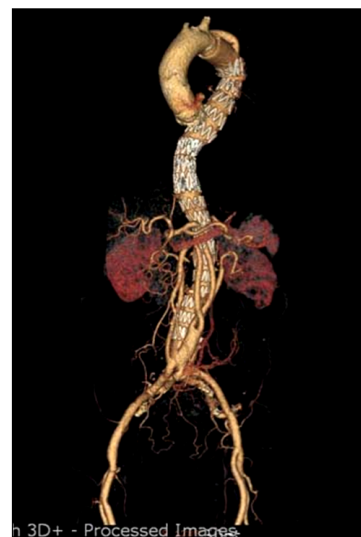The staged approach is preferred in elective patients to reduce the debranching operation time, transfusion amount, and rates of complications such as respiratory insufficiency and neurologic complications [2]. However, this approach may increase the risk of aneurysm rupture during the waiting period for the second procedure. In our case, the debranching procedure was very tedious, requiring multiple long anastomoses



**Fig. 2.** (A) The custom-designed graft made of two Y grafts. There were eight branches to be connected to the visceral branches of the abdominal aorta. For both renal arteries, the 7 mm limbs of a 14×7 mm Y graft was anastomosed to the side of the trunk of a 16×8 mm Y graft; for the SMA and the celiac trunk, a 14×7 mm Y graft was connected to the front of the trunk of the 16×8 mm Y graft; and for both internal iliac arteries, the 8 mm limb of a 16×8 mm Y graft was connected to the medial side of both limbs of the 16×8 mm Y graft. (B) The exposed abdominal aorta with its visceral branches that were encircled with rubber trips. (C) The angiogram after the visceral debranching procedure, which shows the replaced graft with good perfusion. SMA, superior mesenteric artery; Rt, right; Lt, left.

and the endoscopic procedure was not simple, so we chose the staged approach. Case reports have indicated that the design of the debranching graft may vary widely. The design of the graft used in this case was our original design (Fig. 2A); the branches were all separated and well fitted anatomically without any postoperative perfusion problems (Fig. 3).

So far, few hybrid thoracoabdominal aortic aneurysm repair procedures have been reported. Reported debranching techniques are quite diverse and have been mostly applied to high-risk patients such as those who are older, have comorbidities from heart, lung, or kidney disease, and have undergone prior open chest surgery. The hybrid repair strategy avoids repeating chest exposure and lung injury. In our case, the patient had already undergone an open thoracotomy to replace the proximal descending aorta, so we were concerned about the potential of subsequent lung injury and/or respiratory difficulty after reopening the adherent left thorax. Existing aortic grafts generally provide excellent landing



**Fig. 3.** The final computed tomography angiogram nine months after the operation. The entire enlarged pseudolumen of the aortic dissection had completely subsided. There was no endoleak and no restriction of perfusion.

zones, which was the case for our patient: the proximal descending aortic graft from the previous operation and the abdominal aortic graft from the debranching procedure provided an excellent landing zone. In most studies of the hybrid repair strategy, the debranching operation was a variable procedure involving inflow from the iliac arteries, abdominal aorta, or a previous abdominal graft. According to the preliminary results from the North American Complex Abdominal Aortic Debranching Registry [3], which includes 163 thoracoabdominal aortic aneurysms (6% type I, 25% type II, 31% type III, and 31% type IV), a total of 659 visceral arteries were debranched. The inflow was based on the iliac arteries in 63% of cases, the aorta or an aortic graft in 29% of cases, and a hepatic/splenic artery in 8% of cases. The extent of visceral reconstruction included one or two vessels in 28% of cases and three or four vessels in 72% of cases. The 30-day or in-hospital mortality rate for hybrid thoracoabdominal aortic aneurysm repair was 16% [3].

However, the hybrid strategy has its limitations. The visceral debranching operation is not a simple procedure because a meticulous approach to the abdominal visceral branches with extensive dissection in multiple abdominal areas and careful design of the grafts without kinking or redundancy to prevent organ malperfusion are required. This results in a prolonged procedure time. Multiple anastomoses cause extensive bleeding and may require multiple transfusions. In our case, we did experience a prolonged operation time and an increased amount of transfusions due to multiple anastomoses. Eventually, our patient required four days of intensive care.

The question of whether hybrid thoracoabdominal aortic

aneurysm repair leads to improved outcomes compared to conventional thoracoabdominal aortic aneurysm repair is still controversial, and the issue requires larger studies and long-term follow-up [4]. This hybrid procedure does not replace conventional repair strategies, but may provide alternative options for high-risk patients who might otherwise be denied therapy for a potentially fatal aortic rupture.

## CONFLICT OF INTEREST

No potential conflict of interest relevant to this article was reported.

## REFERENCES

1. Rigberg DA, McGory ML, Zingmond DS, et al. *Thirty-day mortality statistics underestimate the risk of repair of thoracoabdominal aortic aneurysms: a statewide experience.* J Vasc Surg 2006;43:217-22.
2. Hughes GC, Andersen ND, Hanna JM, McCann RL. *Thoracoabdominal aortic aneurysm: hybrid repair outcomes.* Ann Cardiothorac Surg 2012;1:311-9.
3. Oderich GS, Gloviczki P, Farber M, et al. *Abdominal debranching with aortic stent grafts for complex aortic aneurysms: preliminary results of the North American Complex Abdominal Aortic Debranching (NACAAD) Registry.* Proceedings of the Society for Vascular Surgery meeting; 2011 Jun 15-18; Chicago, USA. Smithtown (NY): International Society for Vascular Surgery; 2011.
4. Chiesa R, Tshomba Y, Melissano G, et al. *Hybrid approach to thoracoabdominal aortic aneurysms in patients with prior aortic surgery.* J Vasc Surg 2007;45:1128-35.