

Contents lists available at [ScienceDirect](https://www.sciencedirect.com)

## American Journal of Ophthalmology Case Reports

journal homepage: [www.ajocasereports.com/](http://www.ajocasereports.com/)

## Minimally invasive, indirect corneal neurotization using an ipsilateral sural nerve graft for early neurotrophic keratopathy

Brendon W.H. Lee<sup>a,b,c</sup>, Muhammad A. Khan<sup>a</sup>, Quan D. Ngo<sup>a</sup>, Krishna Tumuluri<sup>b</sup>,  
Chameen Samarawickrama<sup>a,b,c,\*</sup>

<sup>a</sup> Faculty of Medicine, University of New South Wales, Sydney, Australia

<sup>b</sup> Sydney Medical School, University of Sydney, Sydney, Australia

<sup>c</sup> Westmead Institute of Medical Research, Sydney, Australia

## ARTICLE INFO

## Keywords:

Neurotrophic keratopathy  
Corneal neurotization  
Sural nerve autograft  
Corneal sensation  
In vivo confocal microscopy

## ABSTRACT

**Purpose:** Neurotrophic keratopathy is a degenerative disease characterized by damage to the corneal nerves leading to corneal hypoesthesia and anaesthesia. The resultant progressive visual deterioration is refractory to existing conventional treatment options. Corneal neurotization is a novel and effective surgical procedure that directly targets the underlying pathology of nerve loss by stimulating new corneal nerve growth. This study reports the outcomes and the pre- and postoperative in vivo confocal microscopy findings of the first published Australian case of indirect, minimally invasive, corneal neurotization using an ipsilateral sural nerve autograft. **Observations:** An 11-year-old boy developed corneal hypoesthesia in the left eye following surgical debulking of a cerebellopontine angle arachnoid cyst. He was diagnosed with Mackie Stage 1 neurotrophic keratopathy. Due to his hypoesthesia, he had developed recurrent microbial keratitis and corneal ulceration secondary to foreign bodies sustained during contact sports. At presentation, he reported photophobia and dry eye symptoms, corrected-distance visual acuity was 6/18, Cochet-Bonnet aesthesiometer demonstrated reduced corneal sensation (5–15mm), Schirmer's I test was 15mm, and in vivo confocal microscopy showed a complete absence of a subepithelial corneal plexus. He underwent indirect, minimally invasive, corneal neurotization using the ipsilateral supratrochlear nerve and a sural nerve autograft. Subjective improvement in corneal sensation was noticed by the patient at 2 months. Objective improvement, measured on Cochet-Bonnet aesthesiometer, was first observed at 6 months with steady stepwise improvement to 20–35mm at 21 months. Importantly, due to the increase in corneal sensation, the patient did not develop any further corneal complications. At 12 months, dry eye symptoms resolved and Schirmer's I test improved to 30mm. At 15 months, corrected-distance visual acuity improved to 6/5 and in vivo confocal microscopy demonstrated evidence of corneal reinnervation with nerves running through the subepithelial space surrounded by healthy and active keratocytes. **Conclusions and importance:** Corneal neurotization represents an exciting development in the armamentarium for the treatment of neurotrophic keratopathy and can be considered for younger patients with early-stage disease.

### 1. Introduction

Corneal neurotization represents a novel and effective surgical procedure that targets the underlying neuropathology of neurotrophic keratopathy. Neurotrophic keratopathy is a degenerative disease characterized by damage to the corneal nerves leading to corneal hypoesthesia and anaesthesia.<sup>1</sup> This loss of corneal sensation and trophic support for the corneal epithelium results in progressive visual deterioration refractory to conventional treatment options. Corneal

neurotization has been increasingly used in early-stage neurotrophic keratopathy and can restore the protective corneal sensation and nerve-derived trophic support by inducing corneal nerve reinnervation from nearby nerves transferred to the perilimbal region.<sup>2–5</sup> Several surgical techniques using an intact donor sensory nerve, indirect interpositional nerve graft (autograft or allograft), on the ipsilateral or contralateral side have been described.<sup>6</sup>

This study reports the outcomes of the first published Australian case of indirect, minimally invasive, corneal neurotization using an

\* Corresponding author. Westmead Institute of Medical Research, Sydney, Australia.

E-mail address: [chameen.sams@sydney.edu.au](mailto:chameen.sams@sydney.edu.au) (C. Samarawickrama).

<https://doi.org/10.1016/j.ajoc.2022.101585>

Received 24 June 2021; Received in revised form 10 May 2022; Accepted 11 May 2022

Available online 20 May 2022

2451-9936/© 2022 The Authors. Published by Elsevier Inc. This is an open access article under the CC BY-NC-ND license (<http://creativecommons.org/licenses/by-nc-nd/4.0/>).

ipsilateral sural nerve autograft. A surgical video of the procedure, clinical outcomes, and pre- and postoperative in vivo confocal microscopy findings are provided.

## 2. Case report

An 11-year-old male developed corneal hypoesthesia in the left eye following surgical debulking of a cerebellopontine angle arachnoid cyst 2 years prior. He had a congenital left ptosis of 3–4mm with 4mm of levator function which had been refractory to an upper lid brow suspension at age 4 and silicone brow suspension at age 6. The other branches of the ipsilateral and contralateral trigeminal nerve were functional on preoperative sensory testing (Semmes-Weinstein monofilament). The patient was passionate about contact sports but was unable to adequately protect his left eye due to the corneal hypoesthesia. He was commenced on an intensive artificial tear regime but despite this, he developed recurrent microbial keratitis and corneal ulceration secondary to foreign bodies. At presentation, he reported photophobia and dry eye symptoms. Corrected-distance visual acuity was 6/18 in the affected left eye, and 6/4 in the right. Slit-lamp examination demonstrated an adequate tear lake and marked punctate epithelial erosions in the left eye consistent with Mackie Stage 1 neurotrophic keratopathy. There were no corneal opacities or scars observed. A Cochet-Bonnet aesthesiometer demonstrated reduced corneal sensation in the left cornea (5mm centrally, superiorly, nasally, temporally; 15mm inferiorly), compared to the right (60mm centrally and in all four quadrants), and Schirmer's I was 15mm compared to 25mm, respectively. Preoperative in vivo confocal microscopy demonstrated complete absence of a subepithelial corneal plexus in the affected eye (Fig. 1A).

To reduce the risk of further complications, and in view of the patient's insistence on continuing his passion for sport, the patient underwent elective ipsilateral indirect corneal neurotization using a sural nerve autograft. Under general anaesthesia, the ipsilateral supra-trochlear nerve was exposed using a 20mm medial infra-brow incision. A left sural nerve graft measuring 75mm in length was harvested. The sural nerve was split lengthwise into two halves, with half harvested. A blepharotomy incision was then performed through the medial left upper eyelid, and the distal sural nerve stump delivered to the superior perilimbal space through sub-Tenon's space using a Wright needle, which passed smoothly. The distal sural nerve epineurium was then dissected, and the fascicles separated and secured within 400- $\mu$ m depth scleral tunnels, created with a 400- $\mu$ m ophthalmic Feather® blade, using

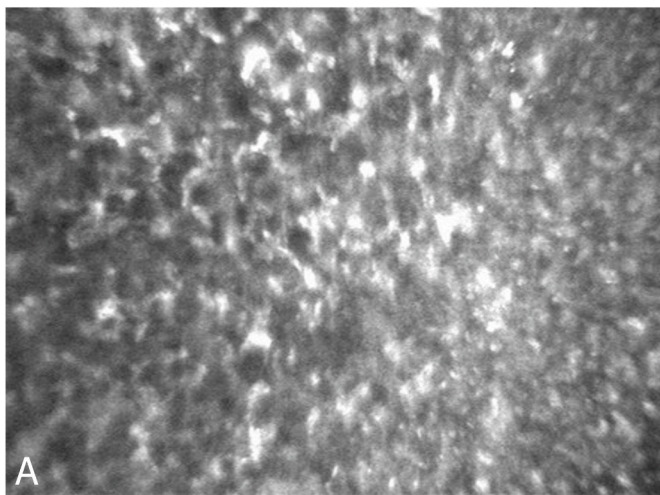
10–0 vicryl sutures. Concurrently, forced duction testing was completed to assess tethering of the globe. Finally, the nerve graft was anastomosed end-to-end with the supratrochlear nerve using 10–0 nylon and fibrin glue (Tisseel, Baxter). A temporary tarsorrhaphy and eye patching was completed for protection; the patch was removed the following day, and the tarsorrhaphy at 2 weeks. An edited video of the procedure is included (Supplementary Material 1).

No surgical complications relating to the eye or sural nerve harvest occurred postoperatively. The patient developed general-anaesthesia-induced priapism on day 1 which required insertion of a shunt. Regular chloramphenicol and dexamethasone eye drops were prescribed. The patient was reviewed at 2, 6, 9, 12, 15, and 21 months postoperatively. The perilimbal corneal, upper lid, infra-brow and sural nerve site incisions all healed with excellent cosmesis. At 2 months, there was subjective improvement in corneal sensation. For the first time, the patient was able to detect a "cold, wet liquid" sensation on administration of lubricating drops. Objective improvement in corneal sensation was first observed at 6 months, with steady stepwise improvement at 15 months (10mm centrally; 15mm inferiorly; 20mm superiorly; 25mm temporally; 35mm nasally). The central corneal sensation improved to 20mm at 21 months. Dry eye symptoms and corneal punctate changes resolved, with Schirmer's I improving to 30mm by 12 months. At 15 months, corrected-distance visual acuity improved to 6/5 with subjective refraction of  $-0.25/+5.00 \times 100$ , and in vivo confocal microscopy demonstrated evidence of corneal reinnervation with a nerve fiber running through the subepithelial space surrounded by healthy and active keratocytes (Fig. 1B). Due to the increase in corneal sensation, the patient did not develop any further episodes of corneal ulceration or keratitis during follow up.

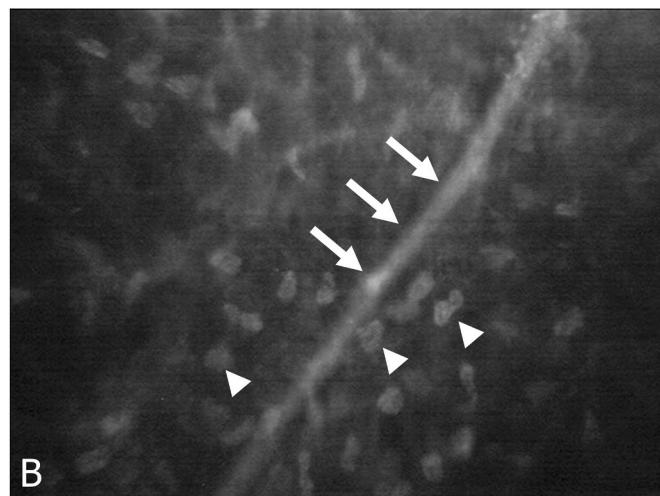
## 3. Discussion

Corneal sensation is supplied by the ophthalmic division of the trigeminal nerve, and therefore, neurotrophic keratopathy can arise from several etiologies that cause disruption along the pathway from the trigeminal nucleus to the terminal corneal nerve fibres.<sup>7</sup> Management of neurotrophic keratopathy remains challenging and while conventional treatment options may slow progression and promote healing, they do not address the underlying pathology of the damaged trigeminal nerve. Thus, loss of sensation and visual deterioration often persists.

Corneal neurotization represents a novel and effective surgical



**Fig. 1a.** Preoperative in vivo confocal microscopy of the left eye affected by neurotrophic keratopathy demonstrating complete absence of a subepithelial corneal plexus or nerve fibers within the subepithelial space (Confoscan4, NIDEK technologies, Fremont, CA).



**Fig. 1b.** Postoperative in vivo confocal microscopy of the left affected eye, 15 months after indirect corneal neurotization, demonstrating corneal reinnervation with a nerve fiber running through the subepithelial space (arrows) surrounded by healthy and active keratocytes (arrowheads) (Confoscan4, NIDEK technologies, Fremont, CA).

treatment for neurotrophic keratopathy and is the only treatment that addresses the underlying neuropathology by inducing reinnervation of the cornea.<sup>2,3</sup> Performing corneal neurotization in early-stage neurotrophic keratopathy in younger patients, before irreversible corneal scarring or amblyopia has occurred, has been advocated by some authors in order to facilitate better final visual outcomes.<sup>3</sup> Similar to our case, corneal neurotization has been successfully used in early neurotrophic keratopathy in young patients.<sup>4,5</sup> Undertaking this procedure earlier provides advantages such as a faster rate and more complete recovery of visual acuity and reestablishment of corneal sensation, especially in patients under 18 years of age.<sup>3</sup> The clinical rationale of performing corneal neurotization in our patient was to reinnervate the cornea to protect against further corneal complications and to improve his visual acuity to facilitate driving in the near future. The patient's younger age and early-stage disease, protection of the upper cornea by ptosis, relative preservation of corneal sensation in the inferior cornea, and stepwise improvement in corneal sensation after corneal neurotization likely all contributed to the visual outcome.

Several neurotization techniques have been described including direct and indirect methods, with both demonstrating significant improvement in corneal sensation and visual acuity.<sup>3,7,8</sup> The original direct corneal neurotization techniques did not require the sacrifice of a secondary nerve graft which reduced the donor-site morbidity.<sup>9</sup> However, these utilized larger incisions and often required extension dissection of the primary nerve, necessitating prolonged operating time and risk of scarring, postoperative hematoma, and alopecia.<sup>10</sup> In comparison, indirect corneal neurotization can effectively restore sensation in cases of bilateral corneal anaesthesia or unilateral neurotrophic keratopathy where the contralateral nerves do not have intact sensation. Disadvantages include possible damage to the donor or nerve graft during harvesting or coaptation and reliance on successful axonal regeneration at the coaptation site. Importantly, there appears to be no significant difference between direct or indirect methods in outcomes measures, and the choice of surgical technique should be based on patient factors, surgical experience, or available technologies.<sup>6,7</sup> We utilized an indirect, minimally invasive approach with a sural nerve autograft, which has been demonstrated to be non-inferior to direct surgical approaches. These endoscopic or minimally invasive techniques are favored due to the benefits of decreased anaesthesia duration, amount of scarring due to smaller incisions, and hospital costs.<sup>11</sup> Limitations include a steeper learning curve, need for specialized equipment, and a greater nerve length required in endoscopic procedures to reach the contralateral eye.<sup>8</sup>

The literature reports that *in vivo* confocal microscopy performed preoperatively in eyes with neurotrophic keratopathy showed severe deficiency in the sub-basal nerve plexus, corneal epithelium and stroma, and the corneal endothelium. Whereas postoperative *in vivo* confocal microscopy demonstrated substantial improvement in corneal nerve parameters (fiber area, width, density and length, fractal dimension), as early as 3 months, which eventually reached levels comparable to healthy contralateral eyes.<sup>5,7,8</sup> Our case is consistent with the literature and shows the presence of, previously absent, subepithelial corneal nerve fibers and keratocytes following corneal neurotization. The exact mechanism of reinnervation is yet to be elucidated but it has been proposed to occur secondary to paracrine support provided by the release of neurotrophic factors stimulated by the perilimbal nerve fascicles.<sup>12</sup> Reinnervation may also occur secondary to direct axonal sprouting from the transposed nerve graft fascicles into the cornea.<sup>10</sup>

Furthermore, visual rehabilitative procedures like keratoplasty surgery have been successfully performed following corneal neurotization with visual acuity remaining stable or improving with complete re-epithelization by 4–12 weeks after surgery and return of corneal sensation to pre-keratoplasty levels by 6–12 months.<sup>6,8</sup> Keratoplasty surgeries are typically performed 1–2 years after the original corneal neurotization procedure to allow for substantial corneal reinnervation and establishment of corneal sensation. The potential for visual

rehabilitation post corneal neurotization provides further support for considering this procedure on younger patients.

#### 4. Conclusions

In summary, the recent advances in corneal neurotization present an exciting development in the armamentarium for neurotrophic keratopathy. Without this definitive treatment, corneal anaesthesia is a lifelong problem with only symptomatic treatment, with significant implications on quality of life and vision. To the best of our knowledge, we report the first published case of corneal neurotization performed in Australia using an indirect minimally invasive sural nerve graft technique with successful restoration of corneal sensation, ocular surface parameters, and reinnervation demonstrated on *in vivo* confocal microscopy.

#### Patient consent

The patient's legal guardians provided written consent to the publication of the case, images, and surgical procedure video.

#### Funding

No funding sources for this work.

#### Conflicts of interest

The following authors have no financial disclosures: BWHL, QDN, KT, MK, CS.

#### Authorship

All authors attest that they meet the current ICMJE criteria for Authorship.

#### Intellectual property

We confirm that we have given due consideration to the protection of intellectual property associated with this work and that there are no impediments to publication, including the timing of publication, with respect to intellectual property. In so doing we confirm that we have followed the regulations of our institutions concerning intellectual property.

#### Research ethics

We further confirm that any aspect of the work covered in this manuscript that has involved human patients has been conducted with the ethical approval of all relevant bodies and that such approvals are acknowledged within the manuscript.

IRB approval was obtained (required for studies and series of 3 or more cases).

Written consent to publish potentially identifying information, such as details or the case and photographs, was obtained from the patient(s) or their legal guardian(s).

#### Contact with the editorial office

The Corresponding Author declared on the title page of the manuscript is:

This author submitted this manuscript using his/her account in EVIDE.

We understand that this Corresponding Author is the sole contact for the Editorial process (including EVIDE and direct communications with the office). He/she is responsible for communicating with the other authors about progress, submissions of revisions and final approval of proofs.

We confirm that the email address shown below is accessible by the Corresponding Author, is the address to which Corresponding Author's EVISE account is linked, and has been configured to accept email from the editorial office of American Journal of Ophthalmology Case Reports:

Someone other than the Corresponding Author declared above submitted this manuscript from his/her account in EVISE:

We understand that this author is the sole contact for the Editorial process (including EVISE and direct communications with the office). He/she is responsible for communicating with the other authors, including the Corresponding Author, about progress, submissions of revisions and final approval of proofs.

We the undersigned agree with all of the above.

### Acknowledgements

The patient's legal guardians who consented to the publication of this case.

### Appendix A. Supplementary data

Supplementary data related to this article can be found at <https://doi.org/10.1016/j.ajoc.2022.101585>.

### References

1. Dua HS, Said DG, Messmer EM, et al. Neurotrophic keratopathy. *Prog Retin Eye Res.* 2018;66:107–131.
2. Malhotra R, Elalfy MS, Kannan R, Nduka C, Hamada S. Update on corneal neurotisation. *Br J Ophthalmol.* 2019;103:26–35.
3. Park JK, Charlson ES, Leyngold I, Kossler AL. Corneal neurotization: a review of pathophysiology and outcomes. *Ophthalmic Plast Reconstr Surg.* 2020;36:431–437.
4. Sepehrpour S, Lloyd MS, Nishikawa H, Richard B, Parulekar M. Surrogate outcome measures for corneal neurotization in infants and children. *J Craniofac Surg.* 2017; 28:1167–1170.
5. Fung SSM, Catapano J, Elbaz U, Zuker RM, Borschel GH, Ali A. Vivo confocal microscopy reveals corneal reinnervation after treatment of neurotrophic keratopathy with corneal neurotization. *Cornea.* 2018;37:109–112.
6. Liu CY, Arteaga AC, Fung SE, Cortina MS, Leyngold IM, Aakalu VK. Corneal neurotization for neurotrophic keratopathy: review of surgical techniques and outcomes. *Ocul Surf.* 2021;20:163–172.
7. Fogagnolo P, Giannaccare G, Bolognesi F, et al. Direct versus indirect corneal neurotization for the treatment of neurotrophic keratopathy: a multicenter prospective comparative study. *Am J Ophthalmol.* 2020;220:203–214.
8. Catapano J, Fung SSM, Halliday W, et al. Treatment of neurotrophic keratopathy with minimally invasive corneal neurotisation: long-term clinical outcomes and evidence of corneal reinnervation. *Br J Ophthalmol.* 2019;103:1724–1731.
9. Terzis JK, Dryer MM, Bodner BL. Corneal neurotization: a novel solution to neurotrophic keratopathy. *Plast Reconstr Surg.* 2009;123:112–120.
10. Elbaz U, Bains R, Zuker RM, Borschel GH, Ali A. Restoration of corneal sensation with regional nerve transfers and nerve grafts: a new approach to a difficult problem. *JAMA Ophthalmol.* 2014;132:1289–1295.
11. Wolkow N, Habib LA, Yoon MK, Freitag SK. Corneal neurotization: review of a new surgical approach and its developments. *Semin Ophthalmol.* 2019;34:473–487.
12. Ting DSJ, Figueiredo GS, Henein C, et al. Corneal neurotization for neurotrophic keratopathy: clinical outcomes and in vivo confocal microscopic and histopathological findings. *Cornea.* 2018;37:641–646.