







Original Article



Evaluation of infertility efficacy of the *E. coli* expressed STF2-GnRH vaccine in male cats

Yong Jae Lee ¹, Eun Jung Jo ¹, Hye Won Lee ¹, Bo Ram Hwang¹,
Yong Hyun Kim², Byoung Joo Park², Yoon Ju Cho ³, Young Ah Lee ⁴,
In Soo Choi², Jin Soo Han ^{1*}

¹Department of Laboratory Animal Medicine, College of Veterinary Medicine, Konkuk University, Seoul 05029, Korea

²Department of Infectious Diseases, College of Veterinary Medicine, Konkuk University, Seoul 05029, Korea

³Department of Pet Science, Seojeong College University, Yangju 11429, Korea

⁴Department of Animal Sciences, Shingu College, Seongnam 13174, Korea



Received: Nov 20, 2018

Revised: Apr 20, 2019

Accepted: May 2, 2019

*Corresponding author:

Jin Soo Han

Department of Laboratory Animal Medicine,
College of Veterinary Medicine, Konkuk
University, 120 Neungdong-ro, Gwangjin-gu,
Seoul 05029, Korea.

E-mail: labvet@konkuk.ac.kr


© 2019 The Korean Society of Veterinary
Science

This is an Open Access article distributed
under the terms of the Creative Commons
Attribution Non-Commercial License (<https://creativecommons.org/licenses/by-nc/4.0>)
which permits unrestricted non-commercial
use, distribution, and reproduction in any
medium, provided the original work is properly
cited.


ORCID iDs

Yong Jae Lee 


<https://orcid.org/0000-0002-9000-9927>

Eun Jung Jo 


<https://orcid.org/0000-0001-6749-4314>

Hye Won Lee 


<https://orcid.org/0000-0001-5619-085X>

Yoon Ju Cho 

<https://orcid.org/0000-0002-4875-0906>

Young Ah Lee 

<https://orcid.org/0000-0001-8464-2075>

Jin Soo Han 

<https://orcid.org/0000-0003-2136-1932>

ABSTRACT

Gonadotropin-releasing hormone (GnRH) is secreted from the hypothalamus and anti-GnRH antibodies are not formed under normal conditions. However, administration an excess of recombinant GnRH protein results in the formation of anti-GnRH. We evaluated the efficacy of the recombinant *Salmonella typhimurium* flagellin fljB (STF2)-GnRH vaccine in inducing infertility in 17 intact male cats. The first vaccination and a boosting vaccine was injected for examination. Serum was obtained from blood collected at monthly intervals and anti-GnRH antibodies and testosterone concentrations were determined. Six months after the vaccination, testicular samples are obtained and used for histological examination. Compared with sham control group, the injection groups showed an increase in anti-GnRH antibody titers and testosterone concentrations tended to be reduced in the injection groups and increased in the control group. Histological evaluations and Johnsen's testicular biopsy scores revealed testicular hypoplasia in the 2 injection groups. Consequently, normal sexual maturation with sperm production was observed in the control group. In contrast, the cats that received the GnRH vaccine showed weak (2 of 7 cats) or moderate (4 out of 7 cats) dose-dependent infertility effects. On the basis of the results, the STF2-GnRH vaccine was identified to be effective in inducing infertility in male cats. The results of this study thus indicate the possibility of immunological castration targeting feral cats.

Keywords: Cats; GnRH; vaccines; immunocontraception; testis

INTRODUCTION

Feral cats are widespread not only in Korea but also worldwide, and they are becoming a serious problem because of issues relating to pollution and their detrimental effects on other wild animals. Thus, controlling feral cat populations is essential for the protection of endangered wildlife, and for reducing national economic losses [1-3]. The policy for controlling the numbers of these cats is the trap-neuter-return method. Although surgery after capture is the most reliable method of neutralization [4,5], surgical methods are invasive and require a long recovery period. As a viable alternative, the use of injections

Funding

This work was supported by Korea Institute of Planning and Evaluation for Technology in Food, Agriculture, Forestry and Fisheries (IPET) through Agri-Bio industry Technology Development Program (or Project), funded by Ministry of Agriculture, Food and Rural Affairs (MAFRA) (316035-03-1-SB020).

Conflict of Interest

The authors declare no conflicts of interest.

Author Contributions

Conceptualization: Han JS, Choi IS, Cho YJ; Data curation: Lee YJ; Formal analysis: Han JS, Cho YJ; Funding acquisition: Han JS, Choi IS; Investigation: Lee YJ, Jo EJ, Lee HW, Hwang BR, Lee YA; Methodology: Han JS, Cho YJ, Lee HW, Lee YJ; Project administration: Han JS; Resources: Lee YJ, Jo EJ, Lee HW, Hwang BR, Lee YA, Park BJ, Kin YH; Software: Lee YJ; Supervision: Han JS; Validation: Lee YJ; Visualization: Lee YJ; Writing - original draft: Lee YJ; Writing - review & editing: Han JS.

is non-invasive, reduces the costs associated with surgery, and can reduce the risk of cat mortality due to surgery-related side effects [6,7].

Immunization against gonadotropin-releasing hormone (GnRH) has already been evaluated in several animal species [8-12]. GnRH is a hormone secreted from the hypothalamus, which promotes maturation and reproductive function by stimulating the release of maturation hormones in male and female animals. Under normal *in vivo* conditions, anti-GnRH antibodies are not formed because GnRH is an autologous hormone generated within the body [13]. However, administration of a vaccine containing an excess of recombinant GnRH protein induces the formation of anti-GnRH antibodies that suppress the secretion of GnRH from the hypothalamus. This inhibition of GnRH secretion, resulting in hypoplasia of the testis tissue in male animals, and subsequently leading to testicular atrophy and a reduction in sperm production [14]. There have been several studies on the use of GnRH vaccines against male cats, which have demonstrated the immunocontraception potential of this method [14-16]. However, evaluations have only been performed on a laboratory basis, and thus whether such vaccination can be applied to real cats in the field and, if so, whether it would be effective in controlling the numbers of individuals, have not been assessed. Moreover, since the *Salmonella typhimurium* flagellin fljB (STF2)-GnRH vaccine has yet to be commercialized, this vaccine can be employed for domestic and overseas use. Therefore, in this study, we examined the infertility effect of *Escherichia coli*-expressed STF2-GnRH vaccine and assessed the potential utility of GnRH vaccines for neutering cats.

MATERIALS AND METHODS

Experimental feline model

The 17 male cats used in this study (1.5–3 kg and 4–6 months of age) were of various breeds that were purchased from KOSA Bio (Gyeonggi-do, Korea). The experiment and protocols were approved by the Institutional Animal Care and Use Committee of Konkuk University (KIACUC approval No. 16135). The rearing environment provided the appropriate environment for the cats in compliance with the ILAR guidelines [17]. The research facility was prepared using a 36 m² container, which was divided into an anteroom equipped with research and various other items and the rearing facility. The facility was designed with both space and height in mind so that cats can live as close to nature as possible. In addition, various behavioral enrichment led to the maintenance of stress management and behavioral habits of cats. A warming and cooling air system was installed to maintain the temperature at a level between 20°C and 27°C. Humidity was maintained at levels between 30% and 70% using a humidifier. Temperature and humidity were recorded in 30-day increments using the thermo-hygrograph. Two intake and exhaust ventilation devices were installed to ensure efficient ventilation. Lighting was adjusted using a timer on a 14-h light:10-h dark photoperiod. Prior to the commencement of experimentation, cats were randomly divided into 3 groups: sham control group (n = 3, group A), 100 µg injection group (n = 7, group B), and 400 µg injection group (n = 7, group C).

Vaccine and method of injection

STF2, one of the flagellin proteins of *Salmonella*, is known as a protein that acts as an adjuvant that strongly enhances immune function [18]. A recombinant protein in which STF2 protein was bound to GnRH was expressed using an *E. coli* protein expression system. The STF2-GnRH vaccine was prepared by the Department of Infectious Disease, College of Veterinary

Medicine, Konkuk University (Seoul, Korea) and used at quantities of 100 µg and 400 µg, depending on the experimental group. The control group A was injected with 0.1 mL/kg of phosphate-buffered saline, whereas groups B and C were injected with 100 µg and 400 µg of recombinant *E. coli*, respectively. Male cats were treated by intramuscular injection of the quadriceps femoris muscle. In order to enhance the antibody titer, an additional boosting vaccine of the same amount and concentration as the initial injection was injected 1 month after the initial injection.

Serological evaluation

At monthly interval post vaccination, cats were sedated with an intramuscular injection of medetomidine (0.1 mL/kg) (Sedator; Farvet Laboratories B.V, Netherland) for blood collection. Three milliliters of blood were collected in SST vacutainer tube (BD, USA) through venipuncture of the jugular or cephalic vein. Within 2 h after collection, blood was centrifuged at 2,500 rpm for 10 min to separate the serum. Aliquots (0.7 mL) of the serum were stored at 4°C and testosterone concentration was measured in the Neodin Veterinary Laboratory (Seoul, Korea). The remaining serum was stored at -20°C and used for an indirect enzyme-linked immunosorbent assay (ELISA) test in the laboratory.

Castration for testicular tissue collection

Castration for the collection and examination of testes was performed at 6 months after the initial injection with STF2-GnRH vaccine. The preanesthesia was performed with intramuscular injection of medetomidine (0.08 mL/kg) and anesthesia was induced with intravenously injected alfaxalone (0.4 mL/kg) (Alfaxan; Jurox, Australia). The overall shape of the testes and the presence of the penile spines were assessed before surgery. After the testes had been collected, they were measured and weighed and thereafter stored in 10% aqueous formalin solution for subsequent histological examination. Testis volume was calculated as follows: (length × weight × size × 0.71)

Histological evaluation of the testis

Testes samples were fixed in 10% aqueous formalin solution for 1 day prior to embedding in a paraffin block. The paraffin block was cut into 5-µm slices using a microtome followed by preparation of tissue slides, which were stained with hematoxylin and eosin. The stained tissues were viewed under a microscope to examine the structure of the testicles, and cell and sperm numbers. The maturity of each tubule was evaluated using Johnsen's testicular biopsy score (JTBS) [19], in which each tubule is given a score from 1 to 10, and the maturity of the tubule can be assessed by averaging the scores of 10 adjacent tubules.

Statistical analysis

All statistical analyses were performed using IBM SPSS Statistics 25.0 software, and all data are shown as the mean ± the standard error of the mean. The degree of significance was set at a *p* value of < 0.05. Graphs were generated using GraphPad prism 7 software (GraphPad Software, USA).

RESULTS

Serological evaluation

The results of the indirect ELISA using serum collected at monthly intervals over the 6-month period after vaccine injection revealed no significant changes in anti-GnRH antibody levels

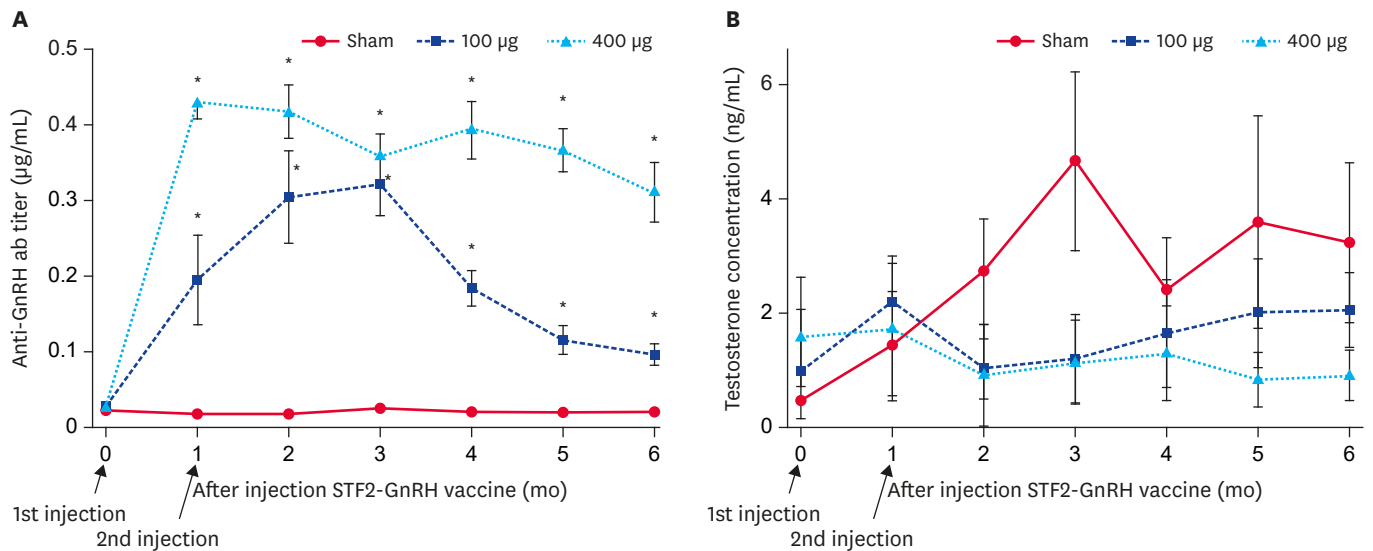


Fig. 1. Anti-GnRH antibody titer and testosterone concentration. (A) Compared with group A cats, there was an increase in the anti-GnRH titer in both group B and group C cats, which were administered 100 µg and 400 µg of the vaccine, respectively ($p < 0.05$). However, the 100 µg injection group showed a comparatively slower increase in antibody titer and a more rapid decline compared with the 400 µg injection group. (B) During the first 1 to 2 months post vaccination, the testosterone response was weak, but thereafter more pronounced changes in testosterone levels were observed. In both the group B ($n = 7$) and group C ($n = 7$) cats, testosterone concentrations tended to be low. Cats in group A ($n = 3$) showed higher testosterone concentrations than those in either of the 2 vaccinated groups.

Data are shown as mean \pm standard error of the mean.

GnRH, gonadotropin-releasing hormone; STF2, *Salmonella typhimurium* flagellin fljB.

* $p < 0.05$ vs. group A.

after injection in the sham control group (**Fig. 1**). In contrast, increases in anti-GnRH antibody levels were evident in both group B and C cats that had been injected with the STF2-GnRH vaccine ($p < 0.05$). No significant differences were detected in the testosterone concentrations of the control or injection group cats until 1 to 2 months after injection. Since testosterone concentration varied in individual subjects, there was a relatively high standard error, and thus no significant effect could be detected ($p > 0.1$). Accordingly, instead, tendency trends were analyzed, which indicated a high tendency for testosterone concentration increase group A cats, whereas increases in testosterone concentration tended to be suppressed in groups B and C.

Morphological analysis

In the control group ($n = 3$), penile spines were clearly observed before castration. In contrast, group C, it was confirmed that there was no ($n = 4$) or little ($n = 2$) penile spine development. The volume and weight of the testes were generally heavier and larger, respectively, in the control group than in the experimental groups (weight: control: 2.22 ± 0.52 g, 100 µg injected: 1.97 ± 0.21 g, 400 µg injected: 1.67 ± 0.31 g; volume: control: 3.62 ± 0.94 cm³, 100 µg injected: 3.12 ± 0.37 cm³, 400 µg injected: 2.14 ± 0.5 cm³) (**Fig. 2**). However, individual differences were found to be larger than group differences ($p > 0.1$) (**Table 1**). Furthermore, the volume and weight of the testes were found to be directly proportional to each other ($p < 0.05$).

Histological evaluation

In the control group, the structure of the normal testicular tubule, in which spermatogenesis typically proceeds in the order spermatogonium-spermatocyte-spermatid-spermatozoa, was observed, and no abnormalities were detected in the surrounding tissues (**Fig. 2A**). In

Table 1. Morphological analysis in the control and vaccinated groups at 6 months after injection

Group	No.	Penile spine	Weight (Lt + Rt) (g)	Average (g)	Volume (cm ³)	Average (cm ³)
A	1	++	2.1045	2.22 ± 0.52	3.893968	3.62 ± 0.94
	2	++	3.1751		5.100003	
	3	++	1.3803		1.88432	
B	1	++	2.1528	1.97 ± 0.21	3.693766	3.12 ± 0.37
	2	+	1.2342		1.931603	
	3	++	1.9682		3.165565	
	4	++	2.4424		3.710296	
	5	+	1.1929		1.78129	
	6	+	2.7051		4.452379	
	7	+	2.0854		3.133492	
C	1	++	2.1707	1.67 ± 0.31	3.144173	2.14 ± 0.5
	2	+	1.8767		2.6152	
	3	-	0.8424		0.709816	
	4	+	2.9721		3.473819	
	5	-	1.6856		2.269631	
	6	-	1.6738		-	
	7	-	0.476		0.6191	

In group A cats, there was a clear development of penile spines, whereas in group B and C cats, penile spine development tended to be weak or absent. The absence of a penile spine means that the testosterone does not come out or function properly. The weight and volume of testes were also found to be lighter and smaller, respectively in groups B and C cats than those in group A cats, although differences were not significant, owing to large individual differences ($p > 0.1$). Overall, morphological development of the injected group was weak compared to the control group. Data are shown as mean ± standard error of the mean.

contrast, cats in the both group B and C could be divided into 2 groups based on testicular tissue development. In the group showing moderate vaccine efficacy, testicular tissue development occurred to some extent, but was characterized by a small number of cells and less tissue development compared with the normal control levels. The numbers of spermatozoa and spermatids were observed to be significantly lower in the group with high vaccine efficacy, and the numbers of other cells were also lower, indicating that the shape and size of the tubules were also altered (**Fig. 2B**).

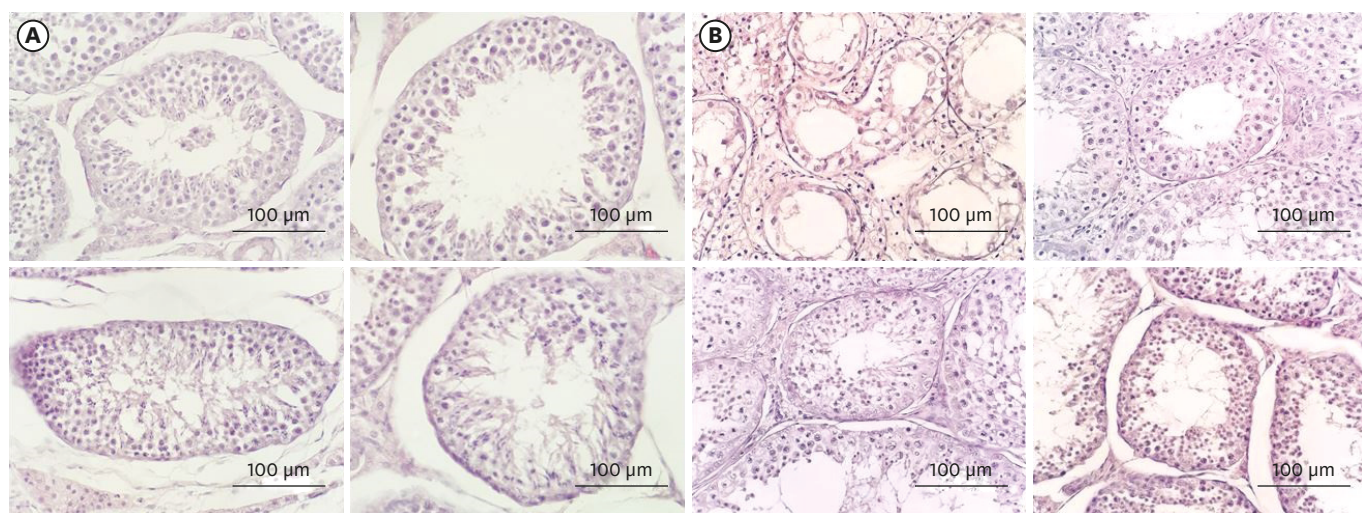


Fig. 2. Testicular tissue of the sham control group and 400 µg injected group (original magnification ×400). (A) The testicular tissue of cats in sham control group was examined microscopically. Numerous spermatozoa and spermatids were observed, and the spermatogonium - spermatocyte - spermatid - spermatozoa differentiation process could be clearly observed. (B) When the testicular tissue of the 400 µg injected group cats was examined, clear differences from the control group could be observed. Spermatozoa and spermatids were absent or present in only very small amounts. Most cells were either spermatocytes or spermatogonia, although their numbers were lower than those observed in the control group.

Table 2. JTBS for 17 castrated male cats

Group	JTBS
A	8.8 ± 0.18
B-1: non-responders	8.06 ± 0.12*
B-2: responders	5.95 ± 0.15*
C-1: non-responders	7.133 ± 0.14*
C-2: responders	3.275 ± 0.22*

Group B and C cats could both be divided into responders and non-responders, which are classified according to JTBS 7 criteria. Both types of which showed a significant decrease in score compared with the cats in control group A. Between the 2 groups, group C showed a larger decrease than B.

Data are shown as mean ± standard error of the mean.

JTBS, Johnsen's testicular biopsy score.

* $p < 0.01$ vs. group A.

Cats in group A had an average JTBS of 8.8 ± 0.18 , confirming good testicular function. In contrast, in group B cats, there was a reduction in testicular activity, which could be divided into 2 stages when compared with the cats in group A, characterized by no effect (group B-1: non-responders, $n = 5$, mean 8.1 ± 0.12) and low testicular activity (group B-2: responders, $n = 2$, mean 6.0 ± 0.15). In group C, the effect was more prominent but could also be divided into 2 groups, the inhibited group (group C-1: non-responders, $n = 3$, mean 7.1 ± 0.14) and the poorly formed group (group C-2: responders, $n = 4$, mean 3.3 ± 0.22) (Table 2). It indicates that the responders have few or no sperm counts and that this will limit normal reproductive activities.

DISCUSSION

This study was conducted on 17 male cats, which received one of the following 3 treatments: sham control, 100 µg vaccine injection group, and 400 µg vaccine injection group. No side effects or abnormal behavior related to the vaccine were detected. Blood sampling was performed using medetomidine as a sedative for the convenience and safety of both cats and researchers [20]. Atipamezole was provided as an antagonist in case of emergency. Similarly, no side effects or behavioral changes were observed in response to venipuncture.

The results of additional ELISA analysis of anti-GnRH antibodies and histological evaluation, revealed, respectively, that antibody titers were elevated at 1 month or less after vaccination, and the development of testicular hypoplasia and reduced sperm production, which tend to be consistent with the findings of previous studies. In contrast, the finding that testosterone concentration was unstable, has not been reported previously. Although the results differed according to vaccine concentration, those for group C cats, which were administered a high concentration of vaccine, could be considered satisfactory when compared with those obtained in previous studies [15,16,21]. Histological evaluation revealed a slight to large degree of testis hypoplasia in the injection groups compared with the control group (100 µg injection group: 2/7, 400 µg injection group: 4/7). In the control group, active spermatogenesis was observed, and therefore it can be assumed that these cats had attained sexual maturity. In contrast, in the experimental groups, only partial spermatogenesis was observed, and, overall, the degree of spermatogenesis was lower than that of the control group when evaluated by JTBS. The JTBS results were found to be correlated with the weight and volume of the testes ($p < 0.05$), indicating a significant relationship with testes development. Therefore, the lower score of JTBS in the injected group can be interpreted as the hypoplasia of testes due to vaccination. And this indicates that there are restrictions on reproductive activities, so the purpose of the vaccine can be observed to be well done.

The group B and group C vaccinated with the anti-GnRH vaccine weighed definitely less than those of group A. However, both of responders and non-responders of group B and C showed significantly low JTBS results than that of group A. Nevertheless, 5 (71%) of the 7 vaccinated cats of group B and 3 (42%) of the 7 vaccinated cats of group C did not respond to the vaccine. Non-responders are frequently identified in several animal species, including cats, after treatment with several types of GnRH immunocontraceptive vaccines. Some researchers reported approximately 20–40% of rats and 33% of cats vaccinated with immunocontraceptive vaccines had been identified to be non-responders [6,22,23] and slightly higher results were found in this study. Even so, group C showed the dose-dependent increase of response and this showed the possibility of the complete dosage of vaccine for the future research and improvement. The lack of response in some animals vaccinated with immunocontraceptive vaccines may be according to the unusual immune responses, but the exact mechanism is still unknown [24]. Most of these non-responder animals have lower levels of anti-GnRH antibodies, but higher concentrations of testosterone than the responders [6,22,23].

On the basis of the aforementioned results, it could be confirmed that administration of a 400 µg amount of the STF2-GnRH vaccine had a good infertility inducing effect during the 6 month trial period. Since the GnRH vaccine has been shown to have an infertility effect, it can be considered to have potential practical application, contingent on performing certain necessary supplementary studies. To confirm the neutralization effect of this vaccine, it will be necessary to determine whether the spermatozoa production is sufficiently suppressed [15]. It might be necessary to examine sperm volume and activity using a semen sampling method, such as electroejaculation. However, in this study, there was lack of domestic electroejaculation equipment for cats, and because of that, there was no proper experimental technique, so the experiment could not proceed. Therefore, if the equipment is equipped or an effective method other than the electroejaculation is developed, additional experiments will be able to verify the STF2-GnRH vaccine. Given that the ability of the vaccine to inhibit testicular tissue growth may not be sufficient, due to the presence of residual GnRH or presence of GnRH before injection of the castration vaccine, it will be necessary to establish the exact timing of injection and determine an efficient means of removing residual hormones [25].

In this study, the author increased the antibody titer of the vaccine by injecting a supplementary boosting vaccine subsequent to the initial injection. However, since it would be very difficult to perform a second administration under actual field conditions, further studies are required to determine how to maintain a high antibody concentration with just a single administration [26]. It is probable that this could be achieved by increasing vaccine dose or concentration. Even if a single injection does not raise enough antibody titer, it is considered possible to inject 1st and boosting injection by developing individual identification methods corresponding to feral cats or by registering using biochips. This study also identifies cats with similar externalities by performing the identification of individuals, so it is expected that feral cats can be identified and vaccinated in a field based on this. In addition, in many cases the cat care-takers can identify their stray cats.

On the basis of the finding of this study, it is not possible to conclude that the STF2-GnRH vaccine has a definite effect; however, the initial results are promising as a vaccine and it is believed that better results can be obtained if the current findings are augmented with further studies. In addition, STF2-GnRH vaccine, which has been applied to other mammal species, shown to be effective against cats as a new target animal. This confirms the possibility that

STF2 can be used instead of the carrier protein keyhole limpet hemocyanin, which was previously used as a vaccine for the immunocontraception.

Unlike previous studies, in this study, we raised cats in a free environment with behavior enrichment rather than in a cage. This allowed the cats to grow in the midst of the laboratory and the wild, and the results of the experiment could be a bridgehead between laboratory research and field testing. Therefore, based on the results of this study, it would be possible to obtain good results in the field if further studies mentioned above are carried out.

In addition to an injected vaccine, it is conceivable that if a bait vaccine could be produced, similar to that currently used for rabies prevention, it will be easier to control feral cat population through neutralization in the wild environment. Ultimately, however, the non-invasive neutralization of feral cats will need to be based on the development commercialized vaccines.

REFERENCES

1. Jessup DA. The welfare of feral cats and wildlife. *J Am Vet Med Assoc* 2004;225:1377-1383.
[PUBMED](#) | [CROSSREF](#)
2. Nogales M, Martín A, Tershy BR, Donlan CJ, Veitch D, Puerta N, Wood B, Alonso J. A review of feral cat eradication on islands. *Conserv Biol* 2004;18:310-319.
[CROSSREF](#)
3. Slater MR. Understanding issues and solutions for unowned, free-roaming cat populations. *J Am Vet Med Assoc* 2004;225:1350-1354.
[PUBMED](#) | [CROSSREF](#)
4. Levy JK, Crawford PC. Humane strategies for controlling feral cat populations. *J Am Vet Med Assoc* 2004;225:1354-1360.
[PUBMED](#) | [CROSSREF](#)
5. Schmidt PM, Swannack TM, Lopez RR, Slater MR. Evaluation of euthanasia and trap–neuter–return (TNR) programs in managing free-roaming cat populations. *Wildl Res* 2009;36:117-125.
[CROSSREF](#)
6. Levy JK, Miller LA, Cynda Crawford P, Ritchey JW, Ross MK, Fagerstone KA. GnRH immunocontraception of male cats. *Theriogenology* 2004;62:1116-1130.
[PUBMED](#) | [CROSSREF](#)
7. Vansandt LM, Kutzler MA, Fischer AE, Morris KN, Swanson WF. Safety and effectiveness of a single and repeat intramuscular injection of a GnRH vaccine (GonaCon™) in adult female domestic cats. *Reprod Domest Anim* 2017;52 Suppl 2:348-353.
[PUBMED](#) | [CROSSREF](#)
8. Dunshea FR, Colantoni C, Howard K, McCauley I, Jackson P, Long KA, Lopaticki S, Nugent EA, Simons JA, Walker J, Hennessy DP. Vaccination of boars with a GnRH vaccine (c) eliminates boar taint and increases growth performance. *J Anim Sci* 2001;79:2524-2535.
[PUBMED](#) | [CROSSREF](#)
9. Janett F, Stump R, Burger D, Thun R. Suppression of testicular function and sexual behavior by vaccination against GnRH (Equity) in the adult stallion. *Anim Reprod Sci* 2009;115:88-102.
[PUBMED](#) | [CROSSREF](#)
10. Jaros P, Bürgi E, Stärk KDC, Claus R, Hennessy D, Thun R. Effect of active immunization against GnRH on androgen concentration, growth performance and carcass quality in intact male pigs. *Livest Prod Sci* 2005;92:31-38.
11. Miller LA, Johns BE, Killian GJ. Immunocontraception of white-tailed deer with GnRH vaccine. *Am J Reprod Immunol* 2000;44:266-274.
[PUBMED](#) | [CROSSREF](#)
12. Purswell BJ, Wilcke JR. Response to gonadotrophin-releasing hormone by the intact male dog: serum testosterone, luteinizing hormone and follicle-stimulating hormone. *J Reprod Fertil Suppl* 1993;47:335-341.
[PUBMED](#)

13. Conn PM, Crowley WF Jr. Gonadotropin-releasing hormone and its analogues. *N Engl J Med* 1991;324:93-103.
[PUBMED](#) | [CROSSREF](#)
14. Thompson DL Jr. Immunization against GnRH in male species (comparative aspects). *Anim Reprod Sci* 2000;60-61:459-469.
[PUBMED](#) | [CROSSREF](#)
15. Levy JK, Friary JA, Miller LA, Tucker SJ, Fagerstone KA. Long-term fertility control in female cats with GonaCon™, a GnRH immunocontraceptive. *Theriogenology* 2011;76:1517-1525.
[PUBMED](#) | [CROSSREF](#)
16. Levy JK. Contraceptive vaccines for the humane control of community cat populations. *Am J Reprod Immunol* 2011;66:63-70.
[PUBMED](#) | [CROSSREF](#)
17. National Research Council (US). *Guide for the Care and Use of Laboratory Animals*. 8th ed. National Academies Press, Washington, D.C., 2011.
18. Song YJ, Kim DG, Nam HM, Lee JB, Park SY, Song CS, Seo KH, Kim HM, Choi IS. Evaluation of the efficacy of immunocastration vaccine composed of gonadotrophin-releasing hormone conjugated with *Salmonella typhimurium* flagellin in rats. *Reprod Domest Anim* 2012;47:e47-e50.
[PUBMED](#) | [CROSSREF](#)
19. Johnsen SG. Testicular biopsy score count--a method for registration of spermatogenesis in human testes: normal values and results in 335 hypogonadal males. *Hormones* 1970;1:2-25.
[PUBMED](#)
20. Westropp JL, Kass PH, Buffington CA. Evaluation of the effects of stress in cats with idiopathic cystitis. *Am J Vet Res* 2006;67:731-736.
[PUBMED](#) | [CROSSREF](#)
21. Robbins SC, Jelinski MD, Stotish RL. Assessment of the immunological and biological efficacy of two different doses of a recombinant GnRH vaccine in domestic male and female cats (*Felis catus*). *J Reprod Immunol* 2004;64:107-119.
[PUBMED](#) | [CROSSREF](#)
22. Han XF, Li JL, Zhou YQ, Ren XH, Liu GC, Cao XH, Du XG, Zeng XY. Active immunization with GnRH-tandem-dimer peptide in young male rats reduces serum reproductive hormone concentrations, testicular development and spermatogenesis. *Asian J Androl* 2016;18:485-491.
[PUBMED](#) | [CROSSREF](#)
23. Yao Z, Si W, Tian W, Ye J, Zhu R, Li X, Ji S, Zheng Q, Liu Y, Fang F. Effect of active immunization using a novel GnRH vaccine on reproductive function in rats. *Theriogenology* 2018;111:1-8.
[PUBMED](#) | [CROSSREF](#)
24. Ferro VA, Khan MA, McAdam D, Colston A, Aughey E, Mullen AB, Waterston MM, Harvey MJ. Efficacy of an anti-fertility vaccine based on mammalian gonadotrophin releasing hormone (GnRH-I)--a histological comparison in male animals. *Vet Immunol Immunopathol* 2004;101:73-86.
[PUBMED](#) | [CROSSREF](#)
25. Franca LR, Parreira GG, Gates RJ, Russell LD. Hormonal regulation of spermatogenesis in the hypophysectomized rat: quantitation of germ-cell population and effect of elimination of residual testosterone after long-term hypophysectomy. *J Androl* 1998;19:335-340.
[PUBMED](#)
26. Killian G, Miller L, Rhyan J, Doten H. Immunocontraception of Florida feral swine with a single-dose GnRH vaccine. *Am J Reprod Immunol* 2006;55:378-384.
[PUBMED](#) | [CROSSREF](#)