

Long-standing necrobiotic xanthogranuloma limited to the skin: A case report

SAGE Open Medical Case Reports
JCMS Case Reports
Volume 9: 1–3
© The Author(s) 2021
DOI: 10.1177/2050313X211057929
journals.sagepub.com/home/sco



Anne-Sophie Smilga¹ , Mona Lavoie^{2,3}, Sungmi Jung³
and Ariane Schreiber⁴

Abstract

Necrobiotic xanthogranuloma is a rare non-Langerhans cell histiocytosis with a known association with monoclonal gammopathies and malignant conditions. There is a lack of consensus regarding the management of necrobiotic xanthogranuloma. In this case report, the patient is diagnosed with a long-standing necrobiotic xanthogranuloma limited to the skin. Although all initial investigations were reassuring, the patient remains at a higher risk of developing a malignant condition. The goal of the authors is to highlight the need for clearer investigation and follow-up guidelines.

Keywords

Dermatology, inflammatory dermatoses, pathology

Introduction

Necrobiotic xanthogranuloma (NXG) is a rare non-Langerhans cell histiocytosis. It is a progressive multisystem histiocytic disease that can lead to organ dysfunction and death. The average age of onset is in the sixth decade.^{1,2} Extensive investigations are considered needed at the time of diagnosis because of the well-described association with monoclonal gammopathies and malignant conditions. There is, however, a lack of official consensus regarding the management of NXG.

We report a case of long-standing NXG limited to the skin. Our aim is to highlight the need for clearer investigation and follow-up guidelines.

Case report

The patient is a 56-year-old Caucasian man with no pertinent past medical history. The reason for consultation was “recurrent eyelid dermatitis.” Upon questioning, the patient reports a 12-year history of oedematous eyelid lesions, describing occasional flares with pruritus. The patient noticed a slight amelioration in the past 4 months with the use of hydrocortisone valerate 0.2% cream twice daily. No other treatments were attempted. The patient additionally reports an occasional burning sensation in the eyes but denies any other ocular symptoms. He also denies any other skin and/or mucous membrane lesions. The review of systems is negative.

On physical examination, there are confluent, yellow-brown plaques on the upper and lower eyelids, bilaterally. Non-palpable purpura is also noted on the left upper eyelid (Figure 1). There is no macroglossia. The ophthalmic examination is normal. An incisional punch biopsy (right lower eyelid) confirmed the diagnosis of NXG. Histopathology indeed shows a diffuse xanthomatized histiocytic infiltrate focally admixed with lymphocytes throughout the dermis into the subcutis. There are frequent Touton type giant cells noted (Figure 2). Laboratory investigations were all normal (complete blood count, renal panel, liver panel, lipid panel, thyroid-stimulating hormone, erythrocyte sedimentation rate, C-reactive protein, antinuclear antibody, rheumatoid factor, immunoglobulins, lactate dehydrogenase, serum protein electrophoresis and immunofixation, and urine protein electrophoresis). Also normal were the chest X-ray, chest–abdomen–pelvis computed tomography, and bone scan. A bone marrow biopsy was not indicated as per the hematology–oncology consultation.

¹Dermatology, Université Laval, Québec, QC, Canada

²Pathology, Hôtel-Dieu de Lévis, Lévis, QC, Canada

³Pathology, McGill University, Montréal, QC, Canada

⁴Dermatology, Hôtel-Dieu de Lévis, Lévis, QC, Canada

Corresponding Author:

Anne-Sophie Smilga, 11 Côte du Palais, Québec, QC G1R 2J6, Canada.
Email: anne-sophie.smilga.1@ulaval.ca



Creative Commons CC BY: This article is distributed under the terms of the Creative Commons Attribution 4.0 License (<https://creativecommons.org/licenses/by/4.0/>) which permits any use, reproduction and distribution of

the work without further permission provided the original work is attributed as specified on the SAGE and Open Access pages (<https://us.sagepub.com/en-us/nam/open-access-at-sage>).

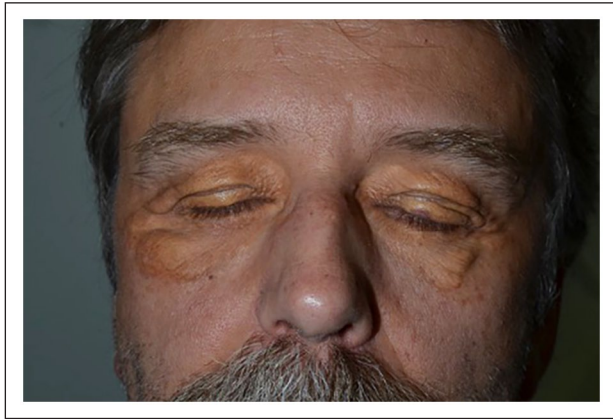

Figure 1. Confluent, yellow-brown plaques on the upper and lower eyelids, bilaterally. Non-palpable purpura also noted on the left upper eyelid.

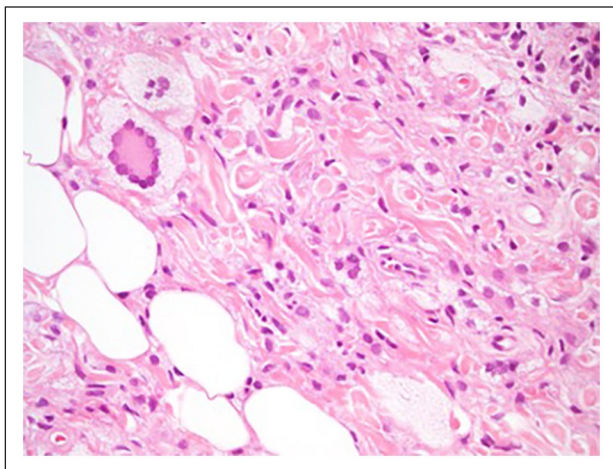


Figure 2. Touton type giant cells. Hematoxylin and eosin stain. 40× magnification.

The patient decided to only continue with his hydrocortisone valerate 0.2% cream twice daily. Other considered treatments were stronger topical corticosteroids, systemic corticosteroids, intravenous immunoglobulin, and thalidomide. Two years later, the patient's condition is stable with no additional findings. There is no evidence of paraproteinemia.

Discussion

Cutaneous lesions are present in virtually all NXG cases. Classically, multiple, asymptomatic, indurated, yellow-to-orange papules, and plaques and/or nodules are found in a periorbital distribution. Other reported features include ulceration, telangiectasias, atrophy, and induration. The remainder of the face, trunk, and proximal extremities can be involved, although less frequently. New skin lesions can also develop within scars. The eyes are the leading site of extracutaneous involvement, with up to half of the patients having ophthalmic manifestations. Other sites are the gastrointestinal tract,

liver, heart, lungs, lymphoreticular system, parotid glands, brain, and muscles.^{1,2}

There is a well-described association between NXG and monoclonal gammopathies, especially of the immunoglobulin G (IgG)-κ type. In a recent multicenter cross-sectional study and systematic review of NXG, paraproteinemia was detected in 82.1% of the patients. A malignant condition was also identified in 25.1% of the patients, with multiple myeloma, lymphoma, and leukemia being the most common ones.²⁻⁴ This underlies the need for clear investigation guidelines at the time of diagnosis as well as on follow-up care. In the case of our patient, there is an uncertainty regarding which investigations to repeat and when. Indeed, although all initial investigations were reassuring, the patient remains at a higher risk of developing a malignant condition.

There is also a lack of consensus regarding the optimal treatment approach and the urgency of implementing it. No controlled clinical studies are available regarding the treatment of NXG. Treatment options include topical and systemic corticosteroids, thalidomide, alkylating agents (chlorambucil, melphalan, and cyclophosphamide), antimalarials, high-dose intravenous immunoglobulin, rituximab, surgery, radiation therapy, psoralen and ultraviolet A radiation (PUVA) therapy, laser therapy, and plasmapheresis.^{2,5-7} Intravenous immunoglobulin appears particularly effective.^{2,7} Newer therapies await future studies.²

Authors' note

This is an invited free submission (Atlantic Dermatology Annual Meeting faculty panel).

Declaration of conflicting interests

The author(s) declared no potential conflicts of interest with respect to the research, authorship, and/or publication of this article.


Funding

The author(s) received no financial support for the research, authorship, and/or publication of this article.

Informed consent

Patient consent was obtained for publication of the case report content.

ORCID iD

Anne-Sophie Smilga  <https://orcid.org/0000-0001-7625-6019>

References

1. Bologna JL, Schaffer JV, Cerroni L, et al. Non-Langerhans cell histiocytoses. In: Bologna JL, Schaffer JV, Cerroni L, et al. (eds) *Dermatology*. Edinburgh: Elsevier, 2018, pp. 1614–1633.
2. Nelson CA, Zhong CS, Hashemi DA, et al. A multicenter cross-sectional study and systematic review of necrobiotic xanthogranuloma with proposed diagnostic criteria. *JAMA Dermatol* 2020; 156(3): 270.

3. Omarjee L, Janin A, Etienne G, et al. Necrobiotic xanthogranuloma: a paraneoplastic skin lesion of haematological malignancies? *Eur J Dermatol* 2018; 28(3): 384–386.
4. Szalat R, Pirault J, Femand JP, et al. Physiopathology of necrobiotic xanthogranuloma with monoclonal gammopathy. *J Intern Med* 2014; 276(3): 269–284.
5. Al-Niaimi FA, Dawn G and Cox NH. Necrobiotic xanthogranuloma without paraproteinaemia: marked improvement with psoralen ultraviolet A treatment. *Clin Exp Dermatol* 2010; 35(3): 275–277.
6. Miguel D, Lukacs J, Illing T, et al. Treatment of necrobiotic xanthogranuloma—a systematic review. *J Eur Acad Dermatol Venereol* 2016; 31(2): 221–235.
7. Olson RM, Harrison AR, Maltry A, et al. Periorbital necrobiotic xanthogranuloma successfully treated with intravenous immunoglobulin. *Case Rep Ophthalmol* 2018; 9(1): 70–75.