



Case report

Bezold's abscess: A rare complication of suppurative mastoiditis

Khurram Malik, Lisa L. Dever*, Rajendra Kapila

Division of Infectious Diseases, Rutgers New Jersey Medical School, Newark, NJ, United States



ARTICLE INFO

Article history:

Received 12 April 2019

Received in revised form 15 April 2019

Accepted 15 April 2019

Keywords:

Bezold's abscess

Suppurative mastoiditis

Skull base osteomyelitis

ABSTRACT

Bezold's abscess is a suppurative complication of mastoiditis rarely seen in the current era of antimicrobials. It can lead to seriously sequelae if not diagnosed and treated early. We describe a patient with recurrent bilateral otalgia who had received multiple courses of antimicrobials who presented with severe headache, neck pain and right sided hearing loss. Imaging studies showed chronic mastoiditis and formation of a Bezold's abscess. Drainage was performed but symptoms persisted. Our report highlights the need for further evaluation of patients presenting with complicated mastoiditis and the need for prolonged antimicrobial therapy.

© 2019 The Authors. Published by Elsevier Ltd. This is an open access article under the CC BY-NC-ND license (<http://creativecommons.org/licenses/by-nc-nd/4.0/>).

Introduction

The clinical importance of the mastoid is related to contiguous structures including the posterior cranial fossa, the middle cranial fossa, the sigmoid and lateral sinuses, the canal of the facial nerve, the semicircular canals, and the petrous tip of the temporal bone. The mastoid air cells are lined with modified respiratory mucosa and all are connected with the antrum. Mastoiditis can occur at any age and may be particularly severe in older adults [1,2]. Incidence of surgical mastoiditis from acute otitis media is reported as 0.004% in the United States [3]. Untreated otitis media increase the risk of acute mastoiditis seen more often in developing countries and very young children [4,5].

Acute mastoiditis and otogenic abscess prior to advent of antibiotics were common. Complications in chronic ear disease usually follow an acute exacerbation of infection often in conjunction with a cholesteatoma. Progression of a middle ear infection to intracranial spread may result from preformed pathways, hematogenously or as a direct extension from the middle ear or mastoid [6]. With the advent of antimicrobial therapy, the overall fatality rate from intracranial complications has decreased from 35% to 5% [7]. We describe a patient with a Bezold's abscess, a suppurative complication of mastoiditis, complicated by skull base osteomyelitis which required prolonged intravenous antimicrobial therapy to eradicate infection.

Case report

A 55-year-old man presented with recurrent right sided ear and post auricular pain. He had been previously treated with multiple course of oral antibiotics and was referred to otolaryngology for follow up. Computed tomography (CT) of the right ear and neck showed right sided chronic mastoiditis, erosion of the inferior mastoid cells, extension of the infection into the neck spaces and formation of a Bezold's abscess in the ipsilateral sternocleidomastoid muscle, extending into the retropharyngeal space (Fig. 1). On examination his temperature was 100.1°F. His only significant finding was post-auricular erythema and tenderness. White cell count was 16,700 cells/cmm with 80% neutrophils. His sedimentation rate was 112 mm/hr and CRP was 43. The patient was admitted and treated empirically with intravenous piperacillin/tazobactam 4.5 g every 6 h.

The patient underwent a right tympanomastoidectomy, canaloplasty, incision and drainage of the Bezold's abscess. Intraoperative findings included abscess fluid collection with surrounding necrotic tissue in the superior aspect of the ipsilateral sternocleidomastoid muscle and extensive granulation and inflammatory tissue with fibrosis in the mastoid air cell and middle ear. Histopathology of the right mastoid revealed fibroconnective tissue with chronic inflammation and possible osteomyelitis of the bone. No granulomas were seen and the acid fast and fungal stains were negative.

Postoperatively the patient continued to complain of hearing loss, severe intermittent headache and low grade fever. No focal neurological signs were present. He had mild neck pain on movement but no nuchal rigidity. The right posterior auricle was tender. There was no drainage or fluctuation over the surgical incision. MRI of the brain, triple phase bone scan and a Gallium

* Corresponding author at: Division of Infectious Diseases, Rutgers New Jersey Medical School, 185 South Orange Avenue, MSB I-689, Newark, NJ, 07103, United States.

E-mail address: deverll@njms.rutgers.edu (L.L. Dever).

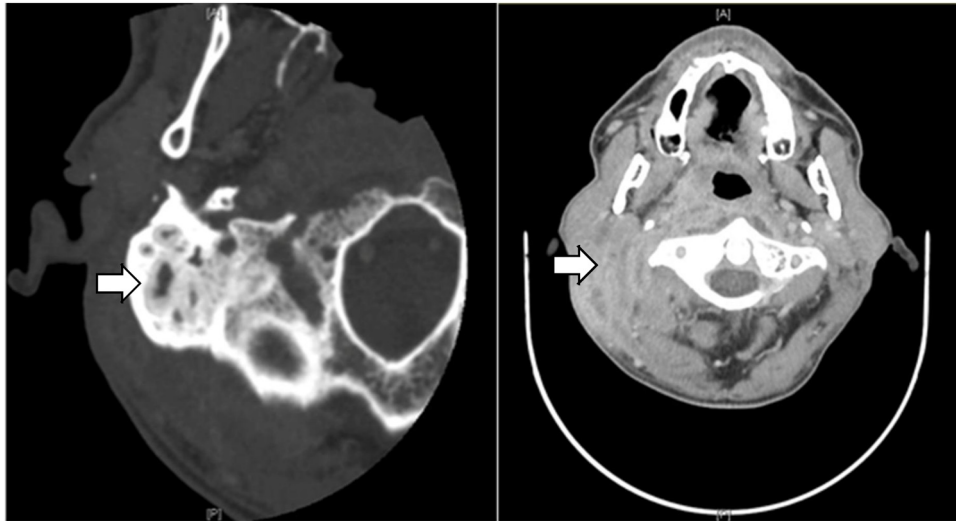


Fig. 1. CT of the temporal bone (left image) showing complete opacification of right mastoid air cells and middle ear cavity with surrounding sclerosis of the mastoid bone (arrow). CT soft tissue of the neck (right image) showing erosion of the cortex of the mastoid tip with adjacent abscess compatible with Bezold's abscess and extension to retropharyngeal space (arrow).

scan (Fig. 2) and SPECT CT scan (Fig. 3) revealed extensive involvement of the infection to the petrous portion of the temporal bone, a retropharyngeal collection, intracranial dural enhancement and skull base. This confirmed the diagnosis of skull base osteomyelitis.

Antibiotics were changed to intravenous vancomycin 1 g every 12 h, cefepime 2 g every 8 h and metronidazole 500 mg every 8 h for broader empiric coverage. HIV test, RPR, tuberculosis interferon-gamma release assay and blood cultures were all negative. *Staphylococcus epidermidis* was recovered from one of three operative tissue cultures, but was not regarded as a pathogen. Otherwise all cultures were negative, including fungal and mycobacterial cultures. After four weeks of intravenous antimicrobials the patient's ESR and white cell count normalized. Repeat MRI brain showed interval improvement however with the intracranial extension of infection a longer duration of intravenous antibiotics continued. The patient had serial ESR, CRP and Gallium scans (Fig. 2) and CT SPECT scans (Fig. 3). After six months of

treatment he had complete resolution of infection and antibiotics were discontinued.

Discussion

Friedrich Bezold, a German otologist, first described the "Bezold" abscess in 1881 as a complication of mastoiditis in 20% of his patients resulting in pus draining through the medial wall of the mastoid process into the digastric groove and forming a suppurative collection [8]. This suppurative process can occasionally track to the digastric muscle to the chin filling the retro maxillary fossa along the occipital artery. If left untreated, further deep extension can occur related to resistance by the sternocleidomastoid, trapezius and splenius muscles. Aeration of the mastoid bone which results in thinning of the osseous walls is a predisposing factor. The rare appearance of a Bezold's abscess in infancy and early childhood is related to incomplete mastoid pneumatization. More serious sequelae arise when the infection

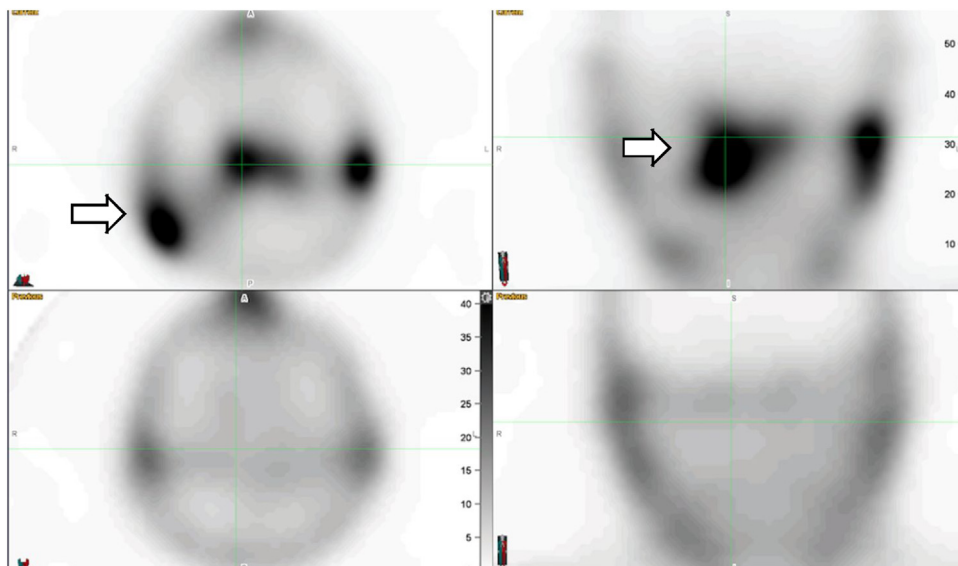


Fig. 2. Gallium scan initial (upper row) increased uptake right mastoid and skull base (arrows). Increase uptake in left parotid is a normal. Repeat studies (second row) following resolution of infection show no focal uptake.

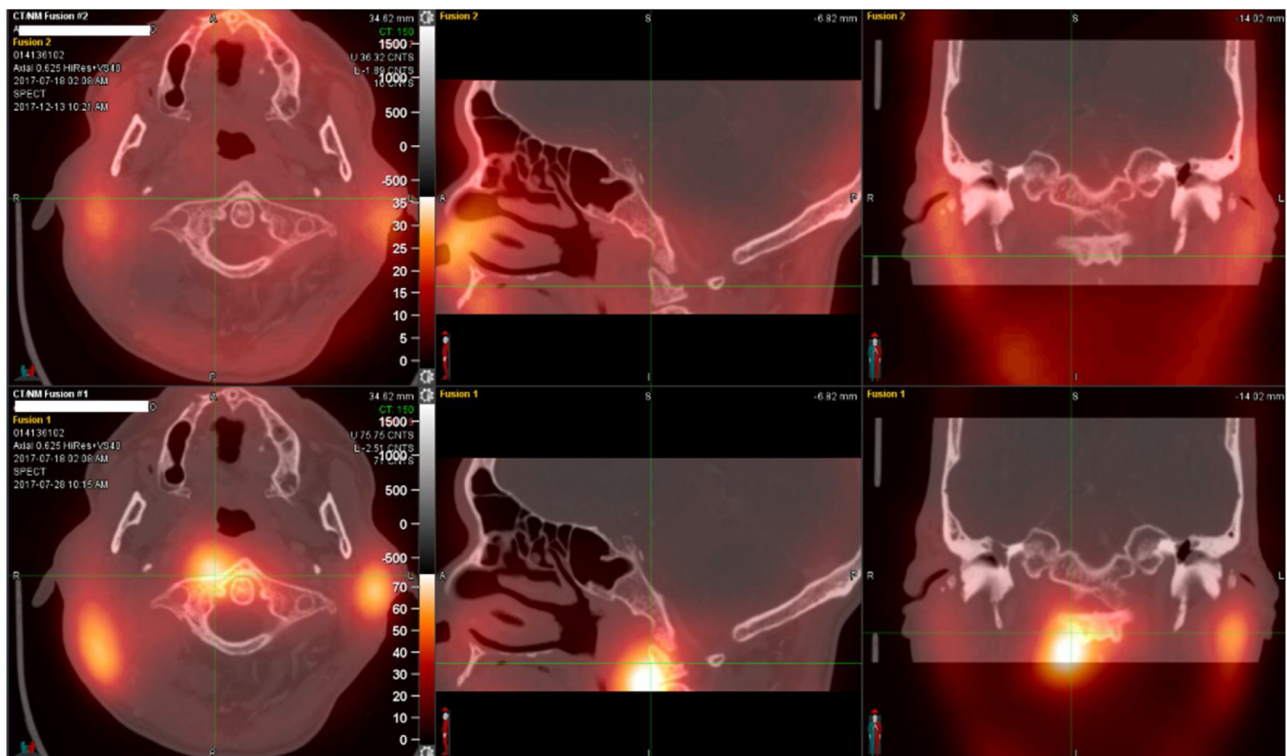


Fig. 3. SPECT CT scans of the skull base after (top row) and before therapy (bottom row). The initial scans show increased uptake and illumination in the right mastoid process (skull base), which were not present on repeat studies (top row).

spreads along the subclavian artery to reach the posterior triangle of the neck, axilla or substernal space of the neck. It may then communicate with the retropharyngeal space via the intervertebral muscles or parapharyngeal space [9].

Clinical presentation is varied and includes pyrexia, otalgia, otorrhea, neck swelling, torticollis, facial nerve palsy and hypoacusia. Patients may not appear septic, and physicians should have a high index of suspicion in patients with otitis. CT and MRI imaging can localize the area of involvement. However, early in the course, when tissue changes associated with necrosis may not have occurred, lesion localization may be extremely difficult. By providing information on pathophysiological and pathobiochemical processing, imaging with nuclear medicine scans can be very useful [10].

The bacteriology of mastoiditis is similar to acute otitis media with *Streptococcus pneumoniae* and *Haemophilus* species as the major pathogens. Patients with persistent perforation of the tympanic membrane may have other organisms from the ear canal including *Pseudomonas* species. Since the introduction of PCV 7 vaccine, emergence of multidrug resistant pneumococcus serotype 19A has been reported in children [2]. Complications of chronic mastoiditis are classified as extracranial and intracranial infections. Extracranial complications include Bezold's abscess (post auricular abscess), zygomatic abscess, facial nerve palsies, petrous apicitis, labyrinthitis, labyrinthine fistula and sensorineural hearing loss. Intracranial complications include meningitis, epidural abscess, subdural empyema, brain abscess, sigmoid sinus thrombosis, meningoencephalocele and CSF rhinorrhea. Lutz et al. published a study of 223 consecutive cases of mastoiditis in which 16 patients presented with complications including cerebellar abscess, peri-sinus empyema, subdural and extradural abscess, cavernous sinus thrombosis, lateral sinus thrombosis, bacterial meningitis, labyrinthitis, petrositis and facial nerve palsy [11].

Our patient was immunocompetent with no evidence of diabetes, HIV infection or chronic debilitating illness. His complications likely developed because of inadequate antimicrobial therapy for acute otitis. Persistent throbbing headaches and hearing loss after surgical drainage prompted us to perform and extensive workup and further imaging studies. We then recognized that the Bezold's abscess was associated with involvement of deeper structures, including skull base osteomyelitis. In such clinical situations, nuclear magnetic imaging is strongly recommended to determine the duration and intensity of antibiotic therapy. In our patient, a very prolonged course of intravenous antimicrobial therapy was required to resolve his infection.

CRediT authorship contribution statement

Khurram Malik: Conceptualization, Data curation, Investigation, Methodology, Writing - original draft, Writing - review & editing. **Lisa L. Dever:** Conceptualization, Data curation, Investigation, Methodology, Writing - original draft, Writing - review & editing. **Rajendra Kapila:** Conceptualization, Data curation, Investigation, Methodology, Writing - original draft, Writing - review & editing.

References

- [1] Samuels MA, Gonzalez RG, Kim AY, et al. Case 34-2007: a 77-year-old man with ear pain, difficulty speaking, and altered mental status. *N Engl J Med* 2007;357:1957–63.
- [2] Ongkasuwan J, Valez TA, Hulten KG, et al. Pneumococcal mastoiditis in children and the emergence of multi-drug resistant serotype 19A isolates. *Pediatrics* 2008;122:34–9.
- [3] Nussinovitch M, Yoeli R, Elishkevitz K, Varsano I. Acute mastoiditis in children: epidemiologic, clinical, microbiologic, and therapeutic aspects over past years. *Clin Pediatr (Phila)* 2004;43:261–7.
- [4] Psarommatis IM, Voudouris C, Douros K, Giannakopoulos P, Bairamis T, Carabino C. Algorithmic management of pediatric acute mastoiditis. *Int J Pediatr Otorhinolaryngol* 2012;6:791–6.

- [5] Palma S, Bovo R, Benatti A, Aimoni C, Rosignoli M, Libanore M, et al. Mastoiditis in adults: a 19-year retrospective study. *Eur Arch Otorhinolaryngol* 2014; (271):925–31.
- [6] Austin DF. Complications of acute and chronic otitis media. In: Ballenger JJ, Snow JB, editors. *Otolaryngology – head and neck surgery*. 15th edition Philadelphia: Williams & Wilkins; 1996. p. 1037–53.
- [7] Yaniv E, Pocock R. Complications of ear disease. *Clin Otolaryngol* 1988;13:357–61.
- [8] Bezold F. Ein neuer Weg für die Ausbreitung eitriger Entzündung aus den Raumen des Mittelohrs auf die Nachbarschaft. *Dtsch Med Wochenschr* 1881;28:381–4.
- [9] Marioni G, de Filippis C, Tregnaghi A, Marchese-Ragona R, Staffieri. Bezold's abscess in children. Case report and review of literature. *Int J Pediatr Otorhinolaryngol* 2001;61:173–7.
- [10] Becker W. The contribution of nuclear medicine to the patient with infection. *Eur J Nucl Med* 1995;22:1195–211.
- [11] Luntz M, Brodsky A, Nusem S, Kronenberg J, Keren G, Migirov L, et al. Acute mastoiditis – the antibiotic era: a multicenter study. *Int J Pediatr Otorhinolaryngol* 2001;57(1):1–9.