

Clinical Observation of COVID-19 in a Patient With an Acquired Humoral Deficiency Secondary to Chemotherapeutic Agents

Allergy & Rhinology
Volume 11: 1–5
© The Author(s) 2020
Article reuse guidelines:
sagepub.com/journals-permissions
DOI: 10.1177/2152656720978764
journals.sagepub.com/home/aar



Jason Schend, DO¹, Phuong Daniels, DPT, OMS-II² ,
Neha Sanan, DO¹, Haig Tcheurekdjian, MD^{1,3} and
Robert Hostoffer, DO, LhD, MSMEd, FACOP, FAAP, FACOI,
FCCP^{1,2,3}

Abstract

Introduction: The coronavirus disease 2019 (COVID-19) pandemic due to the novel severe acute respiratory syndrome coronavirus 2 (SARS-CoV-2) causes worldwide devastation. We describe the course of a patient with COVID-19 in the setting of an acquired humoral deficiency as a result of chemotherapeutic treatment for rheumatologic conditions.

Case Report: A 49-year-old Caucasian male presented with non-relieving fever, hypoxemia, and persistent diarrhea after seven days following a positive SARS-CoV-2 polymerase chain reaction (PCR) assay. The patient's past medical history was significant for mixed connective tissue disease, rheumatoid arthritis, and systemic lupus erythematosus treated with methotrexate and rituximab since 2008. He was diagnosed with acquired humoral deficiency in 2017 managed by intravenous immunoglobulin (IVIG) infusion every three weeks. The patient's course of hospitalization was complicated by acute respiratory distress which necessitated intensive unit care and required up to 20 L/min oxygen supplementation via a humidified high flow generator. He was treated with hydroxychloroquine and azithromycin and received an IVIG transfusion. The patient was discharged to home after forty-two days of hospitalization with oxygen supplementation only during ambulation and a complete resolution of diarrhea.

Discussion: According to current limited data, patients with immunodeficiency have longer length of hospitalization compared to immunocompetent individuals. Our patient demonstrated a form of immunodeficiency as the result of a chemotherapeutic agent, and his clinical course appeared to be more severe.

Conclusion: More studies are necessary to shed light on the immunological response to SARS-CoV-2 and its impact on immunocompromised and immunocompetent individuals. We describe the course of a patient with COVID-19 in the setting of an acquired humoral deficiency.

Keywords

COVID-19, immunodeficiency, rituximab, SARS-CoV-2, chemotherapy

Introduction

The coronavirus disease 2019 (COVID-19) caused by the novel severe acute respiratory syndrome coronavirus 2 (SARS-CoV-2) has created a multifaceted global devastation.¹ There is an existing need for information on the clinical course of COVID-19 in patients with immunodeficiency. We describe the course of a patient with COVID-19 in the setting of an acquired humoral

¹Department of Pulmonary/Critical Care, University Hospitals, Cleveland Medical Center, Cleveland, Ohio

²Department of Pediatrics, Lake Erie College of Osteopathic Medicine, Erie, Pennsylvania

³Allergy/Immunology Associates Inc., Mayfield Heights, Ohio

Corresponding Author:

Phuong Daniels, 5915 Landerbrook Drive, Suite 110, Mayfield Heights, OH 44124, USA.

Email: Pdaniels63891@med.ilecom.edu



deficiency as a result of chemotherapeutic treatment for rheumatologic conditions.

Case Report

A 49-year-old Caucasian male presented with a two-week history of sinusitis, nonproductive cough, and sore throat, which progressed to a fever up to 38.9°C unrelieved by acetaminophen. The patient also experienced generalized myalgia, and had a two-day history of decreased appetite, diarrhea and frontal headache. He tested positive for SARS-CoV-2 by polymerase chain reaction (PCR) assay and was quarantined and medically managed at home for seven days prior to hospital admission. He was admitted due to hypoxemia with oxygen saturation in the low 80 s.

The patient's past medical history was significant for mixed connective tissue disease, rheumatoid arthritis, and systemic lupus erythematosus. The patients' rheumatological symptoms were controlled by a combination of methotrexate weekly and rituximab every six months since 2008. However, the prolonged course of rituximab resulted in chronic pansinusitis which led to a diagnosis of acquired humoral deficiency. The patient was referred by an otolaryngologist for an immunological evaluation because his chronic pansinusitis did not resolve with septoplasty and bilateral sinus surgery followed by several rounds of clarithromycin. His laboratory results revealed poor humoral function as demonstrated by peripheral lymphopenia with zero absolute CD19 count with an absence of IgA and IgM, but a normal level of IgG (Table 1). The IgG serology showed no titer response following a pneumococcal vaccination. Because rituximab was the key in management of his rheumatological conditions, intravenous immunoglobulin (IVIG) was initiated. Initially, the IVIG treatment and dosage were targeted at 400 mg/kg per dose every 4 weeks, increased to 600 mg/kg per dose every 4 weeks, then eventually to 600 mg/kg per dose every 3 weeks along with prophylactic azithromycin daily to effectively manage his chronic sinus infections. The patient's last IVIG and last dose of rituximab was seventeen days prior to hospitalization and two days prior to the start of a non-productive cough.

On admission, the patient presented with tachypnea and visible respiratory distress. His pulse oximetry was 96% on 2 L/min of oxygen via nasal cannula. The vital sign measurements were as follows: temperature of 37.6°C, blood pressure of 119/87 mmHg, heart rate at 82 beats per minute, and respiratory rate at 20 breaths per minute. The auscultation of the lungs revealed fine bibasilar inspiratory crackles with symmetric chest expansion. The initial chest X-ray revealed cardiome-diastinal silhouette enlargement with increased pulmonary vascularity and mild bibasilar atelectasis. The

Table 1. Humoral Panel at Diagnosis of Acquired Humoral Deficiency in 2017.

Test name	Result
IgA, serum (mg/dL)	<5 L
IgG, serum (mg/dL)	739
IgM, serum (mg/dL)	<5 L
IgG subclass 1 (mg/dL)	599
IgG subclass 2 (mg/dL)	89 L
IgG subclass 3 (mg/dL)	34
IgG subclass 4 (mg/dL)	13
CD3 absolute ($\times 10^9/L$)	0.706 L
CD3+CD4+ absolute ($\times 10^9/L$)	0.540
CD3+CD8+ absolute ($\times 10^9/L$)	0.174
CD19 absolute ($\times 10^9/L$)	0 L
CD3 %	85
CD3+CD4+ %	65 H
CD3+CD8+ %	21
CD4/CD8 ratio	3.10
CD3+CD4-CD8-%	1
CD45 %	100
CD3-CD16+CD56+ %	14
CD3-CD16+CD56+ absolute ($\times 10^9/L$)	0.116
CD19 %	0 L
Mannose binding lectin	967
C3 complement	140
C4 complement	21

L = low; H = high.

Note. The boldface values signify abnormal laboratory values (higher or lower than normal reference range).

complete blood count demonstrated leukopenia and lymphocytopenia, which were both normal in January 2020 (Table 2). At this time, the patient was experimentally given hydroxychloroquine and azithromycin, but the lack of pulmonary infiltrate on the initial chest X-ray did not qualify him for the remdesivir trial.

On hospital day four, the patient was transferred to the intensive care unit due to worsening hypoxemia. The laboratory results in Table 2 demonstrated persistent leukopenia and lymphocytopenia with a new elevation of IL-6, C reactive protein, D-dimer, ferritin, glucose, alanine aminotransferase, aspartate transaminase, and lactate dehydrogenase levels. On day five, IVIG was given at 600 mg/kg followed by another 600 mg/kg dose two weeks later. Supplemental oxygen via high flow nasal cannula was initiated at 15 L/min and titrated up to 20 L/min by day twelve. A repeat chest X-ray revealed multifocal ground-glass consolidative opacity that was more significant in the left lower lung with worse aeration compared to prior study.

His respiratory condition was complicated by abdominal distention with diarrhea and ileus, necessitating a nasogastric tube placement. An abdominal computed tomography study was completed on day twenty-six

Table 2. Laboratory Results Prior and During COVID-19.

Timeline	3 months prior to COVID-19	At hospital admission	In ICU	At discharge
WBC (cells/L)	4.5×10^9	3.2×10^9 L	3.2×10^9 L	4.1×10^9 L
Absolute lymphocytes (cells/ μ L)	1157	510 L	330 L	1550
C-reactive protein (mg/L)	2.5 H	5.5 H	10.83 H	3.34 H
Aspartate transaminase, serum (U/L)	27	33	122 H	49 H
Alanine aminotransferase, serum (U/L)	37	25	89 H	70 H
PT (sec)			1.3 H	1.2 H
PTT (sec)			14.6 H	12.9 H
APTT (sec)			23 L	32
D-dimer (ng/mL)		403	887 H	433
Fibrinogen (mg/dL)			673 H	
Troponin I (ng/mL)		<0.02	0.04 H	<0.02
Ferritin, serum (ng/mL)		110	685 H	
Glucose, serum (mg/dL)		135 H	75	87
Ca (mg/dL)		8.4 L	7.7 L	8.7
Na (mmol/L)		137	131 L	141
Cl (mmol/L)		101	94 L	103
BUN (mg/dL)		11	31 H	7
Creatinine (mg/dL)		0.79	0.9	0.51
Albumin (g/dL)		3.6	2.4 L	3 L
Lactate dehydrogenase (U/L)		244	592 H	257 H
pH, arterial			7.53 H	
pCO ₂ , arterial			35 L	
pO ₂ , arterial			53 L	
Bicarbonate, arterial (mmol/L)		30	26	30
Anion gap (mEq/L)		14	9 L	13
IL-6 (pg/mL)			22 H	
IgA, serum (mg/dL)	<5 L		<5 L	
IgG, serum (mg/dL)	1234		1100	
IgM, serum (mg/dL)	<5 L		<5 L	

L = low; H = high.

Note. The boldface values signify abnormal laboratory values (higher or lower than normal reference range).

revealing thickening of the colon. On day twenty-seven, he was discharged from the intensive care unit. Cultures of *Histoplasma*, *Pneumocystis jiroveci*, *Staphylococcus aureus*, *Rhinovirus*, *Metapneumovirus*, *Adenovirus*, and *Clostridium difficile* were found negative for respiratory and gastrointestinal symptoms; however, SARS-CoV-2 remained positive via PCR assay. A computed tomography of the chest was performed on day thirty-three showing diffuse patchy infiltrates in both lungs, worse in the right upper and middle lobes as shown in Figure 1. The patient was discharged to home after forty-one days of hospitalization with oxygen supplementation only with ambulation and a complete resolution of diarrhea despite still being tested positive for SARS-CoV-2. The patient eventually was cleared of SARS-CoV-2 after three different PCR assays at three weeks post hospital discharge.

Discussion

Individuals diagnosed with primary or acquired immunodeficiencies are at high risk for fatal outcomes with

COVID-19.^{2,3} Guan et al. found that the mean hospitalization stay for an immunocompetent patient was 12.8 days compared to the forty-two-day length of stay for our patient.⁴ COVID-19 pneumonia was described in previously reported cases with primary immunodeficient diseases showing similar respiratory decline but followed a shorter course of hospitalization (14–25 days) when compared to our patient's length of stay.^{5–7} According to current data, patients with immunodeficiency have longer lengths of hospitalization compared to immunocompetent individuals.

The “cytokine release syndrome” has been shown to be associated with severe COVID-19 conditions. In the setting of lymphocytopenia observed in severe COVID-19, the cytokine storm release has been suggested to be facilitated by leukocytes other than T lymphocytes.⁸ The possible role of B lymphocytes in the cytokine storm in COVID-19 was discussed by Quinti et al., evidenced by a milder presentation of COVID-19 in patients with agammaglobulinemia when compared to a more severe course in patients with common variable immunodeficiency.⁵

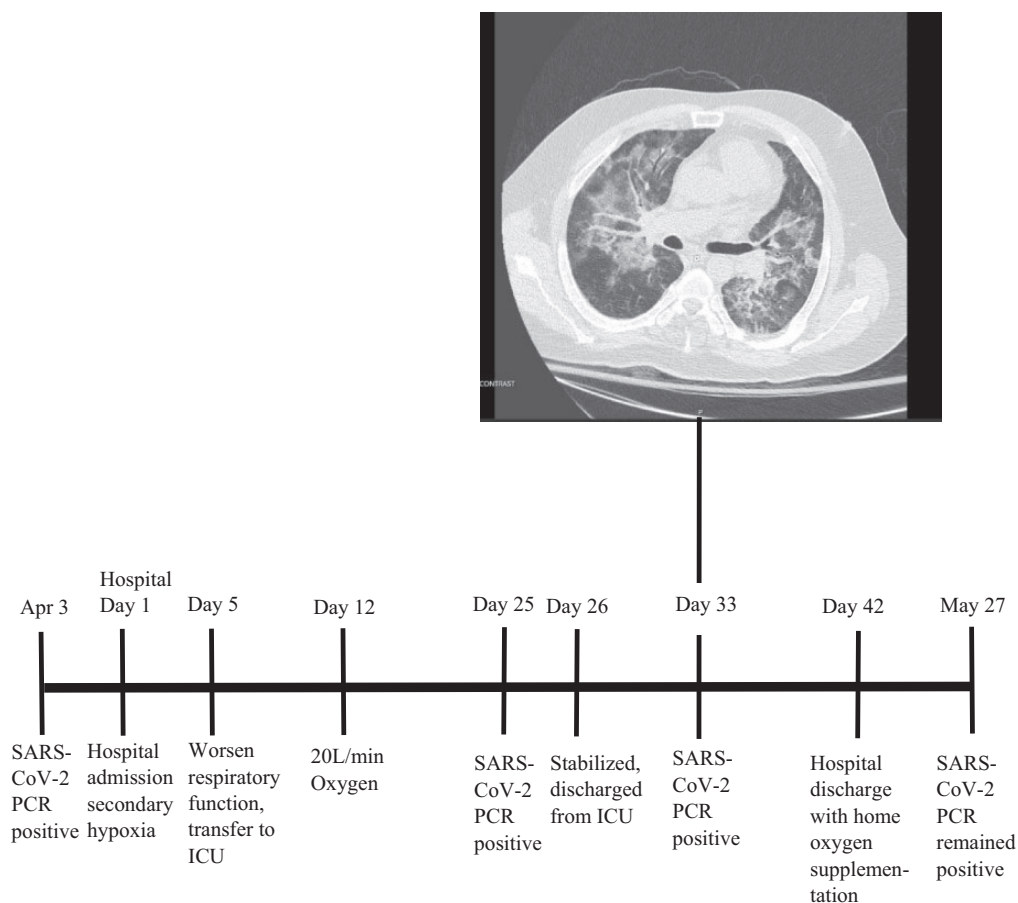


Figure 1. Clinical timeline of COVID-19 and a computed tomography showing diffuse patchy infiltrates in both lungs, worse in the right upper and middle lobes.

Similar observations were reported for two patients with X-linked agammaglobulinemia in Italy infected with SARS-CoV-2 who were able to recover without requiring intensive level of care.⁶ Our patient demonstrated a form of immunodeficiency as the result of a chemotherapeutic agent, and his clinical course appeared to be more severe.

Rituximab is known to modulate autoimmune responses by suppressing the humoral function and decreasing the body's ability to respond to infection independent of COVID-19.⁹ In our case, while providing an essential role in managing the rheumatologic conditions, rituximab resulted in an acquired humoral deficiency requiring IVIG to relieve chronic sinus infections prior to COVID-19. The continuation of IVIG regimen during the course of COVID-19 conferred the importance of passive immunity in helping our patient to recover from COVID-19 pneumonia without the presence of superimposed infections. The highlighted role of IVIG in immunocompromised patients^{6,7} further supported the exploration of the effectiveness of convalescent plasma therapy for COVID-19. Anti-IL-6 monoclonal antibodies were experimentally given to primary

immunodeficient patients in Italy to manage the cytokine storm,⁵ but they are currently under phase 2 clinical trials for immunocompetent patients with COVID-19 (Clinicaltrials.gov identifier: NCT04322773).¹⁰

The inflammatory response to SARS-CoV-2 may be milder in patients with agammaglobulinemia due to the lack of immunoglobulin mediated inflammatory process. It is possible that the pathway which SARS-CoV-2 amplifies inflammatory response is either absent or diminished in patients with agammaglobulinemia, which results in milder course of COVID-19. On the other hand, CVID or acquired humoral deficiencies may have some intact inflammatory mediated pathways that allow SARS-CoV-2 to induce the cytokine storm, which results in a worse clinical presentation of COVID-19. More studies are necessary to shed light on the immunological response to SARS-CoV-2 and its impact on immunocompromised and immunocompetent individuals. We describe the course of a patient with COVID-19 in the setting of an acquired humoral deficiency as a result of chemotherapeutic treatment for rheumatologic conditions.

Author Contributions

Phuong Daniels DPT, OMS-II, Jason Schend D.O., Neha Sanan D.O., Haig Tcheurekdjian M.D., and Robert Hostoffer D.O.: conception and design of the study, data generation, analysis and interpretation of the data, and preparation and clinical revision of the manuscript.

Declaration of Conflicting Interests

The author(s) declared no potential conflicts of interest with respect to the research, authorship, and/or publication of this article.

Ethical Approval

An institutional review board (IRB) approval was sought for this case report (STUDY20200502). The IRB waived the approval process.

Funding

The author(s) received no financial support for the research, authorship, and/or publication of this article.

Statement of Human and Animal Rights

This article does not contain any studies with human or animal subjects.

Statement of Informed Consent

There are no human subjects in this article and informed consent is not applicable.

ORCID iD

Phuong Daniels  <https://orcid.org/0000-0002-2474-6590>

References

1. Sohrabi C, Alsafi Z, O'Neill N, et al. World health organization declares global emergency: a review of the 2019 novel coronavirus (COVID-19). *Int J Surg*. 2020;76:71–76.
2. Harapan H, Itoh N, Yufika A, et al. Coronavirus disease 2019 (COVID-19): a literature review. *J Infect Public Health*. 2020;13(5):667–673.
3. Chen R, Liang W, Jiang M, et al. Risk factors of fatal outcome in hospitalized subjects with coronavirus disease 2019 from a nationwide analysis in China. *Chest*. 2020;158(1):97–105.
4. Guan WJ, Ni ZY, Hu Y, et al.; China Medical Treatment Expert Group for Covid-19. Clinical characteristics of coronavirus disease 2019 in China. *N Engl J Med*. 2020;382(18):1708–1720.
5. Quinti I, Lougaris V, Milito C, et al. A possible role for B cells in COVID-19? Lesson from patients with agammaglobulinemia. *J Allergy Clin Immunol*. 2020;146(1):211–213.e4.
6. Soresina A, Moratto D, Chiarini M, et al. Two X-linked agammaglobulinemia patients develop pneumonia as COVID-19 manifestation but recover. *Pediatr Allergy Immunol*. 2020;31(5):565–510.
7. Fill L, Hadney L, Graven K, et al. The clinical observation of a patient with common variable immunodeficiency diagnosed as having coronavirus disease 2019. *Ann Allergy Asthma Immunol*. 2020;125(1):112–114.
8. Shi Y, Wang Y, Shao C, et al. COVID-19 infection: the perspectives on immune responses. *Cell Death Differ*. 2020;27(5):1451–1454. doi:10.1038/s41418-020-0530-3.
9. Tudesq JJ, Cartron G, Rivière S, et al. Clinical and microbiological characteristics of the infections in patients treated with rituximab for autoimmune and/or malignant hematological disorders. *Autoimmun Rev*. 2018;17(2):115–124.
10. ClinicalTrials.gov. NIH U.S. National Library of Medicine. Anti-iL6 treatment of serious COVID-19 disease with threatening respiratory failure (TOCIVID). <https://www.clinicaltrials.gov/ct2/show/NCT04322773>. Accessed July 1, 2020.