

# Cavernous sinus thrombosis progression from trismus

Jin Yong Cho, Hyeon Min Kim, Jae Young Ryu

Department of Oral and Maxillofacial Surgery, Gachon University Gil Medical Center, Incheon, Korea

**Abstract** (J Korean Assoc Oral Maxillofac Surg 2015;41:43-47)

In the Department of Oral and Maxillofacial Surgery, patients with trismus can be easily identified. If the cause of trismus is infection of the masticatory space near the pterygoid plexus, the possibility of cavernous sinus thrombosis should be considered. We report the case of a patient who presented with limited mouth opening and progressed to cavernous sinus thrombosis, along with a review of the relevant literature.

**Key words:** Cavernous sinus thrombosis, Trismus, Dental focal infection

[paper submitted 2014. 8. 21 / revised 2014. 9. 23 / accepted 2014. 9. 28]

## I. Introduction

Cavernous sinus thrombosis (CST), which was first described by Dease in 1778, is a rare disease associated with high mortality and morbidity rates if not treated immediately<sup>1</sup>. CST can result from infection of the paranasal sinus or any of the anatomic structures drained by the cavernous sinus, including the mid-face, orbit, and oral cavity<sup>2</sup>. Deep neck infection containing lateral pharyngeal, pterygomandibular and infratemporal space that patient are presenting symptom of the limited mouth opening can cause infection of the cavernous sinus from the pterygoid plexus<sup>3,4</sup>.

In this study, we report a patient with CST who initially presented with limited mouth opening.

## II. Case Report

A 55-year-old male visited our department with a chief complaint of limited mouth opening, which began suddenly on August 13, 2013. On physical examination, mouth opening was limited to approximately 10 mm, with mild pain on

opening. However, body temperature was normal and signs of infection including odynophagia, dyspnea, swelling and tenderness were absent. In the transcranial view of the temporomandibular joint, the translation of both temporomandibular joints was limited.(Fig. 1) An orthopantogram revealed chronic periodontitis affecting the right maxillary posterior teeth.(Fig. 2)

The provisional diagnosis was myospasm of the masticatory muscles; we prescribed a muscle relaxant and analgesic with physiotherapy. Three days later, on August 16, 2013, the patient was admitted to the Department of Ophthalmology complaining of orbital swelling and pain. Clinical examination revealed ptosis, proptosis, moderate chemosis, diplopia, and complete ophthalmoplegia of right side.(Fig. 3) Peripheral sensation around the right orbit was good and cranial nerves VII through XII were intact. Symptoms of nuchal rigidity were not observed.

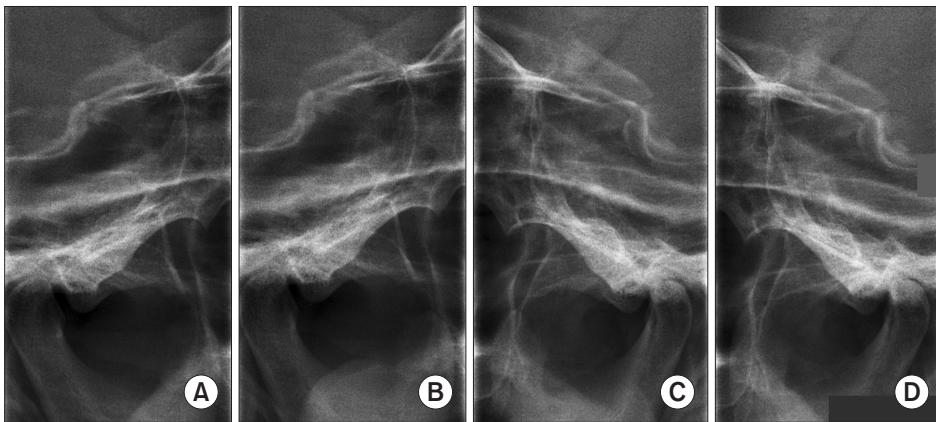
Carotid angiography was performed for differential diagnosis of carotid-cavernous fistula. There was no communication between the carotid artery and the cavernous sinus. (Fig. 4) Computed tomography (CT) and magnetic resonance imaging (MRI) revealed proptosis and engorgement of the right superior ophthalmic vein that was accompanied by enhancement of retrobulbar tissues and swelling of the lateral pterygoid muscle with pus formation. Also, contrast enhancement and dilation indicative of inflammation of the cavernous sinus was noted.(Fig. 5) The paranasal sinuses, including the ethmoid and maxillary sinus of the ipsilateral side, exhibited mucosal thickening and retention of purulent material.(Fig. 6)

### Jae Young Ryu

Department of Oral and Maxillofacial Surgery, Gachon University Gil Medical Center, 21 Namdong-daero 774beon-gil, Namdong-gu, Incheon 405-760, Korea  
TEL: +82-32-460-3373 FAX: +82-32-460-3101  
E-mail: [face@gilhospital.com](mailto:face@gilhospital.com)

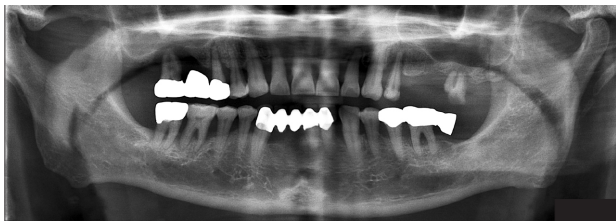©This is an open-access article distributed under the terms of the Creative Commons Attribution Non-Commercial License (<http://creativecommons.org/licenses/by-nc/3.0/>), which permits unrestricted non-commercial use, distribution, and reproduction in any medium, provided the original work is properly cited.

Copyright © 2015 The Korean Association of Oral and Maxillofacial Surgeons. All rights reserved.



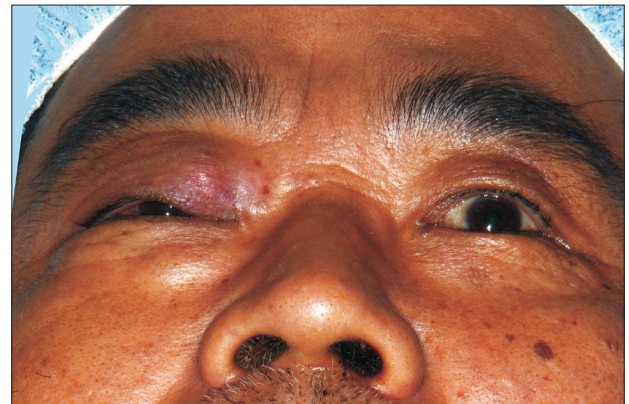**Fig. 1.** Transcranial view indicates limitation of mouth opening. A. Right temporomandibular joint (TMJ); close. B. Right TMJ; open. C. Left TMJ; open. D. Left TMJ; close.

*Jin Yong Cho et al: Cavernous sinus thrombosis progression from trismus. J Korean Assoc Oral Maxillofac Surg 2015*



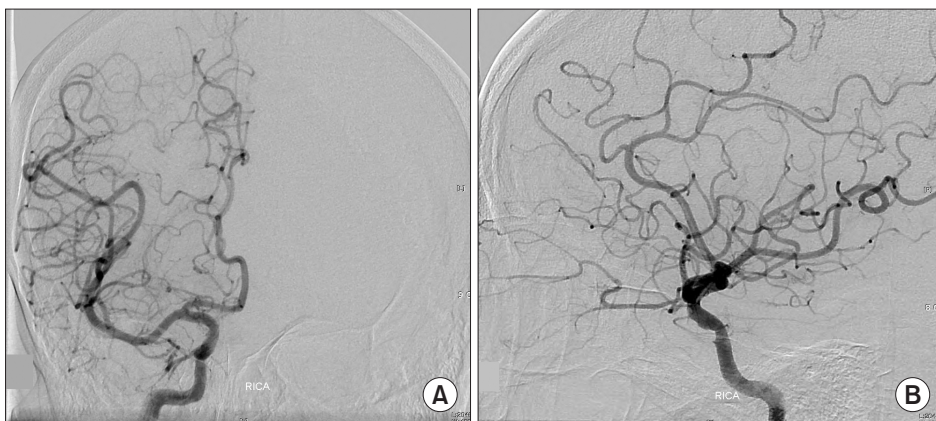**Fig. 2.** Orthopantomogram view indicates chronic periodontitis of the right maxillary posterior teeth.

*Jin Yong Cho et al: Cavernous sinus thrombosis progression from trismus. J Korean Assoc Oral Maxillofac Surg 2015*



**Fig. 3.** Clinical view of right proptosis. Written informed consent has been obtained to publish clinical photographs.

*Jin Yong Cho et al: Cavernous sinus thrombosis progression from trismus. J Korean Assoc Oral Maxillofac Surg 2015*

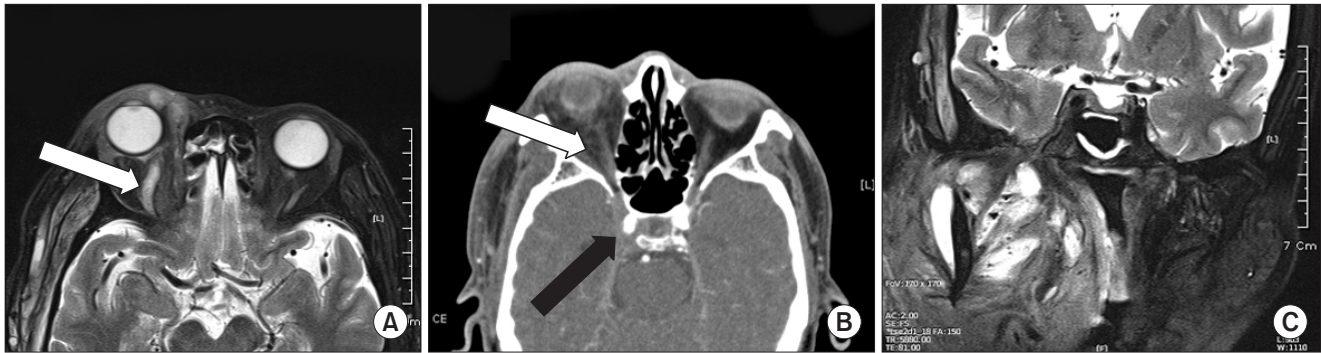

**Fig. 4.** Transfemoral carotid angiography of the right internal carotid artery (RICA). A. Anteroposterior view. B. Lateral view.

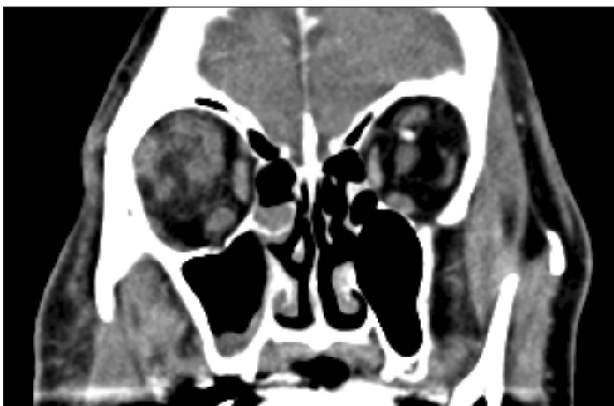*Jin Yong Cho et al: Cavernous sinus thrombosis progression from trismus. J Korean Assoc Oral Maxillofac Surg 2015*

Initially, the patient was empirically treated with intravenous cephalosporin. On hospital day 3, he was prepared for incision and drainage under general anesthesia. The operation was performed via incision in the submandibular area. A large amount of pus was drained from the lateral pharyngeal, pterygomandibular and infratemporal spaces. The wound was

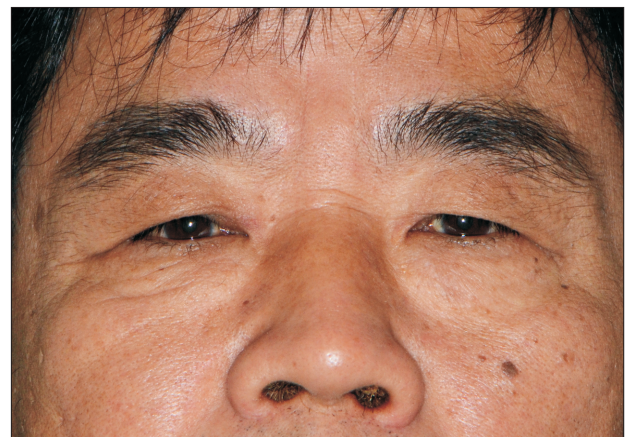irrigated with copious saline through silastic drains placed in the abscess cavity. Intraoperative open cultures of pus were positive for viridans streptococcus. The patient recovered and was extubated 4 days after surgery. Postoperatively, there was rapid improvement in right orbital swelling and ocular movement.



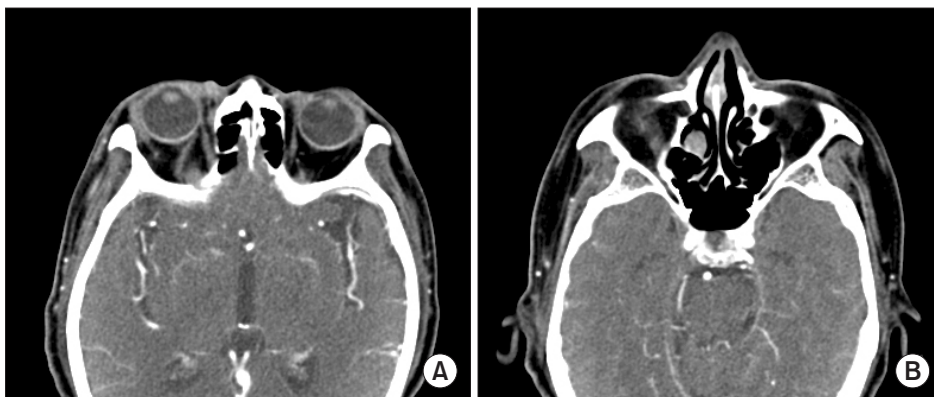
**Fig. 5.** A. Magnetic resonance imaging (MRI) demonstrates engorgement of the right superior ophthalmic vein (arrow). B. Computed tomography illustrates enhancement of the retrobulbar tissues (white arrow) and dilation of the right cavernous sinus (black arrow). C. MRI shows swelling of the lateral pterygoid muscle with pus formation.  
*Jin Yong Cho et al: Cavernous sinus thrombosis progression from trismus. J Korean Assoc Oral Maxillofac Surg 2015*



**Fig. 6.** Preoperative computed tomography depicts mucosal thickening of the right ethmoidal and maxillary sinus.  
*Jin Yong Cho et al: Cavernous sinus thrombosis progression from trismus. J Korean Assoc Oral Maxillofac Surg 2015*



**Fig. 8.** Postoperative clinical view shows complete resolution of orbital symptoms. Written informed consent has been obtained to publish clinical photographs.  
*Jin Yong Cho et al: Cavernous sinus thrombosis progression from trismus. J Korean Assoc Oral Maxillofac Surg 2015*



**Fig. 7.** A. Postoperative computed tomography (CT) shows improvement in the engorgement of the right superior ophthalmic vein. B. Postoperative CT demonstrates improvement in the dilation of the right cavernous sinus.  
*Jin Yong Cho et al: Cavernous sinus thrombosis progression from trismus. J Korean Assoc Oral Maxillofac Surg 2015*

Repeated CT 10 days after surgery demonstrated improvement in the engorgement of the superior ophthalmic vein and dilation of the cavernous sinus.(Fig. 7) Over the following 11 months, his orbital symptoms resolved completely and his

range of mouth opening returned to normal.(Fig. 8)

Written informed consent has been obtained to publish clinical photographs.

### III. Discussion

The cavernous sinus, which is located to the rear of the optic canal and the superior orbital fissure, is an important structure containing the internal carotid artery and cranial nerve III, IV, V, and VI. Thus, if infection or thrombosis occurs in the cavernous sinus, various symptoms referred to as 'cavernous sinus syndrome' can appear, including ophthalmoplegia, diplopia and ptosis due to impairment of cranial nerve III, IV, and VI. Involvement of the ophthalmic nerve and maxillary nerve can cause paresthesia around the orbital cavity<sup>5</sup>.

The cavernous sinus includes tributaries from both superior and inferior ophthalmic veins. Thus, proptosis and chemosis can cause drain blockages of ophthalmic veins to the cavernous sinus<sup>6</sup>. There are also connections between the contralateral cavernous sinus, the intercavernous sinus, facial veins that have not valve, and the pterygoid plexus, which is located very close to the cavernous sinus. Given the complex anastomosis of veins with the cavernous sinus, sometimes orbital symptoms appear on both sides, or on the opposite side<sup>7,8</sup>.

The cause of CST is facial, paranasal, odontogenic, or otogenic infection<sup>9,10</sup>. Childs and Courville<sup>11</sup> reported that an odontogenic source was responsible in up to 10% of cases. Pavlovich et al.<sup>2</sup> presented two cases with different mechanisms: sinusitis and dental infection. In our case, chronic periodontitis of the maxillary posterior teeth and mucosal thickening of the right ethmoidal sinus were observed. Because the initial clinical symptom was the limitation of mouth opening, however, the infection was assumed to be from an odontogenic source. Mazzeo<sup>4</sup> reported that mandibular infections may spread directly to the dural sinuses through the pterygoid plexus. In our case, the patient exhibited symptoms of the proptosis, ptosis, and ophthalmoplegia, accompanied by swelling of the face and neck due to what appeared to be a deep neck infection. The infection was thought to originate around the pterygoid muscle, since trismus preceded orbital symptoms. The route of infection to the cavernous sinus was deemed to be via the pterygoid plexus.

Numerous causes of superior orbital fissure syndrome including trauma, infection of the cavernous sinus, neoplasm, aneurysm of the internal carotid artery, carotid cavernous fistula or idiopathic etiology have been reported in the literature<sup>12,13</sup>. Imaging studies such as CT, MRI, and magnetic resonance angiography should be employed in patients with findings consistent with a CST. If a vascular lesion of the cavernous sinus is suspected, cerebral angiography may be

necessary<sup>5</sup>. Typical radiographic signs of CST include expansion of the cavernous sinus, convexity of the normally concave lateral wall, irregular filling defects, and asymmetry; indirect signs include venous obstruction, dilation of the superior ophthalmic vein, proptosis, and thrombus in the veins<sup>14,15</sup>. Our patients underwent angiography with simultaneous CT and MRI to distinguish the clinical signs from the vascular lesion. On angiography, abnormal blood vessels were not observed, but direct and indirect radiographic signs of CST were demonstrated on CT and MRI.

The treatment of CST includes the use of antibiotics directed at the causative organism and surgery to remove the primary source of infection. The most common organisms are *Staphylococcus aureus* and *Streptococcus* spp.<sup>10</sup>. Culture from the purulent exudates of our patient revealed a viridans streptococcus. Intravenous cephalosporin was administered and the patient recovered from surgery without serious complications. The role of steroid and anticoagulant therapy for the treatment of CST remains controversial<sup>14</sup>.

In summary, CST is a rare disease that can cause life threatening complications. Infections of the pterygoid plexus from an odontogenic source can present as trismus, and clinicians should consider the potential for progression to CST. Prompt diagnosis and appropriate treatment are essential for preventing serious complications.

### Conflict of Interest

No potential conflict of interest relevant to this article was reported.

### References

1. Lyons JB. An early diagnosis of cavernous sinus thrombosis. J Ir Med Assoc 1962;50:76.
2. Pavlovich P, Looi A, Rootman J. Septic thrombosis of the cavernous sinus: two different mechanisms. Orbit 2006;25:39-43.
3. Bentham JR, Pollard AJ, Milford CA, Anslow P, Pike MG. Cerebral infarct and meningitis secondary to Lemierre's syndrome. Pediatr Neurol 2004;30:281-3.
4. Mazzeo VA. Cavernous sinus thrombosis. Report of a case. J Oral Med 1974;29:53-6.
5. Lee JH, Lee HK, Park JK, Choi CG, Suh DC. Cavernous sinus syndrome: clinical features and differential diagnosis with MR imaging. Am J Roentgenol 2003;181:583-90.
6. Horowitz A, Spendel D, Kraut R, Orentlicher G. Cavernous sinus thrombosis as a result of a fungal infection: a case report. J Oral Maxillofac Surg 2013;71:1899.e1-1899.e5.
7. Watkins LM, Pasternack MS, Banks M, Kousoubris P, Rubin PA. Bilateral cavernous sinus thromboses and intraorbital abscesses secondary to *Streptococcus milleri*. Ophthalmology 2003;110:569-74.
8. Goawalla A, Mansell N, Pearson A. Septic cavernous sinus throm-

- bosis with bilateral secondary orbital infection. *Orbit* 2007;26:113-6.
9. Bhatia K, Jones NS. Septic cavernous sinus thrombosis secondary to sinusitis: are anticoagulants indicated? A review of the literature. *J Laryngol Otol* 2002;116:667-76.
  10. DiNubile MJ. Septic thrombosis of the cavernous sinuses. *Arch Neurol* 1988;45:567-72.
  11. Childs HG Jr, Courville CB. Thrombosis of the cavernous sinus secondary to dental infection. *Am J Orthod Oral Surg* 1942;28:B367-73.
  12. Kurzer A, Patel MP. Superior orbital fissure syndrome associated with fractures of the zygoma and orbit. *Plast Reconstr Surg* 1979;64:715-9.
  13. Chen CT, Wang TY, Tsay PK, Huang F, Lai JP, Chen YR. Traumatic superior orbital fissure syndrome: assessment of cranial nerve recovery in 33 cases. *Plast Reconstr Surg* 2010;126:205-12.
  14. Desa V, Green R. Cavernous sinus thrombosis: current therapy. *J Oral Maxillofac Surg* 2012;70:2085-91.
  15. Berge J, Louail C, Caillé JM. Cavernous sinus thrombosis diagnostic approach. *J Neuroradiol* 1994;21:101-17.