

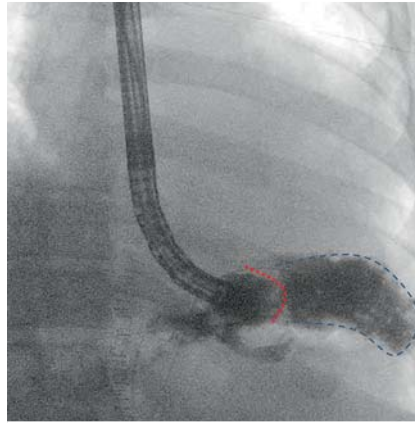
Fix it and feel free to work: endoscopy beside the stent



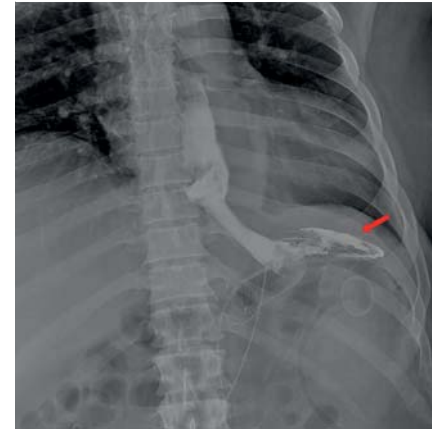A 45-year-old man underwent bariatric surgery (gastric bypass with Roux-en-Y anastomosis) and subsequently developed an anastomotic leak with an intra-abdominal fluid collection and septic status. He underwent a reintervention with complete washing of the cavity, insertion of abdominal drainage, and placement of a percutaneous surgical gastrostomy in the excluded stomach. However, he showed no clinical improvement after 2 weeks and was referred to our institution for endoscopic treatment.

Gastroscopy showed a leak in the upper side of the anastomotic site with extraluminal contrast diffusion (► **Fig. 1**). A fully covered enteric stent was placed and fixed at its proximal side with endoscopic sutures [1–3]. After 2 weeks and still no improvement in the patient's status, X-ray and computed tomography scan with oral contrast were performed, showing a low amount of contrast flowing in the percutaneous drainage (► **Fig. 2**), despite the stent being well positioned. A second gastroscopy performed to treat the leak showed the stent still fixed in place thanks to the endoscopic sutures. We therefore decided to perform the revision without removing the stent, and instead inserted the endoscope parallel to the stent, into the space between the stent and the wall (► **Video 1**). After careful maneuvering of the endoscope beside the stent, endoscopy showed the abdominal drainage into the blind intestinal loop (► **Fig. 3**), so it was moved and re-positioned in the abdominal cavity under both direct endoscopic and radiologic visualization.

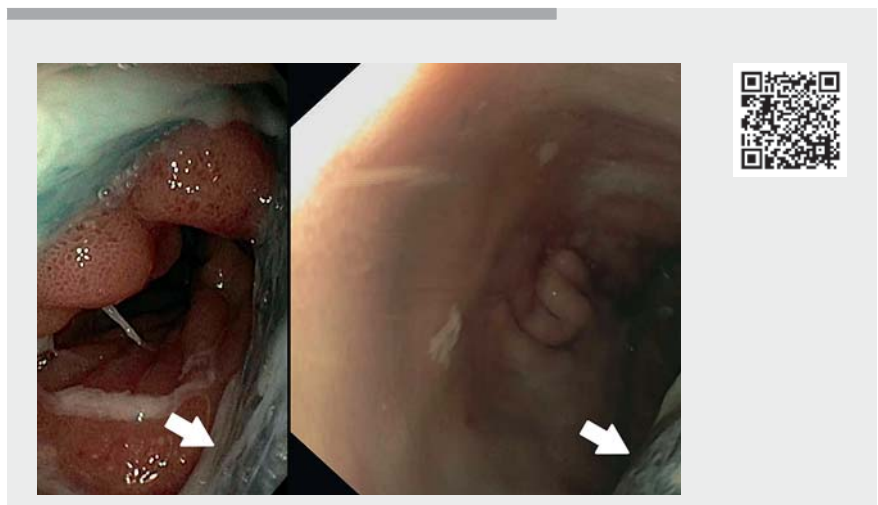
The patient improved and fluid collection gradually decreased, until removal of the abdominal drainage (2 weeks later). After 40 days, endoscopic revision of the leak was performed once again, moving the endoscope beside the stent, as we could not remove the stent before being sure that the leak had resolved. After direct endoscopic and radiologic evidence



► **Fig. 1** Radiography showed extraluminal contrast diffusion into the abdominal cavity (blue dotted area) through a gastric leak (red dotted line indicates the gastric lateral wall where anastomotic leak is located).



► **Fig. 2** X-ray before computed tomography scan after intake of oral contrast, which flowed through the stent but also into the abdominal cavity and drainage (red arrow).

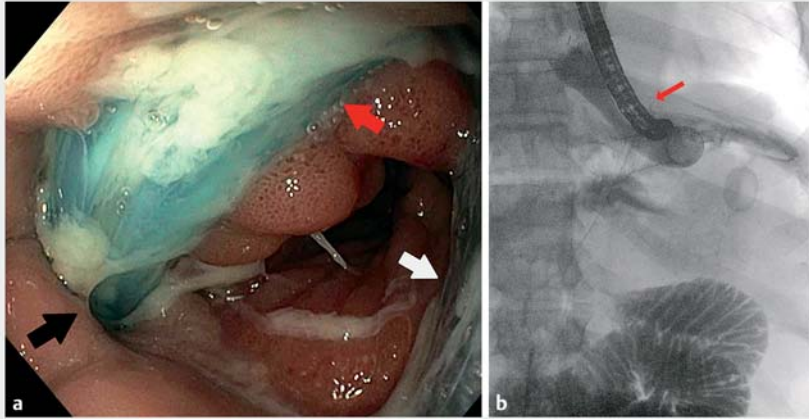


► **Video 1** Endoscopic treatment of post-surgery anastomotic leak included placement of an enteric stent fixed with endoscopic sutures. When the leak persisted, endoscopic re-evaluation without removal of the stent was possible.

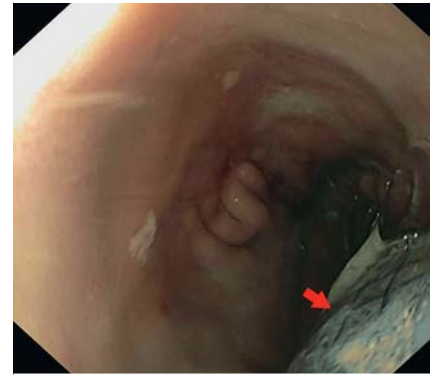of healing of the leak (► **Fig. 4**), the stent was removed. At 3 months' follow-up, the patient did not complain of any sign or symptom of leak recurrence. In conclusion, moving the endoscope alongside the stent appeared to be feasible and safe after

appropriate stent fixation, thus avoiding the need to remove a well-positioned stent.

Endoscopy_UCTN_Code_TTT_1AO_2AI



► **Fig. 3** Endoscopic examination with the stent in place. **a** Endoscopic view of the space next to the stent (white arrow), which the endoscope explored moving in parallel to the stent. Dislocation of the abdominal drainage (red arrow) to the residual gastric cavity (into the space beside the stent) through the anastomotic leak (black arrow) was seen. **b** Radiologic view of the endoscope (red arrow) next to the stent, which maintained its position due to the sutures.



► **Fig. 4** Resolution of the gastric leak in the residual gastric cavity, which was explored without removing the stent (red arrow) and by maneuvering the endoscope beside it.

Funding

Italian Ministry of Health, Rome, Italy
Ricerca corrente: RC 2022, Linea 2E

Competing interests

The authors declare that they have no conflict of interest.

The authors

Antonino Granata¹, **Giacomo E. M. Rizzo**^{1,2,3}, **Giuseppe Nicosia**^{1,3}, **Leo Licari**⁴, **Cosimo Callari**⁴, **Mario Traina**¹

- 1 Endoscopy Service, Department of Diagnostic and Therapeutic Services, IRCCS – ISMETT, Palermo, Italy
- 2 Section of Gastroenterology and Hepatology, Department of Health Promotion Sciences Maternal and Infant Care, Internal Medicine and Medical Specialties, PROMISE, University of Palermo, Palermo, Italy
- 3 Department of Surgical, Oncological and Oral Sciences (Di.Chir.On.S.), University of Palermo, Palermo, Italy
- 4 General Surgery Unit, Buccheri La Ferla Hospital, Palermo, Italy

Corresponding author

Antonino Granata, MD
Endoscopy Service, Department of Diagnostic and Therapeutic Services, IRCCS – ISMETT, Via Ernesto Tricomi 5, 90127 Palermo, Italy
agranata@ismett.edu

References

- [1] Kantsevov SV, Bitner M. Esophageal stent fixation with endoscopic suturing device (with video). *Gastrointest Endosc* 2012; 76: 1251–1255
- [2] Wright A, Chang A, Bedi AO et al. Endoscopic suture fixation is associated with reduced migration of esophageal fully covered self-expandable metal stents (FCSEMS). *Surg Endosc* 2017; 31: 3489–3494
- [3] Law R, Prabhu A, Fujii-Lau L et al. Stent migration following endoscopic suture fixation of esophageal self-expandable metal stents: a systematic review and meta-analysis. *Surg Endosc* 2018; 32: 675–681

Bibliography

Endoscopy 2023; 55: E16–E17
DOI 10.1055/a-1904-7382
ISSN 0013-726X
published online 16.9.2022
© 2022. The Author(s).

This is an open access article published by Thieme under the terms of the Creative Commons Attribution-NonDerivative-NonCommercial License, permitting copying and reproduction so long as the original work is given appropriate credit. Contents may not be used for commercial purposes, or adapted, remixed, transformed or built upon. (<https://creativecommons.org/licenses/by-nc-nd/4.0/>)
Georg Thieme Verlag KG, Rüdigerstraße 14, 70469 Stuttgart, Germany



ENDOSCOPY E-VIDEOS

<https://eref.thieme.de/e-videos>



Endoscopy E-Videos is an open access online section, reporting on interesting cases and new techniques in gastroenterological endoscopy. All papers include a high quality video and all contributions are freely accessible online. Processing charges apply (currently EUR 375), discounts and waivers acc. to HINARI are available.

This section has its own submission website at
<https://mc.manuscriptcentral.com/e-videos>