

# Pholcodine-induced Stevens-Johnson syndrome in a patient with COVID-19

Vedrana Bulat,<sup>1</sup> Robert Likic ,<sup>2</sup> Nives Pondeljic ,<sup>1</sup> Marija Delas Azdajic<sup>1</sup>

<sup>1</sup>Department of Dermatology and Venereology, University Hospital Centre Sestre Milosrdnice, Zagreb, Croatia

<sup>2</sup>Department of Internal Medicine, Division of Clinical Pharmacology and Therapeutics, University Hospital Centre Zagreb, University of Zagreb School of Medicine, Zagreb, Croatia

## Correspondence to

Dr Robert Likic, Department of Internal Medicine, Division of Clinical Pharmacology and Therapeutics, University Hospital Centre Zagreb, University of Zagreb School of Medicine, Zagreb, Croatia; robert.likic@mef.hr

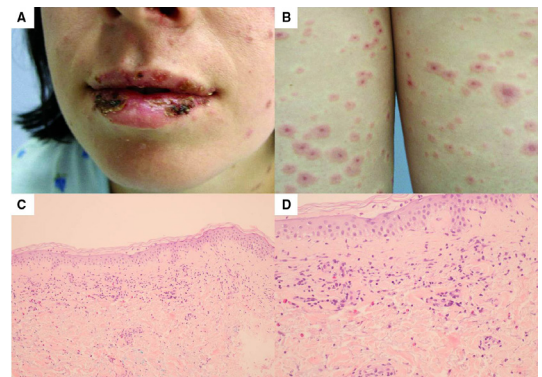
Received 3 February 2021  
Revised 24 March 2021  
Accepted 25 March 2021

Stevens-Johnson syndrome (SJS) is a hypersensitivity reaction with a distinctive clinical pattern characterised by targetoid skin lesions and lesions of at least two anatomic mucosal membranes sites. It is usually triggered by certain drugs, for example, allopurinol, antibiotics (mostly sulfonamides), nonsteroidal anti-inflammatory drugs and aromatic anticonvulsants.<sup>1</sup> Most patients show evidence of SJS 7 to 21 days after the first drug exposure.<sup>1</sup> Viral infections such as COVID-19 might also induce SJS.<sup>2,3</sup> Drug eruptions are often clinically indistinguishable from viral infections.<sup>4</sup>

We present the case of drug-induced Stevens-Johnson syndrome in a patient with COVID-19. A 23-year-old Caucasian female patient was admitted to our hospital due to oral and genital erosions accompanied by erythematous macules with central dusky violaceous region on her thorax, face, lower extremities, palms and soles.

Prior to development of skin lesions, the patient reported symptoms of high fever, pronounced malaise and headache, which were treated symptomatically. Accordingly, a nasopharyngeal swab was obtained and SARS-CoV-2 reverse transcription PCR (RT-PCR) test came back positive. After a prodromal period, she developed a dry cough. The patient was tested for influenza A virus, adenovirus and rotavirus, all of which were negative, indicating that there were no additional infections at the time of the SARS-CoV-2 infection. X-ray images were unremarkable and pholcodine, an opioid cough suppressant was prescribed. The patient was taking this medication for 11 days. Three days after discontinuation of pholcodine, she reported erosive lesions in the oral cavity with dysphagia and burning sensation. At that time and in the past 21 days, no other treatments were prescribed or bought over the counter for the management of the SARS-CoV-2 infection. Personal and family history for autoimmune and allergic diseases were negative. Oral lesions were accompanied by haemorrhagic crusting of the lips (figure 1A). Concomitantly with the appearance of oral lesions, the patient noticed a rapid development of symmetrically distributed, round, erythematous macules with central dusky violaceous region on her thorax, which rapidly spread and conflated on the face, genital area, lower extremities, palms and soles (figure 1B). Genital area lesions led to painful micturition.

On admission, excisional biopsy of the affected skin was performed. Focal liquefaction degeneration of epidermal keratinocytes and exocytosis of mononuclear cells and eosinophils in the epidermis were seen (figure 1C,D), therefore, the diagnosis of SJS was based on clinicopathologic correlation. Marked eosinophilia was detected in full blood count that

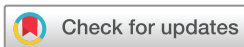

**Figure 1** Patient with Stevens-Johnson syndrome (SJS). (A) Mucosal membrane involvement with haemorrhagic crusting of the lips, (B) macular lesions on lower extremities show a dusky centre, which gives a target-like (targetoid) appearance, (C) lesional skin biopsy in SJS H&E (200x) stain shows focal liquefaction degeneration of epidermal keratinocytes and exocytosis of mononuclear cells and eosinophils in the epidermis, (D) lesional skin biopsy in SJS H&E (400x).

favoured a diagnosis of drug reaction rather than skin lesions induced by viral infection. Parasitic infestations (ectoparasites and helminths), lymphoma, vasculitides (polyarteritis nodosa and Churg-Strauss vasculitis), dermatitis herpetiformis and hepatic cirrhosis were excluded by laboratory and histological findings. Indirect basophil degranulation test to pholcodine was positive. Total IgE and specific IgE to pholcodine were negative due to non-IgE-mediated SJS (performed using ImmunoCAP). Low-dose systemic corticosteroids combined with nonsedating antihistamines were used in order to manage the hyperactivity of the immune system in COVID-19 as well as to control SJS. Skin lesions and lesions of oral and genital mucosa healed without scarring 10 days after discontinuation of pholcodine therapy.

In conclusion, skin and mucosal susceptibility to drugs may be increased in patients with COVID-19. It is possible that the risk of developing SJS is significantly increased in that category of patients as they might have a lowered capacity to detoxify reactive intermediate drug metabolites. Also, SARS-CoV-2 infection could destabilise mastocytes' membranes in some way, making them more susceptible to degranulation. Finally, drug hypersensitivity syndrome should always be ruled out and all skin changes in patients-COVID-19 ought to be investigated with care.

**Contributors** All authors have made equal contributions to the article.



© Author(s) (or their employer(s)) 2021. No commercial re-use. See rights and permissions. Published by BMJ.

**To cite:** Bulat V, Likic R, Pondeljic N, et al. *Postgrad Med J* Epub ahead of print: [please include Day Month Year]. doi:10.1136/postgradmedj-2021-139892

**Funding** The authors have not declared a specific grant for this research from any funding agency in the public, commercial or not-for-profit sectors.

**Competing interests** None declared.

**Patient consent for publication** Obtained.

**Provenance and peer review** Not commissioned; externally peer reviewed.

This article is made freely available for use in accordance with BMJ's website terms and conditions for the duration of the covid-19 pandemic or until otherwise determined by BMJ. You may use, download and print the article for any lawful, non-commercial purpose (including text and data mining) provided that all copyright notices and trade marks are retained.

### ORCID iDs

Robert Likic <http://orcid.org/0000-0003-1413-4862>

Nives Pondeljčak <http://orcid.org/0000-0002-3568-1702>

### REFERENCES

- 1 Hötzenecker W, Prins C, French LE. Erythema Multiforme, Stevens–Johnson Syndrome, and Toxic Epidermal Necrolysis. In: Bologna JL, ed. *Dermatology*. 4th edn. Elsevier Limited, 2019: 332–47.
- 2 Wollina U, Karadağ AS, Rowland-Payne C, et al. Cutaneous signs in COVID-19 patients: a review. *Dermatol Ther* 2020;33:e13549.
- 3 De Giorgi V, Recalcati S, Jia Z, et al. Cutaneous manifestations related to coronavirus disease 2019 (COVID-19): a prospective study from China and Italy. *J Am Acad Dermatol* 2020;83:674–5.
- 4 Weyers W, Metz D. Histopathology of drug eruptions - general criteria, common patterns, and differential diagnosis. *Dermatol Pract Concept* 2011;1:33–47.