


# Endoscopic Therapy in the Management of Patients With Severe Rectal Bleeding Following Transrectal Ultrasound-Guided Prostate Biopsy: A Case-Based Systematic Review

Journal of Investigative Medicine High  
Impact Case Reports  
Volume 9: 1–9  
© 2021 American Federation for  
Medical Research  
DOI: 10.1177/23247096211013206  
journals.sagepub.com/home/hic  


Adnan Malik, MD<sup>1</sup>, Rizwan Ishtiaq, MD<sup>2</sup>,  
Muhammad Hassan Naeem Goraya, MBBS<sup>3</sup>,  
Faisal Inayat, MBBS<sup>4</sup> , and Vinaya V. Gaduputi, MD<sup>2</sup>

## Abstract

Rectal bleeding is a known complication of transrectal ultrasound-guided prostate biopsy. It is usually mild and resolves spontaneously. However, massive life-threatening hemorrhage can also rarely occur in this setting, potentially presenting a therapeutic conundrum. We hereby delineate the case of a patient who experienced severe intermittent lower gastrointestinal bleeding following a transrectal ultrasound-guided prostate biopsy. Traditional tamponade methods failed to control the hemorrhage. Subsequently, an urgent flexible sigmoidoscopy revealed an anterior rectal wall prominence with biopsy punctures as the possible source of bleeding. Endoclip was successfully applied at the bleeding site, achieving permanent hemostasis. The patient had an uneventful recovery and was discharged from the hospital. While the use of endoclipping has been widely reported in gastrointestinal endoscopy, its application remains exceedingly rare in this group of patients. To our knowledge, this case represents only the third report of endoclipping alone to treat massive rectal bleeding following a prostate biopsy procedure. In addition, we systematically review published medical literature to evaluate endoscopic techniques aimed at managing this important complication. This article illustrates that endoscopic therapy may present an efficient, noninvasive method to deal with severe post-biopsy rectal hemorrhage. Therefore, prompt consultation with the gastroenterology service should be advocated.

## Keywords

prostate biopsy, massive rectal bleeding, endoclipping, endoscopic therapy, gastrointestinal evaluation, hemostasis, colonoscopy, flexible sigmoidoscopy

## Introduction

Rectal bleeding frequently occurs in patients undergoing transrectal ultrasound (TRUS)-guided prostate biopsy. In most cases, the hemorrhage is minor and prompt hemostasis can be achieved. However, massive rectal hemorrhage can also occur, affecting up to 1% of cases.<sup>1</sup> This severe post-biopsy adverse event may present with hemodynamic compromise requiring blood transfusion support.<sup>1</sup> It can precipitate disseminated intravascular coagulation warranting intensive care unit admission.<sup>2</sup> Furthermore, it may also lead to large hematoma formation, culminating in luminal occlusion of the rectum.<sup>3,4</sup> Therefore, severe rectal bleeding is uncommon but it can be particularly torrential and life-threatening. Prompt and appropriate management is

warranted to avoid bleeding-related morbidity and mortality in such cases.<sup>5</sup> There are several reported methods to treat rectal hemorrhage after prostate biopsy, but it is traditionally

<sup>1</sup>Loyola University Medical Center, Maywood, IL, USA

<sup>2</sup>Mercy Health St Vincent Medical Center, Toledo, OH, USA

<sup>3</sup>Services Institute of Medical Sciences, Lahore, Punjab, Pakistan

<sup>4</sup>Allama Iqbal Medical College, Lahore, Punjab, Pakistan

Received February 17, 2021. Revised March 25, 2021. Accepted April 3, 2021.

### Corresponding Author:

Faisal Inayat, MBBS, Allama Iqbal Medical College, Allama Shabbir Ahmad Usmani Road, Faisal Town, Lahore, Punjab 54550, Pakistan.  
Email: faisalinayat@hotmail.com



managed by the urologist. Due to this reason, gastroenterology literature concerning endoscopic treatment of this major complication remains scarce.<sup>6</sup>

With the ameliorated therapeutic prowess of endoscopy, a plethora of gastrointestinal disorders previously managed with surgical intervention are now endoscopically amenable.<sup>7-9</sup> Therefore, endoscopic therapy can also be safely opted for severe gastrointestinal bleeding complications that once required surgery for hemostasis. In this context, endoscopic evaluation of patients presenting with massive post-biopsy rectal hemorrhage may allow immediate and effective therapy.<sup>10</sup> The present article chronicles a case of massive hematochezia following TRUS-guided prostate biopsy that was successfully managed by endoclip application using flexible sigmoidoscopy. To our knowledge, only 2 similar cases have previously described the use of endoclippping alone in the management of this complication to date.<sup>11,12</sup> Furthermore, we undertake a systematic review of the available English-language literature regarding endoscopic techniques used to manage rectal bleeding after prostate biopsy.

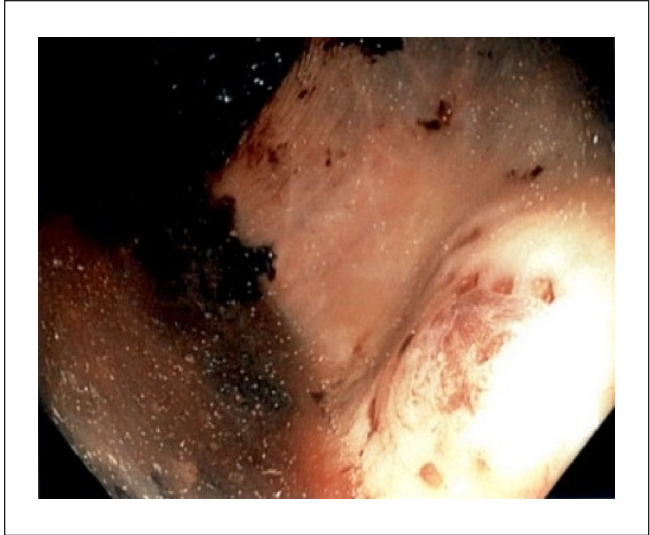
## Illustrative Case

### Presentation

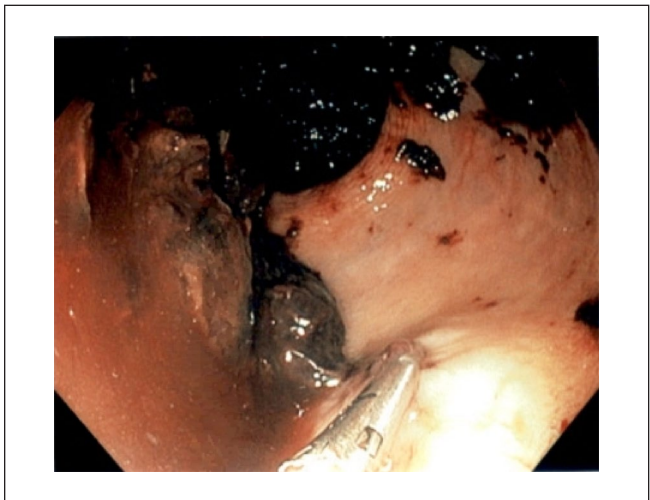
A 69-year-old male presented to the emergency department with severe rectal bleeding and orthostatic changes. The patient underwent an elective TRUS-guided prostate biopsy using an automated 18-gauge core biopsy needle (Boston Scientific). Three tissue cores were obtained within each quadrant for a total of 36 biopsies. Postintervention inspection of the rectum demonstrated no active bleeding. He was discharged from the hospital after 24 hours in a stable condition. After 6 hours of discharge, he experienced gross bleeding per rectum and 2 syncopal episodes. There was no history of hemorrhoidal disease, gastrointestinal bleeding events, abdominal and/or vascular surgeries, peptic ulcer disease, inflammatory bowel disease, or abdominopelvic radiation therapy. At presentation, the patient appeared diaphoretic and pale, with no abdominal tenderness. His vital sign examination revealed a temperature of 36.5 °C, heart rate 117 beats per minute, blood pressure 100/60 mm Hg, and oxygen saturation of 96% on room air. Laboratory studies revealed a hemoglobin level of 7.3 g/dL, which dropped from the preprocedural level of 12.5 g/dL. The platelet count, prothrombin time, and partial thromboplastin time were within normal limits. In the emergency department, initial resuscitation was performed with intravenous fluids and 2 packed red cell transfusions. The patient had a favorable geriatric performance status.

### Treatment

With regard to treatment, digital pressure was initially applied but it failed. A multidisciplinary team with expertise



**Figure 1.** Flexible sigmoidoscopy of the rectum revealing an anterior wall prominence with multiple biopsy punctures.



**Figure 2.** Flexible sigmoidoscopy of the rectum showing successful application of an endoclip at the bleeding site corresponding to the biopsy punctures at the anterior wall prominence.

in gastroenterology, interventional radiology, and surgery recommended endoscopic therapy. The patient was educated about this treatment modality. Informed consent was obtained after discussing both benefits and possible risks. After adequate hemodynamic resuscitation and polyethylene glycol rapid purge, he underwent an urgent flexible sigmoidoscopy. It revealed a 2-cm bulge on the anterior rectal wall with multiple punctures, with no evidence of active bleeding (Figure 1). An endoclip (Olympus Medical Systems) was successfully applied at the protuberant injury area in the rectal wall, which was caused by the prostate multiple biopsies (Figure 2). Even though the preparation

was not optimal, the rest of the rectosigmoid area appeared grossly normal.

### **Clinical Outcome and Follow-up**

The hematochezia resolved with no further drop in his hemoglobin levels. He was tolerating a solid diet and was discharged from the hospital in a stable condition. At the follow-up after 1 week, he showed excellent recovery and did not experience another bleeding episode. At the end of 1 and 6 months after endoclip treatment, the patient developed no symptoms or signs of recurrent bleeding. He did not require a repeat endoscopic intervention, transcatheter arterial embolization, or surgery.

### **Methods**

A systematic review was performed using the Preferred Reporting Items for Systematic Reviews and Meta-Analyses (PRISMA) guidelines.<sup>13</sup> We conducted a systematic search of bibliographic databases, including MEDLINE (PubMed and Ovid), Embase, Scopus, and Google Scholar. Furthermore, we reviewed conference papers from major gastroenterology scientific meetings, including Digestive Disease Week, United European Gastroenterology Week, and the American College of Gastroenterology. A comprehensive search strategy was construed to identify relevant studies, using a combination of subject headings and text words. Search terminologies such as “rectal bleeding,” “transrectal,” “prostate biopsy,” and “complications” were combined using the Boolean operators “AND” and “OR” with the terms “endoscopic therapy” and “endoscopy” with all permutations. We considered English-only articles, with no defined time filter. Pertinently, no consistent or specific definition of “severe,” “massive,” or “life-threatening” hemorrhage was applied. However, hemodynamic compromise and the requirement for blood transfusion were taken as evidence of severe bleeding. Search results were reviewed for 2 major objectives: (1) estimation of the rate of rectal bleeding following prostate biopsy in the past 2 decades based on selected studies and (2) evaluation of the effectiveness of endoscopic treatment for massive bleeding episodes. Two of the authors independently reviewed the titles and abstracts of the search results. In order to determine eligibility, full-text versions of potentially relevant articles were independently retrieved and reviewed by the other 2 authors. The final inclusion of a study into our analysis was based on a discussion headed by the senior author.

### **Results**

Several studies have reported rectal bleeding after the prostate biopsy but the exact rate of this complication remains unknown. We conducted a literature review using a selected pool of studies in order to estimate the rate of this adverse

effect in the past 2 decades. A total of 26 studies were carefully reviewed, with the sample size ranging from 50 to 12 968 patients. As per the results of our analysis, the rate of rectal bleeding demonstrated a remarkable heterogeneity, ranging from 0% to 37.1% (Table 1).<sup>13-39</sup> Notably, the clear stratification between mild, moderate, and severe bleeding in individual studies was not clearly delineated. However, most patients experienced minor bleeding episodes that were amenable to traditional conservative measures. Therefore, massive bleeding secondary to TRUS-guided biopsy remains extremely rare.

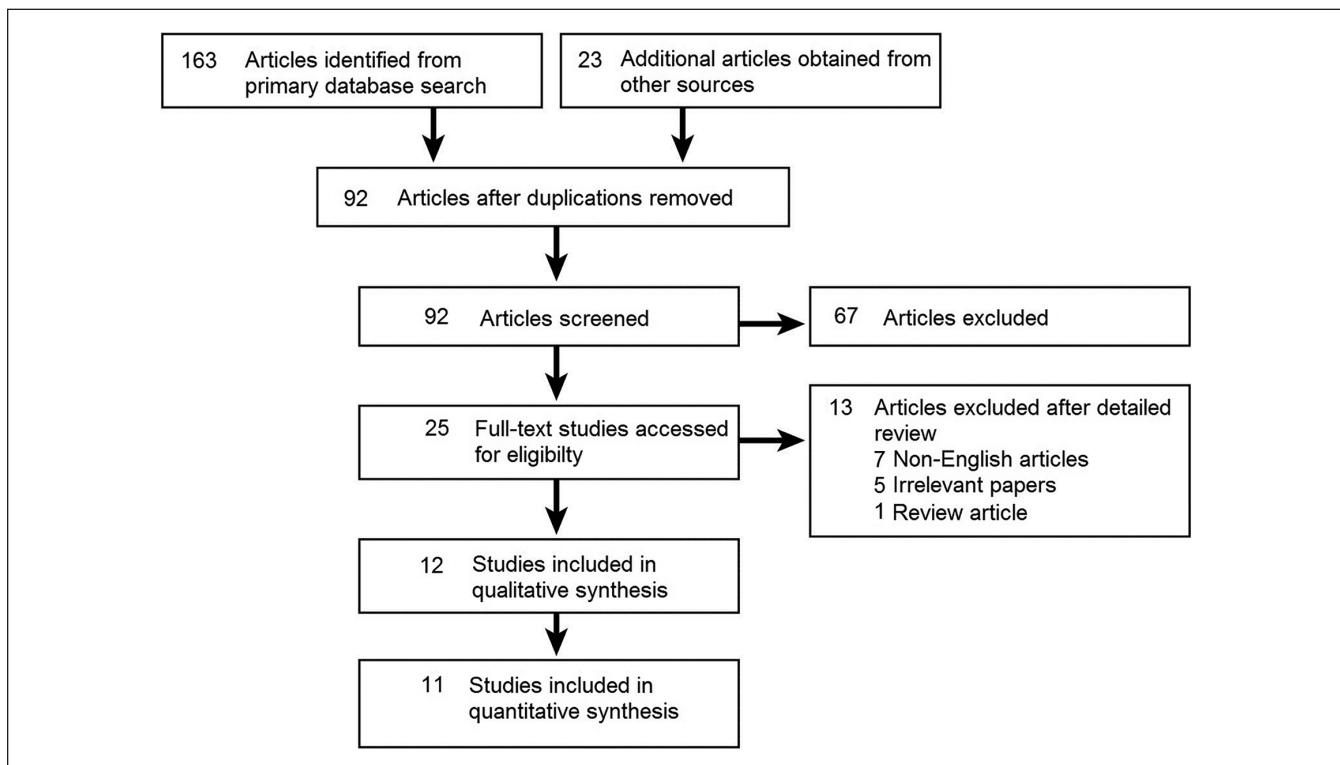
In order to study endoscopic therapy for post-biopsy severe bleeding, an initial systematic search of databases identified a total of 163 articles. Twenty-three studies were obtained from other bibliographic sources. A vast majority of articles were either redundant or duplicate, resulting in exclusion from our analysis. Careful screening and review of remaining search results eventually yielded a total of 11 articles. PRISMA flow diagram outlines the search methodology for data synthesis and results (Figure 3). After a meticulous review of these articles, a total of 18 case reports only (clinical evidence level: 3) were included in the quantitative analysis (Table 2). The age of patients ranged from 57 to 81 years (mean  $\pm$  standard deviation, 65.78  $\pm$  7.17 years). It is notable that 16 of 18 patients were more than 60 years of age. With regard to the temporal relationship between the bleeding onset and timing of the biopsy procedure, significant variation was observed. The delay in post-procedure bleeding ranged from a few hours (n = 11) to several days (n = 7). The mean number of red cell transfusions was 4.4 (range = 2-14). A number of patients (n = 7) were previously on anticoagulant, nonsteroidal anti-inflammatory, and/or antiplatelet medications. Colonoscopy (n = 13) and flexible sigmoidoscopy (n = 5) were among the procedures used for endoscopic evaluation. Several patients underwent unprepped procedure (n = 7), whereas a few (n = 3) received urgent bowel preparation. Bowel preparation status was not specified in 8 patients. Endoscopic therapeutic techniques included injection sclerotherapy (n = 10), combination endoscopic therapy (n = 3), endoclippping alone (n = 2), thermocoagulation (n = 2), and band ligation (n = 1). The overall primary hemostasis rate of endoscopic therapy was 94% (17 of 18), with a rebleeding rate of 6% (1 of 18). The mean duration of hospital stay was 2.7 days, ranging from 12 hours to 5 days.

### **Discussion**

A rare case of severe rectal bleeding secondary to TRUS-guided prostate biopsy has been encountered in a patient and a systematic review of published medical literature has been presented in order to raise awareness regarding the application of endoscopic therapy in the management of this important complication.

**Table 1.** Literature Review Regarding Incidence of Rectal Bleeding Following Transrectal Ultrasound-Guided Prostate Biopsy.

Authors	Country	Study sample size, n	Rectal bleeding, %
Gustafsson et al <sup>14</sup> (1990)	Sweden	145	0
Collins et al <sup>15</sup> (1993)	UK	89	37.1
Clements et al <sup>16</sup> (1993)	UK	80	7.5
Aus et al <sup>17</sup> (1993)	Sweden	391	2.8
Herranz et al <sup>18</sup> (1996)	Spain	100	16.3
Hammemer and Huland <sup>19</sup> (1996)	Germany	651	23.9
Enlund and Varenhorst <sup>20</sup> (1997)	Sweden	426	21.7
Rietbergen et al <sup>21</sup> (1997)	The Netherlands	1687	1.7
Rodriguez and Terris <sup>22</sup> (1998)	USA	128	16.4
Deliveliotis et al <sup>23</sup> (1999)	Greece	120	33.3
Herget et al <sup>24</sup> (1999)	Canada	1180	0.2
Crundwell et al <sup>25</sup> (1999)	UK	104	0
Peters et al <sup>26</sup> (2001)	UK	110	15
Djavan et al <sup>27</sup> (2001)	Austria	1051	2.1
Manseck et al <sup>28</sup> (2001)	Germany	162	4.9
Makinen et al <sup>29</sup> (2002)	Finland	200	13
Raaijmakers et al <sup>30</sup> (2002)	The Netherlands	5676	1.3
Chiang et al <sup>31</sup> (2007)	Taiwan	1875	0.2
Efesoy et al <sup>32</sup> (2013)	Turkey	2049	28.4
Wei et al <sup>33</sup> (2015)	Taiwan	12968	1.1
Park et al <sup>34</sup> (2017)	South Korea	100	32
Cheong et al <sup>35</sup> (2017)	Taiwan	218	0.9
Cheng et al <sup>36</sup> (2019)	Hong Kong	1699	0.4
Lo et al <sup>37</sup> (2019)	Hong Kong	200	0.5
Antoine et al <sup>38</sup> (2020)	Jamaica	185	23
Joshi <sup>39</sup> (2020)	Nepal	50	2

**Figure 3.** Preferred Reporting Items for Systematic Reviews and Meta-Analyses (PRISMA) flow diagram representing the search methodology for data synthesis regarding endoscopic therapy in the management of patients with severe rectal bleeding following transrectal ultrasound-guided prostate biopsy.

**Table 2. Reported Cases of Severe Rectal Bleeding After a Transrectal Ultrasound-Guided Prostate Biopsy Managed With Endoscopic Therapy.**

Authors	Country	No. of patients	Mean age (years)	Bleeding-onset delay	Mean no. of units transfused	Anticoagulants/ antiplatelets	Conservative measures	Procedure	Bowel preparation	Bleeding source	Endoscopic therapy	Clinical outcome
Bullet et al <sup>15</sup> (2000)	Spain	5	62	Shortly after the procedure	4.6	Aspirin or anti-coagulant therapy	Rectal packing and digital pressure	Colonoscopy	Unprepped	Anterior rectal wall bleeding (4) Nonbleeding visible vessel (1)	Epinephrine injection Epinephrine + polidocanol injection	Recovered, 3.4 days
Strate et al <sup>16</sup> (2001)	USA	2	62.5	Several hours; 6 days	5	Aspirin	None	Flexible sigmoidoscopy followed by oral colonoscopy	Oral Golytely rapid prep Fleet's enema X2 Golytely rapid prep	Rectal wall puncture site (1) Focal bleeding site with adherent clot (1)	Band ligation, epinephrine injection	Recovered
Kinney et al <sup>6</sup> (2001)	USA	2	79	Several hours; 4 days	Not reported	Not reported	None	Flexible sigmoidoscopy	Not specified	Pulsatile bleeding (1) Hematoma, oozing (1)	Heater probe Epinephrine injected into the hematoma	Recovered, 12 hours-1 day
Ustündağ et al <sup>16</sup> (2004)	Turkey	1	62	6 days	4	NSAIDs for back pain	None	Colonoscopy	Not specified	Visible vessel on anterior rectal wall	Repeat: atroxysclerol injection	Recovered
Braun et al <sup>17</sup> (2007)	Germany	1	65	8 hours	2	Phenprocoumon	Manual compression, rectal tampon	Colonoscopy followed by inverted gastroscopy	Not specified	Rectal arterial oozing	Epinephrine injection	Recovered
Pacios et al <sup>18</sup> (2007)	Spain	1	59	48 hours	2	Telmisartan + anti-coagulant	None	Colonoscopy	Not specified	Anterior rectal wall bleeding	Epinephrine + ethanol injection	Recovered
Arroja et al <sup>19</sup> (2009)	Portugal	2	66.5	2 hours; 10 days	2	Aspirin	Digital compression or rectal packing (1)	Colonoscopy	Not specified	Focal bleeding site with adherent clot on the anterior rectal wall (1) Focal bleeding site on the anterior rectal wall (1)	Adrenaline + polidocanol followed by elastic band ligation	Recovered
Katsinelos et al <sup>11</sup> (2009)	Greece	1	59	2 hours	2	Not reported	Manual compression and rectal tamponade with balloon inflation	Colonoscopy	Unprepped	Two focal bleeding points in anterior rectal wall	Argon plasma coagulation Endoclipping	Recovered, 2 days
Özveren et al <sup>10</sup> (2013)	Turkey	1	61	24 hours	3	Acetylsalicylic acid	Rectal gauze tamponade	Flexible sigmoidoscopy	Unprepped	Pulsatile bleeding from rectal mucosa	Epinephrine followed by endoclipping	Recovered, 1 day
Ando et al <sup>12</sup> (2018)	Japan	1	75	Multiple episodes after 3, 5, and 16 days	14	Aspirin	Digital compression	Colonoscopy	Not specified	Pulsatile bleeding on the anterior rectal wall	Endoclipping	Bleeding recurrence treated with angiography
Mahmud and Wangenstein <sup>9</sup> (2018)	USA	1	77	4 days	7	Not reported	Clinical monitoring	Flexible sigmoidoscopy	500-mL tap water enema	Pulsatile bleeding lesion with an adherent clot on a large internal hemorrhoid	Epinephrine injection + band ligation	Recovered, 5 days
The present report	USA	1	69	30 hours	2	None	Digital compression	Flexible sigmoidoscopy	PEG prep	2-cm bulge on the anterior rectal wall	Endoclipping	Recovered, 6 months

Abbreviations: NSAIDs, nonsteroidal anti-inflammatory drugs; PEG, polyethylene glycol.

Rectal bleeding is an established complication of the TRUS-guided prostate biopsy procedure. It is frequently categorized as a Clavien-Dindo Grade 1 complication, but rarely, it can result in Grade 2 (eg, blood transfusion required) to Grade 4 (eg, organ dysfunction and intensive care unit admission) adverse events.<sup>1</sup> It has traditionally been treated by the urologist. Direct digital compression is commonly used for hemorrhage that occurs shortly after the biopsy. In patients refractory to this maneuver, several therapeutic techniques such as compression by means of rectal packing or urinary catheter balloon inflation are described in the urology literature.<sup>1,40</sup> The use of anoscopy to identify the bleeding site and subsequent application of transrectal suturing has also been reported.<sup>41</sup> Currently, endoscopic hemostasis can be attempted after the failure of conservative methods. However, it is an unusual observation that endoscopic treatment of this complication remains relatively uncommon. Due to these factors, gastroenterology publications regarding endoscopic therapy for post-biopsy rectal bleeding are scarce.

Endoscopic injection sclerotherapy has frequently been employed in patients with massive rectal bleeding.<sup>42</sup> Several sclerosants or constricting agents have been used in this regard. Initial epinephrine administration can be considered the next management step in patients with rectal bleeding refractory to traditional conservative methods.<sup>43</sup> The usual doses are reported to be 25 mL of 1:10000 epinephrine solution.<sup>43,44</sup> In a case series of 550 participants, Brullet and colleagues<sup>45</sup> showed that 5 (1%) patients developed rectal hemorrhage and hemodynamic changes shortly after TRUS-guided biopsy. The endoscopic management using epinephrine and/or polidocanol injections was successful in achieving permanent hemostasis.<sup>45</sup> Similarly, a combination of epinephrine and ethanol may also be administered. In addition, 1% atroxysclerol has also been reported for endoscopic hemostasis in post-biopsy rectal bleeding.<sup>46</sup>

Endoscopic thermocoagulation is a hemostatic technique that is used to control gastrointestinal bleeding by contact or noncontact methods. Bipolar and heater probes are examples of contact thermocoagulation, whereas argon plasma coagulation is a noncontact technique. Prior anecdotal reports described the use of a 10 F multipolar heater probe with 5 pulses of 2 to 4 seconds for post-biopsy rectal bleeding.<sup>6</sup> Similarly, multiple studies reported successful hemostasis with argon plasma coagulation in severe hemorrhage.<sup>47,48</sup> Notably, contact methods may lead to adverse events such as transmural gastrointestinal injury. Therefore, noncontact thermocoagulation constitutes a relatively safe procedure as it mostly elicits superficial tissue injury. Endoscopic band ligation is another hemostatic modality.<sup>49</sup> This technique particularly helps to achieve hemostasis in cases where the culprit is a submucosal visible bleeding vessel.<sup>50</sup> It may offer added therapeutic benefit in rectal hemorrhage due to punctured internal hemorrhoids after prostate biopsy.<sup>50</sup> However, band ligation has been associated with a prolonged procedural time due to technical complexity and rebleeding following

mucosal ulcer formation. Combination endoscopic therapy, consisting of varying combinations of epinephrine injection, endoclipping, and/or endoscopic band ligation, has also been used with good clinical outcomes.<sup>8,48,49</sup>

The use of endoclipping has been widely reported in gastrointestinal endoscopy. However, the placement of endoclips alone for post-biopsy rectal bleeding has rarely been described thus far. Therefore, the long-term efficacy of this method has not been studied in this patient group. In the 2 previously described cases, one patient achieved adequate hemostasis with endoclipping alone while one required a subsequent embolization procedure.<sup>11,12</sup> Endoclipping can also be used in combination with epinephrine injection.<sup>10</sup> In patients with rectal Dieulafoy's lesion, endoscopic hemoclipping with or without epinephrine achieved a higher primary hemostasis rate (91%) and a lower rebleeding rate (9%) than other endoscopic modalities.<sup>51</sup> Therefore, endoclipping may have a slight therapeutic superiority for bleeding rectal lesions.<sup>52</sup> In light of these results, this technique may facilitate effective endoscopic management of prostate biopsy-related rectal bleeding.<sup>53</sup> The application of endoclip is technically feasible and offers considerable procedural safety. It dislodges spontaneously and is passed in feces without complications.

A TRUS-guided prostate biopsy still remains a commonly performed investigation in the era of prostate-specific antigen testing. Therefore, it is imperative for gastroenterologists to have updated knowledge of possible massive and life-threatening rectal hemorrhage. In these patients, major risk factors for hemorrhagic complications include advanced age, uncontrolled hypertension, constipation, and the number of core biopsies obtained.<sup>1</sup> The association between rectal bleeding and the use of antiplatelet drugs remains controversial.<sup>1</sup> Previous research has shown that there is no significant difference in the risk of bleeding in patients taking low-dose aspirin.<sup>54,55</sup> Raheem and colleagues<sup>56</sup> demonstrated that the discontinuation of antiplatelet or anticoagulant agents was unnecessary in patients undergoing prostate biopsy. In terms of rectal bleeding, there was no difference between the group of patients taking such medications and the control group (40% vs 39%, respectively). This observation points to the causal mechanism involving direct arterial injury rather than a deficit in the coagulation pathways in these patients. The knowledge of the aforementioned risk factors may facilitate early detection and treatment. An appropriate management algorithm consisting of prompt consultation with gastroenterology should be considered. Early endoscopic therapy can spare patients with massive rectal hemorrhage from bleeding-related morbidity and mortality, without the need for surgical intervention. Furthermore, unexpectedly long hospital stays and recurrent hemorrhagic episodes can be avoided, potentially saving valuable hospital resources. Future research should stratify the risks and benefits of various endoscopic therapeutic techniques in patients with post-biopsy rectal bleeding in large multicenter studies.

## Conclusion

Major rectal bleeding following TRUS-guided prostate biopsy remains rare. Based on the most recent information from the limited number of studies, endoscopic therapy may prove to be an effective option in the management of severe rectal hemorrhage in these patients. A consensus on optimal endoscopic technique does not exist, but endoclipping can be a useful tool. The timing of intervention is a crucial factor in controlling the bleeding. In cases of significant drop in hemoglobin or massive rectal bleeding refractory to conservative treatments, it is essential to consider an urgent endoscopic evaluation and treatment. Therefore, urologists should be encouraged to consult gastroenterologists in a timely manner for early management. Future research should compare the efficacy, cost, and morbidity of several endoscopic methods.

## Acknowledgments

The authors thank Dr Daniyal Ishtiaq for his invaluable editorial assistance.

## Author Contributions

AM: Conception and design of the study; performing the literature review; and drafting, reviewing, and revising the manuscript critically for important intellectual content.

RI: Acquiring patient data, contribution to the case presentation, and drafting and reviewing the manuscript.

MHNG: Performing the literature review, analysis of published data for the work, contribution to the introduction, and revision of the manuscript.

FI: Design of the study, reviewing the literature, interpretation of the previously published data, contribution to the discussion, formulation of the data tables, and drafting of the manuscript.

VVG: Reviewing and improving the manuscript by suggesting pertinent modifications, and drafting and revising the work.

All authors read and approved the final manuscript, and are accountable for all aspects of the work.

## Declaration of Conflicting Interests

The author(s) declared no potential conflicts of interest with respect to the research, authorship, and/or publication of this article.

## Funding

The author(s) received no financial support for the research, authorship, and/or publication of this article.

## Ethics Approval

Our institution does not require ethical approval for reporting individual cases or case series.

## Informed Consent

Verbal informed consent was obtained from the patient for their anonymized information to be published in this article.

## ORCID iD

Faisal Inayat  <https://orcid.org/0000-0001-7576-7319>

## References

1. Quinlan MR, Bolton D, Casey RG. The management of rectal bleeding following transrectal prostate biopsy: a review of the current literature. *Can Urol Assoc J.* 2018;12:E146-E153.
2. Al-Otaibi MF, Al-Taweel W, Bin-Saleh S, Herba M, Aprikian AG. Disseminated intravascular coagulation following transrectal ultrasound-guided prostate biopsy. *J Urol.* 2004;171:346.
3. Seymour MA, Oesterling JE. Anterior rectal wall hematoma: complication of transrectal ultrasound-guided biopsy of prostate. *Urology.* 1992;39:177-181.
4. Choyke PL, Blei CL, Jaffe MH, Zeman RK, Lieberman M. Prevesical hematoma: a complication of prostatic biopsy. *Urol Radiol.* 1986;8:32-34.
5. Toren P, Razik R, Trachtenberg J. Catastrophic sepsis and hemorrhage following transrectal ultrasound-guided prostate biopsies. *Can Urol Assoc J.* 2010;4:E12-E14.
6. Kinney TP, Kozarek RA, Ylvisaker JT, Gluck M, Jiranek GC, Weissman R. Endoscopic evaluation and treatment of rectal hemorrhage after prostate biopsy. *Gastrointest Endosc.* 2001;53:117-119.
7. Inayat F, Aslam A, Grunwald MD, Hussain Q, Hurairah A, Iqbal S. Omental patching and purse-string endosuture closure after endoscopic full-thickness resection in patients with gastric gastrointestinal stromal tumors. *Clin Endosc.* 2019;52:283-287.
8. Inayat F, Weissman S, Malik A, Munir B, Iqbal S. Endoscopic submucosal tunnel dissection as a novel therapeutic technique in patients with Barrett's esophagus. *J Investig Med High Impact Case Rep.* 2020;8:2324709620941318.
9. Malik A, Inayat F, Goraya MHN, et al. Jejunal Dieulafoy's lesion: a systematic review of evaluation, diagnosis, and management. *J Investig Med High Impact Case Rep.* 2021;9:2324709620987703.
10. Özveren B, Türkeri L. Massive rectal bleeding after prostate biopsy controlled by endoclipping in a patient using acetylsalicylic acid. *Can Urol Assoc J.* 2013;7:E442-E444.
11. Katsinelos P, Kountouras J, Dimitriadis G, et al. Endoclipping treatment of life-threatening rectal bleeding after prostate biopsy. *World J Gastroenterol.* 2009;15:1130-1133.
12. Ando T, Watanabe K, Mizusawa T, Katagiri A. Late-onset rectal bleeding with hemorrhagic shock after transrectal prostate needle biopsy. *Uro Case Rep.* 2018;21:41-43.
13. Moher D, Liberati A, Tetzlaff J, Altman DG; PRISMA Group. Preferred reporting items for systematic reviews and meta-analyses: the PRISMA statement. *PLoS Med.* 2009;6:e1000097.
14. Gustafsson O, Norming U, Nyman CR, Ohstrom M. Complications following combined transrectal aspiration and core biopsy of the prostate. *Scand J Urol Nephrol.* 1990;24:249-251.
15. Collins GN, Lloyd SN, Hehir M, McKelvie GB. Multiple transrectal ultrasound guided biopsies: true morbidity and patient acceptance. *Br J Urol.* 1993;71:460-463.

16. Clements R, Aideyan OU, Griffiths GJ, Peeling WB. Side effects and patient acceptability of transrectal biopsy of the prostate. *Clin Radiol*. 1993;47:125-126.
17. Aus G, Hermansson CG, Hugosson J, Pedersen KV. Transrectal ultrasound examination of the prostate: complications and acceptance by patients. *Br J Urol*. 1993;71:457-459.
18. Amo FH, Fernandez ER, Cordero JMD, et al. Morbidity of and tolerance to ultrasonography-guided transrectal biopsy of the prostate [in Spanish]. *Acta Urol Esp*. 1996;2:858-866.
19. Hammemer P, Huland H. Systematic sextant biopsies in 651 patients referred for prostate evaluation. *J Urol*. 1994;151:99-102.
20. Enlund AL, Varenhorst E. Morbidity of ultrasound-guided transrectal core biopsy of the prostate without prophylactic antibiotic therapy. A prospective study in 415 cases. *Br J Urol*. 1997;79:777-780.
21. Rietbergen JB, Kruger AE, Kranse R, Schröder FH. Complications of transrectal ultrasound-guided systematic sextant biopsies of the prostate: evaluation of complication rates and risk factors within a population-based screening program. *Urology*. 1997;49:875-880.
22. Rodriguez LV, Terris MK. Risks and complications of transrectal ultrasound guided prostate needle biopsy: a prospective study and review of the literature. *J Urol*. 1998;16:2115-2120.
23. Deliveliotis C, John V, Louras G, et al. Multiple transrectal ultrasound guided prostatic biopsies. Morbidity and tolerance. *Int Urol Nephrol*. 1999;31:681-686.
24. Herget EJ, Saliken JC, Donnelly BJ, Gray RR, Wiseman D, Brunet G. Transrectal ultrasound-guided biopsy of the prostate: relation between ASA use and bleeding complications. *Can Assoc Radiol J*. 1999;5:173-176.
25. Crundwell MCAU, Cooke PWAU, Wallace DMTI. Patients tolerance of transrectal ultrasound-guided prostatic biopsy: an audit of 104 cases. *BJU Int*. 1999;83:792-795.
26. Peters JL, Thompson AC, McNicholas TA, Hines JE, Hanbury DC, Boustead GB. Increased patient satisfaction from transrectal ultrasonography and biopsy under sedation. *BJU Int*. 2001;87:827-830.
27. Djavan B, Waldart M, Zlotta A, et al. Safety and morbidity of first and repeat transrectal ultrasound guided prostate needle biopsies: results of a prospective European prostate cancer detection study. *J Urol*. 2001;166:856-860.
28. Manseck A, Guhr K, Froehner M, Hakenberg OW, Wirth MP. Morbidity and discomfort of ten-core biopsy of the prostate evaluated by questionnaire. *Urol Int*. 2001;66:197-200.
29. Makinen T, Auvinen A, Hakama M, Stenman UH, Tammela TL. Acceptability and complications of prostate biopsy in population-based PSA screening versus routine clinical practice: a prospective, controlled study. *Urology*. 2002;60:846-850.
30. Raaijmakers R, Kirkels WJ, Roobol MJ, Wildhagen MF, Schroder FG. Complication rates and risk factors of 5802 transrectal ultrasound guided sextant biopsies of the prostate within a population based screening program. *Urology*. 2002;60:826-830.
31. Chiang IN, Chang SJ, Pu YS, Huang KH, Yu HJ, Huang CY. Major complications and associated risk factors of transrectal ultrasound guided prostate needle biopsy: a retrospective study of 1875 cases in Taiwan. *J Formos Med Assoc*. 2007;106:929-934.
32. Efesoy O, Bozlu M, Çayan S, Akbay E. Complications of transrectal ultrasound-guided 12-core prostate biopsy: a single center experience with 2049 patients. *Turk J Urol*. 2013;39:6-11.
33. Wei TC, Lin TP, Chang YH, Chen TJ, Lin AT, Chen KK. Transrectal ultrasound-guided prostate biopsy in Taiwan: a nationwide database study. *J Chin Med Assoc*. 2015;78:662-665.
34. Park BH, Kim JI, Bae SR, Lee YS, Kang SH, Han CH. The effect of ultrasound-guided compression immediately after transrectal ultrasound-guided prostate biopsy on postbiopsy bleeding: a randomized controlled pilot study. *Int Urol Nephrol*. 2017;49:1319-1325.
35. Cheong IS, Lin CT, Jou YC, Cheng MC, Shen CH, Chen PC. One day hospitalization for trans-rectal ultrasound guided prostate biopsy: experiences of a single institution. *Urol Sci*. 2017;28:235-239.
36. Cheng KC, Lam WC, Chan HC, et al. Emergency attendances and hospitalisations for complications after transrectal ultrasound-guided prostate biopsies: a five-year retrospective multicentre study. *Hong Kong Med J*. 2019;25:349-355.
37. Lo KL, Chui KL, Leung CH, et al. Outcomes of transperineal and transrectal ultrasound-guided prostate biopsy. *Hong Kong Med J*. 2019;25:209-215.
38. Antoine CM, Morrison BF, Brooks ME. Complications of prostate biopsy: a prospective, single-institution study. *JAMMR*. 2020;32:271-279.
39. Joshi R. Transrectal ultrasound guided prostatic biopsy and its complications: a descriptive cross-sectional study. *JNMA J Nepal Med Assoc*. 2020;58:44-47.
40. Khan SA, Hu KN, Marder C, Smith NL. Hemorrhoidal bleeding following transrectal prostate biopsy. *Dis Colon Rectum*. 1982;25:817-819.
41. Hodge KK, McNeal JE, Stamey TA. Ultrasound guided transrectal biopsies of the palpably abnormal prostate. *J Urol*. 1991;142:1308-1312.
42. Braun KP, May M, Helke C, Hoschke B, Ernst H. Endoscopic therapy of a massive rectal bleeding after prostate biopsy. *Int Urol Nephrol*. 2007;39:1125-1129.
43. Baum RD, Slade M. Use of Foley balloon tamponade in transrectal prostate biopsy hemorrhage. *Urology*. 1988;32:181.
44. Pacios E, Esteban JM, Breton ML, Alonso MA, Sicilia-Urbán JJ, Fidalgo MP. Endoscopic treatment of massive rectal bleeding following transrectal ultrasound-guided prostate biopsy. *Scand J Urol Nephrol*. 2007;41:561-562.
45. Brullet E, Guevara MC, Campo R, et al. Massive rectal bleeding following transrectal ultrasound-guided prostate biopsy. *Endoscopy*. 2000;32:792-795.
46. Ustündağ Y, Yeşilli C, Aydemir S, Savranlar A, Yazicioğlu K. A life-threatening hematochesia after transrectal ultrasound-guided prostate needle biopsy in a prostate cancer case presenting with lymphedema. *Int Urol Nephrol*. 2004;36:397-400.
47. Geraci G, Sciumè C, Pisello F, Facella T, Modica G. Severe rectal bleeding after transrectal US-guided prostate biopsy. Case report [in Italian]. *G Chir*. 2006;27:321-323.
48. Arroja B, Gonçalves C, Silva F, Cotrim I, Vasconcelos H. Major rectal bleeding following transrectal needle prostate biopsy. *Endoscopy*. 2009;41(suppl 2):E145.



49. Mahmud N, Wangenstein KJ. Endoscopic band ligation to treat a massive hemorrhoidal hemorrhage following a transrectal ultrasound-guided prostate biopsy. *Ann Coloproctol*. 2018;34:47-51.
50. Strate LL, O'Leary MP, Carr-Locke DL. Endoscopic treatment of massive rectal bleeding following prostate needle biopsy. *Endoscopy*. 2001;33:981-984.
51. Inayat F, Hussain A, Yahya S, et al. Rectal Dieulafoy's lesion: a comprehensive review of patient characteristics, presentation patterns, diagnosis, management, and clinical outcomes. *Transl Gastroenterol Hepatol*. Published online March 2020. doi:10.21037/tgh.2020.02.17
52. Inayat F, Ullah W, Hussain Q, Abdullah HMA. Dieulafoy's lesion of the colon and rectum: a case series and literature review. *BMJ Case Rep*. 2017;2017:bcr2017220431.
53. Raju GS, Gajula L. Endoclips for GI endoscopy. *Gastrointest Endosc*. 2004;59:267-279.
54. Giannarini G, Mogorovich A, Valent F, et al. Continuing or discontinuing low-dose aspirin before transrectal prostate biopsy: results of a prospective randomized trial. *Urology*. 2007;70:501-505.
55. Kariotis I, Philippou P, Volanis D, Serafetinides E, Delakas D. Safety of ultrasound-guided transrectal extended prostate biopsy in patients receiving low-dose aspirin. *Int Braz J Urol*. 2010;36:308-316.
56. Raheem OA, Casey RG, Galvin DJ, et al. Discontinuation of anticoagulant or antiplatelet therapy for transrectal ultrasound-guided prostate biopsies: a single-center experience. *Korean J Urol*. 2012;53:234-239.