

ORIGINAL PAPER

doi: 10.5455/medarh.2020.74.105-108

MED ARCH. 2020 APR; 74(2): 105-108

RECEIVED: JAN 18, 2020 | ACCEPTED: MAR 30, 2020

¹Eye Clinic "Svjetlost", Sarajevo, Bosnia and Herzegovina²University Eye Hospital "Svjetlost" Zagreb, School of Medicine University of Rijeka, Croatia

Corresponding author: Alma Biscevic, MD, PhD. University Eye Hospital Svjetlost Zagreb, School of Medicine University of Rijeka, Croatia. Address: Heinzelova 39, 10 000 Zagreb. E-mail: alma.biscevic@svjetlost.hr, alma@svjetlost-sarajevo.ba. ORCID: 0000-0002-6496-2853.

Pachymetry and Elevation Back Map Changes in Keratoconus Patients After Crosslinking Procedure

Melisa Ahmedbegovic Pjano¹, Alma Biscevic^{1,2}, Senad Grisevic¹, Ivan Gabric², Ajla Skopljak Salkica¹, Nina Ziga¹

ABSTRACT

Introduction: The crosslinking (CXL) procedure using the standard Dresden protocol is established as the gold standard for the treatment of progressive keratoconus. **Aim:** The aim of this paper is to correlate the pachymetry and elevation back map (EBM) changes in the period from 3 to 12 months of keratoconus patients after the CXL procedure. **Methods:** Forty-four eyes of 34 patients with keratoconus were analyzed after performed standard Dresden protocol CXL procedure. All of them underwent complete preoperative examination with a follow up of 12 months with a focus on pachymetry and EBM changes performed by Oculus Pentacam (Scheimpflug technology) analysis. **Results:** Pachymetry changed significantly in 12 months post cross-linking, especially in the first 6 months after which it slightly increased. Differences in EBM preoperatively and 12 months postoperatively were not statistically significant. **Conclusion:** Corneal pachymetry in keratoconus patients decreases after the CXL procedure. Differences in pachymetry preoperatively and 3, 6 and 12 months postoperatively were statistically significant, but the value of corneal thickness increased from the third month to 12 months post-op. Differences in EBM preoperatively and 12 months postoperatively were not still statistically significant, which is good, because the increase in elevation, as one of the signs of progression of the keratoconus - did not occur.

Keywords: corneal cross-linking, keratoconus, pachymetry, elevation back map.

1. INTRODUCTION

Keratoconus is a chronic, bilateral, non-inflammatory disorder characterized by progressive steepening, thinning and apical scarring of the cornea (1). It is considered to be a noninflammatory corneal disorder characterized by changes in corneal collagen structure and organization (2). A reduced number of collagen cross-links and pepsin digestion higher than normal induce an overall structural weakness of the corneal tissue, resulting in stiffness that is only 60% that of the normal cornea (3). Decreased mechanical corneal stability plays an important role in the progressive protrusion of the keratoconic cornea, resulting in mild to marked impairment of visual acuity owing to irregular astigmatism, progressive myopia, corneal thinning, and central corneal scarring (1). Corneal topography remains the gold standard to evaluate ectatic diseases (4). Corneal pachymetry - corneal thinning is a key pathologic feature of keratoconus; therefore, a keratoconus diagnosis based on corneal thickness measurement may offer

additional information not available on topography. Corneal thickness has been proposed to be a useful parameter for the clinical identification of keratoconus. The posterior surface of the cornea is not optically as important as the anterior surface (5), but it is structurally more fluid and therefore a sensitive indicator of abnormality. This occurs because corneal lamellar disposition and proteoglycan composition allow posterior fibers to buckle inward, while anterior fibers remain under tension and retain their shape. Often, rather than the magnitude of the posterior irregularity, the posterior elevation map is a better indicator of corneal instability whether due to disease, healing or ectasia. Keratoconus management has significantly changed over the last two decades. The advent of new interventions such as cornea cross-linking, intrastromal corneal ring segments, and combined treatments provide corneal clinicians a variety of treatment options for the visual rehabilitation of keratoconus patients (6). Collagen cross-linking (CXL) is the treatment that increas-

© 2020 Melisa Ahmedbegovic Pjano, Alma Biscevic, Senad Grisevic, Ivan Gabric, Ajla Skopljak Salkica, Nina Ziga

This is an Open Access article distributed under the terms of the Creative Commons Attribution Non-Commercial License (<http://creativecommons.org/licenses/by-nc/4.0/>) which permits unrestricted non-commercial use, distribution, and reproduction in any medium, provided the original work is properly cited.

es the biomechanical strength of the human cornea by about 300% by the combined action of a photosensitizing substance (riboflavin) and ultraviolet (UV) light from a solid-state UVA source (7). The treatment creates additional chemical bonds inside the anterior 200-300 microns of the corneal stroma using photopolymerization. There is minimal exposure to the surrounding structures of the eye (8). Collagen cross-linking increases the resistance to pepsin digestion by enhancing corneal anti collagenase activity and induces a thicker collagen fiber diameter (9). Posterior measurements are often the first indicators of future ectatic disease, despite completely normal anterior curvature. Examination of the posterior corneal surface can often reveal pathology that would otherwise be missed if one was relying on anterior analysis alone.

2. AIM

The aim of this paper is to correlate the pachymetry and elevation back map (EBM) changes in the period from 3 to 12 months of keratoconus patients after the CXL procedure.

3. PATIENTS AND METHODS

Forty-four eyes of 34 patients with manifest keratoconus were included in this study. This was a prospective study that enrolled patients treated with CXL at Eye Clinic Svjetlost Sarajevo from January 2017 to January 2018. Twenty-four of them had a procedure performed on one eye, and 10 patients had binocular treatments. Informed consent was obtained from every patient before surgery. Inclusion criteria were: patients diagnosed with keratoconus and progression of the steepest meridian of 1 diopter (D) or more within a year, but not more than 60 D, a subjective decrease of visual acuity (VA), CDVA of 0.8 or less, age frame of 15 to 40 years, and pachymetry of 400 micrometers (μm) or more. Every patient had a complete preoperative ophthalmological examination before deciding if the patient met the criteria for the study. Topography measurements of the keratoconic corneas were taken with a high-resolution imaging system that uses a rotating Scheimpflug camera (Pentacam, Oculus Optikgeräte GmbH, Wetzlar, Germany). Scheimpflug imaging provides the measurement of the entire cornea thickness by determining the front and back surfaces of the cornea. Keratoconic eyes have thinner corneas than normal eyes, with less volume and a more gradual increase in these parameters from the thinnest point toward the periphery (10). Corneal thickness is defined as the thinnest point in the corneal thickness map. The elevation map is defined as the height of the cornea about the "best fit sphere," or the radius of curvature that best matches the average curvature of the map. Elevation maps measure corneal height in micrometers and have a counterintuitive interpretation (11). The posterior elevation maps were evaluated and posterior corneal elevation values from the corneal apex were analyzed. Elevation based Scheimpflug imaging has advantages over Placido based systems in that it allows measurements of both the ante-

rior and posterior corneal surfaces and the computation of a complete pachymetric map.

Surgical technique

CXL therapeutical protocol was performed using the model of Dresden protocol. Before the surgery treated eye was cleaned with povidone iodide, the speculum was placed on the eyelids and anesthetic and miotic drops were instilled to protect the inner part of the eye from UVA radiation. Then using a spatula, mechanical debridement of 8-9 mm of corneal epithelium under local anesthesia was performed. After that application of topical vitamin B2-riboflavin 0.1% solution (Riboflavin, Ricrolin, Peschke Meditrade) was used every 2 minutes during the first 30 minutes in combination with balanced salt solution (BSS). Then UVA radiation starts. Before radiation, ultrasonic pachymetry was necessary to confirm that the thinnest part of the stroma is not less than 400 μm . If pachymetry was less than that, hypotonic riboflavin (0.1% in a sterile solution, Medio Cross hypotonic) was used in intervals of 10 seconds. This was repeated until the pachymetry was not at least 400 μm . This least diameter has been shown in the literature to keep the posterior structures protected from UVA radiation. The wavelength of UVA was arranged at 365 nm (UVX system), with an energy intensity of 3 mW/cm². UVA radiation treatment lasts for 30 minutes, and during the treatment riboflavin drops and BSS were used the same way as mentioned before. After the surgery antibiotic and corticosteroids, both topically were used, and a bandage contact lens was inserted. The contact lens was removed 3-5 days after the treatment, depending on epithelium healing. Drops were used during the first postop month. Patient follow up was first 3 days in a row, then 1 week, 1 month, 3 months, 6 months and 12 months after the procedure.

4. RESULTS

Pachymetry

Differences in pachymetry preoperatively and 3 months postoperatively were statistically significant, $p=0.0001$. Preop pachy was 451.36 ± 28.25 micrometers (μm), while 3 months postop it decreased to 418.18 ± 35.79 μm . Six months of postop differences in pachy were also statistically significant $p=0.0001$, where pachymetry decreased to 418.86 ± 41.01 . After 12 months of follow up, postop differences are still statistically significant, $p=0.0001$, and values were 431.86 ± 36.78 . The results are presented in Table 1 and Figure 1.

Pachymetry	Mean	Std. Deviation	Std. Error Mean
Preop	451.36	28.251	6.023
3 months	418.18	35.789	7.630
Preop	451.36	28.251	6.023
6 months	418.86	41.011	8.744
Preop	451.36	28.251	6.023
12 months	431.86	36.775	7.840

Table 1. Pachymetry values preoperatively and 3,6 and 12 months postoperatively

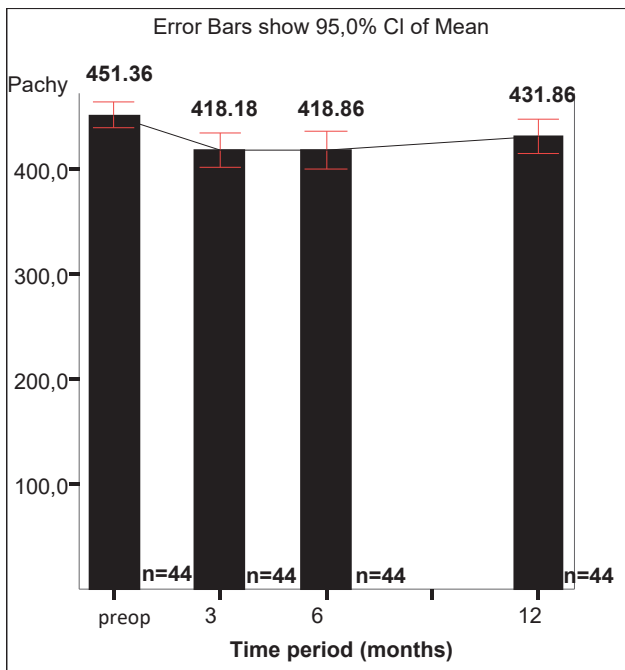


Figure 1. Error bars of pachymetry preoperatively and 12 months postoperatively after CXL

Elevation back map (EBM)

Differences in EBM preoperatively and 3 months postoperatively were statistically significant, $p=0.017$. Preop EBM was 63.77 ± 20.52 , while 3 months postop it decreased to 58.82 ± 21.04 . Six months postop differences in EBM were not statistically significant, $p=0.582$, where EBM increased to 65.09 ± 20.94 . After 12 months of follow up postop differences were not still statistically significant, $p=0.527$, and values were 65.09 ± 19.82 . The results are presented in Table 2 and Figure 2.

Elevation back map (EBM)	Mean	Std. Deviation	Std. Error Mean
Preop	63.77	20.517	4.374
3 months	58.82	21.039	4.485
Preop	63.77	20.517	4.374
6 months	65.09	20.937	4.464
Preop	63.77	20.517	4.374
12 months	65.09	19.816	4.225

Table 2. Elevation back map (EBM) preoperatively and 3,6 and 12 months postoperatively

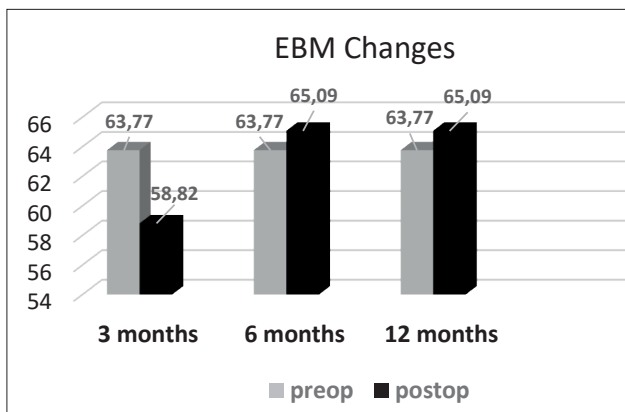


Figure 2. EBM changes preoperatively and after follow up of 12 months

5. DISCUSSION

Studies (12) have reported that the repeatability of pachymetry measurements taken by Pentacam was high. Pachymetry and elevation parameters show high repeatability and reproducibility in several studies where posterior elevation measurements are more accurate in detecting keratoconus (13). Ambrósio et al. introduced the analysis of corneal thickness spatial profiles and demonstrated significant differences in absolute thickness and percentage thickness increase as a function of distance from the thinnest point between normal and KC eyes (14). In our study pachymetry at baseline was 451.36 ± 28.25 micrometers (μm), and at 12 months it decreased to $431.86 \pm 36.78 \mu\text{m}$ (difference was statistically significant $p < 0.0001$). Henriques et al. performed CXL for treatment of keratoconus and found that mean pupil center pachymetry measured using Pentacam optical pachymetry at baseline, was $490.68 \pm 30.69 \mu\text{m}$. At 12 months they had decreased to $470.09 \pm 29.01 \mu\text{m}$, a significant difference ($p < 0.05$) (15). Their results are similar to our study. Collagen fiber compression, changes in corneal hydration and edema, keratocyte apoptosis and changes in glycosaminoglycans may play an important role in defining corneal thickness (16). CXL affects central cornea more than periphery; so more decrease in pachymetry compared with periphery induces an increased average progression index. The rotating Scheimpflug device we used measures posterior elevation by fitting the best-possible sphere to the posterior cornea. It is believed that the first sign of ectasia is an alteration in the posterior corneal shape (17). Sedaghat et al. (18) reported that anterior BFS and elevation did not change significantly after CXL, however, posterior BFS and elevation increased 6 months postoperatively, and remained stable during the 12 months follow-up. An increase in posterior elevation can reduce corneal dioptric power and myopia in patients, which may have a role in improved postoperative visual acuity. Our study showed that differences in elevation back map preoperatively 63.77 ± 20.52 and 12 months postoperatively were not still statistically significant, $p=0.527$, and values were 65.09 ± 19.82 . Our results are similar to Sedaghat’s research. However, Grewal et al. (19) reported that the corneal surface remained stable, and anterior and posterior elevation did not change after CXL. In another study, 80% of the 10 eyes, that had undergone CXL to treat keratoconus, showed a decrease in the anterior and posterior elevation, respectively at the end of the 12 months follow-up (15). The controversy in these results may partially be explained by the difference in the devices used for analyzing corneal elevation.

6. CONCLUSION

Corneal pachymetry in keratoconus patients decreases after the CXL procedure. That is one of the reasons why minimal pachymetry before CXL should be at least 400 microns. Differences in pachymetry preoperatively and 3, 6 and 12 months postoperatively were statistically significant, but the value of corneal thickness increased from the third month to 12 months post-op. Our study showed that differences in elevation back map preopera-

tively and 12 months postoperatively were not still statistically significant, which is good, because the increase in elevation, as one of the signs of progression of the keratoconus - did not occur.

- **Author's contribution:** All the authors gave substantial contributions to the conception or design of the work in acquisition, analysis, or interpretation of data for the work. All authors had a part in article preparing for drafting or revising it critically for important intellectual content, and gave final approval of the version to be published and agreed to be accountable for all aspects of the work in ensuring that questions related to the accuracy or integrity of any part of the work are appropriately investigated and resolved.
- **Conflicts of interest:** There are no conflicts of interest.
- **Financial support and sponsorship:** None.

REFERENCES

1. Rabinowitz YS. Keratoconus. *Surv Ophthalmol* 1998; 42(4): 297-319.
2. Cheng EL, Maruyama I, SundarRaj N, et al. Expression of type XII collagen and hemidesmosome-associated proteins in keratoconus corneas. *Curr Eye Res*. 2001; 22(5): 333-340.
3. Radner W, Zehetmayer M, Skorpik Ch, Mallinger R. Altered organization of collagen in apex of keratoconus corneas. *Ophthalmic Res*. 1998; 30(5): 327-332.
4. Turner T. What corneal topography can tell you about corneal shape. In: *Customized corneal ablation: The quest for super-vision*. Grove Road: Slack Inc.; 2001: 221-227.
5. Ambrosio R, Jr, Alonso RS, Luz A, Coca Velarde LG. Corneal-thickness spatial profile and corneal-volume distribution: tomographic indices to detect keratoconus. *J Cataract Refract Surg*. 2006; 32(11): 1851-1859.
6. Andreassen TT, Simonsen AH, Oxlund H. Biomechanical properties of keratoconus and normal corneas. *Exp Eye Res* 1980; 31(4): 435-441.
7. Luce DA. Determining in vitro biomechanical properties of the cornea with an ocular response analyzer. *J Cataract Refract Surg*. 2005; 31(1): 156-162.
8. Wollensak G, Spoerl E, Seiler T. Increased resistance of riboflavin/ultraviolet-A treated cornea against enzymatic digestion. *Curr Eye Res*. 2004; 29(1): 35-40.
9. Spornl E, Huhle M, Kasper M, Seiler T. Increased rigidity of the cornea caused by intrastromal crosslinking. *Ophthalmologie*. 1997; 94(12): 902-906.
10. Ambrósio R. Jr., Alonso RS, Luz A, et al. Corneal-thickness spatial profile and corneal-volume distribution: tomographic indices to detect keratoconus. *J Cataract Refract Surg*. 2006; 32(11): 1851-1859.
11. Ucakhan OO, Cetinkor V, Ozkan M, Kanpolat A. Evaluation of Scheimpflug imaging parameters in subclinical keratoconus, keratoconus, and normal eyes. *J Cataract Refract Surg*. 2011; 37(4): 1116-1124.
12. Miranda MA, Radhakrishnan H, O'Donnell C. Repeatability of corneal thickness measured using an Oculus Pentacam. *Optom Vis Sci*. 2009; 86(3): 266-272.
13. de Sanctis U, Loiacono C, Richiardi L, Turco D, Mutani B, Grignolo FM. Sensitivity and specificity of posterior corneal elevation measured by Pentacam in discriminating keratoconus/subclinical keratoconus. *Ophthalmology* 2008; 115(9): 1534-1539.
14. AmbrósioR Jr., Caiado ALC, Guerra FP. et al. Novel pachymetric parameters based on corneal tomography for diagnosing keratoconus. *J Cataract Refract Surg*. 2011; 27(10): 753-758.
15. Henriquez MA, Izquierdo L Jr, Bernilla C et al. Riboflavin/Ultraviolet a corneal collagen cross-linking for the treatment of keratoconus: Visual outcomes and Scheimpflug analysis. *Cornea*. 2011; 30(3): 281-286.
16. Labiris G, Giarmoukakis A, Sideroudi H, Bougatsou P, Lazaridis I, Kozobolis VP. Variability in Scheimpflug image-derived posterior elevation measurements in keratoconus and collagen-crosslinked corneas. *J Cataract Refract Surg*. 2012; 38(9): 1616-1625.
17. Caporossi A, Mazzotta C, Baiocchi S, Caporossi T. Long-term results of riboflavin ultraviolet a corneal collagen cross-linking for keratoconus in Italy: The Siena eye cross study. *Am J Ophthalmol*. 2010; 14(9): 585-593.
18. Sedaghat M, Bagheri M, Ghavami S, Bamdad S. Changes in corneal topography and biomechanical properties after collagen cross linking for keratoconus: 1-year results. *Middle East Afr J of Ophthalmol*. 2015; 22(2): 212-219.
19. Grewal DS, Brar GS, Jain R, Sood V, Singla M, Grewal SP. Corneal collagen crosslinking using riboflavin and ultraviolet-A light for keratoconus: One-year analysis using Scheimpflug imaging. *J Cataract Refract Surg*. 2009; 35: 425-432.