

CASE REPORT

Spontaneous delivery through a cervical tear without cervical os dilatation

Dusan Djokovic, Cristina Costa, Ana Martins & Shadi Abushad

Serviço de Obstetrícia e Ginecologia, Hospital S. Francisco Xavier – CHLO, Lisbon, Portugal

Correspondence

Dusan Djokovic, Serviço de Obstetrícia e Ginecologia, Hospital de São Francisco Xavier – CHLO, Estrada do Forte do Alto do Duque, 1495-005 Lisbon, Portugal. Tel: + 351 91 66 99 603; Fax: + 351 210 431 422; E-mail: dusan.d.jokovic@gmail.com

Funding Information

BIAL - Portela & C^a, S.A. S. Mamede do Coronado, Portugal

Received: 16 December 2014; Revised: 27 June 2014; Accepted: 27 June 2014

Clinical Case Reports 2015; 3(1): 3–6

doi: 10.1002/ccr3.107

Consent: Patient has given her consent for the case report to be published.

Introduction

Cervical injuries represent frequent morbidities associated with vaginal deliveries [1]. The rates of intrapartum cervical lesions increase in the cases of nulliparity, precipitous labor, operative vaginal delivery, and cervical surgical interventions such as cervical cerclage during pregnancy [2]. Induction of labor also increases the probability of cervical damage [3].

Spontaneous deliveries through intrapartum cervical lesions have been documented in women with medical history of cervical interventions. These include loop electro-surgical excision procedure due to cervical intraepithelial neoplasia [4] and cervical cerclage in previous pregnancy [5, 6]. We report a case of cervical tearing without external os dilatation that occurred upon prostaglandin induction of labor in a woman with a history of voluntary interruption of pregnancy by cervical dilatation and uterine curettage (CD&C). The tear resulted in a spontaneous delivery of the fetus through the lesion and postpartum hemorrhage successfully treated by the lesion suture.

Key Clinical Message

Spontaneous delivery through a cervical tear, provoked by prostaglandin-induced uterine contractions, was described in a G2P0 woman with a history of cervical dilatation and uterine curettage. This rare complication with potentially serious maternal–fetal consequences can be predicted by an aberrant cervical response to prostaglandins in parturients with previous cervical interventions.

Keywords

Delivery through a cervical tear, intrapartum cervical lesions, labor induction, postpartum hemorrhage.

Case Presentation

A 39 year-old G2P0 woman, with a spontaneously conceived, singleton and uneventful pregnancy was admitted to our institution at 41 weeks of gestation for labor induction. Her past obstetric history revealed a voluntary interruption of pregnancy 13 years before, at 6 weeks, performed by CD&C without complications. There was no suggestive symptom or clinical evidence of any cervical lesion, consequent fibrosis, and stenosis. The patient menstrual history after the intervention did not reveal any deviation from normality. The speculum and digital examinations during the current pregnancy did not indicate any pathology. Neither relevant medical conditions nor abdominopelvic surgical interventions were reported.

The digital examination on admission revealed a 15 mm long, posteriorly oriented cervix of rigid consistency with a 5 mm wide external os and cephalic presentation. To promote cervical ripening, 2.5 mg of dinoprostone (i.e., prostaglandin E2 [PGE2]) were vaginally applied. However, no significant cervical changes

occurred during the *induction day 1*. Observing normal CTVG records without significant uterine contractility, 50 µg of misoprostol were vaginally given the next day (*induction day 2*). As presented in Figure 1, the regular uterine contractility was initiated nearly 4 h after the application of this prostaglandin E1 (PGE1) analog. The patient required analgesia and received loco-regional anesthesia. The establishment of regular uterus contractions coincided with spontaneous rupture of the membranes and resulted in cervical effacement. In contrast, no change of the external os occurred. It remained rigid and 5 mm dilated, as evidenced by serial digital assessments 0, 2, 4, and 5 h after the misoprostol application (Fig. 1, red dots). The next digital evaluation, performed ~45 min later, surprisingly indicated “a complete dilatation” with the presentation at the level of ischial spines (De Lee station 0). A healthy male newborn was vaginally delivered weighing 3355 g, with Apgar score 10/10. After the spontaneous placental removal, an intense vaginal bleeding drew attention. The uterus was well contracted while no ultrasonography signs of placental or fetal membrane retention were visualized. The examination with a speculum revealed that original cervical os remained closed. In parallel, a 4 cm wide, posterior cervical tear was observed from 4 to 9 o’clock without extension to the vaginal fornix, as schematically presented in Figure 2. The lesion had provided a gate out to the fetus and caused the hemorrhage. The suspicion of a significant lesion of the uterine corpus was rejected by the identification of the tear borders. Additionally, there were no clinical signs of

hemoperitoneum while ultrasonography confirmed the absence of free fluid in the abdominopelvic cavity. We achieved the hemostasis by repairing the lesion with a continuous suture using absorbable Vicryl® 1 (Ethicon, Somerville, NJ, USA). The permeability of the natural cervical os was indicated by the observation of spontaneous lochia drainage.

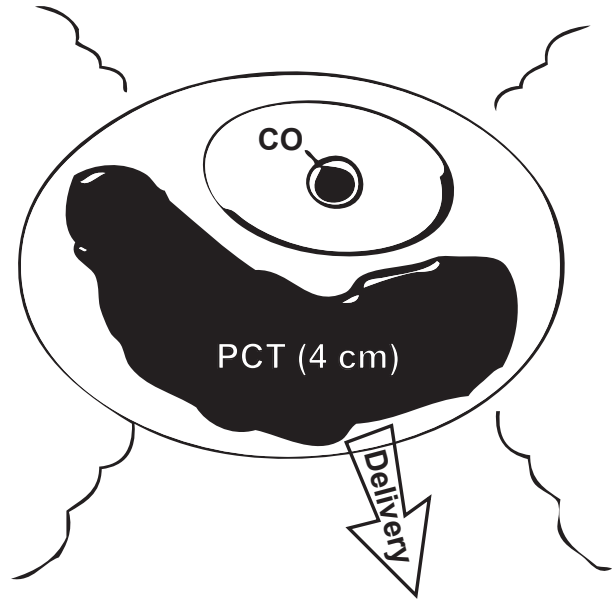


Figure 2. Schematic presentation of observed posterior cervical tear (PCT), below unopened cervical os (CO), that permitted spontaneous delivery of the fetus.

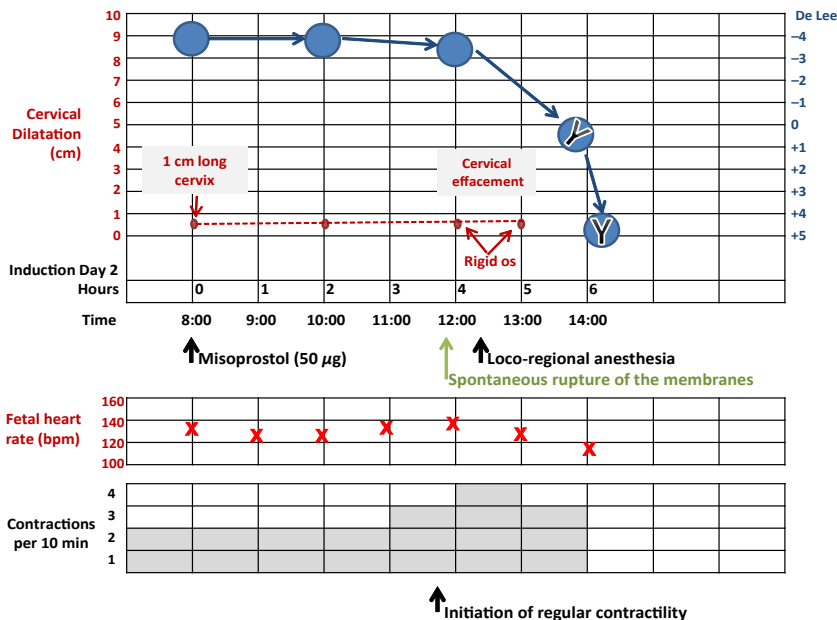


Figure 1. Bedside partogram (induction day 2).

The patient received oxytocin perfusion (20U) and 2 g of cefazolin. The hemorrhage resulted in a reduction of the hemoglobin level from 12.9 to 10.7 g/dL, thus the patient was also medicated with daily iron supplement. Having an uneventful postoperative course, the patient was discharged on day 3 postpartum and referenced to the Hospital's Unit for Puerperal Revision and Family Planning.

Discussion and Conclusions

Clinically significant lesions of the cervix occur in 0.2–1.7% of vaginal deliveries [1]. Cervical tears have been frequently reported with instrumental delivery, particularly when forceps was engaged. However, large tears that mimic a full dilatation and lead to fetus delivery are ultimate rarity.

Cervicovaginal fistula represents a complication of induced midtrimester termination of pregnancy, observed in the past to follow intraamniotic hypertonic saline injections and the use of prostaglandin F₂- α [5–7]. It is also a known complication of cervical cerclage [6, 8, 9]. There are reports of vaginal deliveries through these lesions leading to extension of the defect into the vaginal fornix, bladder or lower uterine segment [6, 9]. Besides, a spontaneous delivery through a cervical tear with an intact cervical os was reported in a patient with a history of cervical intraepithelial neoplasia which was treated with a loop electrosurgical excision procedure (LEEP) [4]. The cervical tearing occurred upon the labor induction with PGE₂. Differently, in two other reported cases with unmentioned medical history, large cervical tears coexisted with partially [10] or fully dilated cervixes [11]. Thus, cervical tearing in these cases probably occurred during, and not before the fetal passage.

In our patient, prostaglandins were used for labor induction as a standard method. It may be suspected that misoprostol itself resulted in observed cervical damage. Indeed, misoprostol increases the risk of corporal rupture in women with uterine scar [12]. Vaginal misoprostol can also decrease the macrophage function resulting in the overgrowth of clostridial organisms and developmental gangrene of gastrointestinal and reproductive tracts [13]. However, cervical lesions after prostaglandin application were more often reported in midtrimester abortions as highlighted before [5–7]. Generally, the drug allows appropriate cervical modification and fetal passage through the low-resistant cervical canal [8]. Although no previous cervical trauma was documented, CD&C used for the termination of preceding pregnancy opens up possibility of subclinical cervical injury. Despite the fact that a high percentage of patients with a history of CD&C have a favorable outcome of future pregnancies/deliveries, the procedure is associated with an increased rate of

postpartum hemorrhages [14]. We believe that previous cervical injury, although clinically silent, should be considered as the principal reason for cervical tearing. The induction drugs were applied in a habitual and safe manner while no other obvious predisposing factors existed. Similarly to the case of patient submitted to LEEP, presumptive cervical tissue alteration did not allow dilatation of the external os due to fibrosis. Persisting rigidity of the os weakened the nearby cervical segment. Under the effect of prostaglandin-induced contractions, this resulted in tissue thinning and tearing. Alternatively, the intrinsic cervical os stiffness in our patient can be taken into account, making the above tissue prone to rupture.

Regardless of etiology, this complication could be prevented by performing a cesarean section upon the recognition of the pathologic significance of the external os rigidity. In nulliparous women at term, external cervical os remains stationary during the cervical shortening, but quickly evolves once the cervical effacement is completed [15]. Thus, identification of women at risk for significant cervical tearing is fundamentally important. It can be achieved by strict and careful monitoring of the labor progression. During the serial digital examinations of the cervical response, a particular attention should be paid to the characteristics and modification of the external os. Upon the completion of cervical effacement and in the presence of significant uterine contractility, repetitive finding of a rigid external os should be considered as a sign of alarm.

In conclusion, rigidity of the external cervical os and the lack of its dilation after the cervical effacement may indicate the imminence of cervical tearing beside a closed natural orifice. In particular, this cervical response should be valorized in women with a history of a cervical intervention, even when it is not associated with apparent complications. The case suggests that the group at risk of described complication also involves women submitted to minimally invasive procedures such as cervical dilatation. Labor induction in women with the history of CD&C is relatively common. Therefore, the prevalence of intrapartum cervical tearing may increase. Although the described event is rare, the possibility of its occurrence should not be neglected because of the serious maternal and fetal morbidities that may arise.

Conflict of Interest

None declared.

References

1. Landy, H. J., S. K. Laughon, J. L. Bailit, M. A. Kominiarek, V. H. Gonzalez-Quintero, M. Ramirez, et al. 2011. Characteristics associated with severe perineal and cervical

- lacerations during vaginal delivery. *Obstet. Gynecol.* 117:627–635.
2. Melamed, N., A. Ben-Haroush, R. Chen, B. Kaplan, and Y. Yogeve. 2009. Intrapartum cervical lacerations: characteristics, risk factors, and effects on subsequent pregnancies. *Am. J. Obstet. Gynecol.* 200:e381–e384.
 3. Parikh, R., S. Brotzman, and J. N. Anasti. 2007. Cervical lacerations: some surprising facts. *Am. J. Obstet. Gynecol.* 196:e17–e18.
 4. Chan, V. Y. T., W. L. Lau, and W. C. Leung. 2012. Delivery through a cervical tear in a patient with a history of loop electrosurgical excision procedure and intact cervical Os. *Hong Kong J. Gynaecol. Obstet. Midwifery* 12:86–88.
 5. Lowensohn, R., and C. Ballard. 1974. Cervicovaginal fistula: an apparent increased incidence with prostaglandin F₂alpha. *Am. J. Obstet. Gynecol.* 119:1057–1061.
 6. Pelosi, M. A., A. Langer, J. T. Harrigan, M. DeVanesan, and J. Zanvettor. 1975. Term delivery through a cervicovaginal fistula. *Am. J. Obstet. Gynecol.* 122:789–790.
 7. El-Etriby, E. K., and E. Daw. 1981. Rupture of the cervix during prostaglandin termination of pregnancy. *Postgrad. Med. J.* 57:265–266.
 8. Grotegunt, C. A., N. L. Moore, K. L. Reddick, B. J. Canzoneri, B. K. Boyd, and H. L. Brown. 2010. Cervicovaginal fistula presenting during miscarriage. *Ultrasound Obstet. Gynecol.* 36:112–114.
 9. Harrigan, J. T., D. Karbhari, and A. Halpern. 1977. Term delivery through a spontaneously occurring cervicovaginal fistula following second-trimester surgical repair. *Am. J. Obstet. Gynecol.* 128:912–913.
 10. Uchil, D., W. Kumakech, and A. Jolaoso. 2006. Spontaneous vaginal delivery through an unusual posterior cervical tear. *J. Obstet. Gynaecol.* 26:263–264.
 11. Oyelese, Y., H. J. Landy, and J. V. Collea. 2001. Cervical laceration associated with misoprostol induction. *Int. J. Gynaecol. Obstet.* 73:161–162.
 12. Weeks, A., Z. Alfirevic, A. Faúndes, G. J. Hofmeyr, P. Safar, and D. Wing. 2007. Misoprostol for induction of labor with a live fetus. *Int. J. Gynecol. Obstet.* 99:S194–S197.
 13. Dasari, P., H. Sagili, and G. Udupi. 2012. Unusual complication of vaginal delivery: is misoprostal the cause? *BMJ Case Rep.* 2012:2012.
 14. Lohmann-Bigelow, J., S. A. Longo, X. Jiang, and A. G. Robichaux III. 2007. Does dilation and curettage affect future pregnancy outcomes? *Ochsner J.* 7:173–176.
 15. Zilianti, M., A. Azuaga, F. Calderon, G. Pages, and G. Mendoza. 1995. Monitoring the effacement of the uterine cervix by transperineal sonography: a new perspective. *J. Ultrasound Med.* 14:719–724.