

Long-Term Efficacy and Safety of Anlotinib as a Monotherapy and Combined Therapy for Advanced Sarcoma

Weitao Yao¹, Xinhui Du¹, Jiaqiang Wang¹, Xin Wang¹, Peng Zhang¹, Xiaohui Niu²

¹Bone and Soft Department, The Affiliated Cancer Hospital of Zheng Zhou University, He Nan Cancer Hospital, Zheng Zhou City, 450000, People's Republic of China; ²Department of Orthopedic Oncology Surgery, Beijing Ji Shui Tan Hospital, Peking University, Beijing, 100035, People's Republic of China

Correspondence: Weitao Yao, Bone and Soft Department, The Affiliated Cancer Hospital of Zheng Zhou University, He Nan Cancer Hospital, 127 Dong Ming Road, Zheng Zhou City, 450000, People's Republic of China, Email ywtdwhm@163.com; Xiaohui Niu, Department of Orthopedic Oncology Surgery, Beijing Ji Shui Tan Hospital, Peking University, No. 31 Xin Jie Kou Dong Jie, Xi Cheng District, Beijing, 100035, People's Republic of China, Email niuxiaohui@263.net

Objective: To analyze the effectiveness of the long-term (> 12 months) administration of anlotinib as a monotherapy or combined therapy in patients with advanced sarcomas.

Methods: A retrospective analysis was conducted of patients with advanced sarcomas with measurable target lesions since 2018. Twenty-two of the patients had taken anlotinib regularly for > 12 months. The patients' general information and the drug's clinical efficacy and toxicity data were collected and statistically analyzed using RECIST 1.1 to measure the target lesions and tumor PFS time as the main endpoints. We used a swimmer plot to observe the drug's efficacy and duration, and employed a waterfall plot to express the best treatment effect.

Results: The study included 14 male and 8 female patients, ranging in age from 14 to 75 (mean: 44.82) years. The primary diseases included alveolar soft part sarcoma, synovial sarcoma, leiomyosarcoma, and others. The metastasis sites were the lungs in fifteen cases, lymph nodes in four cases, and multiple sites in three cases. Fourteen patients had previously undergone chemotherapy. The current therapy protocol was oral anlotinib alone for nine cases, combination chemotherapy for nine cases, and combination immunotherapy (anti-PD-1) for four cases. The highest clinical efficacy was complete remission (CR) in four (18.18%) cases, partial response (PR) in five (22.73%) cases, and stable disease in 13 (59.09%) cases, with an odds ratio of response of 40.91%. The mean PFS for the CR, PR, and stable disease groups was 16.50, 14.50, and 29.31 months, respectively ($p < 0.05$). The main adverse effects included hand-foot syndrome, hypertension, and leukopenia.

Conclusion: Anlotinib monotherapy or combination therapy can be more effective and safer for certain advanced sarcomas, with more extended maintenance and acceptable side effects. Clinical efficacy at the CR and PR levels might predict the long-term PFS in certain advanced sarcomas.

Keywords: anlotinib, advanced sarcoma, targeted therapy, immunotherapy, clinical efficacy

Bone and soft tissue sarcomas (STS) are a group of malignant tumors derived from mesenchymal tissue and are characterized by high heterogeneity, complicated subtypes, high malignancy, and few available therapeutic methods. Moreover, most sarcomas are prone to metastasis through blood vessels to vital organs such as the lungs.¹ The treatment of sarcoma is mainly based on extensive surgical resection, supplemented by perioperative radiotherapy, chemotherapy, and other treatments.^{2–5} For localized tumors, the 5-year survival rate can reach 70%–80%; however, advanced and metastatic sarcomas have a 5-year survival rate below 20%.⁵ The prognosis for patients with sarcomas remains poor, with a median overall survival (OS) of slightly more than 1 year. Therefore, exploring new methods for treating advanced sarcoma is a hot topic and challenging research area.

Angiogenesis plays an essential role in tumor growth and metastasis, and blocking this pathway is a strategy that has been successfully employed in clinically treating cancer.^{6–8} Receptor tyrosine kinases are among the most promising therapeutic targets and can be used to modulate cell proliferation, growth, angiogenesis, and metastasis in a wide range of cancers.^{8–12} Anlotinib (AL3818) is a novel oral receptor tyrosine kinase inhibitor (TKI) that targets vascular endothelial growth factor receptors 2 and 3, fibroblast growth factor receptors 1–4, platelet-derived growth factor receptors α and β , c-Kit, and Ret,¹³ thereby exerting inhibitory effects on tumor growth and angiogenesis. A Phase I study of anlotinib by Sun et al¹⁴ demonstrated promising antitumor potential against STS. A multicenter, Phase II study by Chi et al (NCT01878448)¹⁵ investigated single-agent anlotinib in 166 patients with STS who experienced disease progression after anthracycline-based first-line chemotherapy. The progression-free survival (PFS) rate at 12 weeks was 68%, with an odds ratio of response (ORR) of 13% (95% confidence interval [CI], 7.6–18.0%), and the median PFS and OS were 5.6 and 12.0 months, respectively. The toxicity of anlotinib was acceptable or manageable in these patients and included hypertension and hand-foot syndrome. Anlotinib was approved and launched in the People's Republic of China in May 2018, receiving approval in June 2019 as a second-line treatment for patients with advanced alveolar soft part sarcoma (ASPS), clear cell sarcoma (CCS), and other types of advanced STS after one line of a chemotherapy regimen containing anthracycline.

In addition to the apparent efficacy, the convenience of oral administration, and the acceptable adverse effects, studies have shown that anlotinib, together with chemotherapy and immunotherapy, has synergistic effects.^{16–18} Clinical trials of this drug alone and in combination are being conducted. Anlotinib achieves its antitumor effect by inhibiting neovascularization of the microenvironment, a mechanism similar to that of metronomic chemotherapy administered in small doses over a long period; the longer the drug is administered, the longer its effectiveness.

This study investigated patients with sarcoma who took anlotinib for > 12 months. The study aims included exploring the safety and efficacy of the long-term use of anlotinib and analyzing the factors that influence and possibly predict the long-term efficacy of anlotinib. Additionally, we sought to provide potential therapeutic protocols for the subsequent treatment of advanced sarcomas.

Clinical Data

Patient Population and Data Collection

We collected the clinical data of patients diagnosed with advanced sarcomas who were ineligible for surgery at our hospital from June 2018 to December 2020. The inclusion criteria were as follows: 1) age \geq 12 years; 2) confirmed diagnosis of bone and STS involving the limbs and trunk according to immunohistochemical and genotypic analysis performed by pathologists in our hospital; 3) unresectable or metastatic tumor lesions unsuitable for curative therapy; 4) maintaining \geq 12 months of anlotinib therapy; 5) at least one measurable tumor as defined by the Response Evaluation Criteria in Solid Tumors (RECIST 1.1); 6) having previously taken other TKIs; and 7) with or without other treatments, such as chemotherapy and immunotherapy. The exclusion criteria were 1) unconfirmed pathological diagnosis, and 2) poor compliance, and irregular medication or follow-up.

Clinical data were gathered and recorded throughout the study, including sex, age, histological characteristics, medication methods, primary sites of the sarcomas, metastatic locations, clinical efficacy (PFS), and adverse events (AEs). Our study complies with the Declaration of Helsinki.

Therapeutic Schemes

The patients were initially administered anlotinib (provided by the Zhengda Tianqing Pharmaceutical Company) in 21-day cycles at a dosage of 12 mg/day from day 1 to day 14. Chemotherapy was performed for approximately 6 cycles, using a single agent of doxorubicin (60–90 mg/m²) or ifosfamide (10 g/m²) and then maintained with anlotinib. Anti-PD-1 was administered every 3 weeks. The therapy was continued until the disease progressed or unacceptable AEs occurred. The AEs were classified and graded using the National Cancer Institute's Common Terminology Criteria for Adverse Events (CTCAE), version 5.0.¹⁹ The dose could be reduced or temporarily suspended according to the patient's tolerance. The initial dosage of 12 mg/day of anlotinib was allowed to be reduced to 10 mg/day and then to

8 mg/day after less than 1 week of discontinuation. When the AEs became tolerable, a higher dosage could be readministered.

Assessment of Safety and Toxicity

Radiological assessment of the target lesions by computed tomography scans and magnetic resonance imaging was performed at baseline, 1–2 months after the start of therapy, and then every 12 weeks if clinically indicated. The results were analyzed according to the RECIST (version 1.1). The dual primary endpoint of the objective response rate and median PFS was assessed during the study period. The best responses were recorded from the first efficiency assessment to the time of progression after therapy. The responses were further categorized into either complete response (CR), partial response (PR), stable disease (SD), or progressive disease (PD). The ORR was defined as the percentage of patients who experienced CR and PR. PFS was calculated from the start of treatment to the first documented disease progression or death, whichever occurred first. AEs were graded and recorded using CTCAE.

Statistical Analysis

The quantitative variables are presented as the median (range) or frequency (percentage). The PFS and corresponding 95% CIs were calculated using the Kaplan–Meier method. Statistical analyses were performed using SPSS version 21.0 (IBM, Chicago, IL), employing a swimmer plot to observe the drugs' efficacy and duration and a waterfall plot to express the best treatment effect.

Results

General Information

The study included 22 patients (14 male and 8 female), ranging in age from 14 to 75 years (mean age: 44.82 years). The primary diseases included ASPS in five cases, synovial sarcoma (SS) in four cases, leiomyosarcoma in three cases, epithelioid sarcoma (ES) and undifferentiated pleomorphic sarcoma (UPS) in two cases each, and clear cell sarcoma (CCS), rhabdomyosarcoma, angiosarcoma, fibrosarcoma, pleomorphic liposarcoma and osteosarcoma in one case each (Figure 1). The target observed lesions (confirmed by pathologists) included 15 cases of pulmonary nodules, four cases of enlarged lymph nodes, and three cases of multiple metastases.

The number of treatment lines was as follows: five cases with first-line therapy (with previous no therapy), nine cases with second-line therapy (with a previous first-line therapy), six cases with third-line therapy (with a previous second-line therapy), and two cases with fourth-line therapy (with a previous third-line therapy) or above. There were 14 cases with previous chemotherapy and two cases with antiangiogenic targeted drug therapy. Except for three patients, nineteen cases had unplanned surgery in other general hospitals and reoperation in our department within three months. The surgical margin was R0 in seventeen cases and R1 in five cases (close to vital vessels). The previous chemotherapy protocol included single or combined agents of doxorubicin (60–90 mg/m²), ifosfamide (10 g/m²), gemcitabine (1000mg/m²), docetaxel (70–75mg/m²) in most sarcomas. Some special drugs such as methotrexate (8–12 g/m²) and cisplatin (100 mg/m²) in OS, vincristine (1.4 mg/m²) and cyclophosphamide (1000 mg/m²) in RMS was applied. The previous targeted drug was apatinib (500mg/day).

The choice of treatment modality was as follows: nine cases were treated with oral anlotinib alone. The primary diseases included ASPS in two cases, SS in two cases, and CCS, UPS, leiomyosarcoma, osteosarcoma, and liposarcoma in one case each. Nine cases were treated with anlotinib combined with chemotherapy, including two cases of SS, two cases of leiomyosarcoma, and one case each of ES, UPS, angiosarcoma, rhabdomyosarcoma, and fibrosarcoma. There were four cases of anlotinib combined with anti-PD-1 immunotherapy, including three cases of ASPS and one case of ES (Table 1).

Tumor Response

There were four cases of CR (18.18%), including two cases of anlotinib combined with anti-PD-1 therapy (one case each of ASPS and ES) and one case of anlotinib monotherapy (SS) or combined chemotherapy (ES) (Figure 1). Two of these

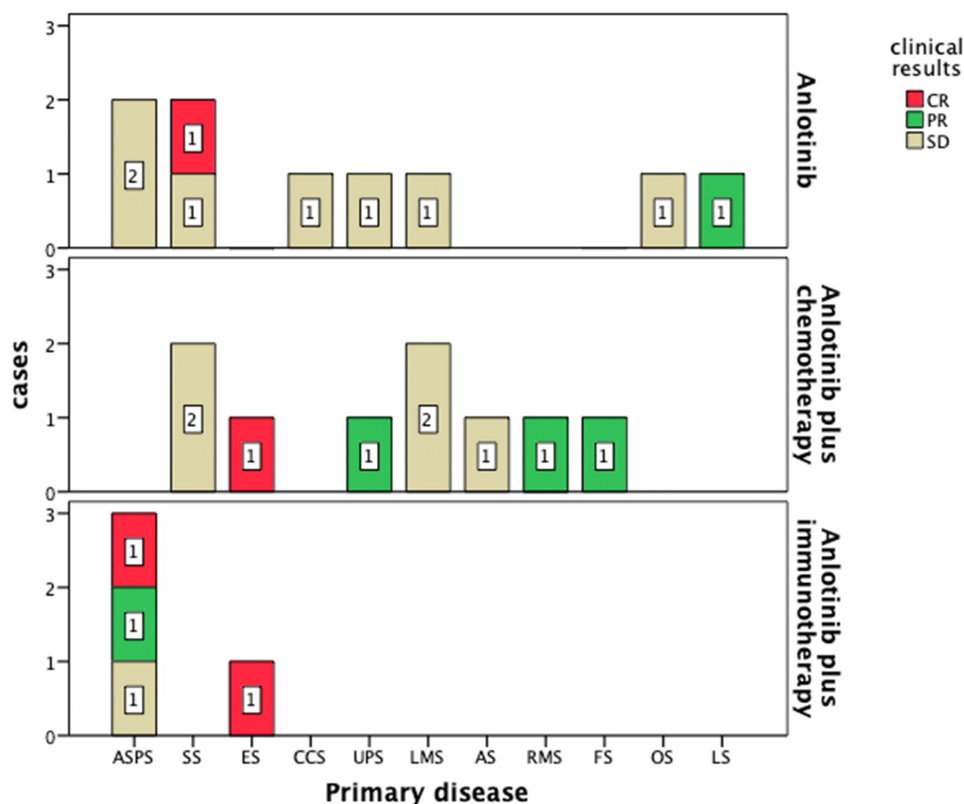


Figure 1 The efficacy of anlotinib monotherapy or combination therapy protocol in various types of sarcomas. 4 complete remission (CR) cases, 5 partial response (PR) cases, and 13 stable disease (SD) cases (odds ratio of response [ORR], 41%). For alveolar soft part sarcoma (ASPS), better control can be achieved with anlotinib alone or in combination with immunotherapy. Anlotinib alone or in combination with chemotherapy had a good effect on synovial sarcoma (SS). CR of epithelioid sarcoma (ES) can be obtained when using anlotinib in combination with immunotherapy or chemotherapy. Anlotinib alone might be effective in clear cell sarcoma (CCS), undifferentiated pleomorphic sarcoma (UPS), leiomyosarcoma (LMS), osteosarcoma (OS), and liposarcoma (LS). The combination of anlotinib with chemotherapy provides better control in UPS, LMS, angiosarcoma (AS), LS, and OS.

patients were treated with second-line therapy, one was treated with third-line therapy, and one was treated with fourth-line therapy (Figure 2).

There were five cases (22.73%) of PR, including one case of anlotinib monotherapy (liposarcoma), three cases of combination chemotherapy (one case of UPS, rhabdomyosarcoma, and fibrosarcoma each), and one case of combination anti-PD-1 therapy (ASPS) (Figure 1). One patient underwent first-line therapy, two underwent second-line, one underwent third-line, and one underwent fifth-line therapy (Figure 2). The remaining 13 cases maintained SD during therapy (59.09%; ORR, 40.91%).

Efficacy Duration of the Study

The earliest occurrence of CR was 1 month after the start of therapy, and the latest time reached was 9 months after the start of therapy. Most target lesions reached a period of PR and then turned to CR. Twenty-five months was the longest CR maintained, and two cases of CR persisted until the end of the study. The CR time lasted a mean of 13.50 months, and the PFS was 16.50 months in this patient group.

PR appeared 1–2 months after therapy in five patients, with four cases of PR persisting until the end of the study. The last period was 9–17 (mean: 12.20) months, and the PFS was 14.50 months for the PR patients.

The longest SD duration was 35 months, and the shortest was 9 months. Consistent efficiency was maintained in four cases at the last follow-up. The SD lasted for approximately 17.62 months, and the PFS was 29.31 months. There was no statistically significant difference in PFS between the three groups ($p = 0.059$).

Table 1 Patient General Information and Clinical Efficacy and Adverse Effects with the Therapy Protocols of Anlotinib Monotherapy or in Combination Therapy

No.	Gender	Age	Pathological Diagnosis	Primary Tumor Surgery	Lines of Therapy	Drug Protocol	Clinical Effect	PFS	Disease Progress	Current Status	AEs
1	Male	36	ASPS	Ro	3	A	SD	24	Yes	Stable	Hypertension of grade 1
2	Male	23	ASPS	Ro	4	A+I	CR	12	Yes	Stable	Hand-foot syndrome of grade 1
3	Male	36	SS	Ro	2	A+C	SD	16	No	Progression	Hypertension of grade 1
4	Male	49	ES	Ro	2	A+I	CR	23	No	Stable	Hypothyroidism, weakness and anorexia of grade 3, hand-foot syndrome of grade 2
5	Male	68	CCS	Ro	1	A	SD	13	No	Death	None
6	Male	38	UPS	Ro	3	A+C	PR	9	No	Death	None
7	Male	40	SS	Ro	2	A+C	SD	24	No	Progression	Leukopenia, hypertension and hand-foot syndrome of grade 1
8	Female	19	ASPS	RI	1	A	SD	38	Yes	Stable	Hypertension and hand-foot syndrome of grade 1
9	Stable	14	ES	RI	2	A+C	CR	26	Yes	Progression	Hand-foot syndrome of grade 1 and wound rupture, pneumothorax
10	Female	37	LMS	Ro	1	A+C	SD	12	No	Progression	None
11	Male	42	RMS	RI	2	A+C	PR	11	Yes	Surgery	Leukopenia and febrile neutropenia of grade 3
12	Female	47	FS	Ro	2	A+C	PR	16	No	Stable	Leukopenia and hand-foot syndrome of grade 1
13	Female	54	LMS	Ro	3	A+C	SD	35	Yes	Stable	Hypertension of grade 2, hand-foot syndrome of grade 1
14	Male	46	SS	Ro	3	A	CR	26	No	Progression	Hand-foot syndrome grade 1
15	Male	75	LMS	RI	1	A	SD	17	No	Progression	Hypertension of grade 1
16	Male	50	UPS	Ro	2	A	SD	10	No	Progress	None
17	Male	57	OS	Ro	2	A	SD	17	No	Death	Hand-foot syndrome of grade 1
18	Female	41	SS	Ro	2	A	SD	16	No	Progression	Weakness and anorexia f grade 2
19	Male	63	ASPS	Ro	1	A+I	PR	18	No	Stable	Hypertension of grade 1,
20	Female	42	ASPS	Ro	3	A+I	SD	11	Yes	Stable	None
21	Female	62	LS	RI	5	A	PR	12	No	Stable	None
22	Female	47	AS	Ro	3	A+C	SD	11	No	Progression	Leukopenia of grade 1

Abbreviations: ASPS, alveolar soft part sarcoma; SS, synovial sarcoma; LMS, leiomyosarcoma; ES, epithelioid sarcoma; UPS, undifferentiated pleomorphic sarcoma; CCS, clear cell sarcoma; RMS, rhabdomyosarcoma; AS, angiosarcoma; FS, fibrosarcoma; LS, pleomorphic liposarcoma; OS, osteosarcoma; A, anlotinib; C, chemotherapy; I, immunotherapy; CR, complete response; PR, partial response; SD, stable disease.

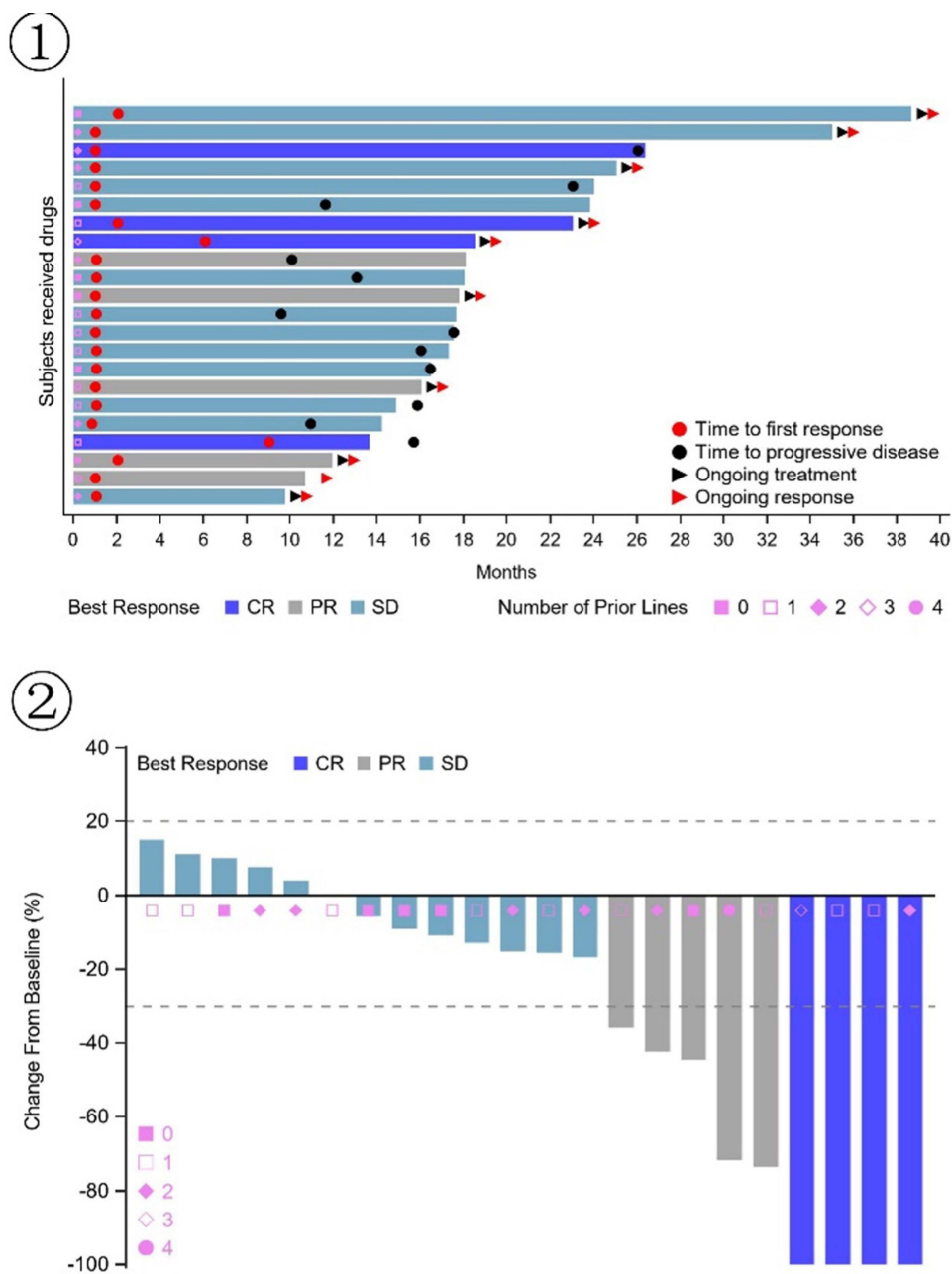


Figure 2 Clinical efficacy analysis graph for 22 patients. ① Swimmer plot showing the best therapeutic efficacy and duration. The longest control time was achieved in a patient with alveolar soft part sarcoma (ASPS). The target lesion’s stable disease status was maintained for approximately 38 months by anlotinib. Complete remission (CR) of the target lesion was achieved in a patient with synovial sarcoma and maintained for up to 26 months using the single-agent anlotinib. The longest partial response (PR) was achieved in a patient with fibrosarcoma, which was maintained for up to 16 months through treatment with anlotinib combined with chemotherapy. ② Waterfall plots showing the best response of the target lesion. There were 4 CR cases, 5 PR cases, and 13 stable disease (SD) cases.

Toxicities

Common toxicities included hand-foot syndrome in nine cases (40.91%), hypertension in six cases (27.27%), leukopenia in four cases (18.18%), and weakness and anorexia in two cases (9.09%). The grade 3–4 severe AEs included febrile neutropenia in one case, weakness due to hypothyroidism in one case, and wound-healing difficulty with ulcers in one case (Table 1).

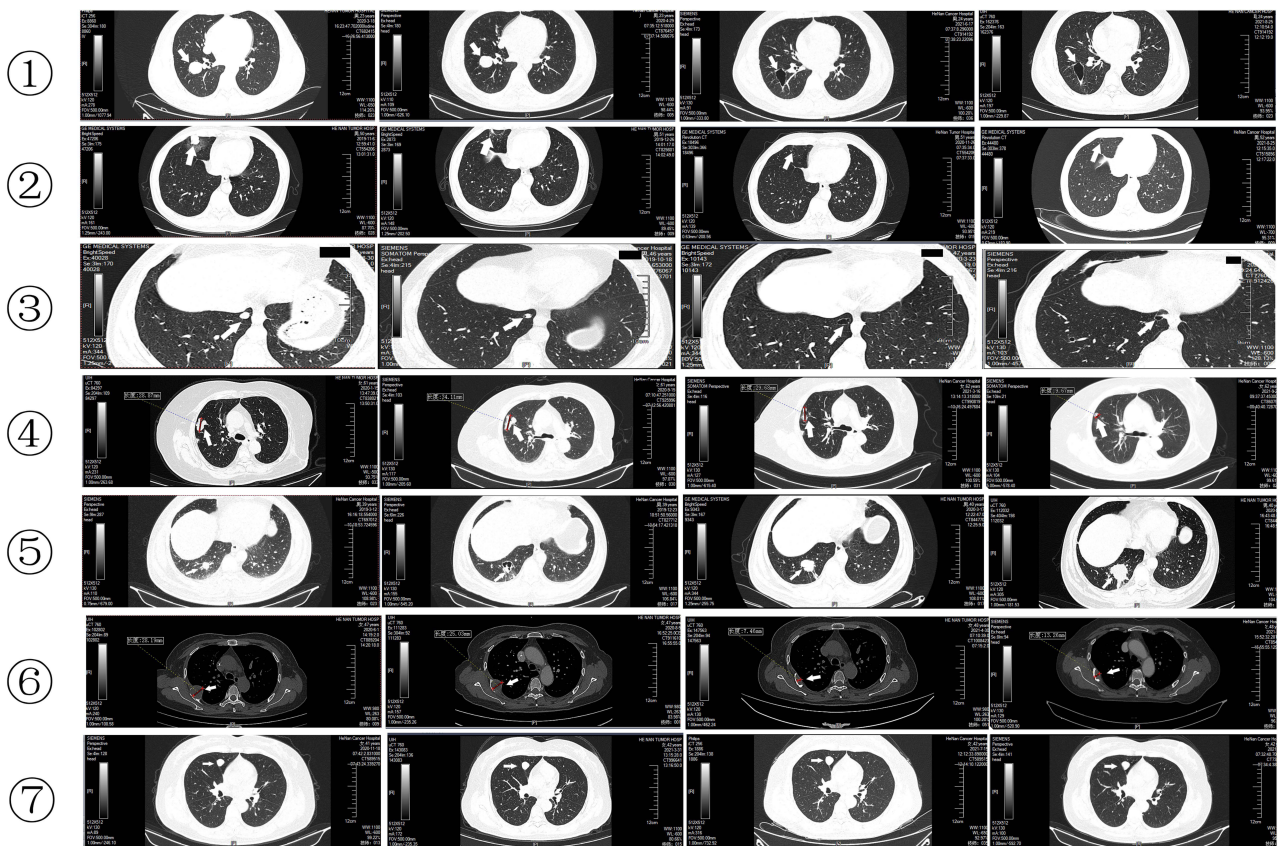


Figure 3 Efficacy analysis of different target lesions. ① 23-year-old male patient with alveolar soft part sarcoma (ASPS). After a previous third-line therapy, the target lesion was cavitated, and complete remission (CR) was achieved after 3 months of anlotinib combined with anti-PD1 therapy and maintained continuously for approximately 19 months. ② 49-year-old male patient with epithelioid sarcoma (ES). After another tyrosine kinase inhibitor (TKI)-targeted first-line drug therapy, the target lesion gradually disappeared. CR was achieved after 1 month of anlotinib combined with anti-PD1 therapy and maintained for approximately 23 months with ongoing efficacy. ③ 46-year-old male patient with synovial sarcoma (SS). After previous second-line chemotherapy, cavitation of the target lesion appeared after 6 months of oral anlotinib. However, the tumor progressed again after that and continued for approximately 26 months. ④ 62-year-old female patient with liposarcoma (LS). After multiple lines of chemotherapy, partial response (PR) was achieved for the target lesion after anlotinib monotherapy for 12 months, and the efficacy was maintained. ⑤ 38-year-old male patient with undifferentiated pleomorphic sarcoma (UPS). After 2 lines of therapy, the target lesion was kept at PR after anlotinib combined with chemotherapy for approximately 9 months; however, mass enlargement led to progressive disease (PD) at 12 months of therapy. ⑥ 47-year-old female patient with metastatic fibrosarcoma of the rib. After first-line chemotherapy, the target lesion shrunk after 1 month, and PR was sustained for 16 months with the protocol of anlotinib combined with chemotherapy. The efficacy is currently maintained. ⑦ 42-year-old female patient with ASPS. After 2 lines of therapy, the target lesion achieved stable disease (SD) status with the protocol of anlotinib combined with anti-PD1 therapy for approximately 12 months.

Typical Cases (See Figure 3)

Case 1 was a 23-year-old male patient with a diagnosis of ASPS. After a previous third-line therapy, the target lesion was cavitated, and CR was achieved after 3 months of anlotinib combined with anti-PD-1 therapy and maintained continuously for approximately 19 months. (see Figure 3①)

Case 2 was a 49-year-old male patient with a diagnosis of ES. After another TKI-targeted first-line drug therapy, the target lesion gradually disappeared. CR was achieved after 1 month of anlotinib combined with anti-PD-1 therapy and was maintained for approximately 23 months with ongoing efficacy. (see Figure 3②)

Case 3 was a 46-year-old male patient with a diagnosis of SS. After previous second-line chemotherapy, cavitation of the target lesion appeared after 6 months of oral anlotinib. However, the tumor progressed again and continued for approximately 26 months. (see Figure 3③)

Case 4 was a 62-year-old female patient with a diagnosis of liposarcoma. After multiple lines of chemotherapy, PR was achieved for the target lesion after anlotinib monotherapy for 12 months, and the efficacy was maintained. (see Figure 3④)

Case 5 was a 38-year-old male patient with a diagnosis of UPS. After two lines of therapy, the target lesion was maintained at a PR after anlotinib combined with chemotherapy for approximately 9 months; however, mass enlargement led to PD at 12 months of therapy. (see [Figure 3\(5\)](#))

Case 6 was a 47-year-old female patient with a diagnosis of metastatic fibrosarcoma of the rib. After first-line chemotherapy, the target lesion shrunk after 1 month, and PR was sustained for 16 months with the protocol of anlotinib combined with chemotherapy. The efficacy is currently being maintained. (see [Figure 3\(6\)](#))

Case 7 was a 42-year-old female patient with a diagnosis of ASPS. After two lines of therapy, the target lesion achieved SD status with the protocol of anlotinib combined with anti-PD-1 therapy for approximately 12 months. (see [Figure 3\(7\)](#))

Discussion

Bone sarcoma and STS account for approximately 1% of adult and 15% of pediatric malignant tumors, with a survival rate of only 20–40% for bone sarcoma and 35% for STS before the use of chemotherapy.^{20,21} Since the 1970s, chemotherapies have been applied and have achieved significantly better outcomes for sarcoma, with a 5-year survival rate of 60–80% when accompanied by surgical resection. Surgical resection can cure certain sarcomas, and better outcomes can be achieved when combined with chemotherapy or radiation.²² However, the systemic toxicity of and multidrug resistance to chemotherapy has limited the maximum applicable dosage, which is one of the major reasons for local recurrence and treatment failure. Metastatic lesions are detected in approximately 10% of patients with sarcomas during the first visit. Moreover, metastatic disease occurs in 25% of patients with sarcomas after the radical treatment of primary tumors. Therefore, there is an urgent need for new treatments for sarcomas.²³

Neovascularization in tumor tissues creates a lifeline for developing tumor cells. Through continuous tumor angiogenesis, nutrients are continuously supplied and simultaneously provide vascular channels for the growth, infiltration, and metastasis of tumor cells.⁶ Vascular endothelial growth factor (VEGF) is expressed in many tumors as an important regulatory factor in tumor angiogenesis.²⁴ Since pazopanib, one of the anti-angiogenesis-targeted drugs acquired its indication for the second-line treatment of sarcomas,^{25,26} more and more multikinase inhibitors (MTKI), such as sorafenib, regorafenib, cabozantinib, and lenvatinib, all with non-specific activities targeting VEGF receptors, have been proved effective in sarcomas.⁸ Among which regorafenib²⁷ and anlotinib²⁸ have achieved good results. Nevertheless, anlotinib is the only drug currently indicated for sarcoma in China. Previous studies have shown that anlotinib has satisfactory effectiveness in certain advanced STS, with fewer side effects, ease of use, and acceptance by patients. The most common grade 3 and 4 AEs of anlotinib are hypertension (4.8%), increased triglyceride levels (3.6%), and pneumothorax (2.4%).¹⁵ This treatment is generally well tolerated as a single or combination therapy.

However, the main problems with anti-angiogenesis-targeted drugs are short duration with secondary drug resistance, and studies are mostly limited to patients in advanced stages after multiple lines of therapy,²⁸ with relatively few reports of patients with long-term effectiveness. Given that tumor angiogenesis is only one pathway, the complex mechanism of tumor growth implies that multi-pathway and multidrug combinations can be more effective in treating sarcomas and achieving long-lasting efficacy. Wang et al²⁹ reported that a low concentration (1 mM) of anlotinib-promoted cisplatin (DDP)-induced cell apoptosis and increased the inhibitory effects of DDP on the proliferation of osteosarcoma cells. Compared to anlotinib or DDP alone, the combination notably reduced tumor weight and volume in vivo. Clinical studies have increasingly shown that anti-angiogenic targeted agents in combination with radiotherapy, chemotherapy, or immunotherapy can be employed for advanced sarcomas, with significant efficacy, a higher ORR, and longer duration than that of single agents.^{17,18,30,31}

A study retrospectively collected medical data from 32 patients with advanced/metastatic STS. The patients underwent chemotherapy and anlotinib plus anlotinib maintenance therapy.¹⁸ The results showed that the combination of chemotherapy and anlotinib could improve the survival rate of patients with advanced/metastatic STS and was well tolerated. Liu et al³² analyzed the data from 21 adults with unresectable or metastatic STS who were retrospectively diagnosed. The results indicated that switching maintenance therapy with anlotinib is a promising strategy for treating patients with unresectable or metastatic STS who have undergone chemotherapy.

Our study employed a retrospective survey of patients who used anlotinib for more than 1 year. The ratio of male to female patients was 1.5. The drug was shown to be in targeted-drug-sensitive diseases, such as ASPS and SS, immunotherapy-

sensitive diseases, such as ES and ASPS, and chemotherapy-sensitive diseases, such as leiomyosarcoma and rhabdomyosarcoma. Four patients achieved CR with the disappearance of the metastatic lesions or thin-walled cavities. However, as the follow-up is extended, certain disappeared lesions reappear and progress rapidly, a phenomenon that might be related to drug resistance or insufficient antitumor effect. Five patients achieved PR, which manifested as a reduction in the diameter of the target lesion, usually about 1 month after the therapy, and was maintained for approximately 9–17 months. The disease control rate of this patient group was 100%, and the ORR was 46%. The results indicate that tumor disappearance or significant shrinkage might indicate long-term tumor control. However, there was no positive correlation between PFS and ORR. In this study, the longest SD duration was 35 months (mean, 17.62 months), the CR duration was 13.50 months, and the PR duration was 12.20 months. The PFS reached 16.50, 14.50, and 29.31 months for the CR, PR, and SD groups, respectively, with no statistically significant difference. Therefore, maintaining tumor regression for a longer period is an important issue for the future.

In our study, the sarcomas that were most effectively treated with targeted drugs alone or in combination were ASPS, SS, and ES. The common feature of these three subtypes is abundant tumor vascularity, which is a relatively straightforward anti-angiogenic effect observed in previous studies.^{15,33} ASPS achieved CR in combination with immunotherapy, ES showed CR in combination with immunotherapy (one case) or chemotherapy (one case), and single-agent anlotinib achieved CR in only one case of SS. Therefore, anti-angiogenesis treatment in combination with other therapeutic measures especially immunotherapy may be necessary to obtain better outcomes.

The primary metronomic chemotherapy methods employ long-term low-dose drugs such as methotrexate and cyclophosphamide for advanced sarcomas.³⁴ This mechanism involves inhibiting the formation of tumor neovascularization, which leads to tumor death.³⁵ As anlotinib has clear anti-VEGF and neovascularization properties, it should, theoretically, meet or exceed the effects of metronomic chemotherapy when used long-term at low doses. The current study suggests that the relatively short PFS is related to the saturation of TKI-related targets in tumor cells or the opening of other tumor pathways, which leads to further elevation of tumor cell activity.²⁸ The oral duration of anlotinib in this study was more than 1 year in all cases, but its effectiveness was maintained in only eight (36.37%) patients at the last follow-up, as shown in the swimmer plot. Tumor resistance remains a significant impediment to the prolonged use of TKI-targeted agents.³⁶ Therefore, changing the dosing strategy or adjusting the treatment sequence of various drugs could lead to better and longer-lasting clinical effects in certain patients with sarcoma.

The main AEs of the long-term use of anlotinib are hypertension, hand-foot syndrome, and weakness. Myelosuppression is the main complication when chemotherapy is added, and hypothyroidism can appear after immunotherapy is combined. However, few severe AEs were observed, which might be due to the patients' good physical condition, timely management of complications, reasonable downward dose adjustment, and short discontinuation of the targeted drugs. However, rare complications do exist as a result of prolonged administration of drugs, including wound ulceration and difficulty in healing, the management of which requires the discontinuation of the targeted drugs, intensive wound dressing changes, and further debridement, if necessary. The AEs of single-agent or combined chemotherapy and immunotherapy in this group did not exceed the severity reported in the available literature.

The novelty of the current study included that we confirmed the feasibility, effectiveness, and safety of the long-term use of anlotinib, providing a new treatment method for the first time. The search for new low-toxic and high-efficiency targeted drugs and metronomic chemotherapy to achieve tumor control is a new direction for treating STS. Combining more drugs or therapeutic methods to achieve rapid tumor shrinkage and proper maintenance might be an effective means to achieve long-term control over advanced STS. The main limitations of this study are its small sample size, the use of retrospective studies, and the inconsistency of the therapeutic agents. Large samples and prospective studies are needed to confirm the long-term efficiency and adverse effects of combination therapies.

Although anlotinib monotherapy or a combination of other therapeutic methods seems to have advantages in synergistic therapeutic effects and overcoming drug resistance, the disadvantages are that it increases the toxicity and few patients can reach long-last effect. More specific immunotherapeutic agents such as immune checkpoint inhibitors and monoclonal antibodies targeting the immune synapse between tumor and T lymphocyte are being tested in sarcomas. However, the side effects for some patients can be harrowing. With high CD8 lymphocyte infiltration and high expression of PD-1, PD-L1 is likely to be the best choice for anti-PD-1 therapy.³⁷ In some special types of sarcomas,

such as synovial sarcoma, myxoid-round cell sarcoma, and malignant peripheral nerve sheath tumor (MPNST), consistently express cancer/testis antigens (CTAs) NY-ESO-1 or melanoma-associated antigen A4 (MAGE-A4), some new therapies such as chimeric antigen receptor T (CART) cell therapy are attractive. Antibody-drug conjugate (ADC) drugs against NY-ESO-1 have already demonstrated evidence of activity.³⁸ Additionally, some new biomarkers such as neurotrophic tyrosine receptor kinase (NTRK),¹¹ RANK-L,¹² and corresponding drugs larotrectinib, denosumab have also been shown to affect certain sarcomas dramatically.

Conclusions

Anlotinib monotherapy or combination therapy can be more effective and safer for certain advanced sarcomas, with more extended maintenance and acceptable side effects. Anlotinib combined with anti-PD-1 therapy had better therapeutic efficacy for specific diseases such as alveolar soft part sarcoma and epithelioid sarcoma. Anlotinib combined with chemotherapy had therapeutic efficacy for synovial sarcoma, leiomyosarcoma, fibrosarcoma, and rhabdomyosarcoma. Clinical efficacy at the CR and PR levels might predict the long-term PFS in certain advanced sarcomas.

Disclosure

The authors report no conflicts of interest in relation to this work.

References

- Ferrari A, Dirksen U, Bielack S. Sarcomas of soft tissue and bone. *Prog Tumor Res.* 2016;43:128–141.
- Tanaka K, Ozaki T. Adjuvant and neoadjuvant chemotherapy for soft tissue sarcomas: JCOG Bone and Soft Tissue Tumor Study Group. *Jpn J Clin Oncol.* 2021;51(2):180–184. doi:10.1093/jjco/hyaa231
- Nakata E, Fujiwara T, Kunisada T, et al. Immunotherapy for sarcomas. *Jpn J Clin Oncol.* 2021;51(4):523–537. doi:10.1093/jjco/hyab005
- Brownstein JM, DeLaney TF. Malignant soft-tissue sarcomas. *Hematol Oncol Clin North Am.* 2020;34(1):161–175. doi:10.1016/j.hoc.2019.08.022
- HaDuong JH, Martin AA, Skapek SX, et al. Sarcomas. *Pediatr Clin North Am.* 2015;62(1):179–200. doi:10.1016/j.pcl.2014.09.012
- Detmar M. Tumor angiogenesis. *J Invest Dermatol Symp Proc.* 2000;5(1):20–23. doi:10.1046/j.1087-0024.2000.00003.x
- Shahneh FZ, Baradaran B, Zamani F, et al. Tumor angiogenesis and anti-angiogenic therapies. *Hum Antibodies.* 2013;22(1–2):15–19. doi:10.3233/HAB-130267
- Duffaud F. Role of TKI for metastatic osteogenic sarcoma. *Curr Treat Options Oncol.* 2020;21(8):65. doi:10.1007/s11864-020-00760-w
- Du Z, Lovly CM. Mechanisms of receptor tyrosine kinase activation in cancer. *Mol Cancer.* 2018;17(1):58. doi:10.1186/s12943-018-0782-4
- Yamaoka T, Kusumoto S, Ando K, et al. Receptor tyrosine kinase-targeted cancer therapy. *Int J Mol Sci.* 2018;19(11):3491. doi:10.3390/ijms19113491
- Recine F, De Vita A, Fausti V, et al. Case report: adult NTRK-rearranged spindle cell neoplasm: early tumor shrinkage in a case with bone and visceral metastases treated with targeted therapy. *Front Oncol.* 2021;11:740676. doi:10.3389/fonc.2021.740676
- De Vita A, Vanni S, Miserocchi G, et al. A rationale for the activity of bone target therapy and tyrosine kinase inhibitor combination in giant cell tumor of bone and desmoplastic fibroma: translational evidences. *Biomedicines.* 2022;10(2):372. doi:10.3390/biomedicines10020372
- Gao Y, Liu P, Shi R. Anlotinib as a molecular targeted therapy for tumors. *Oncol Lett.* 2020;20(2):1001–1014. doi:10.3892/ol.2020.11685
- Sun Y, Niu W, Du F, et al. Safety, pharmacokinetics, and antitumor properties of anlotinib, an oral multi-target tyrosine kinase inhibitor, in patients with advanced refractory solid tumors. *J Hematol Oncol.* 2016;9(1):105. doi:10.1186/s13045-016-0332-8
- Chi Y, Fang Z, Hong X, et al. Safety and efficacy of anlotinib, a multikinase angiogenesis inhibitor, in patients with refractory metastatic soft-tissue sarcoma. *Clin Cancer Res.* 2018;24(21):5233–5238. doi:10.1158/1078-0432.CCR-17-3766
- Liu J, Deng YT, Jiang Y. Switch maintenance therapy with anlotinib after chemotherapy in unresectable or metastatic soft tissue sarcoma: a single-center retrospective study. *Invest New Drugs.* 2021;39(2):330–336. doi:10.1007/s10637-020-01015-z
- Su H, Yu C, Ma X, et al. Combined immunotherapy and targeted treatment for primary alveolar soft part sarcoma of the lung: case report and literature review. *Invest New Drugs.* 2021;39(5):1411–1418. doi:10.1007/s10637-021-01105-6
- Wang HY, Chu J-F, Zhang P, et al. Safety and efficacy of chemotherapy combined with anlotinib plus anlotinib maintenance in Chinese patients with advanced/metastatic soft tissue sarcoma. *Oncol Targets Ther.* 2020;13:1561–1568. doi:10.2147/OTT.S235349
- Freites-Martinez A, Santana N, Arias-Santiago S, et al. Using the common terminology Criteria for adverse events (CTCAE - Version 5.0) to evaluate the severity of adverse events of anticancer therapies. *Actas Dermosifiliogr.* 2021;112(1):90–92. doi:10.1016/j.ad.2019.05.009
- Skubitz KM, D'Adamo DR. Sarcoma. *Mayo Clin Proc.* 2007;82(11):1409–1432. doi:10.4065/82.11.1409
- Ceyssens S, Stroobants S. Sarcoma. *Methods Mol Biol.* 2011;727:191–203.
- Reynoso D, Subbiah V, Trent JC, et al. Neoadjuvant treatment of soft-tissue sarcoma: a multimodality approach. *J Surg Oncol.* 2010;101(4):327–333. doi:10.1002/jso.21481
- Liu W, Jiang Q, Zhou Y. Advances of systemic treatment for adult soft-tissue sarcoma. *Chin Clin Oncol.* 2018;7(4):42. doi:10.21037/cco.2018.08.02
- Claesnon-Welsh L, Welsh M. VEGFA and tumour angiogenesis. *J Intern Med.* 2013;273(2):114–127. doi:10.1111/joim.12019
- Nguyen DT, Shayahi S. Pazopanib: approval for soft-tissue sarcoma. *J Adv Pract Oncol.* 2013;4(1):53–57. doi:10.6004/jadpro.2013.4.1.6

26. van der Graaf WT, Blay J-Y, Chawla SP, et al. Pazopanib for metastatic soft-tissue sarcoma (PALETTE): a randomised, double-blind, placebo-controlled Phase 3 trial. *Lancet*. 2012;379(9829):1879–1886. doi:10.1016/S0140-6736(12)60651-5
27. Agulnik M, Attia S. Growing role of regorafenib in the treatment of patients with sarcoma. *Target Oncol*. 2018;13(4):417–422. doi:10.1007/s11523-018-0575-0
28. Li S. Anlotinib: a novel targeted drug for bone and soft tissue sarcoma. *Front Oncol*. 2021;11:664853. doi:10.3389/fonc.2021.664853
29. Wang G, Sun M, Jiang Y, et al. Anlotinib, a novel small molecular tyrosine kinase inhibitor, suppresses growth and metastasis via dual blockade of VEGFR2 and MET in osteosarcoma. *Int J Cancer*. 2019;145(4):979–993. doi:10.1002/ijc.32180
30. Zhu MMT, Shenasa E, Nielsen TO. Sarcomas: immune biomarker expression and checkpoint inhibitor trials. *Cancer Treat Rev*. 2020;91:102115. doi:10.1016/j.ctrv.2020.102115
31. Hall F, Villalobos V, Wilky B. Future directions in soft tissue sarcoma treatment. *Curr Probl Cancer*. 2019;43(4):300–307. doi:10.1016/j.crrproblcancer.2019.06.004
32. Liu Y, Liu L, Liu L, et al. A phase I study investigation of metabolism, and disposition of [(14)C]-anlotinib after an oral administration in patients with advanced refractory solid tumors. *Cancer Chemother Pharmacol*. 2020;85(5):907–915. doi:10.1007/s00280-020-04062-8
33. Paoluzzi L, Maki RG, Nguyen DT, Shayahi S. Diagnosis, prognosis, and treatment of alveolar soft-part sarcoma: a review. *JAMA Oncol*. 2019;5(2):254–260. doi:10.1001/jamaoncol.2018.4490
34. Penel N, Adenis A, Bocci G. Cyclophosphamide-based metronomic chemotherapy: after 10 years of experience, where do we stand and where are we going? *Crit Rev Oncol Hematol*. 2012;82(1):40–50. doi:10.1016/j.critrevonc.2011.04.009
35. Mutsaers AJ. Metronomic chemotherapy. *Top Companion Anim Med*. 2009;24(3):137–143. doi:10.1053/j.tcam.2009.03.004
36. Shao Y, Zhong DS. Histological transformation after acquired resistance to epidermal growth factor tyrosine kinase inhibitors. *Int J Clin Oncol*. 2018;23(2):235–242. doi:10.1007/s10147-017-1211-1
37. Hashimoto K, Nishimura S, Ito T, et al. Immunohistochemical expression and clinicopathological assessment of PD-1, PD-L1, NY-ESO-1, and MAGE-A4 expression in highly aggressive soft tissue sarcomas. *Eur J Histochem*. 2022;66(2). doi:10.4081/ejh.2022.3393.
38. Hashimoto K, Nishimura S, Ito T, et al. Clinicopathological assessment of cancer/testis antigens NY-ESO-1 and MAGE-A4 in highly aggressive soft tissue sarcomas. *Diagnostics*. 2022;12(3). doi:10.3390/diagnostics12030733.

OncoTargets and Therapy

Dovepress

Publish your work in this journal

OncoTargets and Therapy is an international, peer-reviewed, open access journal focusing on the pathological basis of all cancers, potential targets for therapy and treatment protocols employed to improve the management of cancer patients. The journal also focuses on the impact of management programs and new therapeutic agents and protocols on patient perspectives such as quality of life, adherence and satisfaction. The manuscript management system is completely online and includes a very quick and fair peer-review system, which is all easy to use. Visit <http://www.dovepress.com/testimonials.php> to read real quotes from published authors.

Submit your manuscript here: <https://www.dovepress.com/oncotargets-and-therapy-journal>