

# Simultaneous Bilateral Patella Fracture After Single Stage Bilateral Total Knee Arthroplasty: A Report of Two Cases and Literature Review

Babaji Thorat<sup>1</sup>, Avtar Singh<sup>1</sup>, Rajeev Vohra<sup>1</sup>, Sudhanshu Bansal<sup>1</sup>

## Learning Point of the Article:

Possibility of bilateral periprosthetic patellar fractures should be kept in mind in resurfaced or unresurfaced patella, and ORIF using TBW can be considered as a treatment option to achieve a satisfactory clinical outcome.

## Abstract

**Introduction:** Periprosthetic patellar fracture after total knee arthroplasty (TKA) is an uncommon yet devastating complication, and management of these fractures is challenging with unreliable results. An isolated bilateral patellar fracture is often associated with systemic diseases, steroid usage, and repeated microtrauma. Isolated simultaneous bilateral periprosthetic patellar fracture after TKA is seldom reported in the literature.

**Case Report:** This report consists of two cases of simultaneous isolated closed bilateral periprosthetic patellar fracture after TKA, treated with open reduction and internal fixation of patella using tension band wiring. Union was achieved in both cases with satisfactory knee range of motion without significant extension lag.

**Conclusion:** Regardless of the fact that surgical outcome of periprosthetic fracture of the patella has unpredictable and poor results in past, it can be considered for acute traumatic periprosthetic patella fractures with less comminution and good bone stock to avoid revision arthroplasty and poor outcome.

**Keyword:** Periprosthetic fracture, bilateral, patella fracture, bilateral total knee arthroplasty, tension band wiring.

## Introduction

Knowing the fact that the number of total knee arthroplasty (TKA) has risen in recent years with a high rate of aging and improved life expectancy, there is an upsurge in the incidence of complications too [1]. Patellar fracture is an uncommon yet challenging complication after TKA irrespective of the primary prosthesis used [1, 2]. Simultaneous isolated bilateral patellar fractures are infrequently reported in the literature and usually associated with systemic diseases, steroid use, and repeated microtrauma [3, 4].

Evidence from the previous studies suggests that patellar resurfacing during TKA is associated with increased risk of periprosthetic patellar fracture [2], thereby disrupt the knee extensor mechanism and may lead to failure of TKA [2, 3].

Simultaneous bilateral periprosthetic patellar fracture after TKA is even more uncommon complication associated with unpredictable results and poor outcomes [2]. Timely diagnosis and early treatment are crucial for rehabilitation and successful outcome.

We report two cases of simultaneous isolated closed bilateral periprosthetic fractures of the patella after TKA which were treated surgically. It includes analysis of the literature with a discussion of risk factors, management options, and measures for its prevention.

## Case Report

We present two unique cases.

### Author's Photo Gallery



Dr. Babaji Thorat



Dr. Avtar Singh



Dr. Rajeev Vohra



Dr. Sudhanshu Bansal

<sup>1</sup>Department of Orthopaedic Surgery, Amandeep Hospital, Amritsar, Punjab, India.

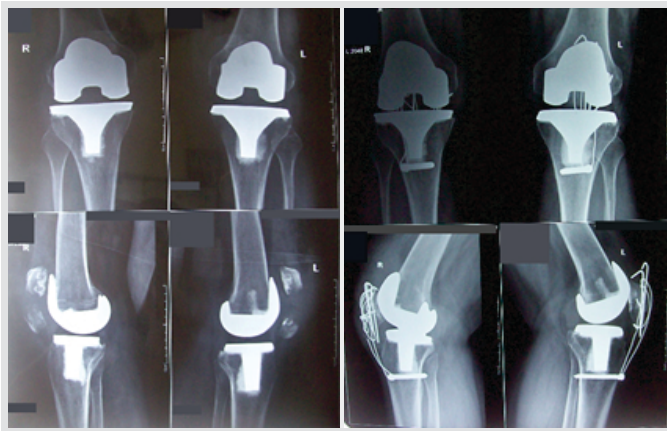
#### Address of Correspondence:

Dr. Babaji Thorat,  
Amandeep Hospital, Model Town, G. T. Road, Amritsar - 143 001, Punjab, India.  
E-mail: trt.babaji98@gmail.com

Access this article online

Website:  
www.jocr.co.in

DOI:  
10.13107/jocr.2020.v10.i06.1866

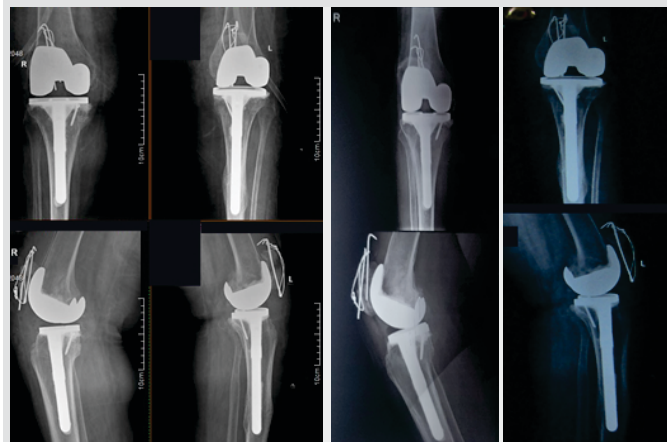

**Figure 1:** Pre-operative radiograph of case 1 showing bilateral periprosthetic patella fracture without any signs of implant loosening. Post-operative radiograph after open reduction and internal fixation with tension band wiring showing union.

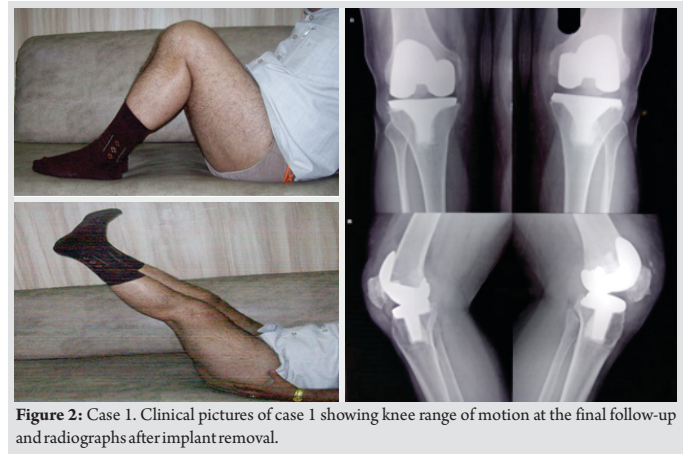
### Case 1

A 58-year-old man presented to the emergency room complaining of bilateral knee pain, swelling and inability to extend his both knee. He was operated for cemented posterior stabilized (PS) TKA with resurfacing of the bilateral patella in our institute through a medial parapatellar approach 5 weeks back. During TKA, Hoffa fat pad was excised for better visualization and patellar osteophytes were resected. At 5 weeks postoperatively, while he had no problems with his everyday activities, his knees were suddenly hyper flexed due to imbalance when he was going downstairs. Initial assessment showed compromised extensor mechanism of the bilateral knee. Anteroposterior and lateral radiographs of both knee (Fig. 1) showed a bilateral periprosthetic fracture of the resurfaced patella with no signs of loosening of the prosthesis (Type II according to Ortiguera and Berry classification) [5].

Using previous skin incision, an examination of components was done for malfunction or any signs of loosening, which was intact. Open reduction and internal fixation (ORIF) with tension band wiring (TBW) was done using two K-wires and sternum wires with extensor mechanism repair and patellar



**Figure 3:** Perioperative radiographs of case 2 after open reduction and internal fixation with tension band wiring and final follow-up radiographs showing fracture union.



**Figure 2:** Case 1. Clinical pictures of case 1 showing knee range of motion at the final follow-up and radiographs after implant removal.

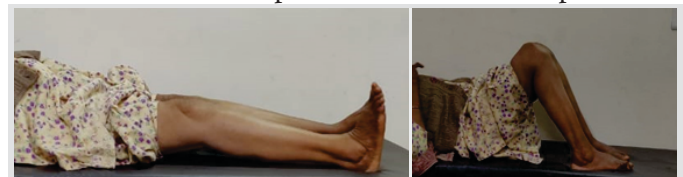
tendon reinforcement (Fig. 1).

Immediate post-operative radiographs showed a satisfactory reduction. The patient was advised toe-touch weight bearing with support and knee range of motion exercises. He was discharged on 4th post-operative day to be followed up regularly on an outpatient basis. During follow-up, the union was achieved in both patellae without any implant failure and complication (Fig. 1). He gained full knee range of motion with no residual pain or extension lag. Patients underwent implant (TBW) removal done after 12 months of surgery. The patient was pain-free, capable to walk without support without any extension lag at the end of the 2-year follow-up (Fig. 2).

### Case 2

A 60-year-old obese female (body mass index-32.3) presented to the emergency room with bilateral fracture of the unresurfaced patella after 1 month of PS bilateral TKA done elsewhere. Her medical history revealed that she was taking medications for hypothyroidism and hypertension. Her pre-operative records showed advanced gonoarthritis which failed to improve to anti-inflammatory drugs and knee physiotherapy. Post-operative radiographic images showed well-aligned tibial and femoral components. At 1 month after TKA, when she was trying to squat, she suddenly heard a pop sound and was not able to get up from the squatting position. Radiographs showed a transverse displaced periprosthetic fracture of both patellae with the disruption of the knee extensor mechanism, which was treated surgically by ORIF with TBW (Fig. 3).

Similar procedure and post-operative rehabilitation protocols were followed as described in case 1. The patient was able to walk unaided with mild pain at 3 months follow-up. Her knee



**Figure 4:** Clinical pictures of case 2 showing knee range of movements at the final follow-up

**Table 1: Treatment and clinical outcome in each case**

Case	Treatment	Follow-up (months)	Range of motion (degree)		Extensor lag (degree)	Bone union	Pain	Walking aid
			Before fracture	After fracture				
1	ORIF with TBW	24	0–110	0–120	0	Yes	No	None
2	ORIF with TBW	18	0–110	10–110	10	Yes	No	None

ORIF: Open reduction and internal fixation, TBW: Tension band wiring

range of motion was 10°–100° at final follow-up of 18 months (Fig. 4).

We then reviewed the treatment and clinical outcome for each fracture case (Table 1).

**Discussion**

Simultaneous bilateral patellar fractures are rarely reported in the literature [2] and are usually associated with steroid usage, repeated microtrauma, and systemic diseases such as hyperparathyroidism, osteoporosis, stress fracture, and renal failure [4]. Therefore, it is crucial to identify patients with an increased risk of fracture for its prevention.

Periprosthetic patellar fractures after TKA is a challenging situation which may lead to poor outcome and necessitate a revision TKA. The reported incidence of periprosthetic patellar fracture after TKA is 0.2–21% in resurfaced and 0.05% in non-resurfaced patella [1, 2]. Although resurfacing of the patella is a common practice during TKA, the resurfaced patella is at increased risk of subluxation, component loosening, patellar clunk syndrome, and fracture due to poor bone stock (excessive bony resection), and poor bone quality (osteolysis and patellar component loosening) [6]. Periprosthetic patellar fracture after TKA can be a stress fracture due to osteonecrosis, an indirect consequence of an eccentric quadriceps muscle contraction or a traumatic fracture, which is infrequent [7, 8].

Median parapatellar arthrotomy, fat pad removal, and lateral release lead to devascularization of the patella [8] and its subsequent stress fracture after TKA; however, its significance has not been proved in all studies [9, 10]. Most of these occur within the first few years after TKA [8, 11], and more common in older patients [11]. This can be attributable to poor bone stock or fatigue failure when there is osteonecrosis of the patellar bone [12]. Maltracking of the patella due to malalignment of the femoral or tibial component, overstuffing of anterior compartment result in higher contact stresses transferring to the patella and lead to abnormal loading of patellofemoral compartment resulting in fracture of the patella. [13] Traumatic fractures often need an open reduction and fixation to re-approximate the fragments [14]. Patient-related risk factors include male sex, osteoporosis, bone cyst, rheumatoid arthritis, obesity, limited preoperative knee range of movements, the previous surgery of patella, metabolic

conditions, and excessive activity or knee range of motion [1, 15].

Patellar fracture in case 1 was type II according to Ortiguera and Berry classification, which is a relatively rare type [5, 16, 17]. In our report, the use of a posterior stabilizing component and sudden hyperflexion of the knee leads to increased patellofemoral contact stress which was independently and significantly associated with the patellar fracture in both the cases. Besides this, patellar resurfacing resulting in post-operative thinning and reduced mechanical strength of the patella were also the probable factors responsible for periprosthetic traumatic stress patellar fracture in case 1. However, obesity, hypothyroidism, osteoporosis (old age), and stress from excessive knee flexion during squatting leading to eccentric contraction of the quadriceps may have predisposed to patellar fracture in case 2.

Management of periprosthetic patellar fractures is a debatable zone [7]. Literature analysis showed that non-surgical treatment of undisplaced periprosthetic patellar fracture with a stable prosthesis and an intact knee extension mechanism was associated with a successful outcome. A study by Ortiguera and Berry obtained favorable results in 37 out of 38 periprosthetic fracture of the patella with conservative management [16]. Whereas, operative treatment was reported to associate with a high complication rate with poor results of [17]. A systematic review of a 752 periprosthetic patellar fractures by Chalidis et al. showed that 88.3% fractures were atraumatic which were discovered during follow-up and a failure rate of 92% among the cases who underwent ORIF [2]. Dennis reported that surgical treatment for periprosthetic patella fracture is associated with a complication rate of 39% [18]. However, this can be attributed to:

- A high proportion of atraumatic, fatigue fractures because of osteonecrosis associated with poor bone stock has a higher risk for nonunion
- Surgical intervention such as partial or complete patellectomy is associated with poor surgical outcome
- Post-traumatic fractures among relatively young patients are more promising to unite as compared with stress fractures in the elderly.

In our study, the bony union was achieved in both the cases with TBW which is a strong and dynamic construct, leading to an excellent functional outcome without residual pain. In fracture of resurfaced patella, we recommend using thin Kirschner wire for TBW which should be passed just anterior to the patellar prosthesis to achieve sufficient hold in remaining patellar bone stock. The reinforcement wire should be used to protect the construct.

The key factors deciding the best treatment modality are



extensor apparatus integrity, prosthesis stability, fracture displacement, quality, and quality of patellar bone stock [19]. If there is loosening of pre-existing patellar prosthesis, bony anatomy should be restored before deciding as to whether or not to proceed with re-resurfacing the patella. If needed, patellectomy along with allograft reconstruction of the extensor mechanism is recommended, if the patellar bone stock is poor. Familiarity with radiological signs and clinical significance of a periprosthetic patella fracture after TKA assists in early diagnosis and timely intervention to achieve good results. Knowledge of the risk factors responsible for spontaneous periprosthetic patellar fracture after TKA provides a valuable insight into its prevention.

### Conclusion

Simultaneous bilateral periprosthetic patella fracture is a rare, important complication after TKA, and challenging to treat it.

Although former published studies report an exorbitant rate of failure and uncertain outcomes and give emphasis to non-operative treatment, surgical treatment using ORIF with TBW can be considered in displaced fractures, disruption of the extensor mechanism and open fractures having good remaining bone stock and intact prosthesis. Still, additional studies are necessary to validate this statement.

### Clinical Message

Familiarity with radiological signs and clinical significance of a periprosthetic patella fracture after TKA assists in early diagnosis and timely intervention to achieve good results. Knowledge of the risk factors responsible for spontaneous periprosthetic patellar fracture after TKA provides a valuable insight into its prevention.

### References

1. Yoo JD, Kim NK. Periprosthetic fractures following total knee arthroplasty. *Knee Surg Relat Res* 2015;27:1-9.
2. Chalidis BE, Tsiridis E, Tragas AA, Stavrou Z, Giannoudis PV. Management of periprosthetic patellar fractures. A systematic review of literature. *Injury* 2007;38:714-24.
3. Sheth NP, Pedowitz DI, Lonner JH. Periprosthetic patellar fractures. *J Bone Joint Surg Am* 2007;89:2285-96.
4. Hadlow AT, Medlicott PA. Bilateral simultaneous sleeve fractures of the patella in secondary hyperparathyroidism. *Injury* 1987;18:417-8.
5. Ortiguera CJ, Berry DJ. Patellar fracture after total knee arthroplasty. *J Bone Joint Surg Am* 2002;84:532-40.
6. Burnett RS, Bourne RB. Periprosthetic fractures of the tibia and patella in total knee arthroplasty. *Instr Course Lect* 2004;53:217-35.
7. Masmoudi K, Grissa Y, Benzarti S, Cheikhrouhou H, Mensi Z. Open periprosthetic patellar fracture after total knee replacement. *J Orthop Case Rep* 2016;6:89-91.
8. Berry DJ. Patellar fracture following total knee arthroplasty. *J Knee Surg* 2003;16:236-41.
9. Scuderi G, Scharf SC, Meltzer LP, Scott WN. The relationship of lateral releases to patella viability in total knee arthroplasty. *J Arthroplasty* 1987;2:209-14.
10. Reed MR, Farhan MJ, Chaudhuri C. Patellar stress fracture: A complication of knee joint arthroplasty without patellar resurfacing. *J Arthroplasty* 1999;14:383-5.
11. Brick GW, Scott RD. The patellofemoral component of total knee arthroplasty. *Clin Orthop Relat Res* 1988;231:163-78.
12. Bourne RB. Fractures of the patella after total knee replacement. *Orthop Clin North Am* 1999;30:287-91.
13. Figgie HE 3rd, Goldberg VM, Figgie MP, Inglis AE, Kelly M, Sobel M. The effect of alignment of the implant on fractures of the patella after condylar total knee arthroplasty. *J Bone Joint Surg Am* 1989;71:1031-9.
14. Windsor RE, Scuderi GR, Insall JN. Patellar fractures in total knee arthroplasty. *J Arthroplasty* 1989;4:S63-7.
15. Chun KA, Ohashi K, Bennett DL, El-Khoury GY. Patellar fractures after total knee replacement. *AJR Am J Roentgenol* 2005;185:655-60.
16. Parvizi J, Kim KI, Oliashirazi A, Ong A, Sharkey PF. Periprosthetic patellar fractures. *Clin Orthop Relat Res* 2006;446:161-6.
17. Keating EM, Haas G, Meding JB. Patella fracture after post total knee replacements. *Clin Orthop Relat Res* 2003;416:93-7.
18. Dennis DA. Periprosthetic fractures following total knee arthroplasty. *J Bone Joint Surg* 2001;83:120-30.
19. Sarmah SS, Patel S, Reading G, El-Husseiny M, Douglas S, Haddad FS. Periprosthetic fractures around total knee arthroplasty. *Ann R Coll Surg Engl* 2012;94:302-7.



**Conflict of Interest:** Nil  
**Source of Support:** Nil

**Consent:** The authors confirm that Informed consent of the patient is taken for publication of this case report

#### How to Cite this Article

Thorat B, Singh A, Vohra R, Bansal S. Simultaneous Bilateral Patella Fracture After Single Stage Bilateral Total Knee Arthroplasty: A Report of Two Cases and Literature Review. Journal of Orthopaedic Case Reports 2020 September;10(6): 36-40.

