

Role of Electromyography Endotracheal Tube in preventing recurrent laryngeal nerve injury during thyroid surgery: A case report

INTRODUCTION

Thyroid surgeries are the most frequently performed endocrine procedures worldwide. Recurrent laryngeal nerve (RLN) palsy is one of the common and serious complications after thyroid surgery that can diminish the quality of life.^[1] While it is generally accepted that direct visualisation of the nerve is the gold standard, intraoperative nerve monitoring (IONM) is being used increasingly as an adjuvant to help identify the nerve.^[2]

CASE REPORT

A 52-year-old diabetic female with left-sided colloid goitre, having normal pre-operative blood investigations and chest and neck radiograms, was posted for left hemithyroidectomy.

Premedication with intravenous (IV) glycopyrrolate 0.2 mg bolus and IV dexmedetomidine 1 µg/kg over 10 min was given under monitored anaesthesia care. Standard monitoring along with neuromuscular monitoring (NMT) and Entropy™ was used. After pre-oxygenation for 3 min, anaesthesia was induced with IV propofol 2 mg/kg followed by IV succinylcholine 2 mg/kg to facilitate endotracheal intubation with a Medtronic™ 7.0 mm cuffed flexometallic electromyography (EMG) tube, placing the tube surface electrodes at the level of vocal cords [Figure 1]. Midline fixation of the tube with bite blocks was done to prevent tube rotation and malposition of these electrodes. After neck extension, nasal fibre-optic scope was used to reconfirm the position of the tube surface electrodes. Use of local anaesthetic solution around the cord was avoided. Anaesthesia was maintained using 50% oxygen in nitrous oxide, sevoflurane (MAC 1) and titrated IV infusions of propofol at 0.5–1 mg/kg/h and dexmedetomidine at 0.3–0.5 µg/kg/h to maintain Entropy™ values between 40 and 60. Complete recovery from muscle relaxation due to succinylcholine was confirmed using NMT and by recording low amplitude waves (30–70 µV) on the

IONM monitor which occur due to spontaneous vocal cord movements. No muscle relaxant was used then on. At all times, train of four (TOF) count was 4 and TOF ratio was 0.9–1. The surgeon confirmed correct EMG tube placement and integrity of the IONM electrical circuit by directly stimulating the ipsilateral vagus nerve and then the RLN with a 1–2 mA current from a handheld sterile probe. Stimulation of the nerve gave a sinusoidal wave on the nerve integrity monitor (NIM-Neuro 3.0™) along with an audible signal confirming its intactness [Figure 2].

Intraoperative haemodynamics were stable throughout the 4 h of surgery. Before closure, intactness of nerve was reconfirmed by stimulating it. Dexmedetomidine and propofol infusion was stopped after excision of the gland. Injection paracetamol 1 g was given. Sevoflurane was then tapered off, and patient was extubated under direct laryngoscopy while visualising vocal cord movement thus confirming nerve integrity.

A total of 18 ml of sevoflurane, 200 mg of propofol and 60 µg of dexmedetomidine was used. Postoperatively, vocalisation was normal and visual analogue score of pain was 2–3/10.

DISCUSSION

The incidence of RLN injury during thyroid surgeries varies from 0.5% to 20% and may be due to damage to the nerve's anatomic integrity, thermal lesions, excessive nerve skeletization, or axonal damage caused by excessive strain, oedema, haematoma, difficult intubation and neuritis.^[3]

Direct visualisation of the RLN does not guarantee the functional integrity of the nerve.^[4] Various techniques have been described for nerve monitoring including cricoarytenoid muscle palpation, observing




Figure 1: Electromyography tube and electrodes with connector box

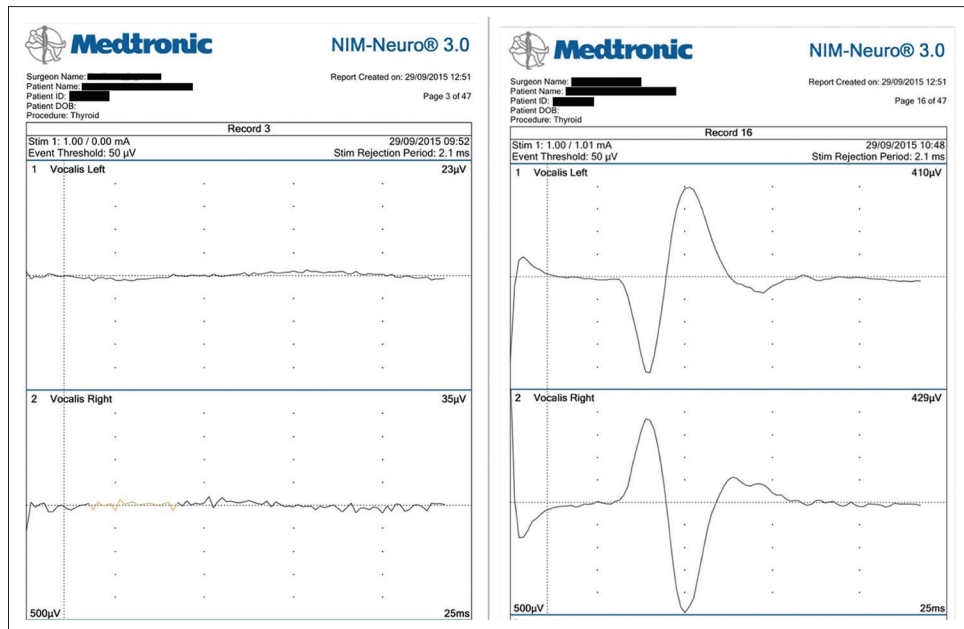


Figure 2: NIM-Neuro 3 monitor showing low amplitude waves with spontaneous vocal cord movements (left) and sinusoidal waveform after recurrent laryngeal nerve stimulation (right)

glottic movement, glottic pressure monitoring, endoscopically placed intramuscular vocal cord electrodes, intramuscular electrodes placed through the cricothyroid membrane, endotracheal tube-based surface electrodes and post-cricoid surface electrodes.^[5] Barczynski^[6] and Vasileiadis^[7] demonstrated statistically significant lower rates for nerve paralysis by neural monitoring as compared to visual identification alone. Hermann *et al.*^[8] argued in favour of IONM for three reasons, namely, increased the ability to reliably identify the RLN, confirming the functional integrity of the nerve, and guidance for surgeon in difficult dissections.

A functioning neuromuscular junction is necessary for IONM to work. The use of muscle relaxant reduces the EMG amplitude,^[9] thus making monitoring less sensitive to impending nerve injury. Hence, all muscle relaxants need to be avoided during the case. We used succinylcholine to aid proper placement of the EMG tube. Return of full muscle activity was documented by the NMT monitor. After that, no further muscle relaxants were used. No local anaesthetic jelly or spray was used on vocal cords.

When muscle relaxants are not used, a deeper plane of anaesthesia is required to prevent spontaneous movement of vocal cords.^[10] We achieved this by keeping entropy between 40 and 60 using a combination

of sevoflurane, propofol and dexmedetomidine. This ensured that spontaneous vocal cord movements were curbed but an evoked response was possible.

The cost of anaesthesia is increased with the use of EMG tube; it can be helpful in difficult dissections and redo surgeries.

CONCLUSION

The RLN is at risk during thyroid surgeries, and use of the EMG tube objectively identifies the nerve. Despite its limitations, IONM by EMG tube can be useful in difficult cases.

Financial support and sponsorship

Nil.

Conflicts of interest

There are no conflicts of interest.

**Hrudini Dixit, Laxmi Kamat, Meenoti Potdar,
Tejash Modi**

Department of Anesthesia, Dr. L H Hiranandani Hospital, Mumbai, Maharashtra, India

Address for correspondence:

Dr. Hrudini Dixit,
604 Amartaru 7B, Opposite Chinai College,
Old Nagardas Road, Andheri East, Mumbai - 400 069,
Maharashtra, India.
E-mail: hrudini@gmail.com

REFERENCES

1. Rulli F, Ambrogio V, Dionigi G, Amirhassankhani S, Mineo TC, Ottaviani F, *et al.* Meta-analysis of recurrent laryngeal nerve injury in thyroid surgery with or without intraoperative nerve monitoring. *Acta Otorhinolaryngol Ital* 2014;34:223-9.
2. Flukes S, Ling S, Leahy T, Sader C. Intraoperative nerve monitoring in otolaryngology: A survey of clinical practice patterns. *Int J Otolaryngol Head Neck Surg* 2013;2:21-6.
3. Calò PG, Pisano G, Medas F, Pittau MR, Gordini L, Demontis R, *et al.* Identification alone versus intraoperative neuromonitoring of the recurrent laryngeal nerve during thyroid surgery: Experience of 2034 consecutive patients. *J Otolaryngol Head Neck Surg* 2014;43:16.
4. Randolph GW, Kamani D. Intraoperative electrophysiologic monitoring of the recurrent laryngeal nerve during thyroid and parathyroid surgery: Experience with 1,381 nerves at risk. *Laryngoscope* 2017;127:280-6.
5. Sari S, Erbil Y, Sümer A, Agcaoglu O, Bayraktar A, Issever H, *et al.* Evaluation of recurrent laryngeal nerve monitoring in thyroid surgery. *Int J Surg* 2010;8:474-8.
6. Barczynski M, Konturek A, Cichon S. Randomized clinical trial of visualization versus neuromonitoring of recurrent laryngeal nerves during thyroidectomy. *Br J Surg* 2009;96:240-6.
7. Vasileiadis I, Karatzas T, Charitoudis G, Karakostas E, Tseleni-Balafouta S, Kouraklis G. Association of intraoperative neuromonitoring with reduced recurrent laryngeal nerve injury in patients undergoing total thyroidectomy. *JAMA Otolaryngol Head Neck Surg* 2016;142:994-1001.
8. Hermann M, Hellebart C, Freissmuth M. Neuromonitoring in thyroid surgery: Prospective evaluation of intraoperative electrophysiological responses for the prediction of recurrent laryngeal nerve injury. *Ann Surg* 2004;240:9-17.
9. Hemmerling TM, Schmidt J, Bosert C, Jacobi KE, Klein P. Intraoperative monitoring of the recurrent laryngeal nerve in 151 consecutive patients undergoing thyroid surgery. *Anesth Analg* 2001;93:396-9.
10. Rajan S, Puthenveetil N, Paul J. Transtracheal lidocaine: An alternative to intraoperative propofol infusion when muscle relaxants are not used. *J Anaesthesiol Clin Pharmacol* 2014;30:199-202.

This is an open access article distributed under the terms of the Creative Commons Attribution-NonCommercial-ShareAlike 3.0 License, which allows others to remix, tweak, and build upon the work non-commercially, as long as the author is credited and the new creations are licensed under the identical terms.

For reprints contact: reprints@medknow.com

Access this article online	
Quick response code	Website: www.ijaweb.org
	DOI: 10.4103/ija.IJA_414_16

How to cite this article: Dixit H, Kamat L, Potdar M, Modi T. Role of electromyography endotracheal tube in preventing recurrent laryngeal nerve injury during thyroid surgery: A case report. *Indian J Anaesth* 2017;61:435-7.