

Received: 2019.12.13  
Accepted: 2020.02.20  
Available online: 2020.03.23  
Published: 2020.05.11

# Effects of Endovascular Stent-Assisted Angioplasty on Cellular Metabolism in the Hippocampus of Elderly Patients with Symptomatic Vertebrobasilar Artery Stenosis

Authors' Contribution:  
Study Design A  
Data Collection B  
Statistical Analysis C  
Data Interpretation D  
Manuscript Preparation E  
Literature Search F  
Funds Collection G

ACEFG **Yongxing Yan**  
BCDE **Jun Wang**  
BCDF **Changyang Zhong**  
BCEF **Yan Zhang**  
BCF **Yingnan Wei**  
DEF **Huili Liu**

Department of Neurology, The Third People's Hospital of Hangzhou, Hangzhou, Zhejiang, P.R. China

**Corresponding Author:** Yongxing Yan, e-mail: [yyxing20@126.com](mailto:yyxing20@126.com)

**Source of support:** This work was supported by a grant from the Hangzhou City Science and Technology Agency (grant no. 20150733Q29)

**Background:** Cerebral artery stenosis is closely related to cognitive function, and angioplasty can improve the cognitive function of elderly patients with vertebrobasilar artery stenosis. The specific mechanism, however, is not clear. This study explored the effect of angioplasty on cellular metabolism in the hippocampus of elderly patients with symptomatic vertebrobasilar artery stenosis.


**Material/Methods:** Eighteen elderly patients with symptomatic vertebrobasilar artery stenosis who underwent endovascular stent-assisted angioplasty (ESAA) in our department were studied. The changes in cellular metabolism (NAA/Cr, CHO/Cr, NAA/CHO) in bilateral hippocampal areas were detected by MRS before and at 6 months and 12 months after the ESAA. The Montreal Cognitive Assessment Scale (MoCA), Hamilton Depression Self-assessment Scale (HAMD), and Hamilton Anxiety Self-assessment Scale (HAMA) were also used to evaluate the cognition, depression, and anxiety of patients at different time points of the study, and analyzed the correlation between the changes of cellular metabolism in the hippocampus and the scores of MoCA, HAMD, and HAMA.

**Results:** The levels of NAA/Cr in left/right hippocampal areas were significantly higher at 6 and 12 months after the ESAA than before ( $1.01 \pm 0.17 / 1.22 \pm 0.26$  vs.  $1.10 \pm 0.20 / 1.05 \pm 0.26$  vs.  $0.82 \pm 0.10 / 0.84 \pm 0.11$ , respectively) ( $P < 0.01$ ). MoCA scores were positively correlated with the levels of NAA/Cr in the left/right hippocampal areas ( $P < 0.05$  and  $P < 0.01$ , respectively).

**Conclusions:** ESAA can improve cognitive function of patients by changing the cellular metabolism of the hippocampus in elderly patients with symptomatic vertebrobasilar artery stenosis.

**MeSH Keywords:** **Magnetic Resonance Spectroscopy • Cognition Disorders • Stents • Vertebrobasilar Insufficiency**

**Full-text PDF:** <https://www.medscimonit.com/abstract/index/idArt/922131>

 3420

 1

 8

 43



## Background

Posterior circulation ischemia (PCI) is transient ischemic attack (TIA) or cerebral infarction caused by vertebrobasilar circulation system supply blood disorder. The common clinical manifestations are dizziness/vertigo, numbness/weakness of limbs, diplopia, walking instability, falls, and consciousness disorders. PCI has a variety of clinical manifestations and lack of fixed forms, which is difficult to identify compared with cerebral infarction in anterior circulation. Symptomatic vertebrobasilar artery stenosis an important cause of posterior circulation ischemic stroke. Although PCI accounts for about 20% of all strokes, the clinical symptoms of vertebrobasilar artery system are non-specific and the imaging lacks sensitivity, leading to missed diagnoses of PCI [1,2]; the mortality rate is high and prognosis is poor [3]. Therefore, it is very important to actively and effectively manage symptomatic vertebrobasilar artery stenosis in the early stage. At present, endovascular stent-assisted angioplasty (ESAA) is a common method of treating symptomatic vertebrobasilar artery stenosis, and its short- and long-term effects are good [4–7]. Yan et al. [8] found that ESAA can prevent the recurrence of stroke and improves the cognitive function of elderly patients with symptomatic vertebrobasilar artery stenosis. However, in previous studies, only a dementia scale was used to assess cognitive function. Due to the subjectivity of the scale, clinicians need more objective detection methods, and need to understand the mechanism by which cognitive function can be improved. Therefore, this study used magnetic resonance spectroscopy (MRS) to evaluate changes in cellular metabolism in the hippocampus of elderly patients with symptomatic vertebrobasilar artery stenosis before and after ESAA.

## Material and Methods

### General information

We selected 18 patients with PCI in our department from January 2015 to May 2018. Their clinical manifestations included dizziness/vertigo, numbness/weakness of limbs, slurred speech, and unstable walking. There were 5 cases of posterior circulation TIA and 13 cases of posterior circulation cerebral infarction, including 11 males and 7 females. The average age was  $72.67 \pm 4.62$  years. All the patients were examined and diagnosed by MRI+ diffusion-weighted imaging (DWI) in accordance with the diagnostic criteria for ischemic cerebrovascular disease [9]. All patients were treated with antithrombotic and statins, and were controlled for blood pressure, blood sugar, and other risk factors of stroke. Digital subtraction angiography (DSA) was performed in all patients. The results showed there were 13 cases of vertebral artery stenosis at the opening, 1 case of vertebral artery stenosis at the V2 segment, 2 cases

of vertebral artery stenosis at the V4 segment, and 2 cases of basilar artery stenosis.

Indications of ESAA were: (1) age  $\geq 60$  years; (2) symptomatic vertebrobasilar artery stenosis, stenosis rate  $\geq 50\%$ ; (3) patients and/or their families accept and sign for angioplasty treatment; (4) patients' compliance with follow-up was good, follow-up on time, and data were complete. Contraindications were: (1) severe neurological dysfunction after previous cerebral infarction; (2) severe disease or cardiopulmonary renal failure; (3) coagulation dysfunction; (4) intracranial aneurysm or malformation and intracranial tumor.

This study was a case series. We obtained signed informed consent and the study was approved by the Ethics Committee of our hospital.

### Treatment method

Before ESAA, the patients were treated with double antibiotics, aspirin 100 mg/d (Bayer), and clopidogrel 75 mg/d (Sanofi) for 3–5 days, taking atorvastatin 20 mg/d (Pfizer), and controlling blood glucose and blood pressure. During the operation, local anesthesia was used for stent implantation of V1 and V2 segments of the vertebral artery, general anesthesia was used for stent implantation of basilar artery and V4 segments of the vertebral artery. With angiographic guidance, the stent was placed across the narrow segment. After the stent was placed, the angiography was repeated. If the stent was not adequately expanded, we expanded it later. After the operation, the vessel was sutured or the artery sheath was retained and pulled out 4 h later. Individualized blood pressure was controlled after the operation. The patients were treated with aspirin 100 mg and clopidogrel 75 mg once a day for 3–6 months after the operation, and then changed to monoclonal antibody (aspirin 100 mg once a day or clopidogrel 75 mg once a day). All patients received long-term statins treatment, and the risk factors for stroke were strictly controlled.

### Evaluating cognition, depression, and anxiety

The MoCA scale was used to evaluate cognitive function. The standard MoCA scoring is that  $\geq 26$  points is normal, and if the education is  $\leq 12$  years, 1 point is added. The HAMD scale was used to evaluate depression, with scores over 17 indicating depression. The HAMA scale was used to evaluate anxiety, with scores over 13 indicating anxiety. All the scales were evaluated by special personnel before the operation and at 6 months and 12 months after ESAA.

## **<sup>1</sup>H-MRS was used to evaluate hippocampal cellular metabolism**

<sup>1</sup>H-MRS was performed with a 1.5T MR scanner (GE, USA). First, a conventional MRI scan was performed. The imaging sequence included T1W, T2W, sagittal T1W, and DWI. <sup>1</sup>H-MRS used chemical displacement imaging to collect the single voxel, scan the point resolution spectrum sequence, and located on the axial T2W image (bilateral temporal hippocampus at mid-brain level). The voxel size was 25×10×10 mm.

The baseline calibration and the identification of various metabolites were automatically completed by the spectral analysis software of the 1.5T magnetic resonance scanner, and the area under the peak curve of each metabolite was calculated at the same time. The main metabolites were N-acetylaspartate (NAA), creatine (Cr), and choline (Cho), and their chemical displacement positions were 2.01 ppm, 3.03 ppm, and 3.20 ppm, respectively. With creatine (Cr) as a reference, the MR scanner can automatically calculate the ratio of area under the curve of each metabolite (NAA/Cho, NAA/Cr, Cho/Cr). All patients were evaluated by <sup>1</sup>H-MRS before the operation and at 6 months and 12 months after ESAA.

### **Follow-up**

We followed up all 18 patients in our Outpatient/Inpatient Department, and the neurological symptoms and signs were observed at 6 and 12 months after discharge. Recurrence of stroke was suspected based on the symptoms and signs, and suspected patients underwent computerized tomography (CT) or MRI examination within 24 h to prevent recurrence of stroke. Computerized tomography angiography (CTA) or magnetic resonance angiography (MRA) or DSA of the head and neck were reexamined in all 18 patients at 6 and 12 months after the operation.

### **Statistical analysis**

Using the SPSS 20.0 statistical software package to statistics data, the measurement data were analyzed for normality, and data conforming to normal distribution are expressed as mean±standard deviation ( $\bar{x}\pm s$ ). The statistical comparison of the mean of 2 samples was performed by *t* test of independent samples. Count data are expressed as frequency and percentage (%). Comparisons between 2 groups was performed by chi-square test or Fisher test, and Pearson correlation was used.  $P<0.05$  was regarded as indicating a significant difference between 2 groups.

## **Results**

### **Analysis of cognitive function, depression, and anxiety**

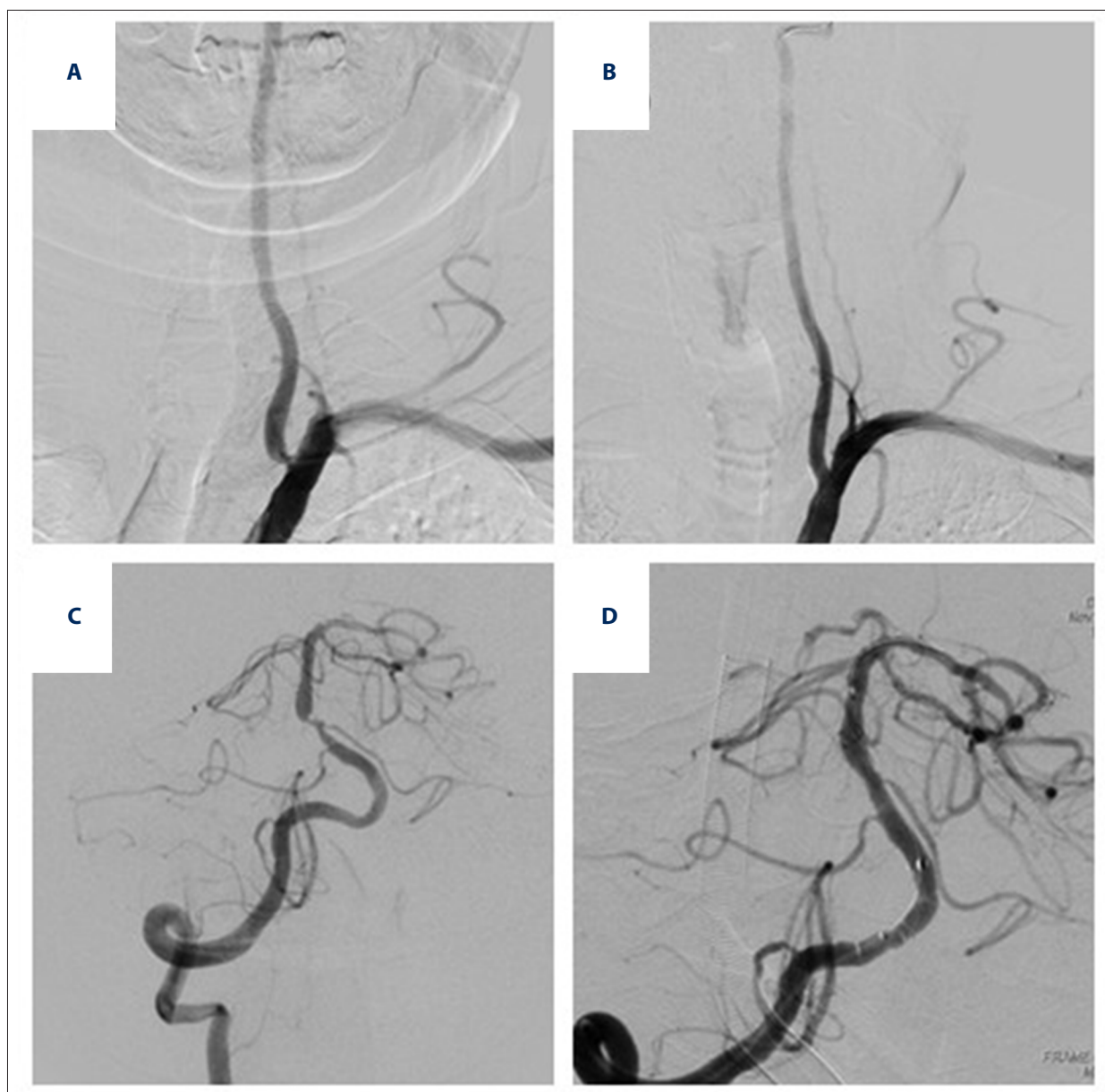
ESAA was successfully implemented in all 18 patients. There were no complications in the perioperative period, and the stenosis rate improved significantly ( $83.50\pm 7.64$  vs.  $2.61\pm 2.81$ ) ( $P<0.01$ ) (Figure 1). Before ESAA, the total MoCA score was  $25.22\pm 2.80$ , and 50% of patients (9/18) had scores lower than 26, indicating cognitive impairment. MoCA scores increased gradually at 6 and 12 months after ESAA –  $27.50\pm 1.50$  and  $27.89\pm 1.53$ , respectively – which were significantly higher than those before ESAA ( $P<0.01$ ), but there were no significant differences between 12 and 6 months after ESAA ( $P>0.05$ ). HAMD and HAMA scores were  $15.44\pm 4.13$  and  $16.56\pm 7.14$ , respectively; 22.2% patients (4/18) had depression and 55.6% patients (10/18) had anxiety. The HAMD and HAMA scores were significantly lower at 6 and 12 months after ESAA ( $P<0.01$ ). There was no significant difference between HAMD and HAMA scores at 6 and 12 months after ESAA ( $P>0.05$ ) (Table 1).

### **Hippocampal cellular metabolism**

The results of <sup>1</sup>H-MRS showed that there were clear NAA, Cr, and Cho spectra in the hippocampus, the NAA/Cr level increased gradually after ESAA, and the NAA/Cr level in the left/right hippocampus was significantly higher than before ESAA ( $1.01\pm 0.17/1.22\pm 0.26$  vs.  $1.10\pm 0.20/1.05\pm 0.26$  vs.  $0.82\pm 0.10/0.84\pm 0.11$ ), and the difference was statistically significant ( $P<0.01$ ). There was no significant difference between 6 and 12 months after ESAA ( $P>0.05$ ). There was no significant difference in the level of NAA/Cr between the left and right hippocampus ( $P>0.05$ ). There was no significant difference in the levels of Cho/Cr and NAA/Cho at different time points ( $P>0.05$ ) (Table 1).

### **Correlation between cellular metabolism and MoCA score**

There was a positive correlation between the NAA/Cr level of the left/right hippocampus and MoCA score at the same time point ( $P<0.05$ ,  $P<0.01$ ). The NAA/Cr level of the left/right hippocampus was positively correlated with the MoCA score before ESAA ( $r=0.4344$ ,  $P=0.0358$ ;  $r=0.4386$ ,  $P=0.0343$ ), as shown in Figures 2 and 3. The NAA/Cr level of the left/right hippocampus was positively correlated with the MoCA score at 6 months after ESAA ( $r=0.5486$ ,  $P=0.0009$ ;  $r=0.4646$ ,  $P=0.0260$ ), as shown in Figures 4 and 5. The NAA/Cr level of the left/right hippocampus was positively correlated with the MoCA score at 12 months after ESAA ( $r=0.4547$ ,  $P=0.0290$ ;  $r=0.5403$ ,  $P=0.0103$ ), as shown in Figures 6 and 7, and the differences were significant ( $P<0.05$ ;  $P<0.01$ ). There was no correlation between the values of Cho/Cr, NAA/Cho, and MCAO score ( $P>0.05$ ), and no



**Figure 1.** The stenosis of the vertebral artery, basilar artery, and the clinical efficacy. Before ESAA, opening stenosis degree of the vertebral artery was 85% (A); after ESAA, it was 0% (B). Before ESAA, the stenosis degree of the basilar artery was 90% (C); after ESAA, it was 10% (D). ESAA – endovascular stent-assisted angioplasty.

significant correlation between the values of NAA/Cr, Cho/Cr and NAA/Cho ( $P>0.05$ ).

#### Follow-up

All 18 patients were followed up, and there was no recurrence of stroke during the follow-up period. All 18 patients were followed up for 6 months and 12 months with MRA or CTA or DSA examination. Two patients had increased stent residual stenosis (25% and 30%), and 2 patients were asymptomatic and did not receive special treatment, as shown in Figure 8.

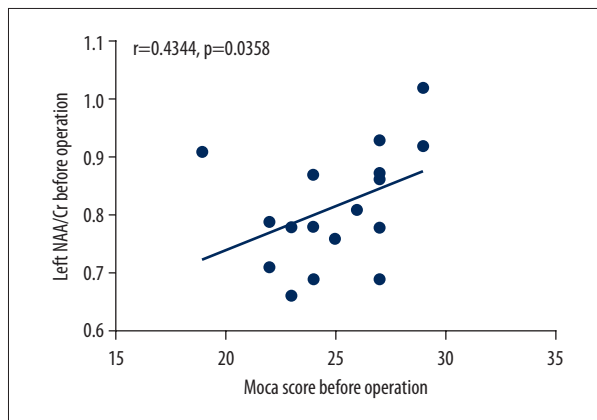
#### Discussion

Stroke has the characteristics of high incidence, disability, mortality, and recurrence, which are the most common causes of functional disability [10,11]. Stroke is also the leading cause of death in China, and imposes a heavy burden on society and families [12,13]. Ischemic stroke is the main type, accounting for about 70–80% of all stroke cases [14]. PCI is a type of ischemic stroke, accounting for about 20% of all strokes [1], but it has higher mortality and disability rate. Vertebrobasilar artery stenosis is an important risk factor, so it is very important

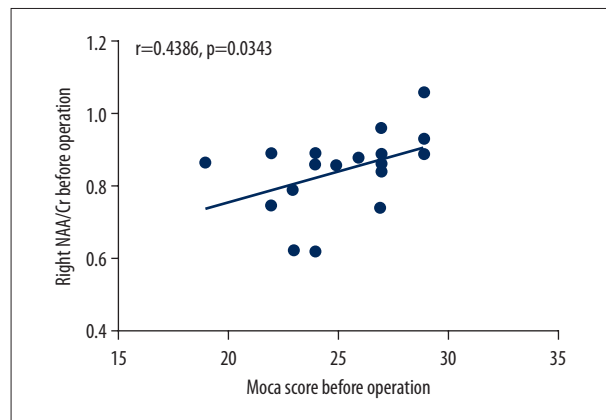
**Table 1.** Comparison of NAA/Cr, Cho/Cr and NAA/Cho levels in hippocampus before ESAA, 6 and 12 months after ESAA.

|                      | NAA/Cr     |            | Cho/Cr    |           | NAA/Cho   |           | Moca score  | HAMD score  | HAMA score  |
|----------------------|------------|------------|-----------|-----------|-----------|-----------|-------------|-------------|-------------|
|                      | Left       | Right      | Left      | Right     | Left      | Right     |             |             |             |
| Before ESAA          | 0.82±0.10  | 0.84±0.11  | 0.81±0.21 | 0.81±0.16 | 1.91±0.16 | 1.90±0.18 | 25.22±2.80  | 15.44±5.40  | 16.56±7.14  |
| 6 months after ESAA  | 1.01±0.17* | 1.22±0.26* | 0.90±0.29 | 0.92±0.27 | 1.94±0.16 | 1.90±0.21 | 27.50±1.50* | 11.00±5.31* | 10.39±4.59* |
| 12 months after ESAA | 1.10±0.20* | 1.05±0.26* | 0.89±0.21 | 0.92±0.19 | 1.91±0.15 | 1.90±0.19 | 27.89±1.53* | 10.94±5.56* | 10.78±5.19* |

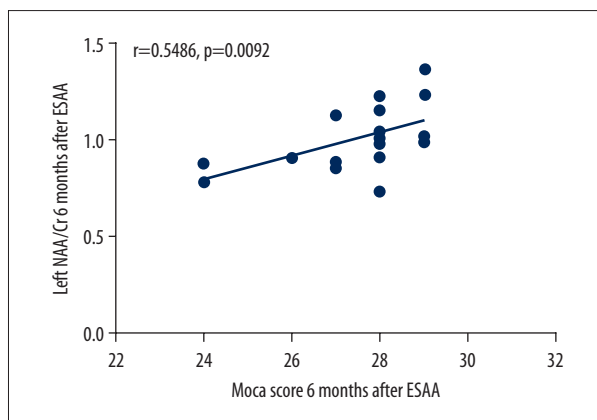
\* Compared with before ESAA,  $p < 0.01$ . ESAA – endovascular stent-assisted angioplasty.



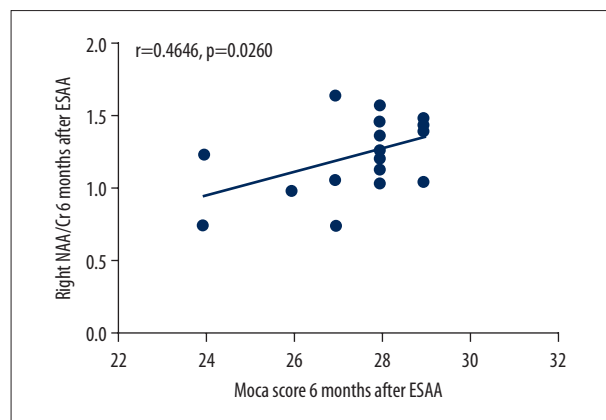
**Figure 2.** The NAA/Cr level of the left hippocampus was positively correlated with the MoCA score before ESAA.  $r=0.4344$ ,  $P=0.0358$ . ESAA – endovascular stent-assisted angioplasty.



**Figure 3.** The NAA/Cr level of the right hippocampus was positively correlated with the MoCA score before ESAA.  $r=0.4386$ ,  $P=0.0343$ . ESAA – endovascular stent-assisted angioplasty.



**Figure 4.** The NAA/Cr level of the left hippocampus was positively correlated with the MoCA score at 6 months after ESAA.  $r=0.5486$ ,  $P=0.0009$ . ESAA – endovascular stent-assisted angioplasty.

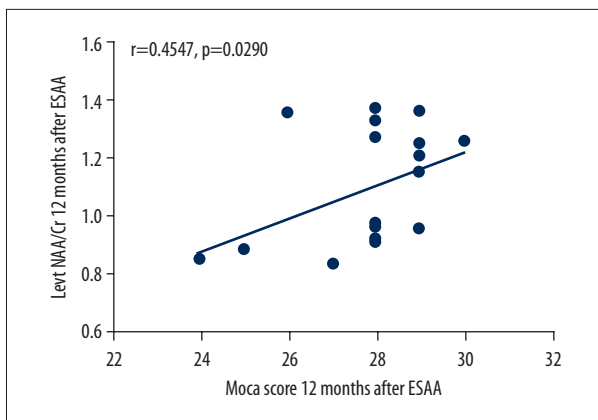


**Figure 5.** The NAA/Cr level of the right hippocampus was positively correlated with the MoCA score at 6 months after ESAA.  $r=0.4646$ ,  $P=0.0260$ . ESAA – endovascular stent-assisted angioplasty.

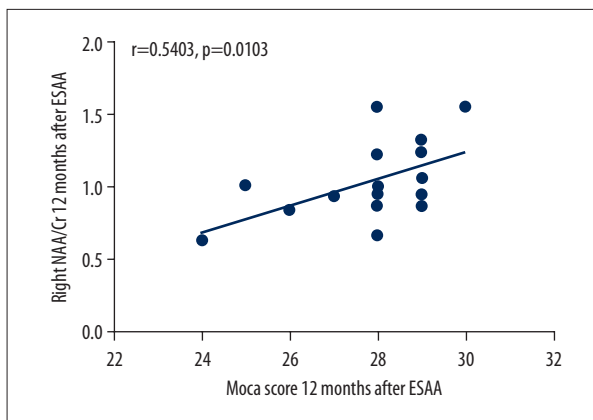
to actively and effectively treat vertebrobasilar artery stenosis in the early stage, which can effectively reduce recurrence and disability rates. In addition to the physical symptoms in most stroke patients, it was found that cognitive disorders,

depression, and anxiety are also common sequelae of stroke. After the occurrence of post-stroke depression, anxiety, and other emotional disorders and lead to more severe dysfunction, and the disability and mortality rates rise [15–18]. Yan et al. [8]

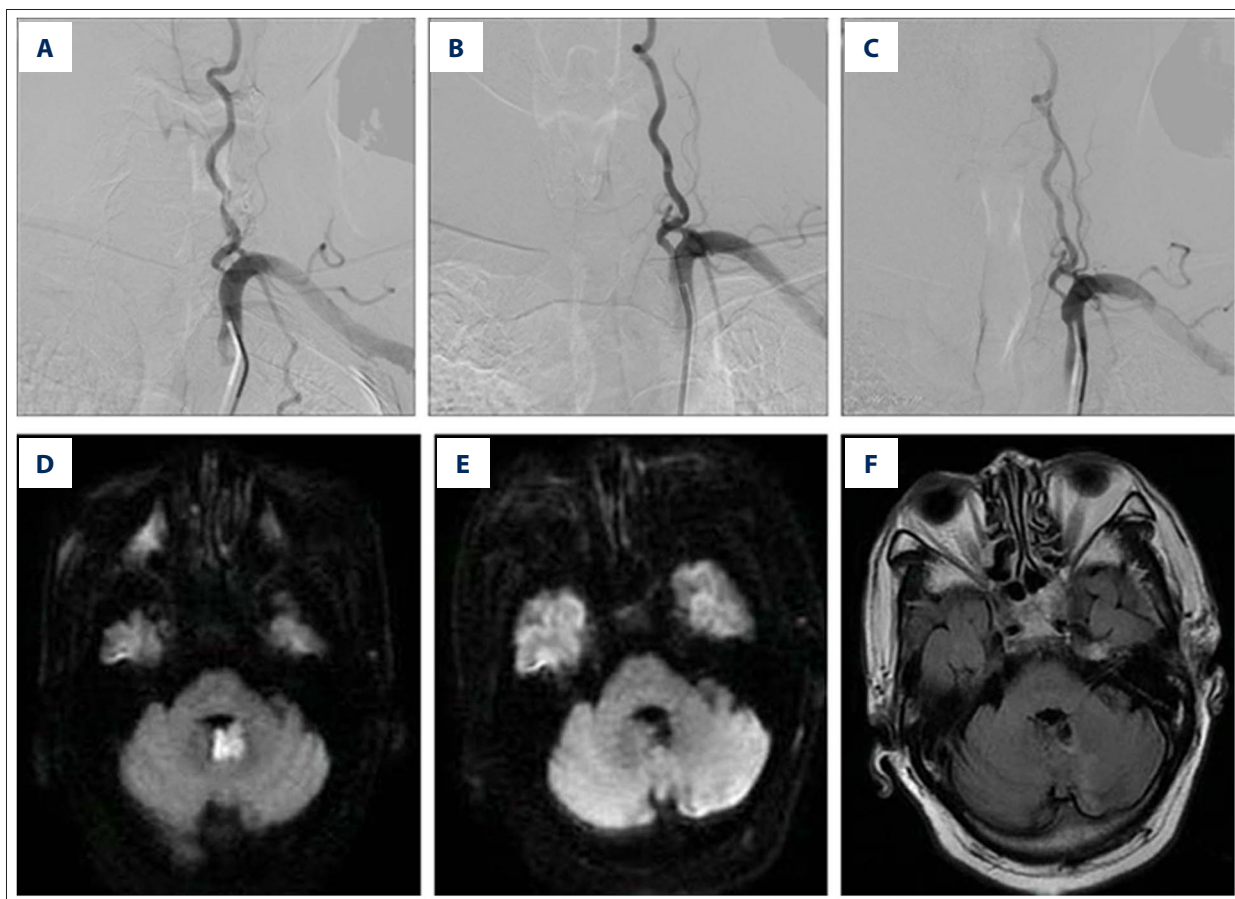




**Figure 6.** The NAA/Cr level of the left hippocampus was positively correlated with the MoCA score at 12 months after ESAA.  $r=0.4547$ ,  $P=0.0290$ . ESAA – endovascular stent-assisted angioplasty.



**Figure 7.** The NAA/Cr level of the right hippocampus was positively correlated with the MoCA score at 12 months after ESAA.  $r=0.5403$ ,  $P=0.0103$ . ESAA – endovascular stent-assisted angioplasty.



**Figure 8.** MRI and DSA manifestations of the skull in a patient with cerebellar infarction. Before ESAA, opening stenosis degree of the left vertebral artery was 75% (A); immediately after ESAA, it was 10% (B); at 12 months after ESAA, the stenosis was 30% (C); before ESAA the patient’s head MRI scan DWI showed high signal intensity in the left cerebellar vermiform (D); after ESAA at 12 months, DWI showed low signal intensity in the left cerebellar vermiform (E); after ESAA at 12 months, T2WI Flair showed low signal intensity in the left cerebellar vermiform, mixed with small high signal intensity (F). ESAA – endovascular stent-assistant angioplasty.

found that 53.8% of elderly patients with symptomatic vertebrobasilar artery stenosis had mild cognitive impairment, and the cognitive function was significantly improved after stenting. Our study also found that ESAA not only can prevent the recurrence of stroke, but also improves the cognitive function of patients and reduces the incidence of depression and anxiety.

Magnetic resonance spectroscopy (MRS) is a non-invasive imaging technique that shows the metabolism of living tissue. Before histomorphology changes, the degree of tissue changes can be evaluated by brain metabolism. MRS measures changes in cellular metabolism by detecting the concentration and ratio of various metabolites in brain tissue. At present, MRS technology can be used to measure the peaks and ratios of more than 10 brain metabolites and even various neurotransmitters, including N-acetyl-aspartic acid (NAA), creatine (Cr), choline (Cho), inositol (MI), lipid (Lip), lactic acid (Lac), and glutamine. According to the contents and ratios of these metabolites, metabolic changes can be shown in brain tissue cells. NAA mainly exists in the neuron body and synapse and can sensitively indicate damaged brain nerve cells. The content of NAA can directly reflect the density of neurons. When nerve cells are damaged, the NAA content of neurons decreases. Cr is mainly synthesized in the liver and kidneys. At present, Cr is considered to be a marker of energy metabolism in brain cells. Cho is a cell membrane component and can form some neurotransmitters. The content of Cho determines the height of the Cho peak, which reflects cell membrane function. Although there are many metabolites, NAA, Cr, and Cho are the main metabolites used in clinical MRS technology, and their metabolic changes are used to evaluate the metabolic capacity of cells.

MRS technology is widely used in patients with stroke or even in cerebral artery stenosis. For example, Demougeot [19] suggested that mitochondrial energy metabolism disorder can significantly reduce NAA concentration in the brain, even up to 80%. After correcting the metabolic disorder, NAA concentration returns to normal, indicating that the synthesis of NAA is closely related to mitochondrial activity, and there is a correlation between NAA concentration and metabolic efficiency. In patients with severe cerebral artery stenosis or occlusion, MRS technology can assess the activity of ischemic tissue and help clinicians decide about further treatment. Because of the heterogeneity of the single metabolite spectrum, the ratio between them is widely used to judge the clinical effect. Cr content is relatively stable in all brain metabolites, so it is often used as an internal benchmark to evaluate the metabolic ratio of other substances. For example, in terms of the severity of brain injury and prognosis, Garnett [20] found that the ratio of Cho/Cr and NAA/Cr was significantly correlated with Glasgow scale score, and the increase of Cho/Cr and the decrease of NAA/Cho are closely correlated with the severity of disease. Cecil [21] found that the decrease value of NAA/Cr in

the white matter was positively correlated with nerve damage. Wang et al. [22] found that decreased levels of NAA/Cr in the hippocampal area can damage the contact fibers of brain tissues, which can affect cognitive function, including executive power and memory. To reduce the error rate, NAA/Cr, Cho/Cr, and NAA/Cho were used in the present study. The results showed that the level of NAA/Cr in the left/right hippocampal area had increased significantly at 6 and 12 months after ESAA, and the difference was statistically significant. This shows that ESAA can affect the hippocampal cell metabolism in elderly patients with symptomatic vertebrobasilar stenosis.

Our correlation analysis of the level of NAA/Cr in the left/right hippocampus showed it was positively correlated with the MoCA score at the corresponding time point, suggesting that the improvement of cognitive function was related to the level of NAA/Cr in the hippocampus. It was speculated that the level of NAA/Cr in the hippocampus might be one of the indicators by which to assess cognitive dysfunction. The improvement of cognitive function in patients after angioplasty might be due to improved cell metabolism in the hippocampus. Cerebral artery stenosis is not only an important risk factor of cerebrovascular disease, but is also closely related to cognitive dysfunction [23,24]. The vertebrobasilar system, also known as the posterior circulation system, is composed of bilateral vertebral arteries, basilar arteries, and their branches. It mainly supplies blood to the brainstem, cerebellum, medial and posterolateral thalamus, occipital lobe, medial temporal lobe, and parietal lobe [25], while the temporal lobe, hippocampus, and thalamus are closely related to cognitive function.

Cerebral artery stenosis is an important pathological cause of low-perfusion vascular cognitive impairment (VCI) [26]. The integrity of brain function depends on cerebral circulation, especially the continuous and stable blood supply of the cerebral microvascular circulation system. Changes in cerebral circulation system can affect cognitive function [27,28]. In the spectrum diseases of cognitive impairment, changes in microcirculation and structure and cardiovascular system function are an important pathophysiological mechanism, especially the relationship between changes in hemodynamic and cognitive function [29]. Lattanzi et al. [30,31] found that cerebral hemodynamics was an independent and potentially reversible determinant of cognitive dysfunction in severe carotid artery disease. Cerebral hemodynamic status before carotid endarterectomy can predict neurocognitive performance changes after surgical stenosis correction. Tools used to assess hemodynamics include TCD, CT, MR, DSA, and PET. Among them, TCD plays an important role in hemodynamic evaluation because it is non-invasive, cheap, safe, and effective. TCD can also continuously record changes in hemodynamic parameters of intracranial and extracranial arteries. In our previous study [7], we also found that patients with vertebrobasilar artery stenosis

had abnormal hemodynamics, which was corrected after stent implantation, consistent with previously reported results [4,32]. Therefore, for patients with cerebral arterial stenosis, in addition to providing a possible mechanism for cognitive impairment, the assessment of hemodynamic status can also provide a basis for more aggressive treatment in patients at an early stage. Hemodynamic variables can be reliable predictors of post-stent outcome in vertebrobasilar artery disease. For patients with abnormal cerebral hemodynamics, early treatment may be more beneficial.

ESAA can improve the hippocampal cellular metabolism of patients with vertebrobasilar artery stenosis. The possible mechanisms are as follows: (1) Long-term stenosis of the vertebrobasilar artery caused slow cerebral blood flow and easily produces low perfusion. Chronic ischemia and hypoxia can lead to decreased cellular metabolism of brain contact fibers and can cause cognitive impairment [33–35]. The blood supply of brain tissue was increased after ESAA, which improved the chronic hypoperfusion state of cerebral blood flow caused by previous artery stenosis, and improved the level of cell metabolism. In this study, patients with symptomatic vertebrobasilar artery stenosis were treated with ESAA. The vascular pathway was reconstructed and the perfusion pressure of brain tissue increased accordingly, which increased the supply of cerebral blood flow. (2) Changes in cellular metabolism biochemical substances occur in the hippocampus. The hippocampus is closely involved in cognitive function, and changes in its cell metabolism can lead to cognitive dysfunction. It has been found that carotid stenosis can lead to insufficient cerebral perfusion in the frontal lobe, decreasing of NAA/Cr metabolites in the hippocampus and damaging cerebral cortical connective fibers [22]. Carotid angioplasty can improve the cognitive function and cellular metabolism of such patients. Similar effects may occur in patients with vertebrobasilar artery stenosis after ESAA. Blood perfusion increased in patients after ESAA, which improved the blood and energy supply to neurons in the hippocampus, and also improved the metabolism of neurons and restored brain and nerve function. (3) The recurrence of posterior circulation infarction was reduced. Symptomatic arterial stenosis is an important risk factor for cerebral infarction in patients with severe vascular stenosis, which can occur with or without symptomatic cerebral infarction, especially in the key part of cerebral infarction, which is more likely to cause cognitive damage. When ESAA was used to treat vertebrobasilar artery stenosis, atherosclerotic plaques were covered by stents to prevent plaque from falling off and to reduce the incidence of cerebral infarction and prevent cognitive impairment of stroke after stenting. In this study, patients with symptomatic vertebrobasilar artery stenosis were followed up for 1 year, and no recurrence of stroke was found.

Due to the severity and harmfulness of posterior circulation ischemia, early and aggressive intervention is extremely important in secondary prevention of stroke. Traditionally, the treatment of patients with symptomatic vertebrobasilar arterial stenosis mainly included medical treatment, surgical treatment, and endovascular treatment based on actively controlling the risk factors of atherosclerosis. The complexity and complications of surgery limit its use in these patients [36–38]. In recent years, with the advancement of interventional techniques and materials, ESAA has become an effective method for the treatment of symptomatic vertebrobasilar stenosis due to small trauma and exact effect [4,7,39,40]. None of the randomized controlled trials that compared medical treatment versus endovascular treatment in patients with symptomatic vertebral artery stenosis identified any clear-cut difference in the safety and efficacy with respect to secondary stroke prevention and vascular event outcomes, and currently there is no clear evidence to guide treatment [41–43]. The present study found that ESAA can prevent recurrence of stroke and improve non-somatic symptoms in patients, as well as affecting cell metabolism in the hippocampus of elderly patients with symptomatic vertebrobasilar stenosis. In this regard, our findings offer some suggestions for alternative indications for treating symptomatic atherosclerotic vertebrobasilar stenosis.

Our study has certain shortcomings that deserve mention (1) This was a single-center study with a small number of patients and no control group. (2) The follow-up time was too short to assess long-term improvement of cognitive function. (3) Although brain cellular metabolism combined with brain perfusion testis provides stronger evidence, we did not evaluate brain perfusion. Our results need to be confirmed by controlled clinical studies.

## Conclusions

For elderly patients with symptomatic vertebrobasilar artery stenosis, intravascular stenting can not only reduce the recurrence rate of stroke, but also improves cognitive function and changes in cellular metabolism in the hippocampus. The mechanism underlying the improvement of cognitive function may be related to the influence of cellular metabolism in the hippocampus.

## Conflict of interest

None.



## References:

1. Markus HS, van der Worp HB, Rothwell PM: Posterior circulation ischaemic stroke and transient ischaemic attack: Diagnosis, investigation, and secondary prevention. *Lancet Neurol*, 2013; 12(10): 989–98
2. Merwick Á, Werring D: Posterior circulation ischaemic stroke. *BMJ*, 2014; 348: g3175
3. Nouh A, Remke J, Ruland S: Ischemic posterior circulation stroke: A review of anatomy, clinical presentations, diagnosis, and current management. *Front Neurol*, 2014; 5: 1–16
4. Yan Y, Liang L, Chen T et al: Treatment of symptomatic vertebrobasilar artery stenosis with stent-assistant angioplasty in the elderly. *Rev Assoc Med Bras*, 2012; 58(4): 422–26
5. Stayman AN, Nogueira RG, Gupta R: A systematic review of stenting and angioplasty of symptomatic extracranial vertebral artery stenosis. *Stroke*, 2011; 42(8): 2212–16
6. Li J, Zhao ZW, Gao GD et al: Wingspan stent for high-grade symptomatic vertebrobasilar artery atherosclerotic stenosis. *Cardiovasc Intervent Radiol*, 2012; 35(2): 268–78
7. Wang J, Zhong C, Zhang Y et al: Seven years' follow-up of comparative study between stenting and medication for treatment of symptomatic vertebrobasilar artery stenosis. *Interv Neuroradiol*, 2018; 24(1): 43–50
8. Yan Y, Liang L, Yuan Y et al: Influence of stent-assisted angioplasty on cognitive function and affective disorder in elderly patients with symptomatic vertebrobasilar artery stenosis. *Med Sci Monit*, 2014; 20: 1129–36
9. Sacco RL, Kasner SE, Broderick JP et al: An updated definition of stroke for the 21st century: a statement for healthcare professionals from the American Heart Association/American Stroke Association. *Stroke*, 2013; 44(7): 2064–89
10. Wang W, Jiang B, Sun H et al: Prevalence, incidence, and mortality of stroke in China: Results from a nationwide population-based survey of 480 687 adults. *Circulation*, 2017; 135(8): 759–71
11. Wu S, Wu B, Liu M et al: Stroke in China: Advances and challenges in epidemiology, prevention, and management. *Lancet Neurol*, 2019; 18(4): 394–405
12. Zhou M, Wang H, Zhu J et al: Cause-specific mortality for 240 causes in China during 1990–2013: a systematic subnational analysis for the Global Burden of Disease Study, 2013. *Lancet*, 2016; 387(10015): 251–72
13. GBD 2016 Healthcare Access and Quality Collaborators: Measuring performance on the Healthcare Access and Quality Index for 195 countries and territories and selected subnational locations: a systematic analysis from the Global Burden of Disease Study 2016. *Lancet*, 2018; 391(10136): 2236–71
14. Benjamin EJ, Blaha MJ, Chiuve SE et al: Heart disease and stroke statistics-2017 update: A report from the American Heart Association. *Circulation*, 2017; 135(10): e146–603
15. Robinson RG, Jorge RE: Post-stroke depression: A review. *Am J Psychiatry*, 2016; 173(3): 221–31
16. Pucite E, Krievina I, Miglane E et al: Influence of severe carotid stenosis on cognition, depressive symptoms and quality of life. *Clin Pract Epidemiol Ment Health*, 2017; 13: 168–80
17. Tu J, Wang LX, Wen HF et al: The association of different types of cerebral infarction with post-stroke depression and cognitive impairment. *Medicine (Baltimore)*, 2018; 97(23): e10919
18. Barnes DE, Alexopoulos GS, Lopez OL et al: Depressive symptoms, vascular disease, and mild cognitive impairment: findings from the Cardiovascular Health Study. *Arch Gen Psychiatry*, 2006; 63(3): 273–79
19. Demougeot C, Garnier P, Mossiat C et al: N-Acetylaspartate, a marker of both cellular dysfunction and neuronal loss: its relevance to studies of acute brain injury. *J Neurochem*, 2001; 77(2): 408–15
20. Garnett MR, Blamire AM, Rajagopalan B et al: Evidence for cellular damage in normal-appearing white matter correlates with injury severity in patients following traumatic brain injury: A magnetic resonance spectroscopy study. *Brain*, 2000; 123(Pt 7): 1403–9
21. Cecil KM, Hills EC, Sandel ME et al: Proton magnetic resonance spectroscopy for detection of axonal injury in the splenium of the corpus callosum of brain-injured patients. *J Neurosurg*, 1998; 88(5): 795–801
22. Wang T, Xiao F, Wu G et al: Impairments in brain perfusion, metabolites, functional connectivity, and cognition in severe asymptomatic carotid stenosis patients: An integrated MRI study. *Neural Plast*, 2017; 2017: 8738714
23. Bo M, Massaia M, Speme S et al: Risk of cognitive decline in older patients after carotid endarterectomy: An observational study. *J Am Geriatr Soc*, 2006; 54(6): 932–36
24. Zhou Z, Zhang Y, Zhu C et al: Cognitive functions of carotid artery stenosis in the aged rat. *Neuroscience*, 2012; 219: 137–44
25. Schulz UG, Fischer U: Posterior circulation cerebrovascular syndromes: diagnosis and management. *J Neurol Neurosurg Psychiatry*, 2017; 88(1): 45–53
26. Duncombe J, Kitamura A, Hase Y et al: Chronic cerebral hypoperfusion: A key mechanism leading to vascular cognitive impairment and dementia. Closing the translational gap between rodent models and human vascular cognitive impairment and dementia. *Clin Sci (Lond)*. 2017; 131(19): 2451–68
27. Keage HA, Kurylowicz L, Lavrencic LM et al: Cerebrovascular function associated with fluid, not crystallized, abilities in older adults: A transcranial Doppler study. *Psychol Aging*, 2015; 30(3): 613–23
28. Keage HA, Churches OF, Kohler M et al: Cerebrovascular function in aging and dementia: A systematic review of transcranial Doppler studies. *Dement Geriatr Cogn Dis Extra*, 2012; 2(1): 258–70
29. Picano E, Bruno RM, Ferrari GF et al: Cognitive impairment and cardiovascular disease: So near, so far. *Int J Cardiol*, 2014; 175(1): 21–29
30. Lattanzi S, Carbonari L, Pagliariccio G et al: Neurocognitive functioning and cerebrovascular reactivity after carotid endarterectomy. *Neurology*, 2018; 90(4): e307–15
31. Lattanzi S, Carbonari L, Pagliariccio G et al: Predictors of cognitive functioning after carotid revascularization. *J Neurol Sci*, 2019; 405: 116435
32. Fiorella D, Chow MM, Anderson M et al: A 7-year experience with balloon-mounted coronary stents for the treatment of symptomatic vertebrobasilar intracranial atheromatous disease. *Neurosurgery*, 2007; 61(2): 236–43
33. Cheng HL, Lin CJ, Soong BW et al: Impairments in cognitive function and brain connectivity in severe asymptomatic carotid stenosis. *Stroke*, 2012; 43(10): 2567–73
34. Sun D, Zhang J, Fan Y et al: Abnormal levels of brain metabolites may mediate cognitive impairment in stroke-free patients with cerebrovascular risk factors. *Age Ageing*, 2014; 43(5): 681–86
35. Pereira FM, Ferreira ED, de Oliveira RM et al: Time-course of neurodegeneration and memory impairment following the 4-vessel occlusion/internal carotid artery model of chronic cerebral hypoperfusion in middle-aged rats. *Behav Brain Res*, 2012; 229(2): 340–48
36. Ausman JI, Diaz FG, Vacca DF et al: Superficial temporal and occipital artery bypass pedicles to superior, anterior inferior, and posterior inferior cerebellar arteries for vertebrobasilar insufficiency. *J Neurosurg*, 1990; 72(4): 554–58
37. Blacker DJ, Flemming KD, Wijdticks EF: Risk of ischemic stroke in patients with symptomatic vertebrobasilar stenosis undergoing surgical procedures. *Stroke*, 2003; 34(11): 2659–63
38. Borhani Haghghi A, Edgell RC, Cruz-Flores S et al: Vertebral artery origin stenosis and its treatment. *J Stroke Cerebrovasc Dis*, 2011; 20(4): 369–76
39. Markus Hugh S, Drazyk Anna M: Recent advances in the management of symptomatic vertebral artery stenosis. *Curr Opin Neurol*, 2018; 31(1): 1–7
40. Markus HS, Larsson SC, Dennis J et al: Vertebral artery stenting to prevent recurrent stroke in symptomatic vertebral artery stenosis: The VIST RCT. *Health Technol Assess*, 2019; 23(41): 1–30
41. Lattanzi S, Brigo F, Di Napoli M et al: Endovascular treatment of symptomatic vertebral artery stenosis: A systematic review and meta-analysis. *J Neurol Sci*. 2018; 391: 48–53
42. Compter A, van der Worp HB, Schonewille WJ et al: Stenting versus medical treatment in patients with symptomatic vertebral artery stenosis: A randomised open-label phase 2 trial. *Lancet Neurol*, 2015; 14(16): 606–14
43. Markus HS, Larsson SC, Kuker W et al: Stenting for symptomatic vertebral artery stenosis: The Vertebral Artery Ischaemia Stenting Trial. *Neurology*, 2017; 89(12): 1229–36