



Contents lists available at ScienceDirect

## International Journal of Surgery Case Reports

journal homepage: [www.casereports.com](http://www.casereports.com)

# Complication of Hirschsprung's disease immediately after pregnancy: A rare case report

William Sergi\*, Francesco Serra, Giovanni Cucciarre, Nicola De Ruvo, Roberta Gelmini

Department of Surgery, University of Modena and Reggio Emilia – Policlinico of Modena, Via del Pozzo, 71, 41100, Modena, Italy

## ARTICLE INFO

### Article history:

Received 21 March 2021

Received in revised form 8 April 2021

Accepted 8 April 2021

Available online 15 April 2021

### Keywords:

Hirschsprung

Volvulus

Duhamel

Colorectal surgery

Pregnancy

## ABSTRACT

**INTRODUCTION AND IMPORTANCE:** Hirschsprung's disease (HD) is a rare congenital colonic disorder that may develop in adult age, often determining a poor life quality with complications needing an emergency surgical setting. The disease rarely presents as an acute intestinal obstruction like SV, which represents an abdominal emergency issue.

**CASE PRESENTATION:** A few days after discharge from gynecology unit because of her first childbirth, a young woman with HD developed colonic obstruction due to sigmoid volvulus, which was treated with Hartmann's procedure.

**CLINICAL DISCUSSION:** Some months later, the patient underwent a two-stage Duhamel's procedure to restore the digestive tract's continuity. Both hospital periods were free of critical events.

**CONCLUSION:** The woman regained a good quality of life: Duhamel's procedure revealed as a safe technique to use in HD adult.

© 2021 The Authors. Published by Elsevier Ltd on behalf of IJS Publishing Group Ltd. This is an open access article under the CC BY-NC-ND license (<http://creativecommons.org/licenses/by-nc-nd/4.0/>).

## 1. Introduction

Hirschsprung's disease is a motor disorder in the gut due to the absence of ganglion cells in the submucosal and myenteric plexus of the distal bowel. Most cases become manifest during the neonatal period, but in rare instances, this disease is initially diagnosed in adult age [2]. Hirschsprung's disease (HD) is an uncommon cause of a long and redundant sigmoid colon with an elongated mesentery prone to rotating on itself, eventually conditioning sigmoid volvulus (SV).

HD usually presents as severe constipation, with colonic dilatation proximal to the aganglionic segment. The treatment is surgical, removing the aganglionic part and restoring continuity of the digestive tract. The disease rarely presents as an acute intestinal obstruction like SV, which represents an abdominal emergency issue. We report the case of a young woman with a previous diagnosis in childhood, which soon after childbirth presented a massive sigmoid dilatation as a volvulus, with imminent risk of perforation that forced to perform emergency surgery.

The work was written in line with the SCARE criteria [1].

**Abbreviations:** CT, computerized tomography; HD, Hirschsprung's disease; SV, sigmoid volvulus; WBC, white blood cells.

\* Corresponding author.

E-mail addresses: [willi.sergi@hotmail.it](mailto:willi.sergi@hotmail.it) (W. Sergi),

[serrafrancescomd@gmail.com](mailto:serrafrancescomd@gmail.com) (F. Serra), [g.cucciarre@icloud.com](mailto:g.cucciarre@icloud.com) (G. Cucciarre),

[deruvo.nicola@aou.mo.it](mailto:deruvo.nicola@aou.mo.it) (N. De Ruvo), [roberta.gelmini@unimore.it](mailto:roberta.gelmini@unimore.it) (R. Gelmini).

<https://doi.org/10.1016/j.ijscr.2021.105893>

2210-2612/© 2021 The Authors. Published by Elsevier Ltd on behalf of IJS Publishing Group Ltd. This is an open access article under the CC BY-NC-ND license (<http://creativecommons.org/licenses/by-nc-nd/4.0/>).

## 2. Case report

In January 2019, a 27-years-old woman referred to a Gynecology Unit in a district hospital three days after her first childbirth. Her past medical record was characterized ten years earlier by a diagnosis of Hirschsprung's disease, which caused recurrent constipation with neither need of enemas or laxatives nor of repeated hospitalizations.

In the previous weeks, the patient referred nausea, abdominal distension and pain with persistent constipation, refractory to enemas and oral laxatives. Abdominal X-rays showed an abnormal bowel distension with multiple air-fluid levels in right upper quadrants without signs of perforation (Fig. 1); laboratory tests showed WBC  $7.61 \times 10^3/\text{mL}$ , HB 7.7 g/dl, C-reactive protein 2 mg/dl, lactic acid 1.1 mmol/l, D-dimer 1700 ng/mL.

After referral to Emergency at Policlinico of Modena, the patient showed instability of hemodynamic parameters, with hypotension, tachycardia and tachypnea without fever, with visible distortion of abdominal silhouette (Fig. 2).

She was rapidly admitted to the Intensive Care Unit and, after surgical evaluation, a likely suspicion of toxic megacolon was raised, which indicated a complete abdominal CT-scan. This exam revealed an abnormal sigmoid distension with the aspect of volvulus, starting at 20 cm from the anal verge, transverse diameter of 22 cm, associated with liquid effusion in right quadrants (Fig. 3).

After an unsuccessful attempt of endoscopic derotation, an emergency laparotomy was performed. At surgical exploration a huge sigmoid volvulus occupied every abdominal quadrant (Fig. 4);

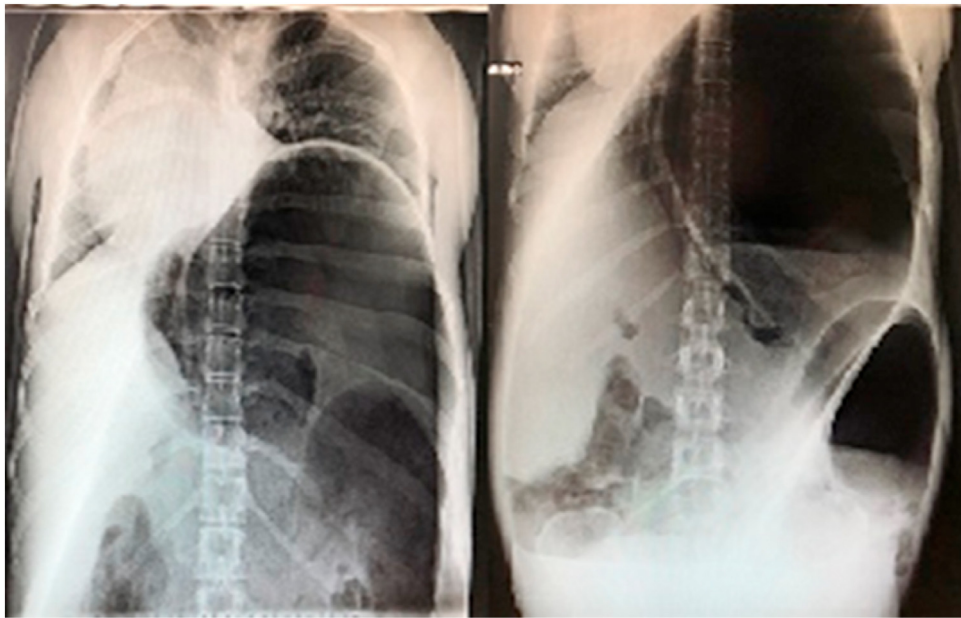

Fig. 1. Abdomen X-rays showed colonic obstruction.

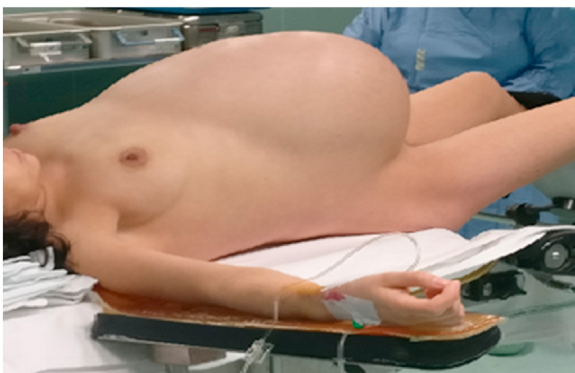

Fig. 2. Altered abdominal silhouette of the patient.

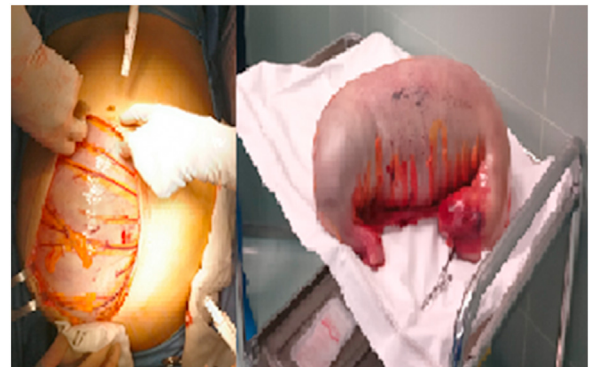

Fig. 4. Enormous sigmoid volvulus occupied all abdominal quadrants.

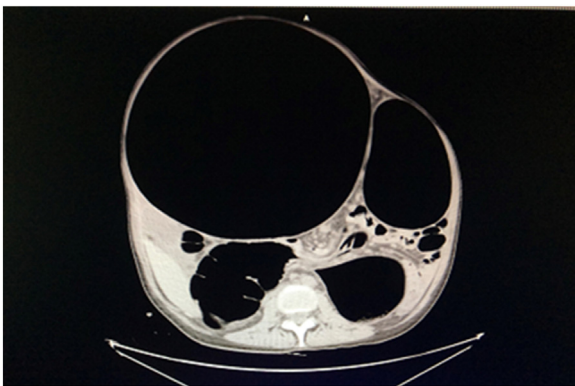

Fig. 3. Suspicious megacolon in CT-scan.

the sigmoid wall was free of necrotic features, the rectum was collapsed but no visible mechanical cause of obstruction was retrieved. Manual derotation of volvulus and execution of Hartmann's resection with temporary colostomy was subsequently operated.

After surgery, the patient was readmitted to ICU, and after two days transferred to our surgical unit. The clinical course was regular, and she rapidly regained normal colonic functions as colostomy

appeared well docked and functional, and was finally discharged in six days after resuming a regular diet.

The specimen length was 92 cm e was markedly distended; pathological examination revealed loss of haustra with the vanishing of normal colonic plication and the presence of petechial haemorrhage; the most remarkable feature was complete absence of ganglionic cells in submucosal and muscular layers in the distal 20 cm of the specimen. A confirmed diagnosis of Hirschsprung's disease was accepted, whereas the sigmoid volvulus was its complication, appeared at the term of pregnancy: a sporadic kind of clinical presentation of HD.

During the outpatient follow-up the young woman executed a barium enema through the stoma and the rectum: it showed the regular backward passage of contrast enema and absence of stenotic areas or spillage points (Fig. 5).

After six months from the first operation, restoration of continuity of intestinal tract by the Duhamel procedure was proposed, consented by the patient and performed in two stages.

The first stage consisted of a repeat laparotomy. The colostomy was taken down and resected, the left colon was fully mobilized with ligation of the inferior mesenteric artery at its origin, with no preservation of the left colic artery. After mobilization of the mesorectum, a mucosal-submucosal posterior semicircular detachment of the anal canal was performed, so obtaining a 6 ×

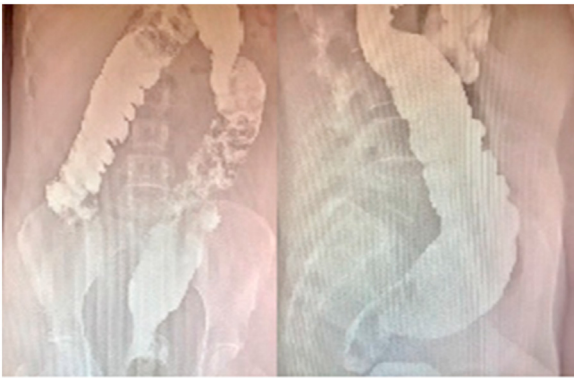


Fig. 5. Post-operative barium enema.

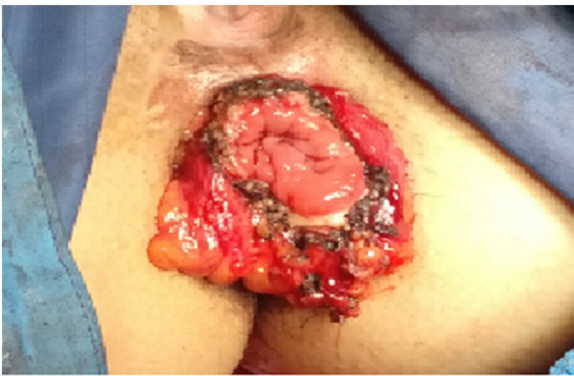

Fig. 6. Result of Duhamel procedure (first stage): the perineal colostomy.

6 cm pouch on the posterior wall of rectum. The left colon was pulled through the posterior wall of rectum, and Duhamel's perineal colostomy wrapping was performed (Fig. 6). A Jackson-Pratt aspirating drainage was left in the pelvis. The total operating time was 348 min.

After two weeks, the second stage of Duhamel's procedure was executed, during which a perineal step consisted of a mechanic anastomosis between the externalized descending colon and the rectal stump. To avoid post-surgical stenosis, the surgeon applied some mucous-mucosal absorbable sutures on the posterior wall of the anastomosis. The total procedure time was only 85 min.

The patient was discharged five days after the second procedure with no complication whatsoever and 19 days of hospital stay. During follow-up, the patient referred complete return to normal faecal continence in one week, with 2–3 bowel movements daily. After two weeks more, anoscopy showed an absence of stenosis or fissures of the anastomosis. After one month from surgery, a control barium enema reported normal transit and absence of notches (Fig. 7).

### 3. Discussion

Hirschsprung's disease usually presents in the neonatal period (1 in 5.000 live births), but only a few cases remain undiscovered after five years of age. Only 300 cases of HD have been described in adults, with male predominance at a 4:1 rate [2]. The patients' age ranges between 10 and 73 years; half of the patients are younger than 30 years. Nowadays, the adult incidence is unknown as this diagnosis is often overlooked in the adult population [3–6].

The main feature of HD is the absence in the affected segment of the large bowel of ganglion cells in Meissner's submucosal plexus and Auerbach's myenteric plexus, because of a lack of migration of neuroblasts from the neural crest to the large intestine dur-

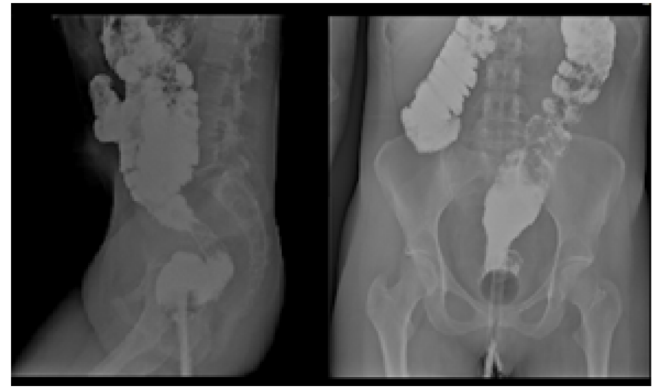


Fig. 7. Barium enema performed one month after Duhamel's procedure: absence of stenosis or fissures.

ing embryonic period. Other possible hypotheses propose defects in the neuroblast differentiation and accelerated destruction of intestinal ganglion cells [5]. RET proto-oncogene is the most frequent mutation among over eight, consistently detected in this disease (50 % of familial cases and 20 % of sporadic) [7]. The aganglionic segment remains always contracted, while proximal segment retains peristalsis; this results in hypertrophy, megacolon and sometimes perforation of normally innervated segment [2].

Typically, adolescent and adult people with HD present with lifelong constipation typically refractory to treatment. Most patients regularly need enemas for defecation (73–92 %), whose frequency ranges from once a week to once every 2 months [5]; multiple hospitalizations for abdominal pain with distention and partial bowel obstruction are unfortunately recurrent. Other symptoms are abdominal distention, pain and defense (83–86 %), frequent palpable fecal mass (50–56 %) or fecal impaction (25–36 %). Fecal incontinence is typical in children but not in adults.

Despite multiple medical visits, the diagnosis typically remains elusive. In adults, it is much harder than in children due to their rarity as they have often short or ultrashort aganglionic segments, which produce mild symptoms in early stages of the disease. Plain films typically show a massive expansion of proximal colon, with a small distal segment. A CT scan is a helpful tool, not only to show the transition zone, but to exclude other causes of chronic constipation and megacolon in adults [3]. The diagnosis is made by barium enema, anorectal manometry and rectal biopsy. The key finding in barium enema is the existence of a transition zone named "funnel" between distal aganglionic bowel (normal or narrow) and proximal dilated. Not displaying this transition zone does not exclude the diagnosis of HD. Anorectal manometry shows lack of relaxation of internal anal sphincter in response to rectal distension. Confirmation of diagnosis is provided by rectal biopsy of the narrow segment (93 % sensitivity and 100 % specificity) [10]. The rectal biopsy should be made on the back side of the rectum, about 6 cm in height, and it shows absence of ganglion cells, nerve fibres hyperplasia and an increased level of acetylcholinesterase [11].

Surgery should be considered the treatment of choice, to remove the aganglionic segment and restore digestive continuity. The surgical approach will depend on the length of aganglionic area, length and reversibility of colonic dilatation, and nutritional status of patient.

Volvulus is a rare complication of HD. It has been described in children and adults with previously undiagnosed short-segment HD and occasionally in infants [12–15]. The volvulus usually involves the sigmoid colon and, less commonly, the transverse or cecal segments. The cause is thought to be related to torsion of an enlarged colonic segment filled with meconium or faeces. Excessive mobility of the sigmoid mesentery may also have a role [16].

Clinical manifestations are similar to those seen in patients with volvulus caused by other conditions, including abdominal pain, distension, and vomiting (eventually bilious). Typically, patients also have historical features, such as failure to pass meconium (in the neonate) or chronic constipation (in older children), suggesting the underlying disease

The diagnosis is suggested on plain abdominal radiographs, which will reveal distended intestinal loops and air–fluid levels consistent with obstruction [16]. A contrast enema should determine the diagnosis of the disease and, also, should detorse the volvulus. The initial approach to detorsion may include contrast enema or colonoscopy with rectal tube placement in the stable patient. Intravenous fluids and antibiotics should be administered. Surgery is indicated if detorsion is unsuccessful, there are signs of peritonitis, or bowel necrosis or perforation is suspected. Hirschsprung's disease was already known in our patient but was exacerbated by pregnancy: this is a rarely reported phenomenon [8,9].

Moreover, in our case, volvulus may rarely occur as massive colonic dilatation with risk of perforation, which requires emergency surgery, so we opted at that moment for a Hartmann's procedure with the resection of this affected tract and the realization of a temporary colostomy.

Several procedures have been designed to treat HD, but one of paramount importance is the Duhamel technique [18]. This rather complex procedure appeared to be associated with a lower rate of major postoperative complications than others, and carried a higher rate of good long-term results [10,17]. Excellent results have also been described using Duhamel retro-rectal pull-through for the treatment of adult patients. The most significant experience with this procedure has been reported in three articles from St. Mark's Hospital in London [18,19]. Compared with the Soave and Swenson procedures, it is superior in terms of impotence rate, anastomotic dehiscence and reservoir function to minimize soiling. It has confirmed a consistent improvement in the functional outcome [11,20–22].

Although rarely performed nowadays, our patient was treated with a Duhamel procedure to restore the intestinal transit by perineal colostomy: the result after this procedure has proved excellent and durable after time from discharge. Of course, the execution of similar surgical maneuvers needs the skills of a very expert colorectal and proctological surgeon.

As far as the literature is concerned, this is a very rare case of Duhamel's procedure performed in adult patient; the uniqueness is this reconstruction was performed in second time after a Hartmann's procedure.

#### 4. Conclusions

Hirschsprung's disease is a congenital condition that requires possible surgical management in childhood; it's rarely discovered in adults, often in complicated settings that need emergency approach. According to with literature, Duhamel's procedure is a safe technique to restore the continuity of intestinal tract, with long-term good outcomes, as in our case, and complete return to a normal quality of life. The aim of this paper is to report and remember a surgical technique that is rarely used but, in selected cases, should be helpful to practice.

#### Sources of funding

Non funding were used.

#### Ethical Approval

No ethical approval was required.

#### Consent

The submitted case report was not a study, therefore no ethical approval or informed written consent was needed.

The patient's parents signed the informed written consent to the surgical procedure and an explicit permission to use personal details and data.

#### Author's contribution

Sergi William: Data collection, manuscript writing and co-author.

Serra Francesco: Design of manuscript and co-author.

Cucciarrè Giovanni: Data collection.

De Ruvo Nicola: Data collection.

Gelmini Roberta: Supervisor and co-author of entire manuscript.

#### Registration of Research Studies

Not applicable.

#### Guarantor

Gelmini Roberta.

#### Provenance and peer review

Not commissioned, externally peer-reviewed.

#### Declaration of Competing Interest

No conflicts of interest.

#### References

- [1] R.A. Agha, T. Franchi, C. Sohrabi, G. Mathew, for the SCARE Group, The SCARE 2020 guideline: updating consensus Surgical CAse REport (SCARE) guidelines, *Int. J. Surg.* 84 (2020) 226–230.
- [2] A.A. Bakari, B.M. Gali, A.G. Ibrahim, et al., Congenital aganglionic megacolon in Nigerian adults: two case reports and review of the literature, *Niger. J. Clin. Pract.* 14 (2011) 249–252.
- [3] F. Chen, J. Winston, S. Jain, et al., Hirschsprung's disease in a young adult: report of a case and review of the literature, *Ann. Diagn. Pathol.* (2006).
- [4] M. Miyamoto, K. Egami, S. Maeda, et al., Hirschsprung's disease in adults: report of a case and review of the literature, *J. Nippon Med. Sch.* 72 (2005) 113–120.
- [5] C.G. Fu, T. Muto, T. Masaki, et al., Zonal adult Hirschsprung's disease, *Gut* 39 (1996) 765–767.
- [6] G. Martucciello, I. Ceccherin, M. Lerone, et al., Pathogenesis of Hirschsprung's disease, *J. Pediatr. Surg.* 35 (2000) 1017–1025.
- [7] A. Arshad, C. Powell, M.P. Tighe, Hirschsprung's disease, *BMJ* 345 (2012) e5521.
- [8] A. Hjortrup, J. Friis, K. Mauritzen, Aggravation of untreated Hirschsprung's disease during pregnancy, *Acta. Obstet. Gynecol. Scand.* 61 (1982) 381–382.
- [9] P.R. Meier, E. Morfin, Hirschsprung's disease complicating pregnancy, *Am. J. Gastroenterol.* 74 (1980) 36–39.
- [10] J.L. Faucheron, D. Poncet, D. Voirin, et al., Maladie de Hirschsprung chez l'adulte, in: *EMC. Techniques chirurgicales appareil digestif*, Elsevier Masson SAS, Paris, 2009, pp. 40–602.
- [11] G.I. Vorobyov, S.I. Achkasov, O.M. Biryukov, Clinical features, diagnostics and treatment of Hirschsprung's disease in adults, *Colorectal Dis.* 12 (2010) 1242–1248.
- [12] Dean Go, J.W. Murry, Volvulus of the sigmoid colon, *Ann. Surg.* 135 (1952) 830.
- [13] I.R. Neilson, S. Youssef, Delayed presentation of Hirschsprung's disease: acute obstruction secondary to megacolon with transverse colonic volvulus, *J. Pediatr. Surg.* 25 (1990) 1177.
- [14] F.L. Tan, Y.M. Tan, S.M. Heah, F. Seow-Choen, Adult Hirschsprung's disease presenting as sigmoid volvulus: a case report and review of literature, *Tech. Coloproctol.* 10 (2006) 245.
- [15] H. Khalayleh, B.Z. Koplewitz, V. Kapuller, et al., Neonatal sigmoid volvulus, *J. Pediatr. Surg.* 51 (2016) 1782.
- [16] A. Sarioğlu, F.C. Tanyel, N. Büyükpamukçu, A. Hiçsönmez, Colonic volvulus: a rare presentation of Hirschsprung's disease, *J. Pediatr. Surg.* 32 (1997) 117.

- [17] M. Miyamoto, K. Egami, S. Maeda, K. Ohkawa, N. Tanaka, E. Uchida, T. Tajiri, Hirschsprung's disease in adults: report of a case and review of the literature, *J. Nippon Med. Sch.* 72 (2) (2005).
- [18] M.S. Elliot, I.P. Todd, Adult Hirschsprung's disease: results of the Duhamel procedure, *Br. J. Surg.* 72 (1985) 884–885.
- [19] P.R. Barnes, J.E. Lennard-Jones, P.R. Hawley, I.P. Todd, Hirschsprung's disease and idiopathic megacolon in adults and adolescents, *Gut* 27 (1986) 534–541.
- [20] S.W. Moore, R. Albertyn, S. Cywes, Clinical outcome and long term quality of life after surgical correction of Hirschsprung's disease, *J. Pediatr. Surg.* 31 (1996) 1496–1502.
- [21] Y. Bai, H. Chen, J. Hao, et al., Long-term outcome and quality of life after the Swenson procedure for Hirschsprung's disease, *J. Pediatr. Surg.* 37 (4) (2002) 639–642.
- [22] F. Soave, Hirschsprung's disease: a new surgical technique, *Arch. Dis. Child.* 39 (1964) 116–124.

#### Open Access

This article is published Open Access at [sciencedirect.com](https://www.sciencedirect.com). It is distributed under the [IJSCR Supplemental terms and conditions](#), which permits unrestricted non commercial use, distribution, and reproduction in any medium, provided the original authors and source are credited.