

Therapeutic challenges in pregnant women with paroxysmal nocturnal hemoglobinuria

A case report

Juliana Marques Coelho Bastos, MD^{a,b,*}, Patrícia Leal Pinheiro, MD^{a,b}, Lissa Canedo Rocha, MD^a, Elisa Cao Bicalho, MD^a, Alessandra Barbosa Cazeli, MD^c, Sibia Soraya Marcondes, MD^c, Gustavo Carreiro Pinasco, MD, MS^{b,d,e}

Abstract

Introduction: Paroxysmal nocturnal hemoglobinuria (PNH) is a rare acquired disease, arising from the mutation of clonal hematopoietic stem cells, with an estimated incidence of 1 to 5 cases per million individuals. In pregnant women, adequate information regarding the prevalence of PNH is lacking, and its management has been a challenge because of the significant complications in this group. The condition is diagnosed based on clinical findings and laboratory tests. Eculizumab, the drug of choice for the treatment of PNH, reduces hemolysis and stabilizes hemoglobin levels, thereby decreasing the need for blood transfusions and improving the overall quality of life.

Case presentation: A 38-year-old woman was diagnosed with PNH in 2007 and eculizumab therapy was initiated at the end of 2014. She became pregnant in September 2015 and presented various decompensations from forced reductions in therapy due to the nonavailability of eculizumab. The pregnancy was interrupted in week 35, but the well-being of the newborn was not compromised. The patient, however, had to remain hospitalized for resolution of acute kidney insufficiency, anemia, and intense hemolysis, which were reverted by means of intravenous hydration, transfusion of 10 packed red blood cell units, and eculizumab therapy.

Conclusion: The rarity of the disease and the lack of protocols for its management during pregnancy hampered the treatment of the patient. However, the symptoms were progressively treated as they appeared, based on laboratory tests since it was necessary to circumvent and handle the lack of eculizumab which was not readily available in Brazil's Public Health System.

Abbreviations: AKI = acute kidney insufficiency, CKD = chronic kidney disease, GPI = glycosylphosphatidylinositol, Hb = hemoglobin, LDH = lactate dehydrogenase, PNH = paroxysmal nocturnal hemoglobinuria.

Keywords: case report, eculizumab, high-risk pregnancy, paroxysmal nocturnal hemoglobinuria

1. Introduction

Paroxysmal nocturnal hemoglobinuria (PNH), a rare and acquired hemolytic anemia, is caused by an alteration of hematopoietic stem cells resulting from a somatic mutation in the *PIGA* gene.^[1,6] This gene is involved in the synthesis of glycosylphosphatidylinositol (GPI), an anchor for various membrane proteins, such as the CD55 (complement decay-accelerating factor) and CD59 (membrane inhibitor of reactive

lysis), which are regulators of the complement system.^[1–4,6,7] GPI deficiency in PNH results in multiple proteins not being expressed on the cell surface, making the cells exceptionally susceptible to the lytic effects of the complement system.^[1,2]

Due to the rarity of the disease and difficulty in its diagnosis, the exact incidence of PNH is not fully known.^[1] At an estimated 1 to 5 cases per million individuals, it is believed to be common among the Orientals, principally the South Asians.^[1,8] PNH can occur at any age, but a higher incidence has been observed in the third decade of life, with a comparable distribution between the 2 sexes.^[4,9] The diagnosis of PNH is made through clinical findings, immunophenotyping by flow cytometry and analysis of the *PIGA* gene.^[10,11]

Symptoms of PNH usually include fatigue, dyspnea, abdominal pain, pulmonary hypertension, thrombotic events, and chronic kidney disease (CKD).^[4,6] Thrombocytopenia, leucopenia, and bone marrow failure are common and contribute to disease-related mortality and morbidity.^[13] In addition, intravascular hemolysis is seen in affected individuals, as the erythrocytes are more susceptible to attack by the complement system.^[14] Studies have shown that compared to the general population, patients with PNH have a 62 times higher risk of thrombotic events and 6 times higher risk of CKD.^[4]

Surgery, trauma, and pregnancy are suggested risk factors for breakthrough hemolysis.^[15] Although not always modifying the prognosis, pregnancy complicates the management of PNH, putting both the mother and fetus at a significantly higher

Editor: N/A.

The authors have no funding and conflicts of interest to disclose.

^a Escola Superior de Ciências da Santa Casa de Misericórdia de Vitória (EMESCAM), ^b Scientific Writing Office, EMESCAM, ^c Department of Hematology, EMESCAM, ^d Department of Pediatrics, EMESCAM, Vitória, ES, ^e Post-Graduate Program Stricto Sensu, Faculdade de Medicina do ABC, Santo André, SP, Brazil.

* Correspondence: Juliana Marques Coelho Bastos, Faculdade de Medicina, Escola Superior de Ciências da Santa Casa de Misericórdia de Vitória, Vitória, ES, Brazil (e-mail: julianamcbastos@hotmail.com).

Copyright © 2018 the Author(s). Published by Wolters Kluwer Health, Inc. This is an open access article distributed under the terms of the Creative Commons Attribution-Non Commercial-No Derivatives License 4.0 (CCBY-NC-ND), where it is permissible to download and share the work provided it is properly cited. The work cannot be changed in any way or used commercially without permission from the journal.

Medicine (2018) 97:36(e12155)

Received: 20 April 2018 / Accepted: 8 August 2018

<http://dx.doi.org/10.1097/MD.00000000000012155>

risk.^[5,10,16,17] There is very little information on the prevalence of PNH in pregnant women, and part of the difficulty in its diagnosis is due to other pregnancy-related clinical situations, such as the HELLP syndrome, pre-eclampsia, and thrombocytopenia that mimic PNH, leading to misdiagnosis.^[12] The complications include potentially fatal thrombotic events, infections, hemorrhaging, anemia, increased risk of abortions, infant death, and prematurity.^[13] The maternal and perinatal mortality rates can reach 20% and 10%, respectively.^[16]

Despite the high rates of morbidity, there are no well-defined protocols to manage PNH. Eculizumab has been reported to be effective for the treatment of PNH,^[2,10,11] and clinical trials have shown that it reduces hemolysis and stabilizes the levels of hemoglobin (Hb), thereby, reducing the need for blood transfusions and improving the overall quality of life.^[4,10,14,18]

Here we present the case of a 38-year-old woman with PNH who became pregnant and was treated with eculizumab. Given that there are only a few reports on PNH in pregnant women and there is a clear lack of guidelines for its management in this group of patients, we believe that this case report will be a significant contribution to the field and will lead to new studies on PNH during pregnancy.

2. Case report

A 38-year-old white woman patient was diagnosed with PNH in 2007 when she presented with persistent fatigue, epigastralgia, nausea, and hemolytic anemia. She had no history of previous thromboembolism. The diagnosis was based on clinical findings, laboratory testing, and immunophenotyping by flow cytometry, which revealed low levels of both CD55 and CD59 expression on erythrocytes and granulocytes. Since there was no specific treatment available at that time, she was treated with a corticoid, 80 mg/d.

The patient was re-admitted to the hematology clinic at the end of 2014, complaining of fatigue, epigastralgia, and choluria. This time she was started on eculizumab, a humanized monoclonal antibody that prevents erythrocytic lysis and thereby, stabilizes the levels of Hb. Two weeks prior to starting the eculizumab treatment, she was vaccinated against meningitis caused by the bacteria, *Neisseria meningitidis*, as recommended by the European Medicines Agency. The patient's blood work at the beginning of the treatment revealed the following: Hb: 12 g/dL, lactate dehydrogenase (LDH): 1111 U/L, and reticulocyte count: 117,800/mm³ (Fig. 1). The loading dose offered was 600 mg/wk for 4 weeks, followed by a maintenance treatment of 900 mg every 14 days. The patient presented no adverse effects to the medication and showed improvement in her symptoms. Since eculizumab was not registered with ANVISA (National Health Surveillance Agency), it was not easily available in Brazil's Public Health System and had to be obtained from supporting institutions.

The patient became pregnant in September 2015 and, in November of that same year, presented with clinical decompensation due to hemolysis, with the following laboratory data: Hb: 9.6 g/dL, reticulocyte count: 317,420/mm³, and LDH: 354 U/L (Fig. 1). We increased the dose of eculizumab from 900 to 1200 mg. She was also given ferrous sulfate and folic acid due to the pregnancy. The diagnosis of PNH associated with pregnancy justified the initiation of prophylaxis with enoxaparin at a dose of 60 mg, twice a day, to counter the high risk of thrombosis. There was an improvement in the symptoms after increasing the dose of

eculizumab, though the ferrous sulfate was not well tolerated, resulting in nausea and choluria during the initial days of use.

During the course of the pregnancy, the patient presented with other decompensations including anemia and epigastralgia, due to the forced reductions in the dose of eculizumab, which became unavailable. In the 35th gestational week, she presented with intense hemolysis with Hb: 3.8 g/dL, LDH: 1370 U/L, urea: 96 mg/dL, and creatinine: 5.1 mg/dL (Fig. 1), indicative of severe anemia and acute kidney insufficiency (AKI), which necessitated an early delivery.

Anticoagulation was achieved during pregnancy with enoxaparin (60 mg) every 12 hours. Closer to the delivery date, due to the weight gain, it was increased to 80 mg, which was then maintained at the initial dose of 60 mg for 45 days postpartum.

The newborn was healthy, with signs of good vitality (Apgar score 9/9) and was of normal weight (2140 g) for the gestational age. The patient, however, remained hospitalized for resolution of AKI and intense hemolytic anemia, which were reverted by means of intravenous hydration, transfusion of 10 U of packed red blood cells, and 1200 mg eculizumab given every 7 days. She was discharged after 10 days, with the following values: LDH: 472.6 U/L, Hb: 8.1 g/dL, creatinine: 2.7 mg/dL, and urea: 25 mg/dL (Fig. 1).

The patient's clinical improvement was gradual. Her condition was stable at the first consultation at the ambulatory clinic, with the following values: LDH: 370 U/L, reticulocyte count: 203,180/mm³, Hb: 10 g/dL, urea: 37 mg/dL, and creatinine: 1.83 mg/dL.

This study was approved by the Ethics Committee of Escola Superior de Ciências da Santa Casa de Misericórdia de Vitória (Protocol 59622216.0.0000.5065). The patient has given informed consent authorizing the use and disclosure of her protected health information.

3. Discussion

Eculizumab is the only therapy approved by the US Food and Drug Administration for PNH, and is, therefore, the drug of choice.^[3,5,19] It is a humanized monoclonal antibody directed against the complement C5 protein terminal, which results in the inhibition of erythrocytic cellular lysis.^[2,4,6,10,15] It reduces intravascular hemolysis and stabilizes the levels of Hb, thereby decreasing the necessity for blood transfusions and improving the overall quality of life in patients with PNH.^[3,5,6,16]

Increase in the dosage and frequency of eculizumab given as needed during pregnancy has been reported in the literature.^[2,3,6,10,13] In the present case, the dose was increased from 900 to 1200 mg, every 2 weeks. Despite not having been established, more benefits than harm have been cited with reference to the use of these intervals, between 12 and 16 days. The final decision was left to the discretionary judgment of the physician in charge.^[15] Danilov et al^[13] have reported successfully treating PNH during pregnancy by giving 600 mg of eculizumab intravenously, once a week for 4 weeks, followed by 900 mg once a week.

In this case, we opted for 1200 mg every 2 weeks, because of the unavailability of the drug. The patient responded well to this regimen, remaining asymptomatic while receiving the medication. However, the forced interruptions in the treatment again due to a lack of medication led to decompensations. Since the therapeutic objective remained the improvement of symptoms and stabilization in the levels of Hb (keeping the minimal levels around 10 mg/dL), as proposed by Melo et al,^[16] transfusions of packed red blood cells and adjuvant were required.

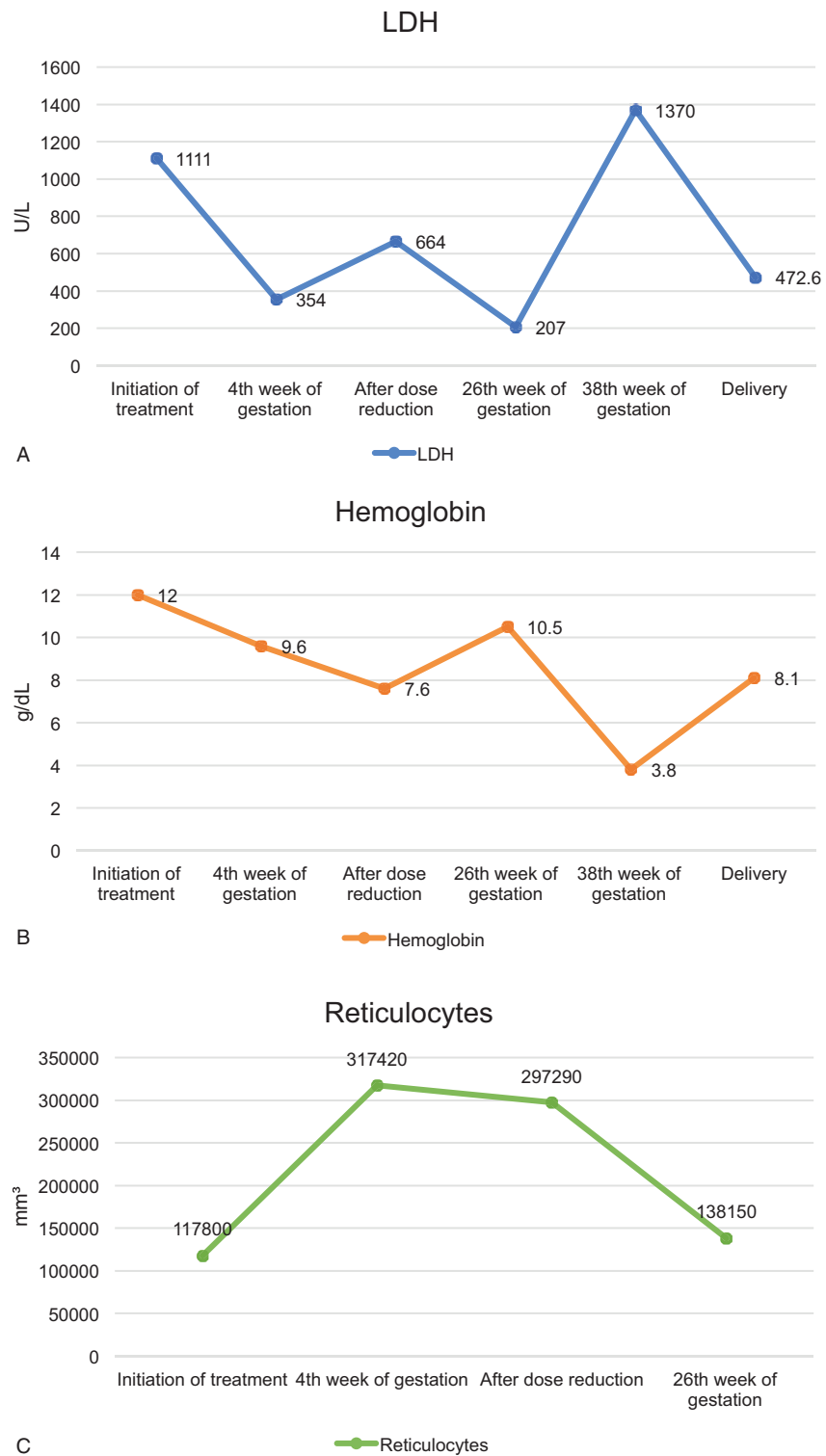


Figure 1. Changes in reticulocyte counts, levels of hemoglobin, and lactic dehydrogenase.

The effects of eculizumab on the fetus, including its permeability across the placenta and excretion in breast milk, are not well known.^[5,6,10] Therapeutic doses of eculizumab in pregnant women have been shown not to affect the complement system of the newborn.^[5] However, 1 study has detected eculizumab in samples of cord blood, leading to the conclusion

that it passes through the placenta, but the levels are not high enough to activate the complement system.^[5,6,10] Similarly, the drug is not excreted in measurable quantities in breast milk, thus making breastfeeding safe.^[5,6,10] Therefore, despite the still obscure strategies, the use of eculizumab in pregnancy produces satisfactory results, based on the findings reported in recent

studies.^[6,16] In this case, the patient had started the treatment before pregnancy, and there was no impact on the newborn. Since there is no consensus regarding the best time to start the drug, its use must be individualized, weighing the risks and benefits for each patient.

Special attention needs to be paid to pregnancy-associated thrombosis in patients with PNH. Though more than 45% of the pregnancies in women with PNH result in abortion or spontaneous interruption, maternal mortality due to fatal thrombotic events, has been reported in only about 6% of the cases.^[6,13] Other studies have shown that 29% to 44% of patients with PNH suffered at least 1 thromboembolic event during the course of their disease.^[20] Therefore, routine utilization of a low molecular load of heparin should be initiated as soon as pregnancy is confirmed, though there is no consensus on how long to use it postpartum. While some studies suggest 3 months,^[13] others suggest 1 to 2 months,^[6,16] and there are still others that do not determine the duration.^[10] In this study, a low molecular load of heparin was used for one-and-a-half months, and there were no thrombotic events.

In patients with PNH, delivery by cesarean section is the preferred choice in order to prevent maternal or fetal complications. The acceleration of fetal lung maturity is considered and is not contraindicated by PNH.^[21] In this case, the decision of cesarean delivery was obstetric and was justified by the serious clinical symptoms including hemolysis and AKI. We utilized corticoids for the acceleration of lung maturity. Studies have reported a high rate of premature births in patients with PNH,^[6] with up to 29% of the cases requiring preterm deliveries due to, among other reasons, preeclampsia, and fall in platelet counts.^[10] Melo et al^[16] have suggested that prematurity is the principal cause of perinatal fetal death, defining it as an iatrogenic cause. In this study, the due date was based on the clinical chart of the patient, after evaluating the risk of thrombosis. The well-being of the fetus was monitored by Doppler ultrasonography. Though there were no signs of fetal distress, the patient presented a high risk of thrombosis, AKI, and increased severity in symptoms, which led to the early interruption of gestation via cesarean section.^[16]

Based on the possible complications, the general consensus is that pregnant patients with PNH should be treated in tertiary hospitals, with multidisciplinary teams, including an obstetrician, hematologist, intensive care unit specialist, and anesthesiologist.^[21]

4. Conclusion

Eculizumab, which is the drug of choice to treat PNH, is expensive and is not widely available in Brazil's Public Health System. During the treatment, the clinical decompensations were sensitive to small dosage alterations, making it difficult to manage and control the disease effectively. Since the medication modifies the course of the disease, making it essential for better prognosis, and decrease in complications for this group of patients, regular and uninterrupted access to eculizumab is necessary. Further studies are required to standardize the treatment protocols, thus ensuring better outcomes in patients with PNH.

Acknowledgement

We thank the Centro Acadêmico Aloísio Sobreira Lima – CAAL for the support offered.

Author contributions

Conceptualization: Juliana Marques Coelho Bastos, Patrícia Leal Pinheiro, Sibia Soraya Marcondes, Alessandra Barbosa Cazelli, Gustavo Carreiro Pinasco.

Data curation: Juliana Marques Coelho Bastos, Patrícia Leal Pinheiro, Sibia Soraya Marcondes, Alessandra Barbosa Cazelli, Gustavo Carreiro Pinasco.

Formal analysis: Juliana Marques Coelho Bastos, Patrícia Leal Pinheiro, Lissa Canedo Rocha, Elisa Cao Bicalho, Sibia Soraya Marcondes, Alessandra Barbosa Cazelli, Gustavo Carreiro Pinasco.

Investigation: Juliana Marques Coelho Bastos, Patrícia Leal Pinheiro, Lissa Canedo Rocha, Elisa Cao Bicalho, Sibia Soraya Marcondes.

Methodology: Juliana Marques Coelho Bastos, Patrícia Leal Pinheiro, Lissa Canedo Rocha, Elisa Cao Bicalho, Sibia Soraya Marcondes, Alessandra Barbosa Cazelli, Gustavo Carreiro Pinasco.

Project administration: Juliana Marques Coelho Bastos, Patrícia Leal Pinheiro, Sibia Soraya Marcondes, Gustavo Carreiro Pinasco.

Supervision: Juliana Marques Coelho Bastos, Patrícia Leal Pinheiro, Lissa Canedo Rocha, Sibia Soraya Marcondes, Alessandra Barbosa Cazelli, Gustavo Carreiro Pinasco.

Validation: Juliana Marques Coelho Bastos, Patrícia Leal Pinheiro, Lissa Canedo Rocha, Elisa Cao Bicalho, Sibia Soraya Marcondes, Alessandra Barbosa Cazelli, Gustavo Carreiro Pinasco.

Visualization: Juliana Marques Coelho Bastos, Patrícia Leal Pinheiro, Lissa Canedo Rocha, Elisa Cao Bicalho, Sibia Soraya Marcondes, Alessandra Barbosa Cazelli, Gustavo Carreiro Pinasco.

Writing – original draft: Juliana Marques Coelho Bastos, Patrícia Leal Pinheiro, Lissa Canedo Rocha, Elisa Cao Bicalho.

Writing – review & editing: Juliana Marques Coelho Bastos, Patrícia Leal Pinheiro, Lissa Canedo Rocha, Elisa Cao Bicalho, Sibia Soraya Marcondes, Alessandra Barbosa Cazelli, Gustavo Carreiro Pinasco.

References

- [1] Arruda MM, Rodrigues CA, Yamamoto M, et al. Paroxysmal nocturnal hemoglobinuria: from physiopathology to treatment. *Rev Assoc Med Bras* 2010;56:214–21.
- [2] DeZern AE, Dorr D, Brodsky RA. Predictors of hemoglobin response to eculizumab therapy in paroxysmal nocturnal hemoglobinuria. *Eur J Haematol* 2013;90:16–24.
- [3] DeZern AE, Brodsky RA. Paroxysmal nocturnal hemoglobinuria: a complement-mediated hemolytic anemia. *Hematol Oncol Clin North Am* 2015;29:479–94.
- [4] Hillmen P, Muus P, Röth A, et al. Long-term safety and efficacy of sustained eculizumab treatment in patients with paroxysmal nocturnal haemoglobinuria. *Br J Haematol* 2013;162:62–73.
- [5] Hallstensen RF, Bergseth G, Foss S, et al. Eculizumab treatment during pregnancy does not affect the complement system activity of the newborn. *Immunobiology* 2015;220:452–9.
- [6] Al-Ani F, Chin-Yee I, Lazo-Langner A. Eculizumab in the management of paroxysmal nocturnal hemoglobinuria: patient selection and special considerations. *Ther Clin Risk Manag* 2016;12:1161–70.
- [7] Gargiulo L, Papaioannou M, Sica M, et al. Glycosylphosphatidylinositol-specific, CD1d-restricted T cells in paroxysmal nocturnal hemoglobinuria. *Blood* 2013;121:2753–62.
- [8] Hussain S, Qureshi A, Kazi J. Kidney involvement in paroxysmal nocturnal hemoglobinuria. *Nephron Clin Pract* 2013;123:28–35.
- [9] Arrizabalaga B, Colado E, Gaya A, et al. Consenso Español para el diagnóstico y tratamiento de la hemoglobinuria paroxística nocturna. *MedClin* 2016;146:278–85.

- [10] Kelly RJ, Höchsmann B, Szer J, et al. Eculizumab in pregnant patients with paroxysmal nocturnal hemoglobinuria. *N Engl J Med* 2015;373:1032–9.
- [11] Jang J, Seok Kim J, Yoon S-S, et al. Predictive factors of mortality in population of patients with paroxysmal nocturnal hemoglobinuria (PNH): results from a Korean PNH registry. *J Korean Med Sci* 2016;31:214–21.
- [12] Vekemans MC, Lambert C, Ferrant A, et al. Management of pregnancy in paroxysmal nocturnal hemoglobinuria on long-term eculizumab. *Blood Coagul Fibrinolysis* 2015;26:464–6.
- [13] Danilov AV, Smith H, Craigo S, et al. Paroxysmal nocturnal hemoglobinuria (PNH) and pregnancy in the era of eculizumab. *Leuk Res* 2009;33:2008–9.
- [14] Kelly R, Arnold L, Richards S, et al. The management of pregnancy in paroxysmal nocturnal haemoglobinuria on long term eculizumab. *Br J Haematol* 2010;149:446–50.
- [15] Nakayama H, Usuki K, Echizen H, et al. Eculizumab dosing intervals longer than 17 days may be associated with greater risk of breakthrough hemolysis in patients with paroxysmal nocturnal hemoglobinuria. *Biol Pharm Bull* 2016;39:285–8.
- [16] Melo A, Gorgal RC, Amaral J, et al. Clinical management of paroxysmal nocturnal haemoglobinuria in pregnancy: three case reports. *Blood Transfus* 2011;9:99–103.
- [17] Parker C, Omine M, Richards S, et al. Diagnosis and management of paroxysmal nocturnal hemoglobinuria. *Blood* 2005;106:3699–709.
- [18] Brodsky AR. How I treat paroxysmal nocturnal hemoglobinuria. *Blood* 2009;113:6522–7.
- [19] Risitano AM. Paroxysmal nocturnal hemoglobinuria in the era of complement inhibition. *Am J Hematol* 2016;91:359–60.
- [20] Hillmen P, Muus P, Dührsen U, et al. Effect of the complement inhibitor eculizumab on thromboembolism in patients with paroxysmal nocturnal hemoglobinuria. *Blood* 2007;110:4123–8.
- [21] Nomura ML, Surita FGC, Parpinelli MA, et al. Paroxysmal nocturnal hemoglobinuria in pregnancy. *Rev Bras Ginecol Obstet* 2004;26:579–82.