



Since January 2020 Elsevier has created a COVID-19 resource centre with free information in English and Mandarin on the novel coronavirus COVID-19. The COVID-19 resource centre is hosted on Elsevier Connect, the company's public news and information website.

Elsevier hereby grants permission to make all its COVID-19-related research that is available on the COVID-19 resource centre - including this research content - immediately available in PubMed Central and other publicly funded repositories, such as the WHO COVID database with rights for unrestricted research re-use and analyses in any form or by any means with acknowledgement of the original source. These permissions are granted for free by Elsevier for as long as the COVID-19 resource centre remains active.

# In situ hybridization technique for the detection of swine enteric and respiratory coronaviruses, transmissible gastroenteritis virus (TGEV) and porcine respiratory coronavirus (PRCV), in formalin-fixed paraffin-embedded tissues

Theerapol Sirinarumitr<sup>a</sup>, Prem S. Paul<sup>b,\*</sup>, John P. Kluge<sup>a</sup>, Patrick G. Halbur<sup>c</sup>

<sup>a</sup>Department of Veterinary Pathology, Iowa State University, 1802 Elwood Drive, Ames, IA 50011, USA

<sup>b</sup>Veterinary Medical Research Institute and the Department of Microbiology Immunology and Preventive Medicine, Iowa State University, 1802 Elwood Drive, Ames, IA 50011, USA

<sup>c</sup>Veterinary Diagnostic Laboratory, College of Veterinary Medicine, Iowa State University, 1802 Elwood Drive, Ames, IA 50011, USA

Accepted 26 June 1995

---

## Abstract

The in situ hybridization (ISH) technique was developed to detect the swine coronaviruses, transmissible gastroenteritis virus (TGEV) and porcine respiratory coronavirus (PRCV), in cell culture and tissue sections from TGEV-or PRCV-infected pigs. The <sup>35</sup>S-labeled RNA probes were generated from two plasmids pPSP.FP<sub>1</sub> and pPSP.FP<sub>2</sub> containing part of the S gene of TGEV. The procedure was first standardized in cell cultures. The radiolabeled pPSP.FP<sub>2</sub> probe detected both TGEV and PRCV in virus-inoculated cell cultures, whereas pPSP.FP<sub>1</sub> probe detected TGEV but not PRCV. The probe was then used to detect TGEV or PRCV in tissues of pigs experimentally infected with TGEV or PRCV or naturally infected with TGEV. Again, the probes detected TGEV in intestines of experimentally and naturally infected pigs and PRCV in the lungs of experimentally infected pigs. TGEV RNA was detected mainly within the enterocytes at the tips of villi and, less often, within some crypt epithelial cells. PRCV was shown to replicate mainly in the bronchiolar epithelial cells and in lesser amount in type II pneumocytes, type I pneumocytes, alveolar macrophages and bronchial epithelial cells, respectively. ISH has potential applications as a diagnostic test for the detection and differentiation of TGEV and PRCV in tissues and in studies to gain a better understanding of the mechanism of pathogenesis of enteric and respiratory coronavirus infections.

**Keywords:** Single stranded RNA probe; In situ hybridization; Transmissible gastroenteritis virus (TGEV); Porcine respiratory coronavirus (PRCV); Coronavirus

---

\* Corresponding author. Tel.: +1 515 294 0913; fax: +1 515 294 8341; e-mail: [pspaul@iastate.edu](mailto:pspaul@iastate.edu).

## 1. Introduction

Coronaviruses are a common cause of enteric and/or respiratory infections in animals and man. Transmissible gastroenteritis virus (TGEV) of swine is one of the best studied coronaviruses, yet diagnostic methods for its detection are less than ideal and limited information is available on mechanisms of TGEV pathogenesis. TGEV causes transmissible gastroenteritis (TGE) in swine characterized by vomiting, severe diarrhea and high mortality in piglets under 2 weeks of age (Bohl and Pensaert, 1989; Saif and Wesley, 1992). In recent years, another coronavirus has been identified in swine and has been designated as porcine respiratory coronavirus (PRCV) which is antigenically closely related to the enteropathogenic TGEV. PRCV was first isolated in 1984 from pigs in Belgium (Pensaert et al., 1986) and is now ubiquitous in swine herds in Europe. PRCV has since been isolated from swine in the US (Hill et al., 1989; Vaughn et al., 1994; Paul et al., 1994). PRCV is different from TGEV in that PRCV has 621–681 nucleotide deletion in the 5' end of S gene (Rassachaert et al., 1990; Wesley et al., 1990; Britton and Page, 1991; Wesley et al., 1991a; Paul et al., 1992; Sanchez et al., 1992; Laude et al., 1993; Paul et al., 1994; Vaughn et al., 1994; Vaughn et al., 1995) and deletions in open reading frame 3 (Rassachaert et al., 1990; Britton and Page, 1991; Wesley et al., 1991a). The S gene of TGEV plays an important role for tissue tropism (Parker et al., 1989; Rassachaert et al., 1990; Laude et al., 1993). The deletion in S gene of PRCV causes virus to replicate only in the respiratory tissue rather than in both respiratory and intestinal tissues as for TGEV (O'Toole et al., 1989; Cox et al., 1990). Because PRCV is similar antigenically to TGEV, this creates a diagnostic problem. The most commonly used method for TGEV detection in diagnostic cases is immunofluorescence method on frozen sections of intestines. This technique has many problems as sections or villus enterocytes often wash off the slides during processing. Virus can be isolated in cell cultures, however many virus isolates do not replicate well in cell culture (Vaughn and Paul, 1993). Other methods have been developed such as dot blot hybridization (Shockley et al., 1987; Paul et al., 1994), slot blot hybridization (Wesley

et al., 1991b), immunofluorescence (Morin et al., 1973; Frederick et al., 1976; Shepherd et al., 1979), peroxidase-antiperoxidase staining technique (Chu et al., 1982) and recently immunogold silver staining (IGSS) (Larochelle and Mogar, 1993). All of these techniques have unique advantages and disadvantages and, except for immunohistochemistry, are not suited for detection of virus in tissue sections.

In situ hybridization (ISH) techniques can be utilized to identify specific nucleic acid in cells. Both ISH and immunohistological staining methods have the advantages of requiring only an ordinary microscope and providing a permanent record, and they can be used for retrospective studies and have very high sensitivity and specificity. Therefore, collectively they can provide information on the presence of nucleic acid and antigen and can be used for pathogenesis studies. This study was undertaken to evaluate the ISH technique for the detection of TGEV and PRCV in infected cell cultures, to distinguish TGEV-infected cells from PRCV-infected cells, and to detect TGEV and PRCV in formalin-fixed paraffin-embedded sections from pigs infected experimentally or naturally with TGEV.

## 2. Materials and methods

### 2.1. Viruses

The virulent Miller strain of TGEV (National Veterinary Services Laboratory, Ames, IA) and PRCV strain AR310 were used as reference viruses (Vaughn and Paul, 1993; Vaughn et al., 1994; Vaughn et al., 1995).

### 2.2. Cell culture

Swine testes (ST) cells were cultured on 8-well chamber slides (Nunc) as reported by Vaughn et al. (1994) by growing in minimum essential medium (Gibco) supplemented with 10% heat inactivated bovine calf serum (Hazelton) and antibiotics. Four wells of 8-well chamber slides were inoculated with 200 plaque-forming units (PFU) of TGEV or PRCV per well. Another four wells served as non-inoculated controls. Twenty hours after inoculation, slides were fixed in 4% buffered paraformaldehyde at 4°C for 1 h.

### 2.3. Source of tissues

In experiment 1, four 8.5-week-old TGEV- and PRCV-negative pigs were divided into 2 groups. Two pigs were inoculated with  $10^5$  PFU of virulent Miller strain of TGEV and two pigs served as non-inoculated controls. In experiment 2, four 5-week-old TGEV and PRCV negative pigs were divided into two groups. Two pigs were inoculated with  $10^7$  PFU of PRCV strain AR310 and two pigs served as non-inoculated controls. Tissues from seven pigs submitted as separate diagnostic cases to the Veterinary Diagnostic Laboratory, College of Veterinary Medicine, Iowa State University were also used as naturally-infected pigs and non-infected pigs. Five of the cases had frozen sections diagnosed as TGEV antigen positive and two were diagnosed as TGEV antigen negative by the standard immunofluorescence method. Histopathology on these animals supported the FA results.

### 2.4. Processing of tissues for *in situ* hybridization

TGEV inoculated pigs were killed and necropsied at 3 days and PRCV inoculated pigs were killed and necropsied at 4 days post inoculation (DPI). At the times of necropsy, 1 cm segments of the posterior part of duodenum, and the anterior and posterior part of jejunum and ileum from two TGEV-inoculated pigs and 6 pieces of lung from two PRCV-inoculated pigs were collected and fixed in 10% neutral buffered formalin. A random segment of the small intestines of the five pigs infected naturally with TGEV and the two TGEV negative pigs were placed in 10% neutral buffered formalin. The tissues were processed for 48 h in an automated tissue processor and embedded in paraffin. Sections of 5- $\mu$ m-thickness were cut and placed on nuclease-free silylated slides (PGC Scientific). These slides were deparaffinized and hydrated by incubating at 55°C for 30 min and subsequently passed in absolute xylene 3 times for 5 min, and 1 min each in 3 changes of absolute ethanol, 95% ethanol, 70% ethanol and diethylpyrrocarbonate (DEPC, Sigma Chemical Co.) – treated water, respectively.

### 2.5. Preparation of probes

RNA probes were prepared from plasmid pPSP.FP<sub>1</sub> and pPSP.FP<sub>2</sub> containing the left half of the S gene of TGEV cloned in phagemid vector (Vaughn et al., 1994). The plasmid pPSP.FP<sub>1</sub> contains S gene segment from nucleotides 1678 to 2250 (Britton and Page, 1990) which is present in TGEV but is deleted in all PRCV (Paul et al., 1994; Vaughn et al., 1994). The plasmid pPSP.FP<sub>2</sub> contains S gene segment from nucleotides 1678 (Britton and Page, 1990) to 2483 (Rassachaert and Laude, 1987). The plasmids pPSP.FP<sub>1</sub> and pPSP.FP<sub>2</sub> were linearized with restriction enzymes *Bam*HI and *Hpa*I (Promega), respectively. The *in vitro* transcription and labeling of the probes were performed as described previously (Gibson and Polak, 1990; Angerer and Angerer, 1992) by using T7-RNA polymerase for plasmid pPSP.FP<sub>1</sub> and T3-RNA polymerase for plasmid pPSP.FP<sub>2</sub> (Promega), the four NTPs (ATP, CTP, TTP and GTP; Sigma Chemical Co.), DTT (dithiothreitol; Bio-Rad) and [<sup>35</sup>S]UTP $\alpha$ S (Amersham). The transcription reaction was stopped by adding 1  $\mu$ l (1  $\mu$ g/ $\mu$ l) of DNase I (Worthington) and 1  $\mu$ l (1  $\mu$ g/ $\mu$ l) of RNasin (Promega) for 20 min at 37°C. Unincorporated [<sup>35</sup>S]UTP $\alpha$ S were removed by passing the labeled RNA through a Sephadex G-25 spin column (Boehringer Mannheim).

### 2.6. *In situ* hybridization

Deparaffinized tissue sections and cells in 8-well chamber slides were treated with 2 ml of proteinase K (Ameresco) for 10 min at 37°C in a moist chamber. Concentration of proteinase K was 0.5  $\mu$ g/ml for cell cultures and 1  $\mu$ g/ml for tissue sections. Slides were washed in DEPC-treated water (0.1% DEPC) for 1 min. These slides were placed in a staining dish containing 400 ml of 0.1 M triethanolamine (pH 8.0) and 1 ml acetic anhydride and rapidly stirred for 10 min at room temperature. Slides were prehybridized in 2  $\times$  SSC for 5 min and dehydrated in graded alcohols and air dried. The hybridization solution (Brahic and Ozden, 1992; Angerer and Angerer, 1992) containing 50% formamide, 10% dextran sulfate, 3  $\times$  SSC, 50 mM sodium phosphate (pH

7.4),  $1 \times$  Denhardt's solution, 0.1 mg/ml yeast tRNA, 10 mM DTT, and  $1 \mu\text{l}$  of  $^{35}\text{S}$ -labeled RNA probe ( $2 \times 10^6$  cpm/ $\mu\text{l}$ ). The amount of hybridization solution added was  $50 \mu\text{l}$  per slide as previously described (Angerer and Angerer, 1992), and coverslips were placed on the slides. Slides were incubated at  $52^\circ\text{C}$  for 20 h. The coverslips were removed by soaking the slides in  $2 \times$  SSC twice for 5 min each at room temperature. The slides were treated with RNase A (Worthington) (Gibson and Polak, 1990; Angerer and Angerer, 1992; Wilcox, 1993) solution (20  $\mu\text{g/l}$ ) containing 10 mM Tris HCl (pH 8.0) and 0.5 M NaCl for 30 min at  $37^\circ\text{C}$ . Slides were washed in  $2 \times$  SSC for 5 min at  $52^\circ\text{C}$ ,  $1 \times$  SSC for 5 min at  $52^\circ\text{C}$ ,  $0.5 \times$  SSC for 1 h at  $52^\circ\text{C}$  and  $0.5 \times$  SSC for 5 min at room temperature. Slides were dehydrated, air dried and were exposed to X-ray films (Fuji Photo film) at  $-70^\circ\text{C}$  for 24 h. X-ray films were developed and evaluated. The slides were then coated with Kodak NTB-2 emulsion gel (Eastman Kodak Co.) which was diluted with 600 mM ammonium acetate (Kohler and Nelsen, 1990; Angerer and Angerer, 1992) and preheated to  $42^\circ\text{C}$  (Gibson and Polak, 1990; Kohler and Nelsen, 1990; Angerer and Angerer, 1992; Wilcox, 1993). These slides were kept in a light-proof box at  $4^\circ\text{C}$  for 2 days. The slides were developed at  $15^\circ\text{C}$  for 3 min using developer (Kodak D-19) diluted 1:1 with water, followed by a 20 s rinse in deionized water and then fixed for 3 min in fixer. The slides were then rinsed with deionized water for 5 min (Wilcox, 1993) and counterstained with hematoxylin and eosin. All of the solutions used in ISH, except for the RNase A solution to remove contaminating ribonucleases, were prepared by using DEPC-treated water (0.1% DEPC).

Controls included uninoculated ST cell monolayers, RNase-treated cells inoculated with TGEV, tissues from two non-infected animals, RNase A treated tissue sections from TGEV-inoculated animals, positive strand  $^{35}\text{S}$ -labeled RNA hybridized with sections from TGEV-infected animals, and excess amount of non-labeled RNA probe hybridized to sections from TGEV-infected animals followed by hybridization with  $^{35}\text{S}$ -labeled RNA probe. The positive strand  $^{35}\text{S}$ -labeled RNA probe was generated by using the same

plasmid DNA and T7-RNA polymerase (Promega). The negative controls for PRCV inoculation experiment were similar to the TGEV inoculation experiment except RNase A-treated tissue sections from PRCV-inoculated animals and 8-well chamber slides inoculated with PRCV,  $^{35}\text{S}$ -labeled RNA probe produced from plasmid pPSP.FP<sub>1</sub>, and the positive strand  $^{35}\text{S}$ -labeled probe was generated by using the same plasmid DNA but linearized by using restriction enzyme *EcoRI* and T3-RNA polymerase.

### 3. Results

#### 3.1. Detection of TGEV and PRCV in cell cultures

The in situ hybridization technique was first standardized using cell monolayers of ST cells. Uninoculated cell cultures and those inoculated with TGEV or PRCV were hybridized with the RNA probe made from plasmids pPSP.FP<sub>1</sub> and pPSP.FP<sub>2</sub>. Following hybridization, slides were exposed to X-ray films. A good dark signal on X-ray films in TGEV or PRCV inoculated wells was usually observed after 24 h exposure and inoculated wells could be differentiated from the uninoculated wells. The virus inoculated wells showed heavy dark squares of silver grains, but non-inoculated wells had only pale gray color as non-specific background. The RNA probe prepared from plasmid pPSP.FP<sub>2</sub> detected both TGEV and PRCV whereas the probe prepared from pPSP.FP<sub>1</sub> reacted with TGEV but not PRCV (Fig. 1). The slides were then coated with emulsion gel, stored in the dark, developed after 2 days and examined under the light microscope. A heavy concentration of silver grains localized above and within the cytoplasm of the TGEV or PRCV-inoculated cells were detected (Fig. 2), only a very low concentration of silver grains were scattered throughout the non-inoculated cells. Positive signal was abolished by RNase A treatment of cells prior to hybridization as well as by addition of unlabeled RNA probe prior to hybridization with radiolabeled probe.

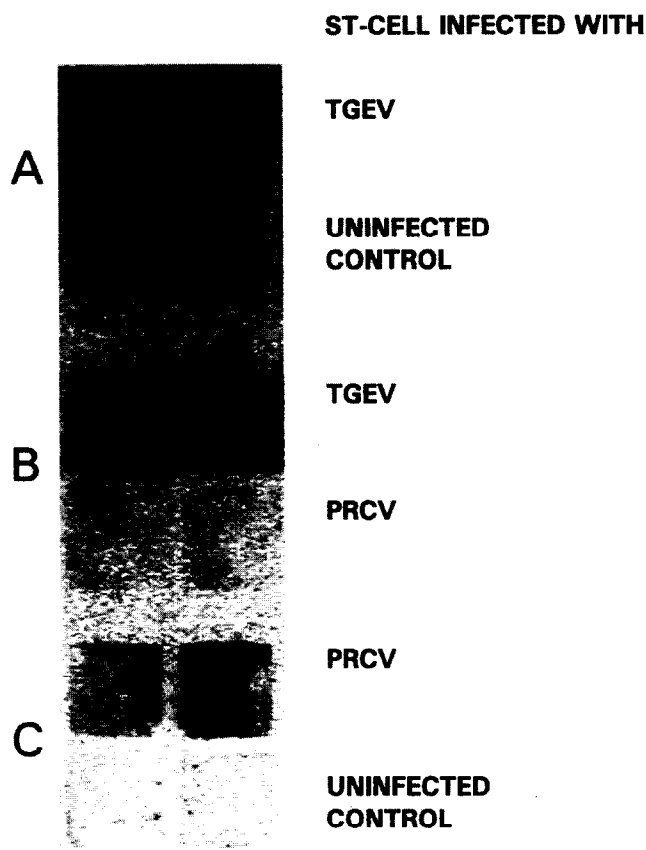


Fig. 1. Autoradiograph of cell cultures in 8-well chamber slides following hybridization with  $^{35}\text{S}$ -RNA probe prepared from plasmid pPSP.FP<sub>1</sub> (B) or pPSP.FP<sub>2</sub> (A and C) containing the left half of TGEV S gene. (A) ST cell cultures in chambers were inoculated with TGEV (upper row) or were left as non-inoculated control (lower row). (B) Cell cultures were inoculated with TGEV (upper row) or PRCV (lower row). (C) Cell cultures were inoculated with PRCV (upper row) or kept as non-inoculated control (lower row). Probe from plasmid pPSP.FP<sub>1</sub> only reacted with TGEV whereas the probe from plasmid pPSP.FP<sub>2</sub> reacted with TGEV and PRCV.

### 3.2. *In situ* hybridization of sections of TGEV-infected tissues

Once the technique was standardized using cell monolayers, it was tested on intestinal sections from uninoculated and TGEV-inoculated pigs. The autoradiography results using X-ray films clearly distinguished between sections from TGEV-inoculated and non-inoculated animals as shown in Fig. 3. The sections of duodenum, anterior jejunum, posterior jejunum, anterior ileum and posterior ileum from infected animals gave heavy dark lines of silver grains along the mucosa. No signal was detected in sections from non-infected animals, RNase A-treated sections from

infected animals and sections treated with excess amount of non-labeled RNA probe demonstrating the specificity of the probe. Slides coated with emulsion gel from the infected animals had heavy concentration of silver grains along the mucosal layer, but the sections from non-infected animals did not. There were numerous silver grains over the cytoplasm of the villous enterocytes (Fig. 4B). A few non-specific silver grains, which were not localized over the cells, were scattered throughout the sections. Viral RNA was detected in some crypt epithelial cells (Fig. 4D). The histopathologic changes were villous atrophy, blunted and denuded villi and replacement of the columnar cells by flat to cuboidal cells.

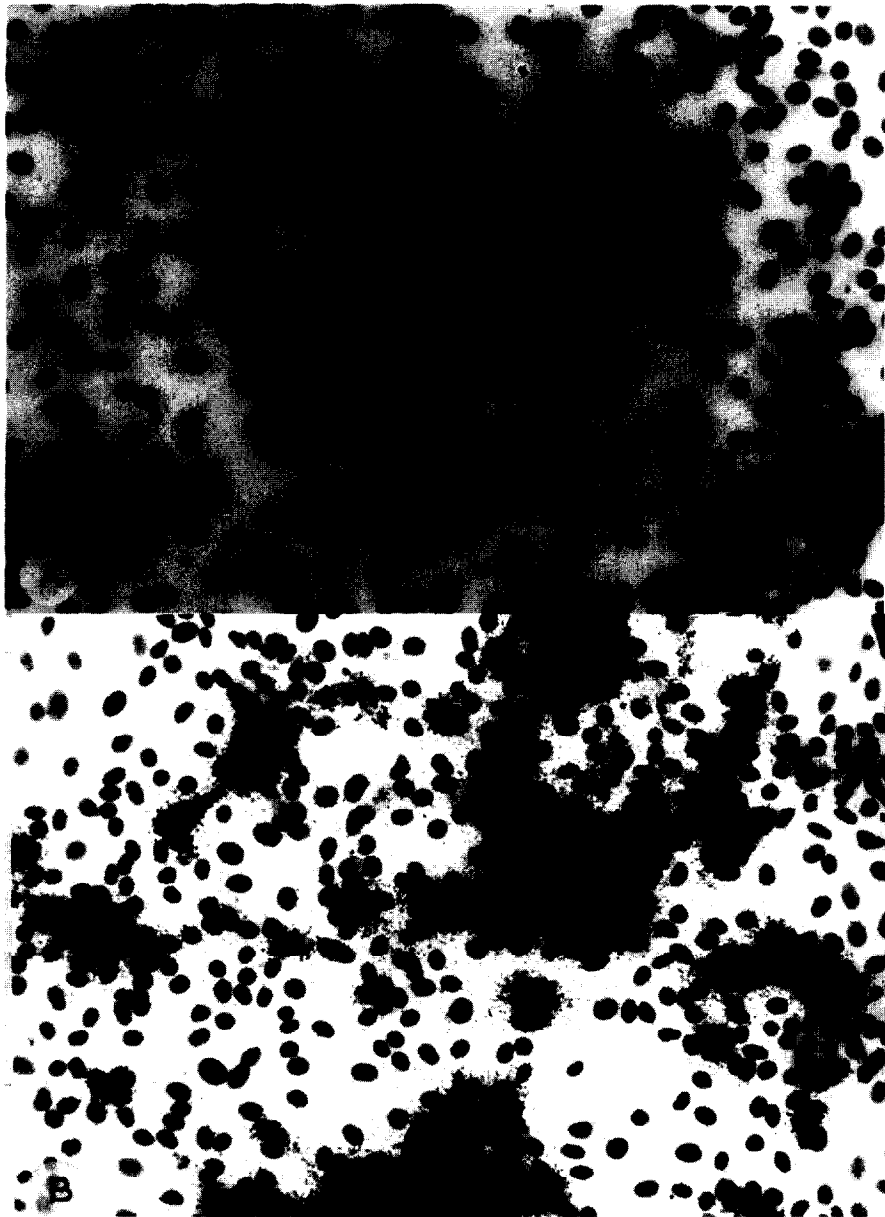


Fig. 2. In situ hybridization of uninoculated control (A) and TGEV-inoculated ST cells (B) with  $^{35}\text{S}$ -RNA probe produced from plasmid pPSP.FP<sub>2</sub> containing TGEV S gene insert. Eight-well chamber slides were exposed to autoradiographic emulsion gel for 2 days.

Once the technique was standardized on tissues of experimentally infected pigs, we wanted to determine if it could be used on tissue sections from pigs naturally infected with TGEV. We took intestinal sections from five pigs that

had been diagnosed as TGE by FA and two that had been TGE negative. As expected, sections from TGE positive pigs were positive by ISH and the TGE-negative sections were negative by ISH.

### 3.3. *In situ* hybridization of formalin-fixed paraffin-embedded sections of PRCV infected tissues

Tissues from PRCV-inoculated pigs were used to determine whether this technique could be used to detect PRCV in PRCV-inoculated pigs. The autoradiography results from X-ray films of the lung sections of the PRCV-inoculated pigs and non-inoculated control pigs distinctly illustrated the differences between these two groups of sections. X-ray films of the lung sections from PRCV-inoculated pigs showed the dark ring of silver grains along the small airways and dark spots scattered throughout the sections, but the lung sections from non-inoculated pigs had homogeneous pale gray color over the lung sections. The slides from the PRCV-inoculated pigs coated with emulsion gel had heavy concentration of silver grains localized over the epithelial cells of bronchi, bronchioles, type II pneumocytes, type I pneumocytes and alveolar macrophages. The hybridization signals were also found over the necrotic epithelial cells that sloughed into the lumen of the bronchioles, and over the alveolar macrophages in the exudate in the alveoli and bronchioles. The cells that most often had the localization of the silver grains were bronchiolar epithelial cells (Fig. 5), especially in terminal bronchioles, followed by type II pneumocytes,

alveolar macrophages and type I pneumocytes. Only a few bronchial epithelial cells were shown to have localization of the silver grains. The microscopic examination showed mild to moderate necrosis and attenuation of the bronchiolar epithelial cells, moderate lymphomacrophagic infiltration in the alveolar septa, mild type II pneumocyte hypertrophy and proliferation, and lymphomacrophagic exudation in bronchioles and alveoli.

## 4. Discussion

In this study, an ISH technique is described for the detection and differentiation of coronaviruses TGEV and PRCV in cell cultures as well as formalin-fixed paraffin-embedded tissues of pigs. This test was first standardized in cell cultures. ISH with radiolabeled probes prepared from plasmids pPSP.FP<sub>1</sub> and pPSP.FP<sub>2</sub> were highly specific for the detection of TGEV and PRCV in cell culture. The TGEV-infected cells had hybridization signals with radiolabeled RNA probes produced from either of the two plasmids pPSP.FP<sub>1</sub> and pPSP.FP<sub>2</sub>. In contrast, the PRCV-infected cells had hybridization signals with radiolabeled RNA probes produced from plasmid pPSP.FP<sub>2</sub> but not with probes generated from plasmid pPSP.FP<sub>1</sub>. Non-infected cell cultures did not show hybridization signals with RNA probes generated from plasmid pPSP.FP<sub>1</sub> or pPSP.FP<sub>2</sub>. Thus, it was possible to distinguish TGEV-infected cells from PRCV-infected cells by using <sup>35</sup>S-RNA probe produced from plasmid pPSP.FP<sub>1</sub>. This plasmid contained TGEV nucleotide sequences in the S gene that were missing in PRCV (Vaughn et al., 1994). The results from X-ray films corresponded well with the results from emulsion coated slides. For rapid results, slides from suspicious cases can be exposed to X-ray films after hybridization with appropriate <sup>35</sup>S-RNA probe. For more details or to differentiate the viruses and to study pathologic changes in tissues, slides can be coated with emulsion gel.

ISH of formalin-fixed paraffin-embedded TGEV-inoculated tissues showed distribution of viral nucleic acid in intestines similar to the distri-



Fig. 3. Photograph of an X-ray film showing autoradiographic results after 24 h exposure of formalin-fixed paraffin-embedded sections from the various portion of small intestines of the non-inoculated pig (L) and TGEV-inoculated pig (R) after hybridization with <sup>35</sup>S-RNA probe produced from plasmid pPSP.FP<sub>2</sub>. Small intestinal sections from non-inoculated pig showed only pale gray color but small intestinal sections from TGEV-inoculated pigs showed a dark continuous line along the mucosal surface of the small intestines.



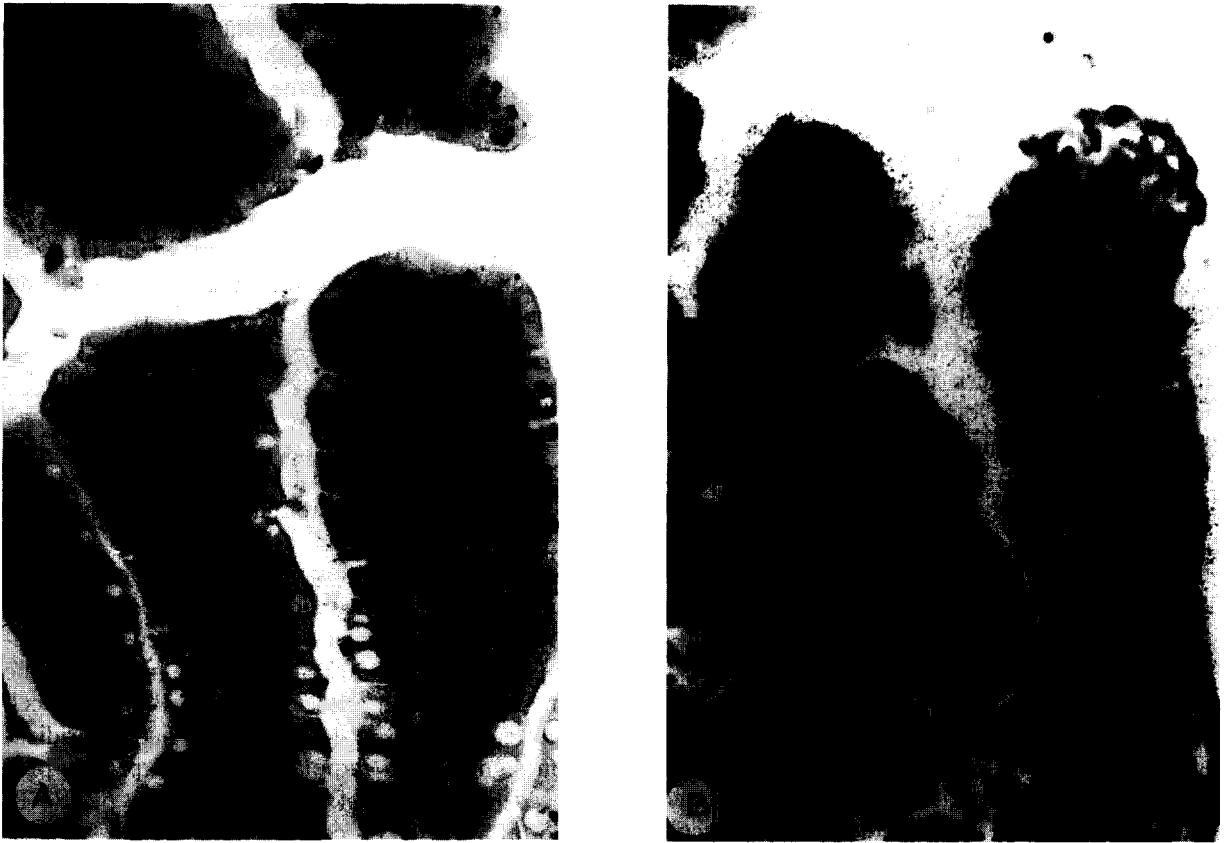

Fig. 4. Photographs of intestinal villi (A and B) and crypt of Lieberkuhn (C and D) of small intestines from uninoculated pig (A and C), or pig inoculated with TGEV (B and D) following in situ hybridization with  $^{35}\text{S}$ -RNA probe produced from plasmid pPSP.FP<sub>2</sub>. The histopathologic changes observed following TGEV inoculation were villous atrophy, blunted and denuded villi and replacement of the columnar cells by flat to cuboidal cells (B). The ISH signals were specifically localized in villi (B) and over the crypt epithelial cells (D).

bution of viral antigen reported previously (Morin et al., 1973; Frederick et al., 1976; Larson et al., 1979; Woods et al., 1981; Chu et al., 1982; Bohl and Pensaert, 1989; Saif and Wesley, 1992; Larochelle and Mogar, 1993). However, we also detected viral nucleic acid in some crypt epithelial cells. The autoradiography results from X-ray films correlated very well with the results from the emulsion gel coated-slides, and the results were similar in both experimentally inoculated and naturally infected pigs. This result was in contradiction to previous reports where no positive cells were identified in the crypt of Lieberkuhn (Morin et al., 1973; Frederick et al., 1976; Shepherd et al., 1979; Larson et al., 1979; Chu et al., 1982; Bohl and Pensaert, 1989; Saif and Wesley, 1992;

Larochelle and Mogar, 1993). The reason for this difference is not known except previous studies have examined for viral antigen, whereas, we have looked for viral nucleic acid. TGEV enters into the cell by specific receptors on the cell membrane of mature enterocytes. Two receptors have been identified: aminopeptidase-N (CD 13) (Delmas et al., 1990) and a second putative 200 kD receptor (Weingartl and Derbyshire, 1994). These receptors are found only on the absorptive enterocytes, but they are not found on the cell membrane of the crypt epithelial cells. The mechanism for TGEV infection of crypt epithelial cells is not known. One possibility is that TGEV might bind non-specifically on the cell membrane of the crypt epithelial cells and thus lead to infection of these cells

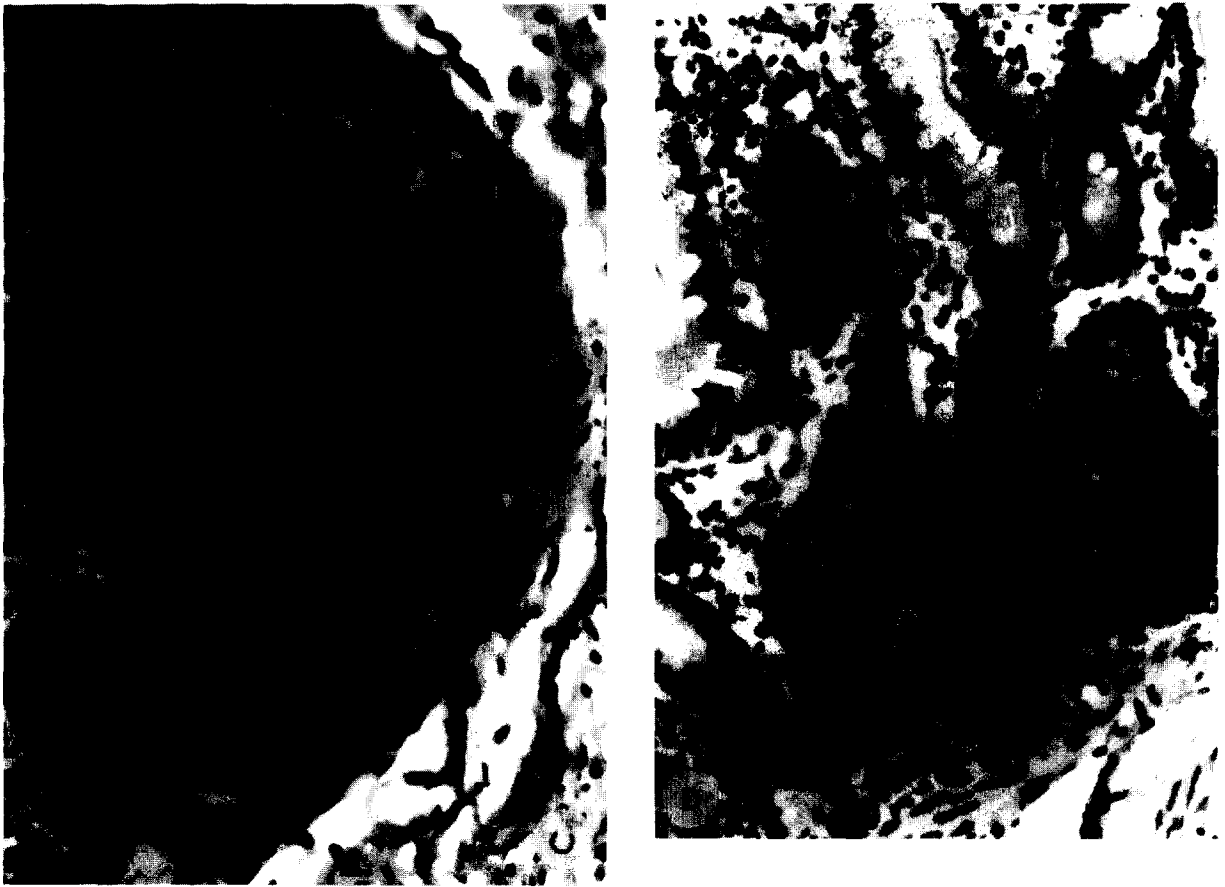


Fig. 4 continued.

(Weingartl and Derbyshire, 1993). Another possibility is that TGEV infection of these cells is non-productive. In this case, there is no viral protein produced in this type of cell, and thus is not detected by immunofluorescence or immunohistological methods (Morin et al., 1973; Frederick et al., 1976; Larson et al., 1979; Woods et al., 1981; Chu et al., 1982; Saif and Wesley, 1992; Larochelle and Mogar, 1993). ISH technique also provides for observation of histopathological lesions. The histopathologic changes were similar to previous reports (Morin et al., 1973; Frederick et al., 1976; Larson et al., 1979; Woods et al., 1981; Chu et al., 1982; Bohl and Pensaert, 1989; Saif and Wesley, 1992; Larochelle and Mogar, 1993).

The distribution of PRCV ribonucleic acid was most intense in the epithelial cells of the bronchiolar epithelium and is compatible with the distribu-

tion of viral antigen as reported previously (O'Toole et al., 1989). However our results are incompatible with those observed by Cox et al. (1990) in which the viral replication occurred mainly in the alveolar cells. The microscopic examination showed microscopic changes in the lung tissue as previous reports (O'Toole et al., 1989; Cox et al., 1990; Halbur et al., 1993).

ISH was described for two swine coronaviruses which should be very useful for diagnostic purposes and retrospective studies. This is also the first description of this technique in TGEV and PRCV infection. Development of a non-radioactive labeled probe will make it even more user friendly. We are exploring the potential of using such a probe. This technique also has applications in elucidating mechanisms of pathogenesis of TGEV and PRCV in swine.



Fig. 5. Photographs of formalin-fixed sections from lungs of uninoculated control (A) and PRCV-inoculated (B) pigs hybridized in situ with  $^{35}\text{S}$ -RNA probe produced from plasmid pPSP.FP<sub>2</sub> and exposed to autoradiographic emulsion for 2 days. ISH signals can be observed over the bronchiolar epithelial cells of small bronchiole of PRCV-inoculated pigs.

#### Acknowledgements

We thank Dr. Igor Morozov for technical guidance. This study was funded in part with a grant from the Iowa Livestock Health Advisory Coun-

cil. Theerapol Sirinarumit is a fellow from the Department of Veterinary Pathology, Faculty of Veterinary Medicine, Kasetsart University, Thailand and is supported with a King's scholarship from the Anandhamahidol Foundation, Thailand.

## References

- Angerer, L.M. and Angerer, R.C. (1992) In situ hybridization to cellular RNA with radiolabeled RNA probe. In: D.G. Wilkinson (Ed), *In situ Hybridization: a Practical Approach*, Oxford University Press, New York, pp. 15–32.
- Bohl, E.H. and Pensaert, M.B. (1989) Transmissible gastroenteritis virus (classical enteric variant) and transmissible gastroenteritis virus (respiratory variant). In: M.B. Pensaert (Ed), *Virus Infections of Porcines*, Elsevier Science Publishers B.N., Amsterdam, pp. 139–265.
- Brahic, M. and Ozden, S. (1992) Simultaneous detection of cellular RNA and protein. In: D.G. Wilkinson (Ed), *In situ Hybridization: a Practical Approach*, Oxford University Press, New York, pp. 85–104.
- Britton, P., Mawditt, K.L. and Page, K.W. (1991) The cloning and sequencing of the virion protein genes from a British isolate of porcine respiratory coronavirus: comparison with transmissible gastroenteritis virus genes. *Virus Res.* 21, 181–198.
- Britton, P. and Page, K.W. (1990) Sequence of the S gene from a virulent British field isolate of transmissible gastroenteritis virus. *Virus Res.* 18, 71–80.
- Cox, E., Hooybergh, J. and Pensaert, M.B. (1990) Sites of replication of a porcine respiratory coronavirus related to transmissible gastroenteritis virus. *Res. Vet. Sci.* 48, 165–169.
- Chu, R.M., Li, N., Glock, R.D. and Ross, R.F. (1982) Applications of peroxidase-antiperoxidase staining technique for detection of transmissible gastroenteritis virus in pigs. *Am. J. Vet. Res.* 43, 77–81.
- Delmas, B., Gelfi, J. and L'Haridon, R. et al. (1990) Aminopeptidase N is a major receptor for the enteropathogenic coronavirus TGEV. *Nature* 357, 417–420.
- Frederick, G.I., Bohl, E.H. and Cross, J.E. (1976) Pathogenicity of an attenuated strain of transmissible gastroenteritis virus for newborn pigs. *Am. J. Vet. Res.* 42, 1163–1169.
- Gibson, S.J. and Polak, J.M. (1990) Principles and applications of complementary RNA probes. In: J.M. Polak and J.O. McGee (Eds), *In situ Hybridization, Principles and Practice*, Oxford University Press, New York, pp. 81–94.
- Halbur, P.G., Paul, P.S., Vaughn, E.M. and Andrews, J.J. (1993) Experimental reproduction of pneumonia in gnotobiotic pigs with porcine respiratory coronavirus isolate AR310. *J. Vet. Diagn. Invest.* 5, 184–188.
- Hill, H.T., Biwer, J.D., Wood, R.D. and Wesley, R.D. (1989) Porcine respiratory coronavirus isolated from two US swine herds. *Proc. Am. Assoc. Swine Pract.* 333–335.
- Kohler, C.R. and Nelsen, J.A. (1990) Technique for double-labelling virus infected cells. In: M.B. Oldstone (Ed), *Animal Virus Pathogenesis, a Practical Approach*, Oxford University Press, New York, pp. 67–86.
- Larochelle, R. and Mogar, R. (1993) The application of immunogold silver staining (IGSS) for the detection of the transmissible gastroenteritis virus in fixed tissue. *J. Vet. Diagn. Invest.* 5, 16–20.
- Larson, D.J., Morehouse, L.G., Solorzano, R.F. and Kinden, D.A. (1979) Transmissible gastroenteritis in neonatal dogs: experimental intestinal infection with transmissible gastroenteritis virus. *Am. J. Vet. Res.* 40, 477–487.
- Laude, H., van Reeth, K. and Pensaert, M. (1993) Porcine respiratory coronavirus: molecular features and virus-host interactions. *Vet. Res.* 24, 125–150.
- Morin, M., Morehouse, L.G., Solorzano, R.F. and Olsen, L.D. (1973) Transmissible gastroenteritis in feeder swine: clinical, immunofluorescence and histopathological observations. *Can. J. Comp. Med.* 37, 239–248.
- O'Toole, D., Brown, I., Bridges, A. and Cartwright, S.F. (1989) Pathogenicity of experimental infection with pneumotropic porcine respiratory coronavirus. *Res. Vet. Sci.* 47, 23–29.
- Parker, S.E., Gallagher, T.M. and Buchmeier, M.J. (1989) Sequence analysis reveals extensive polymorphism and evidence of deletions within the E2 glycoprotein gene of several strains of murine hepatitis virus. *Virology.* 173, 664–673.
- Paul, P.S., Halbur, P.G. and Vaughn, E.M. (1994) Significance of porcine respiratory coronavirus infection. *Compend. Cont. Educ. Pract. Vet.* 16, 1223–1234.
- Paul, P.S., Vaughn, E.M. and Halbur, P.G. (1992) Characterization and pathogenicity of a new porcine respiratory coronavirus strain AR310. *Proc. Int. Pig. Vet. Soc. Congr.* 12, 92.
- Pensaert, M., Callebaut, P. and Vergote, J. (1986) Isolation of a porcine respiratory non-enteric coronavirus related to transmissible gastroenteritis. *Vet. Quart.* 8, 257–261.
- Rassachaert, D., Duarte, M. and Laude, H. (1990) Porcine respiratory coronavirus differs from transmissible gastroenteritis virus by a few genomic deletions. *J. Gen. Virol.* 71, 2599–2607.
- Rassachaert, D. and Laude, H. (1987) The predicted primary structure of the peplomer protein E2 of the porcine coronavirus transmissible gastroenteritis virus. *J. Gen. Virol.* 68, 1883–1890.
- Saif, L.J. and Wesley, R.D. (1992) Transmissible gastroenteritis. In: A.D. Leman, B.E. Strauss, W.L. Mengeling, S. D'Allaire, D.J. Taylor (Eds), *Diseases of Swine*, 7th ed., Iowa State University Press, Ames, IA, pp. 362–386.
- Sanchez, C.M., Gebauer, F., Sune, C., Mendez, A., Dopazo, J. and Enjuanes, L. (1992) Genetic evolution and tropism of transmissible gastroenteritis coronavirus. *Virol.* 190, 92–105.
- Shepherd, R.W., Butler, D.G., Cutz, E. and Gall, D.G. et al. (1979) The mucosal lesion in viral enteritis: extent and dynamics of the epithelial response to virus invasion in transmissible gastroenteritis of piglets. *Gastroenterology* 76, 770–777.
- Shockley, L.J., Kapke, P.A., Lapps, W., Brain, D.A., Potgieter, L.D. and Woods, R.D. (1987) Diagnosis of porcine and bovine enteric coronavirus infections using cloned cDNA probes. *J. Clin. Micro.* 25, 1591–1596.
- Vaughn, E.M., Halbur, P.G. and Paul, P.S. (1995) Sequence comparison of porcine respiratory coronavirus isolates re-

- veals heterogeneity in the S, 3, and 3-1 genes. *J. Virol.* 69, 3176–3184.
- Vaughn, E.M., Halbur, P.G. and Paul, P.S. (1994) Three new isolates of porcine respiratory coronavirus with various pathogenicities and spike (S) gene deletions. *J. Clin. Microbiol.* 32, 1809–1812.
- Vaughn, E.M. and Paul, P.S. (1993) Antigenic and biological diversity among transmissible gastroenteritis virus isolates of swine. *Vet. Microbiol.* 36, 333–347.
- Weingartl, H. and Derbyshire, J.B. (1994) Evidence for a putative second receptor for porcine transmissible gastroenteritis virus on the villous enterocytes of newborn pigs. *J. Virol.* 68, 7253–7259.
- Weingartl, H. and Derbyshire, J.B. (1993) Binding of porcine transmissible gastroenteritis virus by enterocytes from newborn and weaned piglets. *Vet. Microbiol.* 35, 223–232.
- Wesley, R.D., Woods, R.D., Hill H.T. and Biber, J.D. (1990) Evidence for a respiratory coronavirus antigenically similar to transmissible gastroenteritis in the United States. *J. Vet. Diagn. Invest.* 2, 312–317.
- Wesley, R.D., Woods, R.D. and Cheung, A.K. (1991a) Genetic basis for the pathogenesis of transmissible gastroenteritis virus. *J. Virol.* 64, 4761–4768.
- Wesley, R.D., Wesley, I.V. and Woods, R.D. (1991b) Differentiation between transmissible gastroenteritis virus and porcine respiratory coronavirus using a cDNA probe. *J. Vet. Diagn. Invest.* 3, 29–32.
- Wilcox, J.N. (1993) Fundamental principles of in situ hybridization. *J. Histochem. Cytochem.* 41, 1725–1733.
- Woods, R.D., Chevillat, N.F. and Gallagher, J.E. (1981) Lesions in the small intestine of newborn pigs inoculated with porcine, feline and canine coronavirus. *Am. J. Vet. Res.* 42, 1163–1169.