

CASE REPORT

Type 2A von Willebrand disease and systemic sclerosis: Vonico[®] alfa reduced gastrointestinal bleeding

Peter Korsten MD¹   | Manuel Wallbach MD¹ | Claudia Binder MD²

¹Department of Nephrology and Rheumatology, University Medical Center Göttingen, Göttingen, Germany

²Department of Hematology and Medical Oncology, University Medical Center Göttingen, Göttingen, Germany

Correspondence

Peter Korsten, Department of Nephrology and Rheumatology, University Medical Center Göttingen, Robert-Koch-Str. 40, D-37075 Göttingen, Germany.
Email: peter.korsten@med.uni-goettingen.de

Funding information

The authors have not declared a specific grant for this research from any funding agency in public, commercial, or not-for-profit sectors.

Handling Editor: Pantep Angchaisuksiri.

Abstract

Von Willebrand disease (VWD) is a bleeding disorder caused by qualitative or quantitative defects of von Willebrand factor (VWF). This case report of a patient with systemic sclerosis and gastrointestinal bleeding from angiodysplasias seeks to address the key clinical question of a useful diagnostic and therapeutic approach in this setting. The extent of vascular malformations and the frequency of bleeding episodes were unusually severe, and we reached a diagnosis of inherited type 2A VWD. After an insufficient effect of treatment with factor VIII (FVIII)/VWF, prophylactic administration of vonico[®] alfa, a recombinant VWF preparation without FVIII, was initiated. This therapy led to a substantial reduction of transfusion requirements and the improvement of angiodysplasias. In refractory gastrointestinal bleeding, hemostaseological evaluation is crucial, as inherited disorders of hemostasis may go unnoticed, especially in patients with underlying autoimmune diseases, where complications may be ascribed to the underlying disease.

KEYWORDS

angiodysplasias, Autoimmune Diseases, scleroderma, systemic, vascular malformations, von Willebrand diseases

Essentials

- Angiodysplasias are a common source of refractory gastrointestinal bleeding.
- We report a case of a patient with inherited von Willebrand disease and systemic sclerosis.
- A hemostaseological evaluation is crucial in the setting of refractory bleeding.
- Vonico[®] alfa was used as prophylactic therapy and led to a reduction of angiodysplasias.

1 | INTRODUCTION

Von Willebrand disease (VWD) is an inherited platelet-derived bleeding disorder caused by quantitative or qualitative defects of the von

Willebrand factor (VWF).¹ Primary and secondary (acquired) forms of VWD exist.¹ The latter can be associated with various underlying conditions, such as autoimmune diseases, where VWF function is impaired by binding to autoantibodies.² Apart from its role in primary hemostasis, VWF participates in the regulation of angiogenesis. Its

Peter Korsten and Manuel Wallbach equal contribution of both authors.

This is an open access article under the terms of the Creative Commons Attribution-NonCommercial-NoDerivs License, which permits use and distribution in any medium, provided the original work is properly cited, the use is non-commercial and no modifications or adaptations are made.

© 2020 The Authors. *Research and Practice in Thrombosis and Haemostasis* published by Wiley Periodicals LLC on behalf of International Society on Thrombosis and Haemostasis (ISTH)

lack induces gastrointestinal vascular malformations in a subset of patients with VWD leading to recurrent and often therapy-resistant gastrointestinal bleeding.

Systemic sclerosis (SSc) is a rare autoimmune disease and mainly manifests as either diffuse or limited type.³ Limited SSc (lcSSc) is characterized by the presence of anticentromere antibodies and a higher prevalence of vascular sequelae, such as pulmonary arterial hypertension, compared to the diffuse form.³ Gastrointestinal involvement in SSc is frequent in both subtypes and most often manifests as gastroesophageal reflux disease, small intestinal bacterial overgrowth, diarrhea, or constipation.⁴ More severe disease can lead to malnutrition, intestinal pseudo-obstruction, or significant weight loss, and is associated with increased mortality.⁵

Vascular abnormalities are less commonly reported: Telangiectasias are frequently localized in the skin of patients with lcSSc; however, some patients develop disseminated angiodysplasias throughout the gastrointestinal tract with subsequent life-threatening bleeding.⁶ Gastrointestinal angiodysplasias are found in ~1%-5% of all patients undergoing endoscopic studies and are frequently located in the small bowel.⁷ They account for ~10% of all gastrointestinal bleedings and ~50% of all small bowel gastrointestinal bleeding episodes.⁷

With this case report, we seek to address the key clinical question of the appropriate diagnostic testing and subsequent management of severe gastrointestinal bleeding in the setting of a known underlying autoimmune condition.

2 | CASE REPORT

A 54-year-old female patient with a history of lcSSc since 2001 was hospitalized at our center. Throughout the disease course, she developed severe Raynaud phenomenon (RP), pulmonary arterial hypertension (PAH), and autoamputation of several fingertips secondary to calcinosis and digital ulcers with finger necrosis and tissue loss (Figure 1A). Her past medical history was significant for a smoking history of 25 pack-years and hypothyroidism. She had been treated with various immunosuppressive treatments for her skin manifestation and deforming arthritis. Her current treatment included intravenous rituximab 500 mg every 3 months with a notable improvement in her skin disease, which was paused because of frequent hospitalizations and anemia. She had received the last of rituximab 3 months before the current admission. Her disease had most notably been complicated by recurrent and severe gastrointestinal bleeding secondary to gastric, small and large intestinal angiodysplasias,

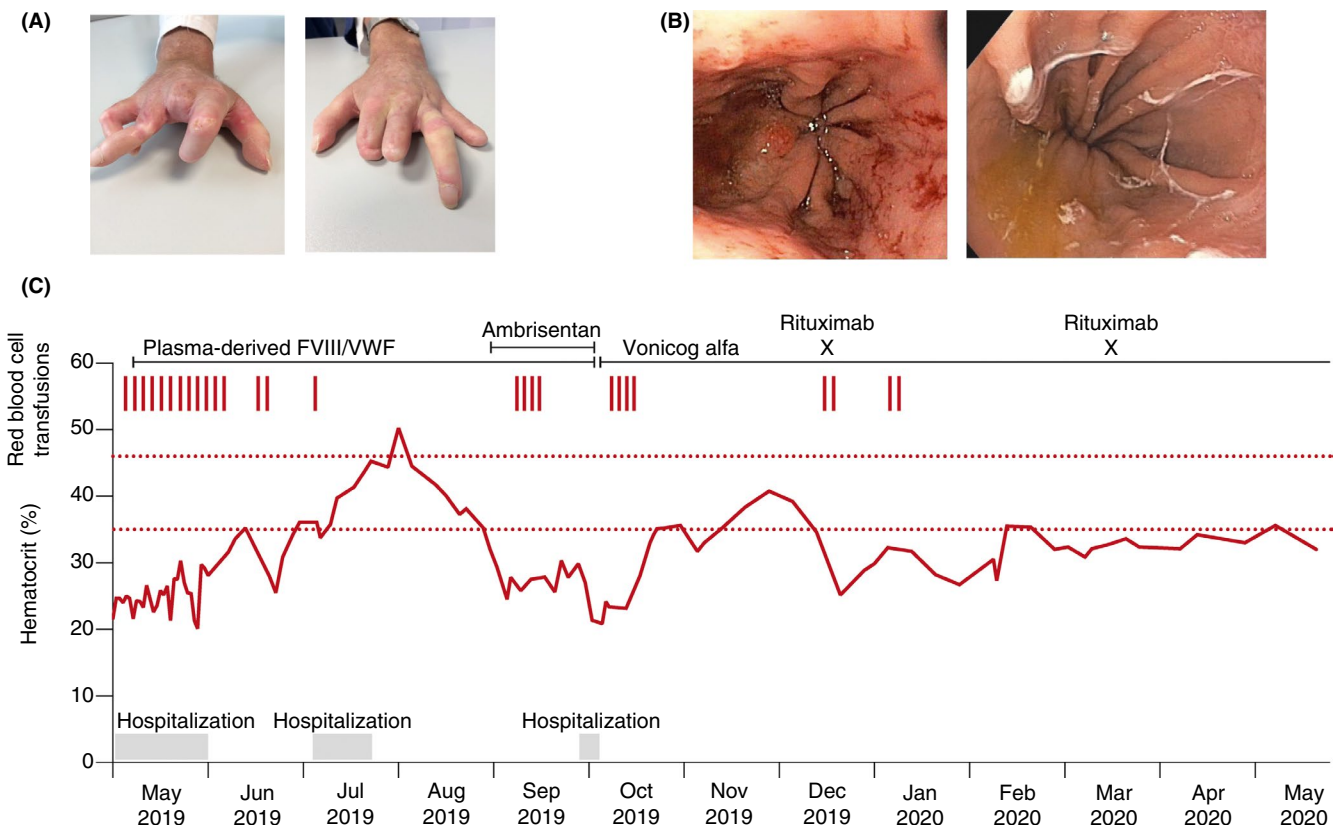


FIGURE 1 (A) Clinical images of the patient with severe deforming arthritis and autoamputation of several digits. (B) Endoscopy studies of the stomach before (left) and 5 months after the initiation of vonicog alfa treatment (right) with significant improvement of angiodysplasias. (C) The course of the hematocrit levels over time in relation to treatment. Treatment with plasma-derived FVIII/VWF led to improved bleeding control and reduced the number of RBC transfusions. A significant improvement of bleeding ensued after initiation of treatment with Vonicog alfa. FVIII, factor VIII; VWF, von Willebrand factor

eventually leading to the persistent need for blood transfusions with frequent hospitalizations and endoscopic interventions over the past months before the current admission to our center.

Immediately before being transferred to our center, she had been admitted to another hospital for severe gastrointestinal bleeding. At that hospital, a minimum hemoglobin level of 5.8 g/dL had been detected, and a computed tomography angiography was performed without an identifiable bleeding source. She received eight red blood cell (RBC) transfusions and 2 units of fresh-frozen plasma. On admission, we measured a hemoglobin level of 7.0 g/dL (normal range, 11.5-15.0 g/dL), and she was transferred to the intensive care unit because of daily RBC transfusion requirements, impending hemodynamic instability and persistent gastrointestinal bleeding despite normal platelet counts and routine tests of coagulation (partial thrombin time and international normalized ratio). An endoscopic intervention with argon plasma coagulation of gastric and colonic angiodysplasias was again performed but did not lead to lasting improvement. Additional laboratory investigations confirmed the presence of antinuclear antibodies and anticentromere

antibodies, as described previously. Because the current bleeding episode was life threatening and refractory to supportive and endoscopic treatments, a multidisciplinary approach between critical care, rheumatology, and hematology ensued.

It was deemed unlikely that the severity of bleeding from angiodysplasias could be ascribed to the underlying autoimmune disease alone, and further hemostaseological workup was performed. At this point, the differential diagnoses favored acquired forms of VWD, which are rare but have been reported in autoimmune diseases. We measured factor VIII (FVIII) activity, VWF antigen, ristocetin cofactor (ACL TOP Analyzer, Instrumentation Lab., Werfen, Vienna, Austria), in-vitro bleeding time (Innovance PFA 200 System, Siemens Healthcare GmbH, Erlangen, Germany), and platelet aggregometry (APACT 4004, LabiTec GmbH, Ahrensburg, Germany). Additionally, collagen-binding activity and multimer analysis were performed (Prof. Budde, MediLys, Hamburg, Germany). Based on the results given in Table 1 and the detected loss of large VWF multimers and the absence of platelet aggregation under low doses of ristocetin, we reached a diagnosis of type 2A VWD according to the current classification.^{8,9} Subsequent further history taking and investigations revealed the same disease in the patient's older brother, who reported frequent epistaxis and prolonged bleeding after minor trauma. The condition was likely inherited in an autosomal-dominant trait by the patient's mother, who had reportedly suffered heavy, and at times, life-threatening menstrual bleeding. She was deceased at the time, which precluded further analyses. Another sister of the patient reported no history of bleeding. Overall, the family history confirmed the diagnosis of inherited VWD (Figure 2).

We initiated treatment with the usual on-demand administration of plasma-derived VWF/FVIII concentrates, which had no long-lasting effect and led to recurrent transfusion requirements and endoscopic interventions with argon plasma coagulation. Therefore, prophylaxis with plasma-derived VWF/FVIII concentrates was administered, which led to a partial response with an improvement of gastrointestinal bleeding but the persistent need for RBC transfusions. However, this therapy was complicated because factor VIII clotting activity (FVIII:C) plasma levels reached values far above the normal range, further deteriorating the patient's underlying RP and PAH. Consequently, treatment with the endothelin receptor antagonist ambrisentan was

TABLE 1 Results of coagulation studies

Assay	Before vonicog alfa treatment	During vonicog alfa treatment	Normal range
FVIII:C activity	88%	101%	70%-170%
VWF antigen	103%	176%	66%-176%
Ristocetin cofactor	28%	109%	61%-239%
Ratio	0.27		>0.6
Collagen binding activity	4.3%		50%-250%
PFA 200 COL/EPI	>300 s		85-165 s
PFA 200 COL/ADP	160 s		71-118 s

Abbreviations: ADP, adenosine diphosphate; COL, collagen; EPI, epinephrine; FVIII, factor VIII; FVIII:C, factor VIII clotting activity; PFA, platelet function analyzer; VWF, von Willebrand factor.

Bold entries denote abnormal values.

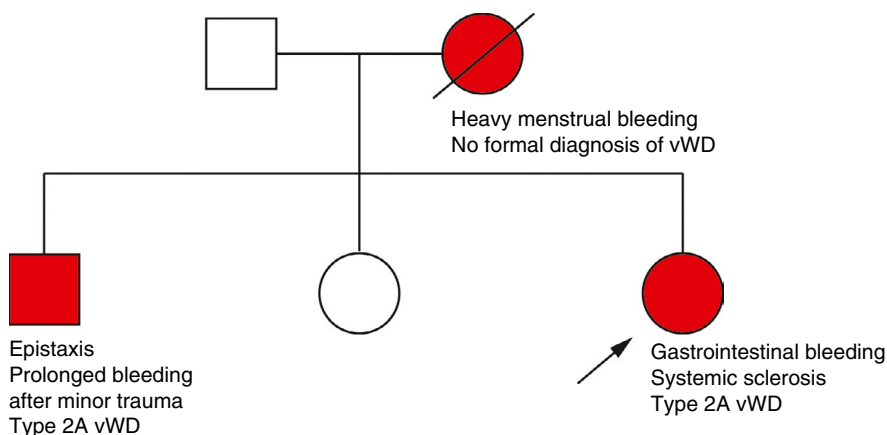


FIGURE 2 Pedigree of the patient. The patient's mother (deceased) reportedly suffered from heavy menstrual bleeding. The patient's older brother experienced frequent epistaxis and prolonged bleeding after minor trauma. Another older sister is unaffected

begun concomitantly with the ongoing substitution of plasma-derived VWF/FVIII. Unfortunately, ambrisentan had to be discontinued due to developing medication-induced anemia.

Since it proved impossible to control the bleeding episodes without worsening the SSc-related sequelae sufficiently, we decided to commence treatment with the only available VWF preparation devoid of FVIII, the recombinant VWF concentrate vonicog alfa. Prophylactic (off-label) administration three times per week (8450 IU/week, 50 IU/kg), significantly reduced bleeding episodes and stabilized hematocrit levels without any adverse events. The number of RBC transfusions could be substantially reduced (Figure 1C). An endoscopic investigation 5 months after vonicog alfa treatment initiation showed a clearly diminished number of angiodysplasias (Figure 1B). Nevertheless, hematocrit levels remain below 35% despite vonicog alfa treatment. We assume that small bowel angiodysplasias persist and may lead to occult bleeding. However, the overt gastric and colonic angiodysplasias have improved.

3 | DISCUSSION

We report the unusual case of a patient with SSc and inherited VWD with an insufficient response to conventional treatment. We successfully treated her with vonicog alfa as repeated administration three times per week. Vonicog alfa contains high amounts of ultra-large VWF multimers,¹⁰ which are essential for hemostasis and particularly for angiogenesis regulation. The Food and Drug Administration has approved vonicog alfa for on-demand treatment, control of bleeding episodes, and perioperative bleeding management in patients with VWD.¹¹

Continuous prophylaxis with vonicog alfa stabilized haemostasis and positively influenced the vascular malformations without the undesirable effects resulting from high FVIII:C levels. The mechanism of vascular homeostasis regulation by VWF is complex: Its binding to integrin $\alpha v\beta 3$ in endothelial cells can activate angiogenesis while at the same time counteracting vessel maturation in vascular smooth muscle cells (reviewed in Randi and Laffan¹²). Since this is predominantly mediated by the ultra-large VWF multimers, vonicog alfa may have effectively interfered with the disrupted vessel formation in this case. An antiangiodyplastic effect of rituximab seems unlikely, as it had been administered for years until 3 months before the current admission without improving the bleeding frequency.

The exact mechanism of how vonicog alfa led to better control of the gastrointestinal bleeding than a plasma-derived VWF/FVIII-containing preparation, which led to only a partial improvement, remains elusive. In this particular patient with concomitant SSc and PAH, we observed worsening of PAH, presumably due to high levels of FVIII. Higher levels of FVIII have been described in patients with chronic thromboembolic pulmonary hypertension and PAH compared to healthy controls.¹³

Because acquired functional VWF defects are increasingly recognized in autoimmune and other diseases,¹⁴ a thorough hemostaseological evaluation is highly recommendable in systemic diseases

because patients who are potentially jeopardized by a further increase of FVIII activity through plasma-derived VWF/FVIII concentrates may particularly benefit from the administration of FVIII-free VWF preparations. Also, the testing of VWD-associated abnormalities is an area of active research.¹⁵

Of note, the patient and her siblings had not been aware of an inherited coagulation disorder, which underscores the importance of history taking in bleeding disorders. This is especially true in patients with an autoimmune disorder because severe complications, as in the presented case, may be falsely ascribed to the underlying condition and preclude appropriate testing.

In conclusion, this is the first reported case of the administration of vonicog alfa as prophylactic therapy in a patient with a combination of SSc-associated gastrointestinal bleeding and inherited type 2A VWD as a result of multidisciplinary care between critical care, rheumatology, and hematology.

ACKNOWLEDGMENTS

The authors are indebted to the patient for providing written informed consent to publish this case report and for the contribution of valuable supporting information from her medical records. Open access funding enabled and organized by Projekt DEAL.

AUTHOR CONTRIBUTIONS

PK treated the patient, collected and analyzed data, wrote the manuscript, and created the figures. MW treated the patient, analyzed data and cowrote the manuscript. CB treated the patient, collected and analyzed data, and edited the manuscript.

RELATIONSHIP DISCLOSURE

PK declared personal fees, travel support, or honoraria from Abbvie, Bristol-Myers Squibb, Chugai, Gilead, Glaxo Smith Kline, Novartis, and Pfizer, all unrelated to this manuscript. MW and CB declared no competing interests.

ORCID

Peter Korsten  <https://orcid.org/0000-0001-6065-5680>

TWITTER

Peter Korsten  @pekor002

REFERENCES

1. Leebeek FWG, Eikenboom JCJ. Von Willebrand's disease. Longo DL, editor. *N Engl J Med*. 2016;375(21):2067–80.
2. Tiede A, Zieger B, Lisman T. Acquired bleeding disorders. *Haemophilia*. 2020.
3. Gabrielli A, Avvedimento EV, Krieg T. Scleroderma. *N Engl J Med*. 2009;360(19):1989–2003.
4. Shreiner AB, Murray C, Denton C, Khanna D. Gastrointestinal manifestations of systemic sclerosis. *J Scleroderma Relat Disord*. 2016;1(3):247–56. [Epub ahead of print].
5. Richard N, Hudson M, Wang M, Gyger G, Proudman S, Stevens W, et al. Severe gastrointestinal disease in very early systemic sclerosis is associated with early mortality. *Rheumatology (Oxford)*. 2019;58(4):636–44.

6. Marie I, Antonietti M, Houivet E, Hachulla E, Maunoury V, Bienvenu B, et al. Gastrointestinal mucosal abnormalities using videocapsule endoscopy in systemic sclerosis. *Aliment Pharmacol Ther*. 2014;40(2):189–99.
7. García-Compeán D, Cueto-Aguilera ÁND, Jiménez-Rodríguez AR, González-González JA, Maldonado-Garza HJ. Diagnostic and therapeutic challenges of gastrointestinal angiodysplasias: A critical review and view points. *World J Gastroenterol*. 2019;25(21):2549–64.
8. The Diagnosis, Evaluation and Management of von Willebrand Disease | National Heart, Lung, and Blood Institute (NHLBI) [Internet]. [cited 2020 Jul 6]. Available from: <https://www.nhlbi.nih.gov/health-topics/diagnosis-evaluation-and-management-of-von-willebrand-disease>
9. Sadler JE, Budde U, Eikenboom JCJ, Favaloro EJ, Hill FGH, Holmberg L, et al. Update on the pathophysiology and classification of von Willebrand disease: a report of the Subcommittee on von Willebrand Factor. *J Thromb Haemost*. 2006;4(10):2103–14.
10. Singal M, Kouides PA. Recombinant von Willebrand factor: a first-of-its-kind product for von Willebrand disease. *Drugs Today*. 2016;52(12):653–64.
11. Tran T, Arnall J, Moore DC, Ward L, Palkimas S, Man L. Vonicog alfa for the management of von Willebrand disease: a comprehensive review and single-center experience. *J Thromb Thrombolysis*. 2020;49(3):431–40.
12. Randi AM, Laffan MA. Von Willebrand factor and angiogenesis: basic and applied issues. *J Thromb Haemost*. 2017;15(1):13–20.
13. Bonderman D, Turecek PL, Jakowitsch J, Weltermann A, Adlbrecht C, Schneider B, et al. High prevalence of elevated clotting factor VIII in chronic thromboembolic pulmonary hypertension. *Thromb Haemost*. 2003;90(3):372–6.
14. Tiede A, Rand JH, Budde U, Ganser A, Federici AB. How I treat the acquired von Willebrand syndrome. *Blood*. 2011;117(25):6777–85.
15. Vangenechten I, Gadisseur A. Improving diagnosis of von Willebrand disease: Reference ranges for von Willebrand factor multimer distribution. *Res Pract Thromb Haemost*. 2020;4(6):1024–34.

How to cite this article: Korsten P, Wallbach M, Binder C. Type 2A von Willebrand disease and systemic sclerosis: Vonicog alfa reduced gastrointestinal bleeding. *Res Pract Thromb Haemost*. 2020;4:1230–1234. <https://doi.org/10.1002/rth2.12426>