

Deep Inferior Epigastric Artery Perforator Flap Breast Reconstruction without Microsurgery Fellowship Training

Hakan Orbay, MD, PhD*
 Brittany K. Busse, MD*
 Thomas R. Stevenson, MD*
 Howard T. Wang, MD†
 David E. Sahar, MD*

Background: Deep inferior epigastric artery perforator (DIEP) flap breast reconstruction requires complex microsurgical skills. Herein, we examine whether DIEP flap breast reconstruction can be performed safely without microsurgical fellowship training.

Methods: A total of 28 patients and 34 DIEP flaps were included in the study. We reviewed the medical records of patients for donor site and flap-related complications and analyzed the correlation between the complications and preoperative risk factors. We also performed a literature review to compare complication rates in our series with the literature.

Results: We observed total flap necrosis in 1 patient (2.9%), partial flap necrosis in 5 patients (14.7%), infection in 1 patient (2.9%), hematoma/seroma in 3 patients (8.8%), donor site complications in 5 patients (18.5%), venous occlusion in 4 patients (11.7%), and arterial occlusion in 1 patient (2.9%). We did not observe any correlation between complications and preoperative risk factors. Literature review yielded 18 papers that met our inclusion criteria. Partial flap necrosis rate was significantly higher in our series compared with literature (14.7% vs 1.6%, $P = 0.003$). Venous complication rate was marginally higher in our series compared with literature (11.7% vs 3.3%, $P = 0.057$). However, total flap loss rate in our series was comparable with the literature (2.9% vs 2.2%, $P = 0.759$).

Conclusion: With proper training during plastic surgery residency, DIEP flap can be performed with acceptable morbidity. (*Plast Reconstr Surg Glob Open* 2015;3:e455; doi: 10.1097/GOX.0000000000000428; Published online 16 July 2015.)

Awareness and provision of reconstruction following mastectomy for breast cancer has increased significantly since the passage of

From the *University of California Davis Medical Center, Department of Surgery, Division of Plastic Surgery, Sacramento, Calif.; and †University of Texas San Antonio Medical Center, Department of Surgery, Division of Plastic Surgery, San Antonio, Tex.

Drs. Orbay and Busse contributed equally to this study.

Received for publication November 24, 2014; accepted May 27, 2015.

Copyright © 2015 The Authors. Published by Wolters Kluwer Health, Inc. on behalf of The American Society of Plastic Surgeons. All rights reserved. This is an open-access article distributed under the terms of the Creative Commons Attribution-Non Commercial-No Derivatives License 4.0 (CCBY-NC-ND), where it is permissible to download and share the work provided it is properly cited. The work cannot be changed in any way or used commercially.

DOI: 10.1097/GOX.0000000000000428

the Women's Health and Cancer Rights Act in 1998. Subsequently, the number of postmastectomy breast reconstruction cases has also increased, and over 91,000 breast reconstructions were performed by plastic surgeons in the United States in 2012.^{1,2} Deep inferior epigastric artery perforator (DIEP) flap breast reconstruction has been repeatedly shown to result in increased patient satisfaction over implant

Disclosure: The authors have no financial interest to declare in relation to the content of this article. This work was supported by funds from the Department of Surgery, University of California Davis Medical Center and by the National Center for Advancing Translational Sciences, National Institutes of Health, through grant number UL1 TR000002. The content is solely the responsibility of the authors and does not necessarily represent the official views of the NIH. The Article Processing Charge was paid for by the authors.

reconstruction.^{3,4} However, the ratio of this technique among breast reconstruction cases is exceedingly low, and only 7.1% of all breast reconstructions performed in 2012 were DIEP flap reconstructions.^{1,2} Because of the complexity and steep learning curve of DIEP flap, most of the plastic surgeons without a formal microsurgical training opt to use simpler methods for breast reconstruction, such as breast implants or pedicled flaps.^{2,5,6} A recent study has shown that in high-volume breast reconstruction centers, whether or not the plastic surgeon had fellowship training in advanced microsurgical techniques is independently associated with the number of microsurgical reconstructions performed.² However, the outcomes of DIEP flap breast reconstructions performed by a novice surgeon without microsurgical fellowship training when compared with more experience surgeons have not been studied before.

In our Plastic Surgery Division, a series of DIEP flap breast reconstructions were performed by a single full-time academic plastic surgeon, immediately after completion of his plastic surgery residency but without a formal microsurgical fellowship. This study's goal is to compare complication rates in our series with previously published series in the literature to determine if lack of formal microsurgical fellowship training increases complication rates in DIEP flap breast reconstruction.

MATERIALS AND METHODS

Our Institutional Review Board approved this study. The senior author reviewed electronic medical records of 28 patients who underwent DIEP flap breast reconstruction between August 2010 and

August 2013. Complications evaluated included total flap loss (TFL), partial flap loss (PFL), breast infection, breast hematoma/seroma, arterial thrombosis, venous thrombosis, fat necrosis, and donor site complications. We compared complication rates between patients younger than 65 years and those 65 years and older, between obese patients [body mass index (BMI) > 30] and nonobese patients, and between patients with and without a history of radiotherapy using Fisher's exact test.

Literature Review

We carried out a literature search in PubMed and Google Scholar databases using “DIEP” and “deep inferior epigastric artery perforator” as search terms. We searched all the papers published since the DIEP flap breast reconstruction was first described (1994–2014; Fig. 1).

Data Extraction and Statistical Analysis

We extracted information from the selected studies in a standardized form starting with lead author and publication year, and followed by the number of patients, TFL, PFL, breast infection, breast hematoma/seroma, arterial thrombosis, venous thrombosis, fat necrosis, and donor site complications (Table 1). We compared the rates of complications between our series (UCD) and previous studies using mixed effects logistic regression models including a fixed effect for our series vs. a random effect for previously published studies. Aggregated overall rates, aggregated rates from previous studies, and odds ratios for our series versus previous studies were all estimated from these models. We conducted the analyses using the statistical software environment R, version 3.1.1 and R package lme4, version 1.1 -7. (R foundation,

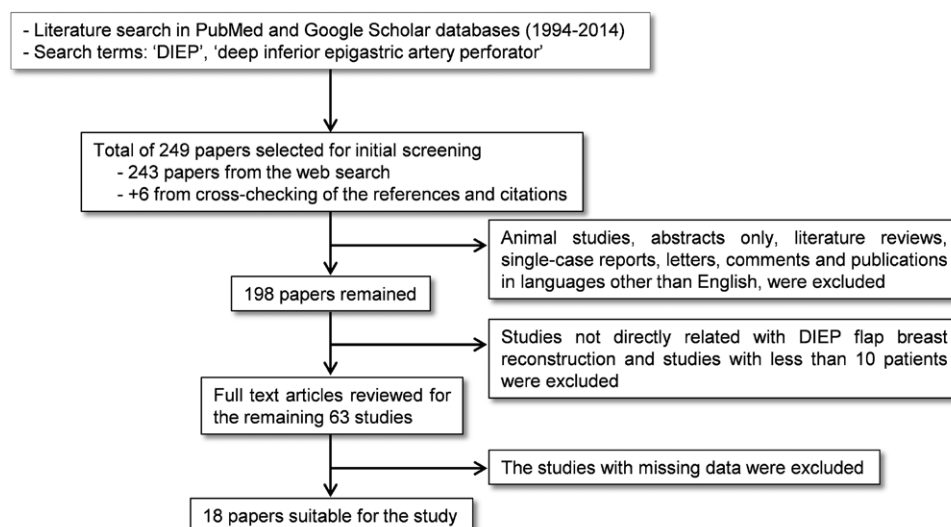


Fig. 1. Study attrition diagram.

Table 1. The Studies Included in the Literature Review

Study	<i>n</i> *	TFL	PFL	Infection	Hematoma/ Seroma	Donor Site	Venous	Arterial	Fat Necrosis
Blondeel ³⁶	87	2 (2%)	7 (7%)	3 (3%)	3 (3%)	2 (2%)	4 (4%)	2 (2%)	6 (6%)
Nahabedian et al ³⁴	17	1 (5%)	0	0	1 (5%)	0	2 (10%)	0	2 (10%)
Guerra et al ³¹	140	0	5 (1.8%)	1 (0.3%)	2 (0.6%)	37 (11.1%)	5 (1.8%)	2 (0.6%)	30 (9%)
Nahabedian et al ³⁷	88	2 (2.7%)	0	0	0	2 (2.7%)	5 (4.5%)	0	8 (6.4%)
Garvey et al ³⁸	96	3 (3.1%)	0	12 (12.5%)	12 (12.5%)	72 (75%)	3 (3.1%)	0	17 (17.7%)
Scheer et al ³⁵	68	5 (7.3%)	1 (1.47%)	3 (4.4%)	13 (19%)	27 (39.7%)	6 (8.8%)	0	36 (52.9%)
Granzow et al ⁷	758†	7 (1%)	18 (2.5%)	53 (7%)	78 (11%)	42 (5.7%)	22 (3%)	7 (1%)	91 (13%)
Lindsey ³⁹	107	9 (8.4%)	1 (0.9%)	3 (2.8%)	0	0	5 (4.6%)	3 (2.8%)	1 (0.9%)
Drazan et al ⁴⁰	55	0	0	0	6 (10.8%)	2 (3.6%)	0	0	2 (1.8%)
Xu et al ⁴¹	113	2 (1.8)	4 (3.5)	0	3 (2.7)	5 (4.4)	5 (4.5)	1 (0.9)	20 (17.7)
Enajat et al ⁴²	501	11 (1.9%)	4 (0.7%)	60 (10.6%)	55 (9.8%)	0	17 (3%)	18 (3.1%)	56 (9.9%)
Acosta et al ⁴³	101	2 (1.9%)	1 (0.9%)	10 (9.9%)	8 (7.8%)	0	0	3 (2.9%)	0
Enajat et al ⁴²	18	0	0	2 (11%)	1 (6%)	0	1 (6%)	0	1 (6%)
Ochoa et al ⁴⁵	418	6 (1%)	0	33 (5.4%)	17 (2.7%)	108 (25.8%)	0	4 (0.6%)	63 (10.4%)
Venkat et al ⁴⁶	54	0	1 (1.8%)	1 (1.8%)	0	5 (9%)	2 (3.6%)	0	1 (1.8%)
Andree et al ⁴⁷	58	1 (1.7%)	0	0	3 (5.1%)	16 (27.2%)	0	0	25 (19.8%)
Kim et al ⁴⁸	100	0	0	0	1 (1%)	0	1 (1%)	0	6 (6%)
Marre and Hontanilla ¹⁸	182	6 (3%)	0	0	0	0	14 (7%)	3 (1.5%)	0

*Number of the patients.

†The number is the number of the flaps for this study.

free software). We conducted mixed effects logistic regression modeling using the R package lme4, version 1.1–7.

RESULTS

Of the 28 patients, 22 underwent unilateral reconstruction and 6 patients underwent bilateral reconstruction. Of the 34 flaps, 100% were performed for breast reconstruction following mastectomy. The mean patient age was 51 ± 8 years (range 31–68) and the mean BMI was 27.6 ± 5.1 (range 21–38). Mean patient follow-up time was 10 months (range 1–25). Nine flaps were created as an immediate reconstruction, and 25 were created on a delayed basis. Mean operating time was 7.6 ± 2.2 hours. Overall, there were flap-related complications in 11 reconstructed breasts (32.3%). A summary of the incidences of complications is listed in Table 2. TFL was observed in 1 case. Final reconstruction for this patient was a latissimus dorsi flap over an implant. PFLs were treated by simple debridement and closure of the defect with adequate remaining tissue ($n = 3$), or insertion of a tissue expander and implant reconstruction ($n = 1$), or latissimus dorsi flap to aug-

ment the remaining tissue ($n = 1$). Figure 2 shows a patient with breast carcinoma before mastectomy and after reconstruction with unilateral DIEP flap and a patient who had venous thrombosis in the flap on the right side after a bilateral DIEP flap reconstruction. Overall, 6 of 28 patients experienced complications relating to their donor site including cellulitis ($n = 2$), abscess formation ($n = 2$), necrotizing infection requiring debridement ($n = 1$), and wound dehiscence ($n = 1$).

No complication was significantly associated with any of the risk factors examined. Table 3 shows complications by age category; Table 4 shows complications by BMI category; and Table 5 shows complications by history of radiotherapy.

Comparison of Outcomes with the Literature

The literature search yielded 243 papers (Fig. 1). Additionally, cross-checking of the references and citations in review papers yielded 6 more papers. Of the 249 total studies, we included the studies performed on women and excluded animal studies, abstracts only, literature reviews, single-case reports, letters, comments, and publications in languages other than English. Application of these filters reduced the number of papers to 198. We retrieved abstracts for the remaining 198 studies. We excluded studies not directly related with DIEP flap breast reconstruction and studies with less than 10 patients. We reviewed full text articles for the remaining 63 studies. If some relevant data were missing from the included studies we contacted the corresponding authors via e-mail to request the missing data. The studies that we could not retrieve the missing data were

Table 2. Complications in Our Patient Series

TFL	1 (2.9%)
PFL	5 (14.7%)
Infection	1 (2.9%)
Hematoma/seroma	3 (8.8%)
Donor site	5 (18.5%)
Venous	4 (11.7%)
Arterial	1 (2.9%)
Fat necrosis	0 (0%)
Total (flaps)	11 (32.3%)

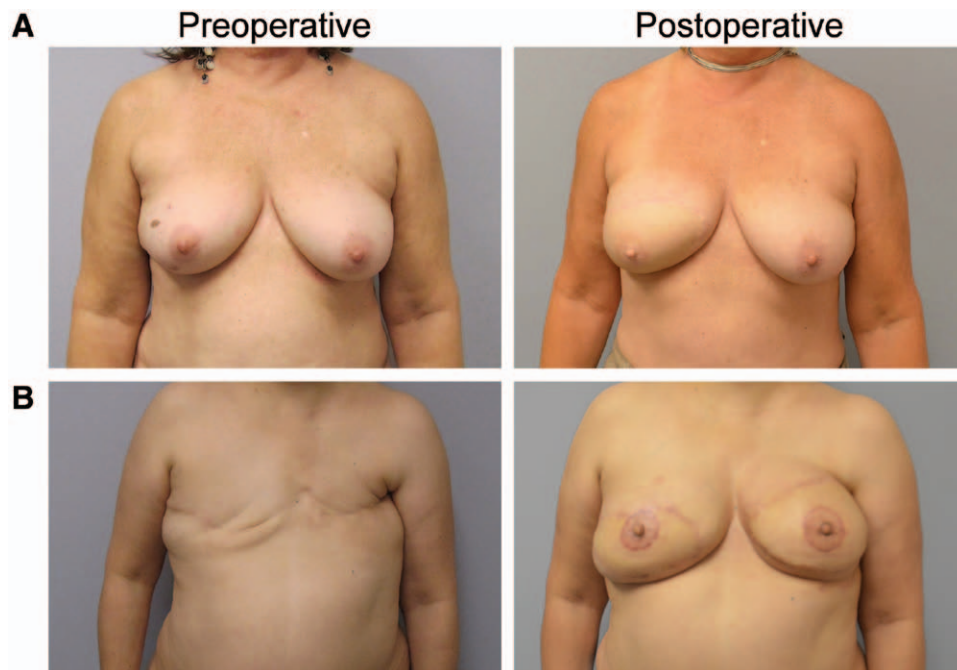


Fig. 2. A, A patient with right breast carcinoma treated with total mastectomy. The breast was reconstructed with a unilateral DIEP flap. Postoperatively, the flap had a perfect skin match with recipient site, and the breasts were symmetrical. We have reconstructed nipple with a cervical visor flap and areola with a skin graft. B, A bilateral DIEP flap breast reconstruction. In this patient, right DIEP flap suffered from venous insufficiency on day 1 after the operation. We have reoperated the patient and performed an embolectomy. The flap had a healthy color soon after embolectomy, and the patient recovered with no other complications.

Table 3. Complications by Age

Complication	Age < 65 (n = 25), n (%)	Age ≥ 65 (n = 2), n (%)	P Value (Fisher's Exact Test)
TFL	0	1 (50)	0.074
PFL	5 (20)	0	>0.999
Infection	1 (4)	0	>0.999
Hematoma/seroma	2 (8)	1 (50)	0.214
Donor site	5 (20)	0	>0.999
Venous	4 (16)	0	>0.999
Arterial	1 (4)	0	>0.999
Fat necrosis	0	0	N/A

N/A, not available.

Table 4. Complications by BMI

Complication	BMI < 30 (n = 17), n (%)	BMI ≥ 30 (n = 10), n (%)	P Value (Fisher's Exact Test)
TFL	1 (6)	0	>0.999
PFL	2 (12)	3 (30)	0.326
Infection	1 (6)	0	>0.999
Hematoma/seroma	2 (12)	1 (10)	>0.999
Donor site	2 (12)	3 (30)	0.326
Venous	1 (6)	3 (30)	0.128
Arterial	1 (6)	0	>0.999
Fat necrosis	0	0	N/A

N/A, not available.

Table 5. Complications by History of Radiotherapy

Complication	No Radiotherapy (n = 11), n (%)	Radiotherapy (n = 16), n (%)	P Value (Fisher's Exact Test)
TFL	0	1 (6)	>0.999
PFL	1 (9)	4 (25)	0.619
Infection	0	1 (6)	>0.999
Hematoma/seroma	0	3 (19)	0.248
Donor site	1 (9)	4 (25)	0.619
Venous	1 (9)	3 (19)	0.624
Arterial	0	1 (6)	>0.999
Fat necrosis	0	0	N/A

N/A, not available.

excluded from the study (Fig. 1). As result a total of 18 studies were identified as suitable for the study (Table 1). Table 6 shows rates of each complication overall, at our series, and published series estimated from the mixed effects logistic regression model. Rates of PFL were significantly higher at our series compared with previous studies, with an observed rate of 14.7% our series and an estimated aggregate rate of 1.6% at previous studies ($P=0.003$, odds ratio for our series vs previous studies = 12.22). Rates of venous complications were marginally higher at our series than in previous studies, with an observed rate

Table 6. Comparison of Complication Rates at UCD and Outside UCD from Mixed Effects Logistic Regression Model

Complication	Estimated Overall Rate (UCD + Previous Studies) (95% CI)	Estimated Rate from Previous Studies (95% CI)	Odds Ratio (UCD vs Previous Studies) (95% CI)	P Value
TFL	0.027 (0.009, 0.078)	0.022 (0.015, 0.032)	1.425 (0.148, 13.73)	0.759
PFL	<i>0.054 (0.025, 0.114)</i>	<i>0.016 (0.010, 0.025)</i>	<i>12.22 (2.407, 62.02)</i>	<i>0.003</i>
Infection	0.031 (0.008, 0.111)	0.034 (0.021, 0.056)	0.817 (0.055, 12.19)	0.884
Hematoma/seroma	0.062 (0.021, 0.171)	0.040 (0.024, 0.067)	2.465 (0.255, 23.87)	0.436
Donor site	0.093 (0.016, 0.396)	0.052 (0.022, 0.116)	3.552 (0.087, 144.9)	0.503
Venous	0.067 (0.032, 0.134)	0.033 (0.023, 0.046)	4.508 (0.959, 21.19)	0.057
Arterial	0.024 (0.008, 0.066)	0.017 (0.012, 0.024)	1.979 (0.233, 16.81)	0.532
Fat necrosis	0.047 (0.010, 0.202)	0.084 (0.047, 0.147)	0.292 (0.011, 7.518)	0.457

UCD, University of California Davis Medical Center; CI, confidence interval.

Italics indicate statistically significant differences between this series and the literature.

of 11.7% at our series and an estimated aggregate rate of 3.3% elsewhere ($P = 0.057$, odds ratio for our series vs previous studies = 4.508).

DISCUSSION

DIEP flap is an excellent choice for autologous breast reconstruction.⁷⁻¹⁶ However, surgery requires advanced microsurgical skills and time commitment, which may be responsible for the very low share of this technique among all breast reconstruction cases. The fear of encountering setbacks, such as increased operating time (leading potentially to increased vascular complications, flap loss, or increased fat necrosis), difficulty in identifying perforators (risk of pedicle trauma), or technical difficulties with anastomosis may lead young surgeons to forego performing a DIEP flap for breast reconstruction altogether.^{17,18} The main concern for reconstructive surgeons performing microsurgical breast reconstruction is total loss of flap, which can be traumatizing to patients who are already emotionally compromised because of the nature of their underlying disease. It can be anticipated that lack of formal microsurgical training increases TFL rates; however, in our series, we have shown that TFL and overall breast-specific complication rates were comparable with literature.

The PFL in our series was significantly higher than aggregated rate derived from literature. During DIEP flap surgery, depending on the anatomy of perforators, it is sometimes necessary to convert to muscle sparing transverse rectus abdominis muscle (TRAM) flap and include a cuff of muscle around perforators to avoid venous and arterial complications.¹⁹⁻²² In our earlier cases, we occasionally dissected both lateral and medial row of abdominal perforators and pick the larger perforator to avoid muscle incision and adhered strictly to DIEP flap technique. This may explain the higher rates of venous complications and related PFL in our series. An alternative strategy we have adapted in our practice to prevent venous complications was to clamp venous perfora-

tors for 10 minutes and leave the largest perforator open before harvest to see if it can support the flap without congestion or ischemia. Our venous occlusion rates have decreased after this modification, and we recommend novice plastic surgeons to do the same to determine the course of operation and convert to muscle sparing TRAM flap if necessary. It should also be noted that although aggregated rate of PFL from previous studies was lower than our series (3.3% vs 11.7%), there are papers reporting a relatively high PFL rate of 31% in series performed by surgeons with prior microsurgical training.²³ Lack of a standard definition for PFL in the literature may explain this variability.

Autologous breast reconstruction has proven long-term benefits and should be available to the patients on a widespread basis. Recently, the American Society of Plastic Surgeons made it a mission to increase patient education about breast reconstruction and encourage plastic surgeon involvement in comprehensive breast cancer care.² Based on our experience, we believe it is in the best interest of patients that all plastic surgeons, fellowship and nonfellowship trained, familiarize themselves with DIEP flap breast reconstruction. A recent literature review suggests that plastic surgeons are losing their hegemony in breast surgery and microsurgical postmastectomy reconstruction.^{2,24} The breast reconstruction practice of the plastic surgeons in the United States consists of 79% tissue expander/implants, 14% pedicled TRAM flaps, 9% latissimus dorsi flaps, 3% free TRAM flaps, and 3% perforator flaps. Overall, only 19% of surgeons perform microsurgical breast reconstruction.^{2,24} The emerging popularity of acellular dermal matrices as an adjunct to implant-based reconstruction allows surgeons to achieve better results with implants, which most likely influences the declining trend in microsurgical breast reconstruction.^{2,24} A survey of female plastic surgeons revealed that most would choose implant-based reconstruction for themselves.²⁵ This trend could be interpreted to

imply breast reconstruction may eventually follow the path of microsurgical head and neck reconstruction, pioneered by plastic surgeons but is now largely performed by other surgical disciplines.^{2,26} In some European countries, oncoplastic breast fellowships have already been established that include training in both ablative and reconstructive breast surgery.^{2,27} Reduction mammoplasty may also be offered by “breast surgeons” in breast cancer units.^{2,28} It is not difficult to imagine that the development of breast surgery as its own specialty could eventually grow to encompass all breast operations, including cosmetic augmentation and mastopexy.² It is important to raise awareness among plastic surgeons of the need to improve access to autologous and microsurgical breast reconstruction.

Although microsurgical fellowship training is closely associated with high volume of microsurgical breast reconstructions, very few surgeons (approximately 1 of 5) actually declare inadequate training as a reason for not performing microsurgical breast reconstruction.² We hope our results will encourage nonfellowship trained plastic surgeons to perform more microsurgical breast reconstructions and help maintain the prominence of plastic surgeons in the field of breast reconstruction.

Limitations of the Study

The limitations of this study are the small sample size and the variability in the literature in the definition of the complications. For example, there is no universally accepted definition or classification of partial necrosis and fat necrosis in DIEP flap, and a broad range of definitions of PFL and fat necrosis based on different parameters (eg, percentage of flap lost, area of flap lost, and necessity of reoperation) have been used in different publications.²⁹ This leads to highly variable complication rates, and it is difficult to compare these complication rates among different centers and case series. A new classification system has been proposed by Lie et al to address this problem.²⁹ Routine use of standardized classification and definition parameters will decrease the variability and yield more meaningful statistical analysis of DIEP flap complications in the future.

Although the correlation between certain risk factors and DIEP flap complications is well documented,^{18,30–35} we did not observe the same correlation in our study. This can be explained by the small size of the patient population. However, the learning curve for DIEP flaps is about 30 flaps.^{5,6,23} With 34 flaps in our series, we are just above this cut off with very good outcomes, and we believe that our results are significant despite the relatively small sample size.

CONCLUSIONS

Microsurgical breast reconstruction using the DIEP flap provides excellent aesthetic outcome with little donor site morbidity, and its use should be increased. With proper training during plastic surgery residency DIEP flap breast reconstruction can be performed with acceptable morbidity and failure rates.

David E. Sahar, MD

Division of Plastic Surgery
University of California Davis Medical Center
2221 Stockton Blvd
Suite 2123, Sacramento, CA 95817
E-mail: david.sahar@ucdmc.ucdavis.edu

ACKNOWLEDGMENTS

Authors would like to thank to Amy Studer and Blythe Durbin-Johnson for their support and assistance for this study.

REFERENCES

- 2012 Plastic Surgery Statistics Report. American Society of Plastic Surgeons. 2013.
- Kulkarni AR, Sears ED, Atisha DM, et al. Use of autologous and microsurgical breast reconstruction by U.S. plastic surgeons. *Plast Reconstr Surg*. 2013;132:534–541.
- Tønseth KA, Hokland BM, Tindholdt TT, et al. Quality of life, patient satisfaction and cosmetic outcome after breast reconstruction using DIEP flap or expandable breast implant. *J Plast Reconstr Aesthet Surg*. 2008;61:1188–1194.
- Yueh JH, Slavin SA, Adesiyun T, et al. Patient satisfaction in postmastectomy breast reconstruction: a comparative evaluation of DIEP, TRAM, latissimus flap, and implant techniques. *Plast Reconstr Surg*. 2010;125:1585–1595.
- Hofer SO, Damen TH, Mureau MA, et al. A critical review of perioperative complications in 175 free deep inferior epigastric perforator flap breast reconstructions. *Ann Plast Surg*. 2007;59:137–142.
- Gill PS, Hunt JP, Guerra AB, et al. A 10-year retrospective review of 758 DIEP flaps for breast reconstruction. *Plast Reconstr Surg*. 2004;113:1153–1160.
- Granzow JW, Levine JL, Chiu ES, et al. Breast reconstruction with the deep inferior epigastric perforator flap: history and an update on current technique. *J Plast Reconstr Aesthet Surg*. 2006;59:571–579.
- Tachi M, Yamada A. Choice of flaps for breast reconstruction. *Int J Clin Oncol*. 2005;10:289–297.
- Craigie JE, Allen RJ, DellaCroce FJ, et al. Autogenous breast reconstruction with the deep inferior epigastric perforator flap. *Clin Plast Surg*. 2003;30:359–369.
- Momoh AO, Colakoglu S, Westvik TS, et al. Analysis of complications and patient satisfaction in pedicled transverse rectus abdominis myocutaneous and deep inferior epigastric perforator flap breast reconstruction. *Ann Plast Surg*. 2012;69:19–23.
- Tan S, Lim J, Yek J, et al. The deep inferior epigastric perforator and pedicled transverse rectus abdominis myocutaneous flap in breast reconstruction: a comparative study. *Arch Plast Surg*. 2013;40:187–191.
- Blondeel N, Vanderstraeten GG, Monstrey SJ, et al. The donor site morbidity of free DIEP flaps and free TRAM flaps for breast reconstruction. *Br J Plast Surg*. 1997;50:322–330.

13. Chen CM, Halvorson EG, Disa JJ, et al. Immediate postoperative complications in DIEP versus free/muscle-sparing TRAM flaps. *Plast Reconstr Surg*. 2007;120:1477–1482.
14. Chun YS, Sinha I, Turko A, et al. Comparison of morbidity, functional outcome, and satisfaction following bilateral TRAM versus bilateral DIEP flap breast reconstruction. *Plast Reconstr Surg*. 2010;126:1133–1141.
15. Egeberg A, Rasmussen MK, Sørensen JA. Comparing the donor-site morbidity using DIEP, SIEA or MS-TRAM flaps for breast reconstructive surgery: a meta-analysis. *J Plast Reconstr Aesthet Surg*. 2012;65:1474–1480.
16. Nelson JA, Guo Y, Sonnad SS, et al. A Comparison between DIEP and muscle-sparing free TRAM flaps in breast reconstruction: a single surgeon's recent experience. *Plast Reconstr Surg*. 2010;126:1428–1435.
17. Feingold RS. Improving surgeon confidence in the DIEP flap: a strategy for reducing operative time with minimally invasive donor site. *Ann Plast Surg*. 2009;62:533–537.
18. Marre D, Hontanilla B. Increments in ischaemia time induces microvascular complications in the DIEP flap for breast reconstruction. *J Plast Reconstr Aesthet Surg*. 2013;66:80–86.
19. Al-Qattan MM. A modified technique for harvesting the reverse sural artery flap from the upper part of the leg: inclusion of a gastrocnemius muscle "cuff" around the sural pedicle. *Ann Plast Surg*. 2001;47:269–274, discussion 274–278.
20. Bhat S, Shah A, Burd A. The role of freestyle perforator-based pedicled flaps in reconstruction of delayed traumatic defects. *Ann Plast Surg*. 2009;63:45–52.
21. Erni D, Harder YD. The dissection of the rectus abdominis myocutaneous flap with complete preservation of the anterior rectus sheath. *Br J Plast Surg*. 2003;56:395–400.
22. Pribaz JJ, Fine N, Orgill DP. Flap prefabrication in the head and neck: a 10-year experience. *Plast Reconstr Surg*. 1999;103:808–820.
23. Basic V, Das-Gupta R, Mesic H, et al. The deep inferior epigastric perforator flap for breast reconstruction, the learning curve explored. *J Plast Reconstr Aesthet Surg*. 2006;59:580–584.
24. Alderman AK, Atisha D, Streu R, et al. Patterns and correlates of postmastectomy breast reconstruction by U.S. Plastic surgeons: results from a national survey. *Plast Reconstr Surg*. 2011;127:1796–803.
25. Sbitany H, Amalfi AN, Langstein HN. Preferences in choosing between breast reconstruction options: a survey of female plastic surgeons. *Plast Reconstr Surg*. 2009;124:1781–1789.
26. Losken A, Nahabedian MY. Oncoplastic breast surgery: past, present, and future directions in the United States. *Plast Reconstr Surg*. 2009;124:969–972.
27. Cardoso MJ, Macmillan RD, Merck B, et al. Training in oncoplastic surgery: an international consensus. The 7th Portuguese Senology Congress, Vilamoura, 2009. *Breast* 2010;19:538–540.
28. Hernanz F, Santos R. Incorporating the surgical treatment of symptomatic macromastia into a Breast Cancer Unit: could this be a useful management policy? *Breast* 2011;20:190–191.
29. Lie KH, Barker AS, Ashton MW. A classification system for partial and complete DIEP flap necrosis based on a review of 17,096 DIEP flaps in 693 articles including analysis of 152 total flap failures. *Plast Reconstr Surg*. 2013;132:1401–1408.
30. Bozиков K, Arnez T, Hertl K, et al. Fat necrosis in free DIEAP flaps: incidence, risk, and predictor factors. *Ann Plast Surg*. 2009;63:138–142.
31. Guerra AB, Metzinger SE, Bidros RS, et al. Bilateral breast reconstruction with the deep inferior epigastric perforator (DIEP) flap: an experience with 280 flaps. *Ann Plast Surg*. 2004;52:246–252.
32. Jandali S, Nelson JA, Sonnad SS, et al. Breast reconstruction with free tissue transfer from the abdomen in the morbidly obese. *Plast Reconstr Surg*. 2011;127:2206–2213.
33. Lee KT, Lee JE, Nam SJ, et al. Ischaemic time and fat necrosis in breast reconstruction with a free deep inferior epigastric perforator flap. *J Plast Reconstr Aesthet Surg*. 2013;66:174–181.
34. Nahabedian MY, Momen B, Galdino G, et al. Breast reconstruction with the free TRAM or DIEP flap: patient selection, choice of flap, and outcome. *Plast Reconstr Surg*. 2002;110:466–475; discussion 476.
35. Scheer AS, Novak CB, Neligan PC, et al. Complications associated with breast reconstruction using a perforator flap compared with a free TRAM flap. *Ann Plast Surg*. 2006;56:355–358.
36. Blondeel PN. One hundred free DIEP flap breast reconstructions: a personal experience. *Br J Plast Surg*. 1999;52:104–111.
37. Nahabedian MY, Tsangaris T, Momen B. Breast reconstruction with the DIEP flap or the muscle-sparing (MS-2) free TRAM flap: is there a difference? *Plast Reconstr Surg*. 2005;115:436–444; discussion 45–46.
38. Garvey PB, Buchel EW, Pockaj BA, et al. DIEP and pedicled TRAM flaps: a comparison of outcomes. *Plast Reconstr Surg*. 2006;117:1711–1719; discussion 1720.
39. Lindsey JT. Integrating the DIEP and muscle-sparing (MS-2) free TRAM techniques optimizes surgical outcomes: presentation of an algorithm for microsurgical breast reconstruction based on perforator anatomy. *Plast Reconstr Surg*. 2007;119:18–27.
40. Drazan L, Vesely J, Hyza P, et al. Bilateral breast reconstruction with DIEP flaps: 4 years' experience. *J Plast Reconstr Aesthet Surg*. 2008;61:1309–1315.
41. Xu H, Dong J, Wang T. Bipedicle deep inferior epigastric perforator flap for unilateral breast reconstruction: seven years' experience. *Plast Reconstr Surg*. 2009;124:1797–1807.
42. Enajat M, Rozen WM, Whitaker IS, et al. A single center comparison of one versus two venous anastomoses in 564 consecutive DIEP flaps: investigating the effect on venous congestion and flap survival. *Microsurgery* 2010;30:185–191.
43. Acosta R, Enajat M, Rozen WM, et al. Performing two DIEP flaps in a working day: an achievable and reproducible practice. *J Plast Reconstr Aesthet Surg*. 2010;63:648–654.
44. Enajat M, Rozen WM, Whitaker IS, et al. The deep inferior epigastric artery perforator flap for autologous reconstruction of large partial mastectomy defects. *Microsurgery* 2011;31:12–17.
45. Ochoa O, Chrysopoulou M, Nastala C, et al. Abdominal wall stability and flap complications after deep inferior epigastric perforator flap breast reconstruction: does body mass index make a difference? Analysis of 418 patients and 639 flaps. *Plast Reconstr Surg*. 2012;130:21e–33e.
46. Venkat R, Lee JC, Rad AN, et al. Bilateral autologous breast reconstruction with deep inferior epigastric artery perforator flaps: review of a single surgeon's early experience. *Microsurgery* 2012;32:275–280.
47. Andree C, Munder BI, Seidenstuecker K, et al. Skin-sparing mastectomy and immediate reconstruction with DIEP flap after breast-conserving therapy. *Med Sci Monit*. 2012;18:CR716–CR720.
48. Kim H, Lim SY, Pyon JK, et al. Rib-sparing and internal mammary artery-preserving microsurgical breast reconstruction with the free DIEP flap. *Plast Reconstr Surg*. 2013;131:327e–334e.