



Since January 2020 Elsevier has created a COVID-19 resource centre with free information in English and Mandarin on the novel coronavirus COVID-19. The COVID-19 resource centre is hosted on Elsevier Connect, the company's public news and information website.

Elsevier hereby grants permission to make all its COVID-19-related research that is available on the COVID-19 resource centre - including this research content - immediately available in PubMed Central and other publicly funded repositories, such as the WHO COVID database with rights for unrestricted research re-use and analyses in any form or by any means with acknowledgement of the original source. These permissions are granted for free by Elsevier for as long as the COVID-19 resource centre remains active.

Ocular Examination and Corneal Surface Disease in the Ferret



Kathern E. Myrna, DVM, MS, DACVO^{a,*},
Nicola Di Girolamo, DMV, GPCert (ExAP), MSc (EBHC), PhD, DECZM
(Herpetology)^b

KEYWORDS

• Ferret • Ophthalmology • Cornea • Mustela • Corneal scar • Eyes

KEY POINTS

- Ocular examination of the ferret can be challenging and requires a systematic approach.
- Ferret ophthalmic disease is uncommon.
- Ferrets eyes are small and relatively well protected but they can still experience corneal surface trauma.

INTRODUCTION

Although ferrets have become popular companion animals, most knowledge on ocular diseases of the ferret comes from research into the development of the retina. This has created a paucity of reliable resources on ferret ophthalmology in clinical practice. This article reviews practical techniques for examining the domestic ferret (*Mustela putorius furo*) and reviews the most common diseases of the cornea and conjunctiva in ferrets.

OCULAR EXAMINATION

Ferrets are quick and inquisitive animals, which makes them a joy to own but a challenge to examine. Depending on the way ferrets are raised by their keepers and on individual characteristics, ferrets may be very quiet and relaxed, or inquisitive, stubborn, and even aggressive. In most cases, an ophthalmic examination can be performed by physically restraining the ferret. The common way of restraining ferrets during medical activities is called scruffing and consists of holding the skin on the back of the neck (**Fig. 1**). Depending on the desired positioning, ferrets may be held on a flat surface

Disclosure Statement: The author has nothing to disclose.

^a Department of Small Animal Medicine and Surgery, UGA Veterinary Medical Center, University of Georgia, 2200 College Station Road, Athens, GA 30602, USA; ^b Tai Wai Small Animal & Exotic Hospital, 75 Chik Shun Street, Tai Wai, Shatin, Hong Kong

* Corresponding author.

E-mail address: kmyrna@uga.edu

Vet Clin Exot Anim 22 (2019) 27–33
<https://doi.org/10.1016/j.cvex.2018.08.004>
1094-9194/19/Published by Elsevier Inc.

vetexotic.theclinics.com

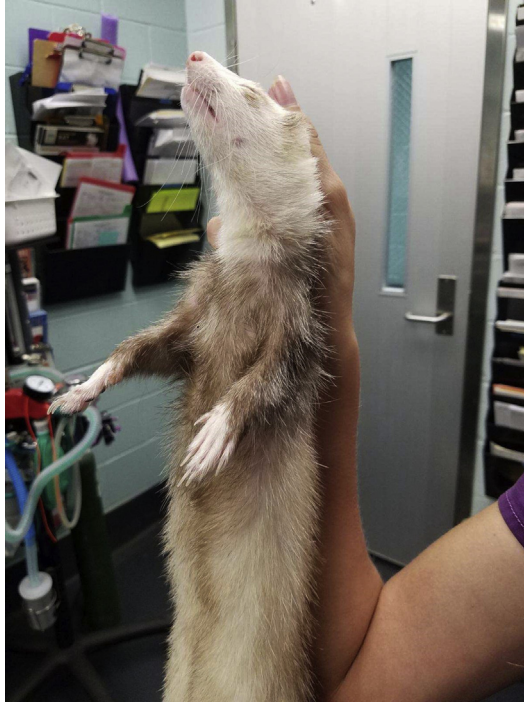

Fig. 1. The scruffing technique for immobilization and examination of the ferret.

or in the air in the so-called hanging position.¹ Holding the back of the neck permits the operators to control the head of the ferret, preventing accidental bites. Also, some ferrets become completely immobile when restrained in this manner.

An alternative to physical restraint is chemical restraint. Chemical restraint is rarely required for a simple ophthalmic examination, including intraocular pressure (IOP) measurement, but may be needed if more invasive diagnostic procedures are performed or if the ferret is especially aggressive.² Because specific literature on the effects of most anesthetic drugs on the ocular parameters of ferrets is lacking, effects similar to those demonstrated in other domestic animals should be assumed. For noninvasive ophthalmic testing procedures, the use of midazolam or butorphanol alone is sufficient. The suggested dose for midazolam or butorphanol that provides relaxation sufficient for ophthalmic testing is 0.2 mg/kg intramuscularly for either drug. This is the minimal dose that allows blood pressure measurement from 10 to 20 minutes postinjection in all ferrets, with no side-effects noted except minimal hypothermia.³

After the ferret is properly restrained, examination can be accomplished with a combination of direct and oblique illumination of the eye. A direct ophthalmoscope is an excellent tool to examine the corneal surface, as is a transilluminator focused on the eyelid and then used at a 90° angle to illuminate the cornea from the side. This technique backlights the cornea somewhat and helps localize abnormalities to the corneal surface. A normal ferret eye is pictured in [Fig. 2](#). Regular ophthalmic diagnostics are also recommended. Schirmer tear tests are cumbersome in the small eye of the ferret but can be accomplished. Normal tear values have been published as 5.31 mm/min plus or minus 1.32 mm.⁴ Fluorescein stain can be used to evaluate for corneal defects by placing a wetted strip to the sclera or a drop of mixed fluorescein solution on the

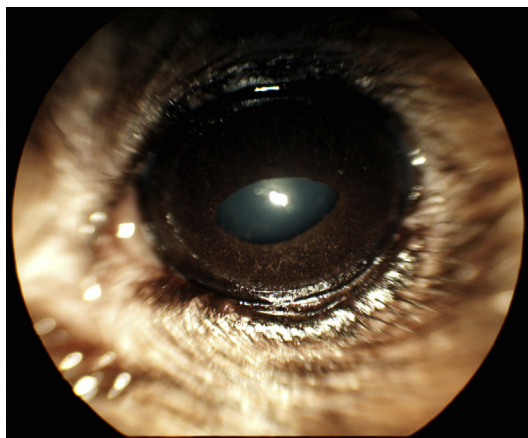


Fig. 2. A normal ferret eye. Note the elliptical pupil and domed cornea. (Courtesy of Christa Corbett, DVM, DACVO, Latham, NY.)

cornea. Rinsing may be necessary to determine true stain uptake. IOP readings are published for the applanation tonometer Tono-Pen (Reichert Technologies, Depew, NY) as 14 mm Hg plus or minus 3.27 mm Hg.⁴ The TonoVet (Icare, Finland, Oy), a rebound tonometer well-suited to the small size of the ferret eye, has published normal values of 14.07 mm Hg plus or minus 0.35.² When applanation and rebound tonometers were compared in the same ferret population, there was poor agreement between these instruments (95% of the results differed between -20.8 and $+23.8$ mm Hg) and applanation tonometry was less consistent. Multiple factors need to be accounted for in ferrets when measuring IOP because a difference between male and female sex, and a circadian trend (with lower IOP found at night) have been found.²

Conjunctivitis

Ferrets housed with improper bedding can develop a conjunctivitis caused by dust and debris.⁵ This conjunctivitis is bilateral and accompanied by the presence of debris in the tear film. This can be appreciated by illuminating the eye from the side and looking for irregularity on the corneal surface, followed by fluorescein staining to rule out corneal ulceration. Conjunctivitis has also been reported in association with systemic disease. Most notably, canine distemper presents with ocular signs early in the course of the disease.⁶ Canine distemper in the early catarrhal phase is characterized by conjunctivitis, anorexia, fever, and nasal discharge.⁷ Ferrets with canine distemper will progress to a pruritic rash followed by hyperkeratosis of the footpads.⁸ The disease has poor prognosis and early identification is helpful for patient isolation and client communication (**Fig. 3**).⁷

Human influenza virus infection can mimic canine distemper virus conjunctivitis and should be considered as a rule-out.^{7,9,10} Salmonellosis, a notable zoonosis, can present with conjunctivitis, lethargy, vomiting, anorexia, diarrhea, and pale mucous membranes.^{11,12} Diagnosis is made by positive fecal culture.¹² *Mycobacterium* infection can result in prominent conjunctival lesions in the disseminated form.¹³ A retrospective study of mycobacterial infection in ferrets showed 3 characteristics: eyelid lesions, upper or lower respiratory and gastrointestinal signs, and digestive symptoms.¹⁴ The eyelid lesions in these reports included unilateral or bilateral swelling, edema, or abscess or elevation of the third eyelid, without conjunctival or corneal lesions, which failed to respond to topical antibiotic or steroid treatment.¹⁴ In another report, an affected ferret presented with a proliferative lesion on the third eyelid, whereas another

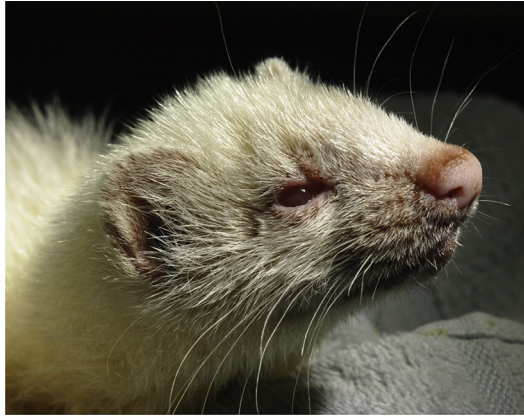

Fig. 3. Ferret distemper conjunctivitis. (Courtesy of Nicola Di Girolamo, DMV, MSc (EBHC), PhD, DECZM (Herpetology), Hong Kong.)

presented with conjunctival swelling and serous ocular discharge.¹⁵ Other clinical signs were vague and included cough, weight loss, and depression. Diagnosis is confirmed by detecting the bacteria with cytologic evaluation of conjunctival swabs or histopathologic evaluation of conjunctival biopsies.¹³

Distichiasis, causing epiphora, chronic blepharospasm, and conjunctivitis, has been reported in a ferret.¹⁶ This ferret responded well to surgical treatment of the aberrant cilia with sharp excision of the hair follicle. Chronic ocular discomfort and discharge is an indication for close examination of the eyelid margins for abnormal hairs.

Corneal Disease

The structure of the ferret cornea is similar to other domestic species and is susceptible to corneal surface trauma. Congenital dermoid cysts have been reported in the ferret and have the classic appearance of haired skin on the corneal surface of the eye.¹⁷ Additionally, intraocular disease can result in corneal edema or scar and should be differentiated from corneal surface disease (**Fig. 4**).

The appearance and causes of corneal ulceration in the ferret are similar to other species. Early indications of corneal ulceration include an elevated third eyelid (**Fig. 5**) and corneal edema (**Fig. 6**). After identification of a corneal ulcer, care should

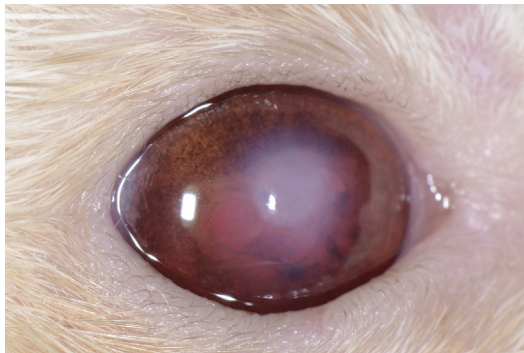


Fig. 4. Focal corneal opacity associated with previous uveitis damaging the corneal endothelium and causing focal scar. Note the irregularity of the iris tissue and dyscoria due to posterior synechia.

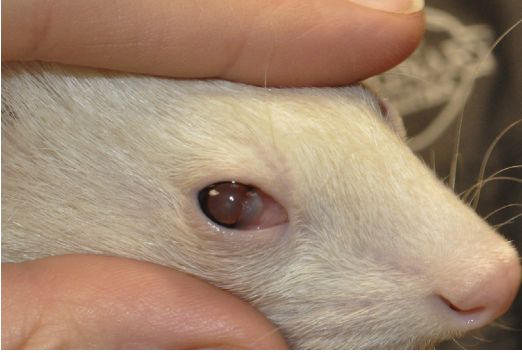

Fig. 5. Elevation of the nictitating membrane in a ferret with ophthalmic disease. (Courtesy of Christa Corbett, DVM, DACVO, Latham, NY.)

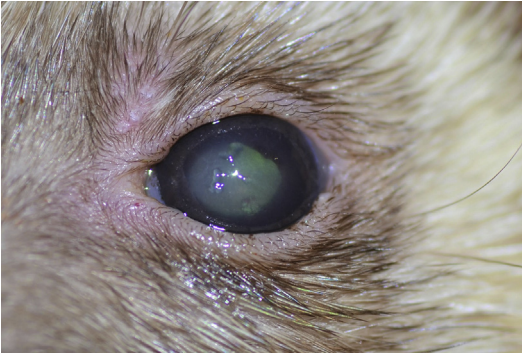


Fig. 6. Diffuse corneal edema and loose epithelium in a ferret with a superficial corneal ulceration. (Courtesy of Manuela Crasta, DECVO, Latham, NY.)

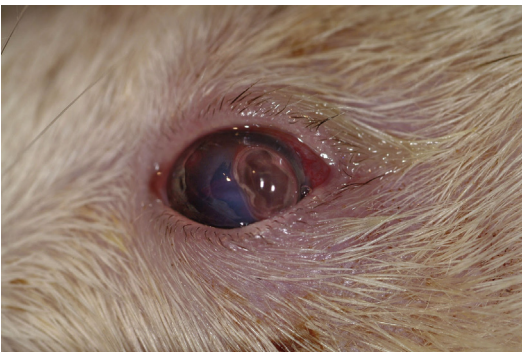


Fig. 7. Perforation of a malacic ulcer in a ferret. Note the protruding fibrin clot and probably iris prolapse temporally. (Courtesy of Manuela Crasta, DECVO, Latham, NY.)

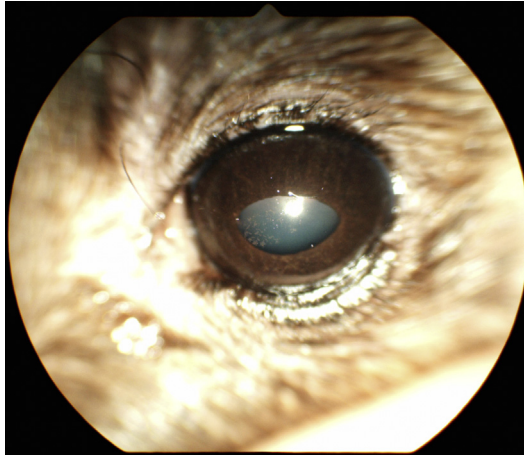


Fig. 8. Corneal pigmentation of unknown cause demonstrated by a spattered appearance of brown spots on the surface of the eye. Corneal pigmentation is typically the result of chronic corneal irritation. (Courtesy of Christa Corbett, DVM, DACVO, Latham, NY.)

be taken to ensure the eye is not exophthalmic given that exposure keratitis secondary to an orbital mass effect has been reported.¹⁸ Treatment of superficial corneal ulceration includes topical, broad-spectrum, antimicrobial agents. If the cornea appears infiltrated or has a hazy yellow or malacic appearance, cytologic evaluation and/or culture is indicated. Perforated eyes warrant systemic antimicrobial therapy in addition to topical antimicrobial therapy. A ruptured ulcer has a characteristic protrusion of fibrin or iris or both (Fig. 7). Healed ulcers may leave focal corneal scars that present as localized gray or white opacities. Additionally, the ferret cornea can pigment in a patient with pigmentary keratitis of unknown cause (Fig. 8).

Lymphoplasmacytic keratitis, an uncommon corneal disease, was reported in a 2-year-old ferret; it was ultimately associated with multicentric lymphoma.¹⁹ The keratitis was unresponsive to topical steroids and the animal did not show systemic signs of disease until 8 weeks after presentation. In a case of systemic coronavirus, the patient presented with lethargy, weight loss, pruritus, and a corneal opacity characterized by a yellow color.²⁰ The eye demonstrated signs of anterior uveitis in a fashion similar to cats with feline infectious peritonitis.²⁰

SUMMARY

Corneal surface disease in the ferret can be a symptom of significant systemic disease and requires a thorough ophthalmic examination to find the underlying cause of any lesions. An examination can be accomplished with a finoff transilluminator and magnification or appropriate use of the direct ophthalmoscope. Many conditions can be successfully managed if properly identified and treated.

REFERENCES

1. Dudás-Györki Z, Szabó Z, Manczur F, et al. Echocardiographic and electrocardiographic examination of clinically healthy, conscious ferrets. *J Small Anim Pract* 2011;52(1):18–25.
2. Di Girolamo N, Andreani V, Guandalini A, et al. Evaluation of intraocular pressure in conscious ferrets (*Mustela putorius furo*) by means of rebound tonometry and comparison with applanation tonometry. *Vet Rec* 2013;172(15):396.

3. van Zeeland YRA, Wilde A, Bosman IH, et al. Non-invasive blood pressure measurement in ferrets (*Mustela putorius furo*) using high definition oscillometry. *Vet J* 2017;228:53–62.
4. Montiani-Ferreira F, Mattos BC, Russ HHA. Reference values for selected ophthalmic diagnostic tests of the ferret (*Mustela putorius furo*). *Vet Ophthalmol* 2006;9(4):209–13.
5. Moody KD, Bowman TA, Lang CM. Laboratory management of the ferret for biomedical research. *Lab Anim Sci* 1985;35(3):272–9.
6. Perpignan D, Ramis A, Tomas A, et al. Outbreak of canine distemper in domestic ferrets (*Mustela putorius furo*). *Vet Rec* 2008;163(8):246–50.
7. Langlois I. Viral diseases of ferrets. *Vet Clin North Am Exot Anim Pract* 2005;8(1):139–60.
8. Deem SL, Spelman LH, Yates RA, et al. Canine distemper in terrestrial carnivores: a review. *J Zoo Wildl Med* 2000;31(4):441–51.
9. Marois P, Boudreault A, DiFranco E, et al. Response of ferrets and monkeys to intranasal infection with human, equine and avian influenza viruses. *Can J Comp Med* 1971;35(1):71–6.
10. Zitzow LA, Rowe T, Morken T, et al. Pathogenesis of avian influenza A (H5N1) viruses in ferrets. *J Virol* 2002;76(9):4420–9.
11. Gorham JR, Cordy DR, Quortrup ER. Salmonella infections in mink and ferrets. *Am J Vet Res* 1949;10(35):183–92.
12. Pignon C, Mayer J. Zoonoses of ferrets, hedgehogs, and sugar gliders. *Vet Clin North Am Exot Anim Pract* 2011;14(3):533–49.
13. Pollock C. Mycobacterial infection in the ferret. *Vet Clin North Am Exot Anim Pract* 2012;15(1):121–9, vii.
14. Mentré V, Bulliot C. A retrospective study of 17 cases of mycobacteriosis in domestic ferrets (*Mustela putorius furo*) between 2005 and 2013. *J Exotic Pet Med* 2015;24(3):340–9.
15. Nakata M, Miwa Y, Tsuboi M, et al. Mycobacteriosis in a domestic ferret (*Mustela putorius furo*). *J Vet Med Sci* 2014;76(5):705–9.
16. Verboven CAPM, Djajadiningrat-Laanen SC, Kitslaar W-JP, et al. Distichiasis in a ferret (*Mustela putorius furo*). *Vet Ophthalmol* 2014;17(4):290–3.
17. Ryland LM, Gorham JR. The ferret and its diseases. *J Am Vet Med Assoc* 1978;173(9):1154–8.
18. McBride M, Mosunic CB, Barron GHW, et al. Successful treatment of a retrobulbar adenocarcinoma in a ferret (*Mustela putorius furo*). *Vet Rec* 2009;165(7):206–8.
19. Ringle MJ, Lindley DM, Krohne SG. Lymphoplasmacytic keratitis in a ferret with lymphoma. *J Am Vet Med Assoc* 1993;203(5):670–2.
20. Lindemann DM, Eshar D, Schumacher LL, et al. Pyogranulomatous panophthalmitis with systemic coronavirus disease in a domestic ferret (*Mustela putorius furo*). *Vet Ophthalmol* 2016;19(2):167–71.