

Available online at [www.sciencedirect.com](http://www.sciencedirect.com)

ScienceDirect

journal homepage: [www.elsevier.com/locate/radcr](http://www.elsevier.com/locate/radcr)

## Case Report

# Gliomatosis cerebri mimicking diffuse demyelinating disease: Case Report ☆☆☆

Erli Mingomataj, MD<sup>a,\*</sup>, Aron Soleiman, BA<sup>b</sup>, Abin Sajan, BS<sup>b</sup>,  
Vinodkumar Velayudhan, DO<sup>a</sup>

<sup>a</sup> SUNY Downstate Health Sciences University, Department of Radiology, 450 Clarkson Avenue, Brooklyn, NY, 11203, USA

<sup>b</sup> SUNY Downstate Medical Center College of Medicine, Brooklyn, NY, USA

## ARTICLE INFO

## Article history:

Received 17 April 2020

Revised 20 June 2020

Accepted 21 June 2020

## Keywords:

Gliomatosis cerebri

Diffuse glioma

## ABSTRACT

Gliomatosis Cerebri (GC) is a rare and rapidly progressive pattern of growth of diffusely infiltrating gliomas with limited treatment options. Imaging findings are usually nonspecific and can mimic other neurologic disorders, including demyelination, encephalitis, and multicentric/multifocal glioma. In this report, we describe a case of a 53-year-old female who presented with left hemiparesis, global headache, and gait ataxia with imaging features initially thought to represent demyelinating disease. A combination of conventional and advanced imaging findings with brain biopsy was utilized to make the diagnosis of GC. In patients with widespread abnormalities on brain imaging, GC should strongly be considered when cortical expansion, involvement of the septum pellucidum and elevated myoinositol levels are observed and the clinical and laboratory findings are atypical for demyelination or infection. Considering GC in such cases can facilitate early biopsy with prompt diagnosis and avoid delay in appropriate treatment.

© 2020 The Authors. Published by Elsevier Inc. on behalf of University of Washington.

This is an open access article under the CC BY-NC-ND license.

(<http://creativecommons.org/licenses/by-nc-nd/4.0/>)

## Introduction

Gliomatosis Cerebri (GC) is a rare and universally fatal pattern of growth of diffusely infiltrating glioma [1]. Prognosis is poor, with a 14-month median survival time from diagnosis, despite aggressive treatment. Characteristic imaging findings include confluent areas of abnormal signal on magnetic resonance imaging (MRI) that enlarge affected structures and involve 3

or more lobes of the brain [1]. However, these imaging findings are nonspecific and can mimic several other pathologic processes, including demyelination, inflammatory diseases (such as encephalitis and vasculitis), and multifocal or multicentric glioma. Clinical findings in GC are also broad and non-specific with the most common presenting symptoms being seizures, altered mental status, headaches, and dementia. Definitive diagnosis can only be made with tissue biopsy, which demonstrates diffusely infiltrative neoplastic cells with preservation

☆ Conflicts of Interest: None.

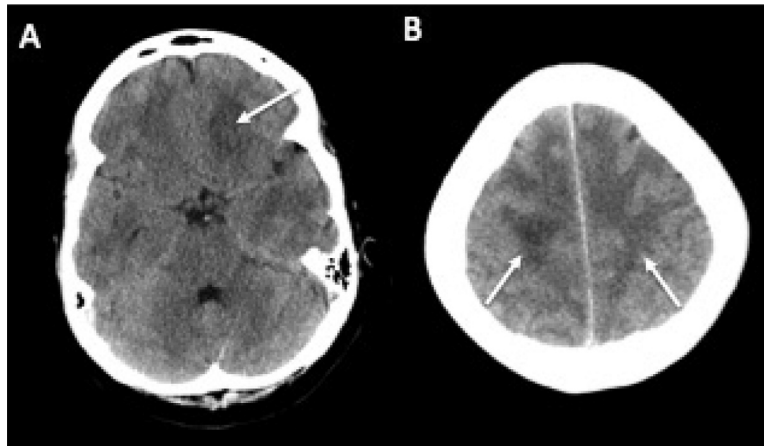
☆☆ This research did not receive any specific grant from funding agencies in the public, commercial, or not-for-profit sectors.

\* Corresponding author.

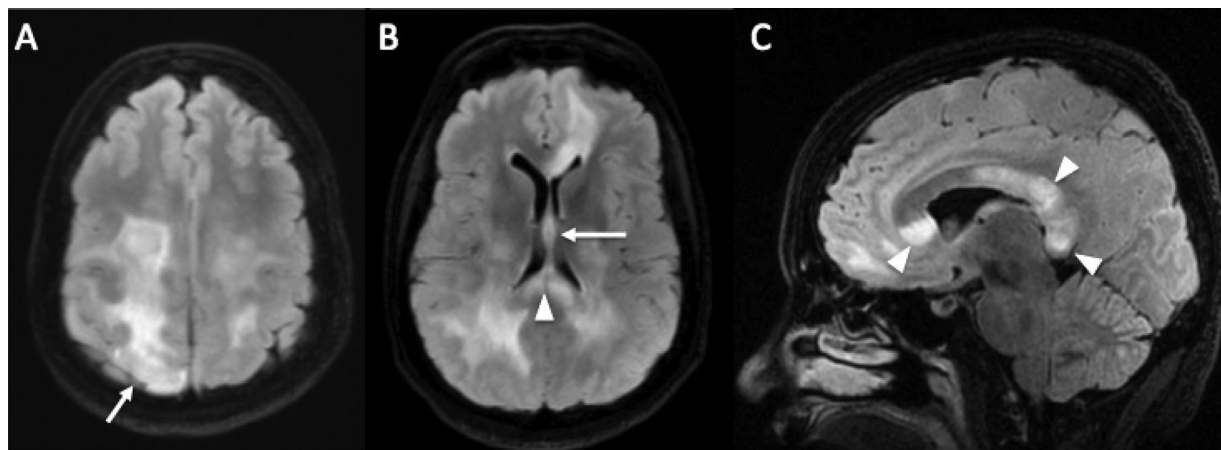
E-mail address: [erli.mingomataj@downstate.edu](mailto:erli.mingomataj@downstate.edu) (E. Mingomataj).

<https://doi.org/10.1016/j.radcr.2020.06.043>

1930-0433/© 2020 The Authors. Published by Elsevier Inc. on behalf of University of Washington. This is an open access article under the CC BY-NC-ND license. (<http://creativecommons.org/licenses/by-nc-nd/4.0/>)



**Fig. 1 – Non Contrast Axial CT images demonstrating areas of hypoattenuation centered in the white matter concerning for vasogenic edema in the frontal and parietal lobes (arrows).**



**Fig. 2 – Axial (A, B) and sagittal FLAIR (C) images showing increased signal of the left frontal and bilateral parietal lobes with extension into the overlying cortex (arrow, A) septum pellucidum and fornix (arrow, B), and corpus callosum (arrowhead B, C) with expansion of these structures.**

of underlying brain architecture [1]. While the differential diagnosis can be broad, GC can more confidently be suggested over demyelination and inflammatory processes when certain features on MRI, MR perfusion and spectroscopy are identified in the appropriate clinical setting.

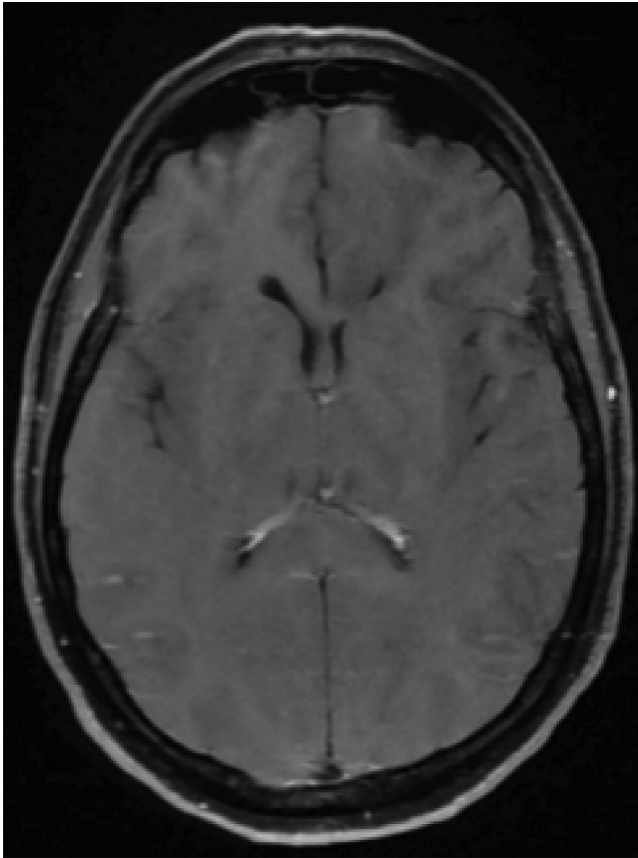
### Case report and imaging findings

A 53-year-old woman without significant past medical history presented to the emergency department with left-sided hemiparesis for 3 months accompanied by headache and ataxia. Complete hematologic workup was within normal limits during the hospital stay with the exception of an isolated episode of leukocytosis to 15.9, which resolved uneventfully. Lumbar puncture and multiple cerebrospinal fluid (CSF) studies were performed, all of which were negative, including cell count, protein, cytology, flow cytometry, myelin basic protein, oligo-

clonal bands, angiotensin-converting enzyme, herpes simplex virus and Epstein-Barr virus polymerase chain reaction (PCR), and titers for Lyme disease and venereal disease research laboratory.

Noncontrast computed tomography (CT) of the head on presentation (Fig. 1) demonstrated ill-defined areas of hypoattenuation in the right high parietal and left basal frontal white matter suspicious for vasogenic edema with generalized narrowing of the fissures and sulci. The basilar cisterns were patent with no midline shift or evidence of herniation. CT angiography of the head and neck revealed no stenosis, aneurysm, or vascular malformation.

Contrast enhanced MRI of the of the brain demonstrated multiple confluent areas of hyperintense signal on fluid attenuation inversion recovery (FLAIR) and T2-weighted images (T2WI) in the white matter of the frontal and parietal lobes bilaterally, the overlying right parietal and inferior left frontal lobe cortex and extension into the corpus callosum, septum pellucidum, and fornix with mild expansion of these



**Fig. 3 – Axial T1-weighted post contrast fat saturated image demonstrates no enhancement in the affected areas of the brain, including the areas of expansion.**

structures (Fig. 2). Abnormal FLAIR and T2 signal also extended along the corticospinal tracts into the internal capsules and brainstem bilaterally. Post contrast T1WI demonstrated no abnormal enhancement (Fig. 3). MRI of the whole spine revealed no associated cord lesions. Subsequent MR spectroscopy (Fig. 4) within an area of abnormal signal in the right high parietal deep white matter revealed elevated choline (Cho) and markedly increased myoinositol peaks, decreased N-Acetylaspartate (NAA) and significantly decreased NAA/Creatine (Cr) and NAA/Cho ratios of approximately 0.8 (normal NAA/Cr >1.6 and NAA/Cho > 1.2; Fig. 4).

The combination of neurocognitive deficits and extensive FLAIR hyperintensities in the cerebral white matter and corpus callosum initially suggested a demyelinating disease, such as multiple sclerosis and progressive multifocal leukoencephalopathy. Cortical involvement and expansion of affected structures in this case also raised the possibility of an encephalitis or primary brain tumor. Absence of leukocytosis, fever, HIV, or other immunocompromised status and normal serologic and CSF studies lowered the suspicion for MS, PML, and encephalitis. Diffusely infiltrating tumor was then thought to be the most likely diagnosis; lack of enhancement, markedly elevated myoinositol on MR spectroscopy and widespread involvement of the brain pointed towards GC or low grade multicentric or multifocal glioma. As such, neu-

rosurgery was consulted and performed a stereotactic brain biopsy of the left frontal lobe 3 weeks after initial presentation.

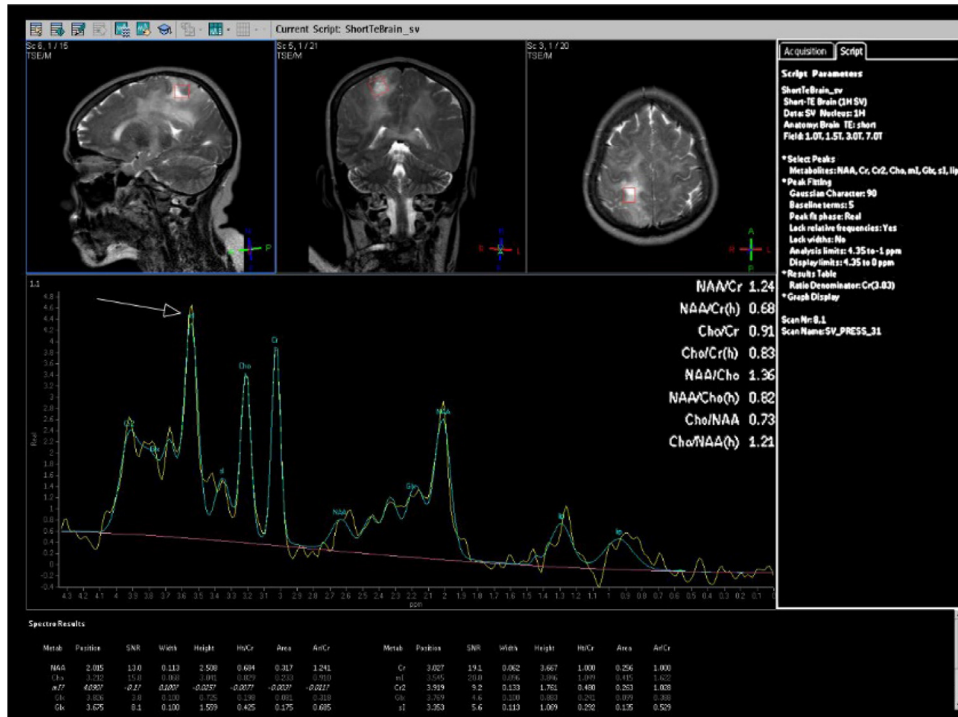
Histopathological studies revealed hypercellular white matter with infiltrating astroglial tumor cells that were diffusely immunopositive for glial fibrillary acidic protein. Genetic tumor assay was negative for isocitrate dehydrogenase type 1 and 2 mutations, and positive for missense mutation of phosphatidylinositol 3-kinase catalytic subunit (PIK3CA). The invading tumor cells exhibited minimal pleomorphism with no mitosis, vascular hyperplasia, or necrosis observed. The Ki-67 labeling index was lower than 5%. Tissue was noted to have preserved underlying cytoarchitecture despite tumor cell invasion. These histopathologic findings and genetic markers combined with the morphologic and MR spectroscopy features of our case were consistent with diffuse low-grade glioma (World Health Organization type II) exhibiting GC pattern of growth.

Radiation and medical oncology planned an outpatient treatment regimen consisting of whole brain radiation therapy with adjuvant procarbazine, lomustine, and vincristine. Unfortunately, the patient was lost to follow-up 1 month after diagnosis.

## Discussion and literature review

As per the World Health Organization, GC is classified as a type of growth pattern within the category of a diffuse glioma involving at least 3 contiguous lobes [1]. GC has conventionally been classified as either primary or secondary. Primary GC arises *de novo* and is further classified into 2 types; type I is a diffuse neoplastic growth without a clear solid tumor component, whereas type II includes an obvious tumor mass in addition to its diffuse component [2]. Secondary GC arises from malignant transformation of a previously diagnosed glioma and is associated with prior radiation or antiangiogenic therapy [2]. GC is a very rare entity with an overall annual incidence rate of 0.15 cases per million, and comprises roughly 1/400 of all glial tumors with a slight male predominance (M/F 1.4) [2]. Prognosis is poor, with a 1- and 5-year overall survival rate of 50% and 18%, respectively, and a median survival time of 14.5 months [3]. Negative prognostic factors include increasing age and rural residence, and positive prognostic factors include tumor location restricted within the cerebral hemispheres [2].

Clinically GC patients will often complain of a variety of symptoms due to the multiple structures affected. A large case series by Georgakis et al. of 1648 patients found that seizures, associated with temporal lobe involvement, were present in roughly half of all patients; headache, associated with increased ICP, in 36% of patients; cognitive decline, associated with wide spread disease, in 32%; focal motor deficits, associated with motor cortex involvement, in 32%; and gait abnormalities, associated with cerebellar involvement, in 15% [4]. Rare, but important, complaints include blurred vision due to tumor involving of the optic nerves and pathways, cranial nerve palsies via involvement of the brainstem, and atypical parkinsonian syndromes via involvement of the basal ganglia



**Fig. 4** – Single voxel MR spectroscopy using point resolved technique (PRESS) at TE of 31 evaluating the right parietal lobe demonstrates a markedly elevated myo-inositol peak (arrow) at approximately 3.5 ppm as well as altered choline (Cho), creatine (Cr), and N-Acetyl Aspartate (NAA) peaks.

[4,5]. The clinical exam findings and imaging/anatomical correlates of this case include left-sided weakness corresponding with involvement of the right paracentral lobule and corticospinal tract and global headache that was most likely related to increased ICP as evidence by diffuse effacement of the sulci and fissures.

The molecular changes associated with GC are still being described in the literature. While negative in our case, a mutated isocitrate dehydrogenase gene is associated with a more favorable prognosis in gliomas across all histologic grades and subtypes and has been found in roughly 50% of GC cases [6]. Molecular genetic analysis on our patient's biopsy showed a missense mutation of PIK3CA, which is associated with tumorigenesis and is seen in most solid human cancers and some overgrowth syndromes [7]. The Ki-67 labeling index, a marker of tumor proliferation that is elevated in high-grade gliomas, was lower than 5%, consistent with low-grade tumor [8]. The invading tumor cells also exhibited minimal pleomorphism with no mitosis, vascular hyperplasia, or necrosis (consistent with low-grade tumor). Underlying cytoarchitecture was preserved, a finding specific for GC that helps differentiate it from multicentric and multifocal glioma.

MRI is the best imaging modality to demonstrate GC due to its greater contrast resolution and ability to more conspicuously depict the specific degree of anatomic involvement. GC typically appears iso- to hypointense on T1-weighted imaging (T1WI), hyperintense on FLAIR and T2WI, and results in expansion of involved structures with absent or minimal enhancement [9]. Areas of enhancement are suspicious for ei-

ther foci of high-grade glioma or malignant progression when seen on follow-up studies. Bilateral hemispheric involvement is seen in 65% of patients, infratentorial infiltration in 30% of patients, and corpus callosum involvement is found in roughly half of patients [9].

Regarding the combination of a patient's clinical presentation and neuroimaging results, the differential diagnosis of GC can be broad. Neurocognitive deficits in conjunction with widespread T2 hyperintensities in the cerebral white matter can be seen in many diseases in addition to GC, including demyelinating diseases (eg, progressive multifocal leukoencephalopathy [PML], multiple sclerosis [MS]), or acute disseminated encephalomyelitis [ADEM]), cerebral vasculitis and leukodystrophies [2]. Further, the differential diagnosis of a lesion involving the white matter, corpus callosum and brainstem includes tumors (ie, infiltrating glioma or lymphoma) in addition to demyelination. Several pertinent negative clinical and laboratory features of this case pointed against an encephalitis or PML, including lack of a fever or leukocytosis, lack of HIV or other cause for an immunocompromised state and normal CSF and serologic studies.

Our case demonstrated several morphologic features on MRI favoring GC and tumor in general. While diffuse nonenhancing white matter changes and involvement of the corpus callosum can be seen in both glioma and demyelination, the presence of lesions extending to the cortex with parenchymal expansion as seen in our case (Fig. 2) is more typical of tumor rather than demyelination. Confluent cortical involvement suggests tumor over tumefactive demyelination



[10]. Conversely, MS is well known to involve the cortex and cause cognitive impairment, though cortical lesions in MS, whether focal or diffuse, typically result in atrophy rather than expansion [11] and are best seen on double inversion recovery sequences [12]. Tumefactive demyelination could also result in the expansile white matter lesions seen in our case, but typically demonstrates enhancement that often has an incomplete rim-like appearance (the “open ring sign”) without significant cortical involvement [11]; no enhancement was seen in our case despite the degree of abnormal signal and parenchymal expansion. Additionally, the involvement of the septum pellucidum and fornix with expansion seen in our patient is also highly suggestive of intra axial tumor [13].

MR spectroscopy can also aid diagnosis, grading, and biopsy planning of GC. Brain metabolites commonly evaluated on MR spectroscopy include NAA, choline, and creatine. NAA is a marker of neuronal integrity and is decreased in diseases that adversely affect the brain. Choline is a cell membrane marker and is increased in processes that result in increased cell turnover, including tumor, subacute infarction, or inflammatory diseases. Creatine provides a measure of energy stores. Myoinositol is a molecule found in astrocytes that functions as an osmolyte, is involved in the protein kinase C pathway and is elevated in low grade glial tumors and demyelination, especially PML [14]. MR spectroscopy results are commonly analyzed using concentrations of metabolites as well as ratios, such as NAA/Cr, NAA/Cho, and Cho/Cr. GC patients almost uniformly have decreased NAA/Cho and NAA/Cr ratios and commonly have elevated Cho/Cr ratio within areas of hyperintensity on FLAIR and T2WI [15]. MR spectroscopy of our patient (Fig. 4) demonstrated expected decreased NAA/Cho and NAA/Cr ratios of approximately 0.8. Myoinositol was found to be significantly elevated corresponding to diffuse low-grade tumor. Cho/Cr ratio was not found to be elevated at 1.04 (normally <1.5), though the combination of normal Cho/Cr ratio and elevated myoinositol seen in our case has previously been reported in cases of low grade gliomas and specifically in GC [16]. High lipid/lactate peaks on MR spectroscopy are observed in areas of necrosis in high-grade tumors and associated with a poorer prognosis; these peaks were not observed on our patient [17].

MR perfusion (MRP) imaging may be useful in differentiating high grade gliomas and lymphoma from tumefactive demyelinating lesions [18]. However, MRP is less useful in differentiating GC from demyelination as both usually demonstrate low relative cerebral blood volume due to relative lack of vascular angiogenesis [19,20] unless areas of areas of higher grade tumor are present.

Treatment options for GC are poor with no standard trial-based recommendation for the initiation of therapy. Many institutions treat patients the same as a high-grade glioma patient with upfront radiation or chemo-radiation [9]. However, radiation therapy has shown no overall survival benefit on several trials [3,21]. There is also discussion surrounding the efficacy of the chemotherapeutic approach. NOA-5, the only prospective clinical trial published evaluating primary chemotherapy's efficacy in GC showed that initial treatment with procarbazine and lomustine may confer clinical benefit in patients with GC according to the NOA-5 trial [22].

## Conclusion

GC is a rare and universally fatal pattern of growth of diffuse gliomas with clinical and imaging findings that are nonspecific and can mimic several other more common conditions, such as demyelination (including MS, PML, and ADEM) and encephalitis, which may result in delay in diagnosis and improper treatment. Several features observed in our case may suggest the diagnosis of GC over demyelination, including diffuse expansion of affected structures without significant enhancement, cortical involvement with expansion and involvement of the septum pellucidum and fornix. Furthermore, a normal or elevated Cho/Cr ratio with increased myoinositol concentration on MR spectroscopy is suggestive of low-grade glioma and GC when suspicious findings are also seen on conventional MRI. Although prognosis is poor and GC is universally fatal there is evidence that treatment confers some short-term survival benefit. It is important, therefore, to include GC in the differential diagnosis in cases of widespread infiltrating brain lesions when the clinical features are atypical or unexpected for more common diseases, and to consider early brain biopsy in those cases.

## REFERENCES

- [1] Louis D, Perry A, Reifenberger G, Deimling A, Figarella-Bragner D, Cavenee W, et al. The 2016 World Health Organization classification of tumors of the central nervous system: a summary. *Acta Neuropathol* 2016;131(6):803–20.
- [2] Herrlinger U. Gliomatosis cerebri. *Handb Clin Neurol* 2012;105:507–15.
- [3] Taillibert S, Chodkiewicz C, Laigle-Donadey F, Napolitano M, Cartalat-Carel S, Sanson M, et al. Gliomatosis cerebri: a review of 296 cases from the ANOCEF database and the literature. *J Neurooncol* 2006;76(2):201–5.
- [4] Georgakis M, Spinos D, Pourtsidis A, Psyrris A, Panourias I, Sgouros S, et al. Incidence and survival of gliomatosis cerebri: a population-based cancer registration study. *J Neurooncol* 2018;138(2):341–9.
- [5] Greenfield J, Castaneda Hereida A, George E, Kieran M, Morales La Madrid A. Gliomatosis cerebri: a consensus summary report from the First International Gliomatosis cerebri Group Meeting, March 26–27, 2015, Paris, France. *Pediatr Blood Cancer* 2016;63(12):2072–7.
- [6] Desestret V, Cicciarino P, Ducray F, Criniere E, Boisselier B, Labussiere M, et al. Prognostic stratification of gliomatosis cerebri by IDH1 R132H and INA expression. *J Neurooncol* 2011;105(2):219–24.
- [7] Madsen RR, Vanhaesebroeck B, Semple RK. Cancer-associated PIK3CA mutations in overgrowth disorders. *Trends Mol Med* 2018;24(10):856–70.
- [8] Thotakura M, Tirumalasetti N, Krishna R. Role of Ki-67 labeling index as an adjunct to the histopathological diagnosis and grading of astrocytomas. *J Cancer Res Ther* 2014;10(3):641–5.
- [9] Georgakis M, Tsvigoulis G, Spinos D, Dimitriou N, Kyritsis A, Herrlinger U, et al. Clinical, neuroimaging and histopathological features of gliomatosis cerebri: a systematic review based on synthesis of published individual patient data. *J Neurooncol* 2018;140(2):467–75.

- [10] Kim DS, Na DG, Kim KH, Kim JH, Kim E, Yun B, et al. Distinguishing tumefactive demyelination lesions from glioma or central nervous system lymphoma: added value of unenhanced CT compared with conventional contrast-enhanced MR imaging. *Radiology* 2009;251(2):467–75.
- [11] Calabrese M, Rinaldi F, Mattisi I, Grossi P, Favaretto A, Atzori M, et al. Widespread cortical thinning characterizes patients with MS with mild cognitive impairment. *Neurology* 2010;74(4):321–8.
- [12] Geurts JGG, Pouwels P, Uitdehaag B, Polman C, Barkhof F, Castelijns J, et al. Intracortical lesions in Multiple Sclerosis: improved detections with 3D double inversion-recover MR imaging. *Neuroradiology* 2005;236-1.
- [13] Russell EJ, Naidich TP. The enhancing septal/alveolar wedge: a septal sign of intraaxial mass. *Neuroradiology* 23(1), 22-40.
- [14] Teresi LM. *A practicing radiologists guide to MR spectroscopy of the brain*. Xlibris Corporation 2007.
- [15] Bendszus M, Warmouth-Metz M, Rudiger K, Burger R, Schichor C, Ton J, et al. MR spectroscopy in gliomatosis cerebri. *AJNR Am J Neuroradiol* 2000;21(2):375–80.
- [16] Saraf-Lavi E, Bowen B, Pattany P, Sklar E, Murdoch J, Petito C. Proton MR spectroscopy of gliomatosis cerebri: case report of elevated myoinositol with normal choline levels. *AJNR Am J Neuroradiol* 2003;24(5):946–51.
- [17] Castillo M, Smith JK, Kwock L. Correlation of myo-inositol levels and grading of cerebral astrocytomas. *AJNR Am. J. Neuroradiol.* 2000;21(9):1645–9.
- [18] Yang S, Wetzel S, Law M, Zagzag D, Cha S. Dynamic contrast-enhanced T2\*-weighted MR imaging of gliomatosis cerebri. *AJNR Am J Neuroradiol* 2002;23(3):350–5.
- [19] Sanchez P, Meca-Lallana V, Barbosa A, Menzhanes R, Palmi I, Vivancos J. Tumefactive demyelinating lesions of 15 patients: clinico radiological features, management and review of literature. *J Neurol Sci* 2017;381:32–8.
- [20] Cha S, Pierce S, Knopp E, Johnson G, Yang C, Ton A. Dynamic contrast-enhanced T2\*- weighted MR imaging of tumefactive demyelinating lesions. *AJNR Am J Neuroradiol* 2001;22:1109–16 Medline.
- [21] Chen S, Tanaka S, Giannini C, Morris J, Yan E, Buckner J, et al. Gliomatosis cerebri: clinical characteristics, management, and outcomes. *J Neurooncol* 2013;112(2):267–75.
- [22] Glas M, Bahr O, Felsberg J, Rasch K, Wiewrodt D, Schabet M, et al. NOA-05 phase 2 trial of procarbazine and lomustine therapy in gliomatosis cerebri. *Ann Neurol* 2011;70(3):445–53.