

Standard Article

J Vet Intern Med 2017;31:1469–1476**Diagnostic Utility of Wireless Video-Electroencephalography in Unsedated Dogs**F.M.K. James , M.A. Cortez, G. Monteith, T.S. Jokinen, S. Sanders, F. Wielaender, A. Fischer, and H. Lohi

Background: Poor agreement between observers on whether an unusual event is a seizure drives the need for a specific diagnostic tool provided by video-electroencephalography (video-EEG) in human pediatric epileptology.

Objective: That successful classification of events would be positively associated with increasing EEG recording length and higher event frequency reported before video-EEG evaluation; that a novel wireless video-EEG technique would clarify whether unusual behavioral events were seizures in unsedated dogs.

Animals: Eighty-one client-owned dogs of various breeds undergoing investigation of unusual behavioral events at 4 institutions.

Methods: Retrospective case series: evaluation of wireless video-EEG recordings in unsedated dogs performed at 4 institutions.

Results: Electroencephalography achieved/excluded diagnosis of epilepsy in 58 dogs (72%); 25 dogs confirmed with epileptic seizures based on ictal/interictal epileptiform discharges, and 33 dogs with no EEG abnormalities associated with their target events. As reported frequency of the target events decreased (annually, monthly, weekly, daily, hourly, minutes, seconds), EEG was less likely to achieve diagnosis ($P < 0.001$). Every increase in event frequency increased the odds of achieving diagnosis by 2.315 (95% confidence interval: 1.36–4.34). EEG recording length (mean = 3.69 hours, range: 0.17–22.5) was not associated ($P = 0.2$) with the likelihood of achieving a diagnosis.

Conclusions and Clinical Importance: Wireless video-EEG in unsedated dogs had a high success for diagnosis of unusual behavioral events. This technique offered a reliable clinical tool to investigate the epileptic origin of behavioral events in dogs.

Key words: Electroencephalography; Epilepsy; Wireless video-electroencephalography.

Despite being the most common chronic neurologic disease in dogs, there have been few advances in the diagnosis of canine epilepsy.^{1,2} Current recommendations are to establish whether the behavioral event is truly a seizure before attempting to identify the

Abbreviations:

EEG electroencephalography

From the Department of Clinical Studies, Ontario Veterinary College, University of Guelph, Guelph, ON, Canada (James, Monteith); Division of Neurology, Department of Paediatrics, Faculty of Medicine, University of Toronto, Toronto, ON, Canada (Cortez); Department of Equine and Small Animal Medicine, University of Helsinki, Helsinki, Finland (Jokinen); Seattle Veterinary Specialists, Seattle, WA (Sanders); Clinic of Small Animal Medicine, Ludwig-Maximilians Universität München, Munich, Germany (Wielaender, Fischer); Department of Veterinary Biosciences and Research Programs Unit, Molecular Neurology, University of Helsinki, Helsinki, Finland (Lohi); and the Folkhälsan Research Centre, Helsinki, Finland (Lohi).

Data were collected at the Ontario Veterinary College, University of Guelph, Canada, the University of Helsinki, Finland, Ludwig-Maximilians Universität München, Germany, and Seattle Veterinary Specialists, USA.

A portion of these data comprised a research report presentation, “Canine Awake Ambulatory Wireless Video Electroencephalography,” at the 2014 ACVIM Forum in Nashville, Tennessee.

Corresponding author: F.M.K. James, Department of Clinical Studies, Ontario Veterinary College, University of Guelph, Guelph ON N1G 2W1, Canada; e-mail: jamesf@uoguelph.ca.

Submitted October 24, 2016; Revised April 27, 2017; Accepted June 22, 2017.

Copyright © 2017 The Authors. *Journal of Veterinary Internal Medicine* published by Wiley Periodicals, Inc. on behalf of the American College of Veterinary Internal Medicine.

This is an open access article under the terms of the Creative Commons Attribution-NonCommercial License, which permits use, distribution and reproduction in any medium, provided the original work is properly cited and is not used for commercial purposes.

DOI: 10.1111/jvim.14789

underlying cause.² These diagnostic criteria comprise many subjective clinical observations or decisions based on the owner-derived history or video, or both, of an event, a process with low interobserver agreement.³

An electroclinical syndrome is a distinctive recognizable clinical disorder identifiable by its clinical features, signs, and specific pattern on electroencephalography (EEG).⁴ These electroclinical syndromes are important in human epilepsy due to their being a focus of etiological and therapeutic investigation. There are few such defined syndromes in veterinary epilepsy, likely because of historic impracticality of using EEG because of technical challenges and the lack of standardization.^{2,5–8} Human pediatric epileptology faced many of the same challenges. However, advances in technology have allowed the addition of synchronized video to the EEG, resulting in improved diagnosis of behavioral events in children.^{9,10}

The objective of this study was to investigate the utility of a novel wireless video-EEG protocol in unsedated dogs that is similar to that used for children for the diagnosis of behavioral events. We expected that diagnostic success would parallel that found in human pediatric epileptology. We defined diagnostic success as: (1) the presence of epileptiform activity during or between behavioral events, or (2) a behavioral event with normal associated EEG suggesting that these events were not seizures. Diagnostic success was predicated upon the acquisition of clinically interpretable,

good quality, video-EEG permitting assessment; if the recording was unreadable, it was considered unsuccessful. We hypothesized that diagnostic success would be positively associated with increasing length of video-EEG recording and higher/increased frequency of reported behavioral events (those events occurring before the video-EEG recording).

Materials and Methods

Medical records were retrieved from participating institutions for dogs that underwent EEG recording. Institutions were the Ontario Veterinary College (OVC) at the University of Guelph, the University of Helsinki (UH), Seattle Veterinary Specialists, and Ludwig-Maximilians-Universität München (LMU Munich). All video-EEG recordings had been obtained with client consent to investigate whether the dog was experiencing seizures. Recordings were selected where a specific unsedated wireless video-EEG recording protocol (as described below) was used. If the dog had received sedation or general anesthesia prior, the recording had to extend beyond clinical recovery or extent of pharmaceutical influence to include a period of unsedated mentation. Signalment, prior sedation, anticonvulsive medications, and the frequency of events occurring before instrumentation for the video-EEG recording (historic event frequency) were noted from the history.

Video-EEG recordings were performed with a wireless video-EEG machine.^a The video camera was kept positioned such that as much of the dog as possible was visible, ideally with the face closest to the camera. The wireless transmitter/amplifier box was attached to the dog via a body harness “backpack” or placed in close proximity to the dog, either adjacent to it if nonambulatory/confined to a small crate, or held by the handler (controlling the dog via a leash and collar). The leads that connected the scalp electrodes to the transmitter/amplifier box were fastened to the neck in a tension loop with nonadhesive bandage. Scalp electrodes were either subdermal wire electrodes (at the OVC) or needle electrodes (at all other recording locations). Electrodes were fastened to the scalp with sticky bandage, with or without additional nonadhesive bandage to hold the leads in place. Occasional dogs were provided an Elizabethan collar as needed to minimize interference with the equipment once instrumented.

Recordings were performed initially in a quiet environment for most dogs. If neither the dog’s handler nor clinical staff stayed with the dog for the duration of the recording, then the dog was checked every 4 hours throughout the night, and the video camera repositioned if necessary, while the dog was confined in a crate or playpen. After a period of baseline recording, any known triggers of the behavioral events reported by the owners were presented to the dog. The only other activation technique employed was to record video-EEG during natural drowsiness or sleep—this was not interrupted if it occurred spontaneously during the recording period.

Recordings were terminated either when the dog removed the equipment spontaneously, or after the target event(s) had occurred, or after a predetermined clinically indicated period of time, for example, after the event of interest had occurred or after 24-hour hospitalization for seizure monitoring. All recordings were digitally saved for later review although the equipment did allow live recording monitoring for clinical observation (performed in a subset of dogs).

Electrode placement expanded upon a previously described protocol, adding up to five more electrodes to increase coverage of the cortex (Figs 1, 2, Table 1).¹¹ Nomenclature of electrodes was consistent with that used for the human EEG 10-20 system, with odd numbers denoting left side electrodes and even numbers for right side electrodes.¹² Routine electrodes included reference (R),

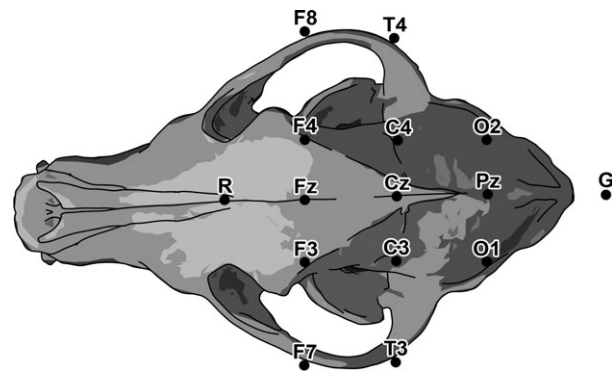


Fig 1. Electrode placement map illustrated on a dorsal view of a canine skull (see also Table 1).

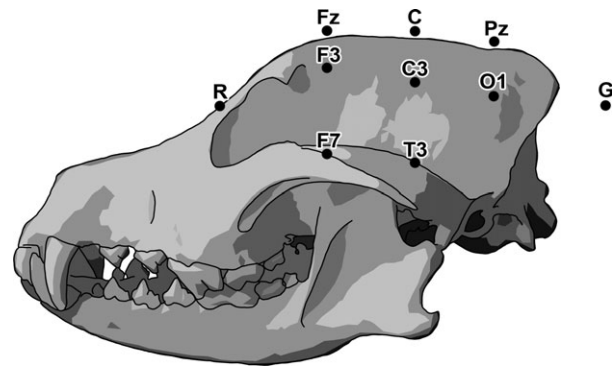


Fig 2. Electrode placement map illustrated on a lateral view of a canine skull (see also Table 1).

Table 1. Electrode placement protocol.

Ref	Midline, between medial canthi
Grd	Dorsal midline neck, 2–5 cm caudal to occipital protuberance
F7/F8	Zygomatic arch just caudal to the lateral canthus of both eyes
F3/F4/Fz	On the temporal lines caudal to the medial canthi and at midline
C3/C4/Cz	Halfway between F and O/P electrodes, in line with T electrodes
O1/O2/Pz	Transverse line between mastoid processes in line with F electrodes
T3/T4	Zygomatic arch, just rostral to the pinnal edge

ground (G), midline (Fz, Cz, Pz), frontal electrodes (F3/F4, F7/F8), central electrodes (C3/C4), temporal electrodes (T3/T4), and occipital electrodes (O1/O2). Some dogs also had electrocardiogram (ECG) electrodes placed. Not all dogs received the full complement of 15 electrodes due to head size, clinical circumstances, and development of the electrode placement protocol (earlier cases did not routinely include all of the midline electrodes, F7/8 or ECG). During instrumentation, impedances were checked, and the electrodes were adjusted to keep them below 30 kOhms.^b

Technical review settings included a notch filter at 50 or 60 Hz (as appropriate for European or North American recordings respectively and only applied if necessary), 0.1–1 Hz low-frequency filter, and 35 or 70 Hz high-frequency filter as needed. The 35 Hz

high-frequency filter was applied when needed to reduce artifact from muscle potentials (i.e., masticatory muscle activity). Analysis was accomplished by medical grade review software.^c Remontaging between bipolar and referential recordings was performed post-hoc as necessary. Epileptiform activity such as spikes and sharp waves, as well as focal abnormalities of the background (e.g., trains of slow waves) was registered and compared against the video recording to determine whether there was any associated ictal semiology. As well, the video recording was reviewed for occurrences of the target behavioral events, and the associated EEG recording was inspected for abnormalities. Event frequency was derived from the medical record history before onset of video-EEG recording and categorized as recurring within seconds (i.e., the behavior had essentially become continuous), within minutes (recurring within 10 minutes), hourly, daily, weekly, monthly, and annually. These were assigned values of 1 through 7, respectively, with 1 corresponding to the highest event frequency, based on the medical record history. Artifacts (both physiological and nonphysiological) were excluded through comparison of video and EEG recordings and through review of the recording in various montages.

Simple descriptive statistics were performed on the study population signalment, anticonvulsants, and recording length, sedation requirement, and findings (ictal/interictal/behavioral). An exact logistic regression was used to determine whether recording duration or frequency of historic events predicted diagnostic success, calculating an odds ratio.^d Significance was set at $P \leq 0.05$. The EEG result was categorized as having achieved a diagnosis (categorical variable, assigned value = 1) if the EEG review: (1) confirmed epileptiform seizures by detecting either ictal or interictal epileptiform discharges that established the epileptic nature of the events, or (2) confirmed no abnormal discharges during the visible behavioral event verifying the nonepileptiform nature of the behavioral event. The EEG result, on the other hand, was categorized as unsuccessful/nondiagnostic (categorical variable, assigned value = 0) if no behavioral target episodes were seen during the video recording, and no epileptiform discharges were detected in the EEG recording or if the recording was unreadable (too much artifact). Analysis of EEG recordings was initially completed by FJ and later reviewed by MAC (who was blinded to the clinical history). If the interpretations were discordant, the consensus diagnosis was recorded after discussion.

Results

Eighty-one dogs met the inclusion criteria from all 4 institutions, with recordings included from 2013 through 2016. There were 7 Rhodesian Ridgebacks, 6 American Staffordshire Terriers, 5 each of Golden Retrievers, German Shepherd Dogs and mixed breed dogs, 4 Bull Terriers, 3 each of Border Collies and English Bulldogs, 2 each of Cavalier King Charles Spaniels, Great Danes, Jack Russell Terriers, Labrador Retrievers, Pitbulls, Pugs, and Rottweilers, and 1 each of: Alaskan Klee Kai, American Bulldog, American Cocker Spaniel, Australian Shepherd, Australian Terrier, Border Terrier, Boxer, Cane Corso, Chinese Crested Hairless, Dachshund, Dalmatian, Doberman Pinscher, Field Spaniel, Finnish Spitz, French Bulldog, German Short-haired Pointer, Havanese, Husky, Irish Setter, Karelian Bear Dog, Kromfohrlander, Lapponian Herder, Miniature Pinscher, Miniature Schnauzer, Parson Terrier, Pomeranian, Shetland Sheepdog, Standard Poodle, and Vizsla. There were 46 males (27 neutered) and 35 females (24 spayed). Median age was 4 years, with a

mean age of 5.42 years (range: 0.25–15 years) (Table S1). The clinical question for all dogs undergoing video-EEG was “are these seizures?” The events were described as combinations of: tonic-clonic seizures, head bobbing or tremors, focal twitching/myoclonus/spasticity (face, ears, head, neck, limbs), altered mentation (trance, staring, absences, excitement, vocalization, awakenings), chasing/holding of visible or invisible stimuli (lights, shadows, tail, “flies,” objects), proprioceptive ataxia, and gastrointestinal upset (Table S1). Triggers presented were sensory stimuli including objects (like a specific food bowl or training dummy), lights (bright lights or sudden sunshine or laser pointers), shadows (flickering sunlight or moving shadows), sounds (rattling dishes/tinfoil or sudden sounds), or touch (brushing of the dorsum). As only few dogs presented each type of event or trigger, we were unable to assess whether certain events or triggers were more likely to result in an EEG diagnosis.

Electrode placement and EEG recording were performed without any chemical or physical restraint in the majority of dogs (69%). Three dogs (4%) were sedated for electrode placement and not reversed but with recording continuing beyond clinical recovery to an awake state (normal activity confirmed on the synchronized video recording). Seventeen dogs (21%) were sedated for electrode placement with subsequent reversal. Sedatives included: dexmedetomidine (10–20 $\mu\text{g}/\text{kg}$) and subsequent reversal with atipamezole (10–20 $\mu\text{g}/\text{kg}$), butorphanol (0.1 mg/kg), and acepromazine (0.1 mg/kg). For 4 dogs (4.9%), electrodes were placed while under general anesthesia for other diagnostic testing, with recording proceeding once they had recovered. Thirty-five (43%) dogs were recorded while receiving single, or combinations of, anticonvulsant drugs: phenobarbital (1.01–6.5 mg/kg), zonisamide (6–14 mg/kg), levetiracetam—including extended release (14.5–65.6 mg/kg), topiramate (4.3–11.8 mg/kg), imepitoin (7.5–22.2 mg/kg), diazepam (≤ 1 mg/kg), and primidone (18.3 mg/kg). The small numbers of dogs receiving each drug or combination of drugs meant that it was not possible to assess for an effect of anticonvulsant drugs on diagnostic success.

All video-EEG recordings were of interpretable quality despite frequent muscle artifact and occasional movement artifact. The median EEG recording duration was 1.5 hours with a mean duration of 3.69 hours (range: 0.17–22.5 hours). Target behavioral events were captured on EEG recordings in 49 of 81 dogs (61%). EEG achieved diagnosis in 58 of 81 cases (72%). Of these 58 dogs, 25 were diagnosed as having epileptiform seizures, based on finding either ictal (18 dogs) or interictal (7 dogs) epileptiform discharges on the EEG recording. These types of epileptiform discharges included spike or sharp waves, spike-and-slow waves, or runs of any of these that stood above and disrupted the background activity (e.g., Figs 3, 4). In 9 of the 25 diagnoses, the epileptiform discharges were not accompanied by paroxysmal behavior visible on video. There were 33 cases with transient behavioral events that showed no associated epileptiform discharges during the events in question and during the remainder of the

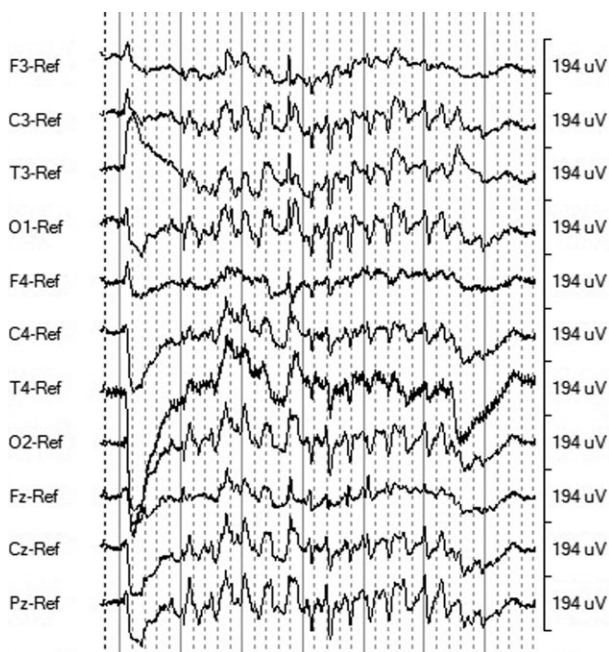


Fig 3. Example of an ictal EEG finding. A 13-year-old female spayed Cavalier King Charles Spaniel presenting for head twitching and staring episodes occurring almost every waking hour. Referential montage shows 3 Hz spike-wave activity lasting approximately 5 seconds with head and eyelid myoclonic jerks time-locked to the spikes. This is bracketed by normal saccadic eye movements (the large opposing deviations from baseline). There is mild muscle artifact on T4-Ref. Sampling rate: 200 Hz. Paper speed: 30 s/page. Sensitivity: 20 μ V. High-frequency filter: 70 Hz. Low-frequency filter: 1 Hz. Horizontal scale: 1 s/solid line, 200 ms/dashed line. Vertical scale: 194 μ V/division.

EEG recording (e.g., Fig. 5). The video-EEG recording was nondiagnostic in 23 of 81 cases. These video-EEG recordings were inconclusive because the event of interest did not occur, and both the video and EEG traces were unremarkable. As frequency of events decreased, video-EEG was less likely to achieve a diagnosis ($P < 0.001$, Fig. 6). For every unit increase in frequency (months to weeks to days to hours, etc.), there were increased odds for successful video-EEG diagnosis of 2.315 (95% confidence interval: 1.36–4.34). The length of video-EEG recording was not associated with the likelihood of achieving a diagnosis ($P = 0.2$).

Discussion

The interobserver agreement for determining the nature of video-recorded transient behavioral events in dogs and cats is relatively low.³ This supports the growing consensus on the need for diagnostic tools, such as video-EEG, to differentiate epileptic versus nonepileptic behavioral paroxysms, particularly the absolute necessity of the simultaneous observation of both characteristic EEG changes and the actual behavioral event to distinguish the two.^{2,3,13,14} Video-EEG technology has advanced to include small portable wireless video-synchronized systems, originally designed to increase ease of recording in people and particularly children, and

that can be used in dogs.¹⁵ Routine 20–40 minute video-EEG studies in human pediatric epileptology are helpful in 45% of cases examined for frequent behavioral events.⁹ Besides helping to establish the diagnosis of a human pediatric epileptic syndrome, video-EEG also aids in excluding the approximately 20% of children with nonepileptic transient behavioral events.¹⁶ In human adults, video-EEG shows a 58% success rate.¹⁷

This study provides the first description of the diagnostic success of wireless video-EEG in unsedated dogs displaying transient paroxysmal behavioral events. The results of this study indicated that the solution to diagnosing canine transient paroxysmal behavioral events is the use of unsedated wireless video-EEG recording. Ambulatory wireless video-EEG in unsedated dogs with these events achieved diagnostic success in 72% of cases with a mean recording time of 3.69 hours and with greater success in capturing more frequent events, as expected. Preliminary data from this cohort of dogs indicate that the diagnostic success was supported by results of subsequent treatment with anticonvulsive medications and repeat video-EEG (data not shown, currently under analysis).

By comparison, the diagnostic success of EEG recordings in sedated or anesthetized epileptic dogs ranges from 20% to 86%, although the high end of the range is an outlier (Table 2).^{18–21} Comparison with previous reports is complicated by the lack of standardized protocols and differences in inclusion criteria. Previous veterinary studies examined dogs with an unequivocal clinical diagnosis of epilepsy based on a combination of semiology and etiology, whereas this study population comprised the broader category of behavioral events of unknown etiology and focused on both the diagnosis and the exclusion of the epileptic origin of the events. Furthermore, the video-EEG recordings in this study were not stratified by the etiological classification of the epilepsy. That is, not all of the dogs in this study had normal neurologic or physical examinations nor underwent full clinical investigation that included blood work, advanced imaging (magnetic resonance imaging or computed tomography of the head), or cerebrospinal fluid analysis, nor necessarily received a final diagnosis. This study focused on the investigation of the utility of unsedated video-EEG for the practical clinical question: *is it an epileptic seizure?*

In this study, interictal epileptiform activity was used to confirm the epileptic nature of transient paroxysmal behavioral events in addition to ictal recordings. Technically, only ictal EEG (18/58 successful EEG diagnoses in this study) can confirm the epileptiform nature of a clinical event. On the other hand, it is known from the human literature that the specificity of interictal epileptiform abnormalities on EEG is high in adults but could be lower in children, with up to 9% of normal children exhibiting epileptiform activity on EEG.^{22,23} This study did not have sufficient numbers to stratify analysis by age.

The length of video-EEG recording did not predict diagnostic success as we had hypothesized, a prediction based on the variable interevent frequencies

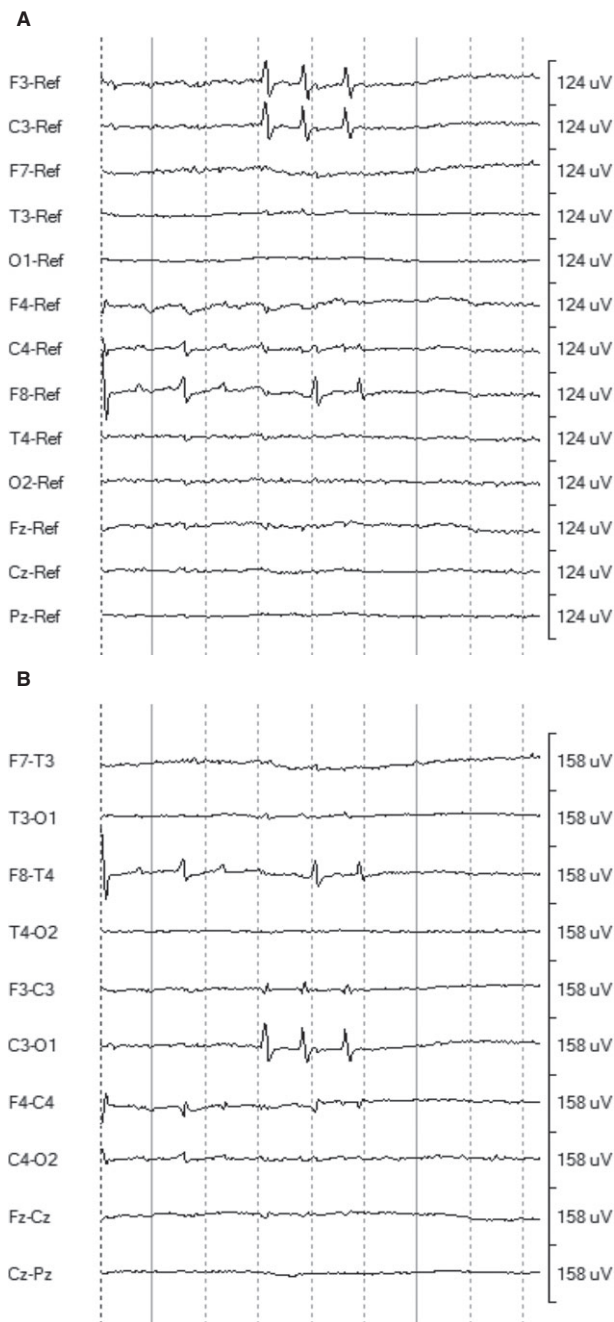


Fig 4. Examples of an interictal EEG finding. A 7-year-old female spayed pitbull terrier presenting for episodic ataxia, sleep abnormalities, and possible seizures occurring daily. (A) Referential montage shows multifocal independent interictal spikes over F3/C3 and F8/C4 during drowsiness with no behavioral/motor correlates. (B) Bipolar montage of the same epoch. Sampling rate: 200 Hz. Paper speed: 5 s/page. Sensitivity: 7 μ V. High-frequency filter: 70 Hz. Low-frequency filter: 1 Hz. Horizontal scale: 1 s/solid line, 200 ms/dashed line. Vertical scale: 124 μ V/division (A) and 158 μ V/division (B).

encountered clinically. This could be because interictal epileptiform activity was identified or that EEG success could be dependent upon other factors, such as length of time since last event, medications received,

skull shape, or masticatory muscle depth. Further study would be required to investigate these factors. In the veterinary EEG literature, length of recording is not always specified, and time since last event is rarely noted. However, routine recording times historically ranged from 20 to 45 minutes (Table 2).^{18,24} A previous study observed that video-EEG could be recorded up to 8 hours after instrumentation in an unsedated dog with minimal physiological artifact accruing.¹¹

The only activation technique that was used deliberately in this study was the presentation of sensory stimuli known to trigger a dog's target behavioral events.¹⁵ Additionally, natural sleep was not interfered with if it occurred during recording. Activation techniques are stimuli that provoke epileptic potentials on the EEG and clinical seizures.²⁵ Examples from human epileptology include natural sleep, sleep deprivation, withdrawal of anti-epileptic medication(s), photic stimulation, and hyperventilation.^{26,27} In veterinary epileptology, photic stimulation and hyperventilation have been reported under propofol anesthesia, especially as the latter technique is only possible if the dog is under general anesthesia with control of airway and respiratory rate.^{19,28} It remains to be explored in veterinary epileptology as to which activation techniques work best for which types of epilepsy, as is known in human epileptology.^{25–27,29}

Veterinary epileptology also lacks a standard electrode positioning protocol similar to the 10–20 system used in human epileptology. Several proposals have been made for standard electrode positioning in veterinary epileptology.^{7,14,30} These proposals have still to be replicated and validated, a process beyond the scope of the present study. In the past, the lack of a standardized electrode positioning protocol and the frequent use of different types of sedation throughout the recording in veterinary epileptology seriously compromised the comparison of findings between patients, clinics, and reports in the literature. This limited the recognition of focal or generalized discharges, the identification of the epileptogenic zone, and the definition of electroclinical syndromes on the basis of characteristic EEG findings. EEG is critical to these concepts, especially to locating the epileptogenic zone. Originally defined as the “area of cortex necessary and sufficient for initiating seizures and whose removal (or disconnection) is necessary for complete abolition of seizures,” for future surgical purposes, a more simplified definition of the epileptogenic zone is the “minimum amount of cortex that must be resected (inactivated or completely disconnected) to produce seizure freedom”.^{14,31,32} This study brings together 81 video-EEGs performed at multiple centers with the same electrode placement map and, for the first time, minimizes the interference of sedatives or anesthetics on findings by recording in unsedated dogs.

The main weakness of scalp EEG is that recordings can be unremarkable in truly epileptic individuals. These false-negative findings could be variously due to weak voltage of the cortical source, smallness of the area of involved cortex, the source being deep to the

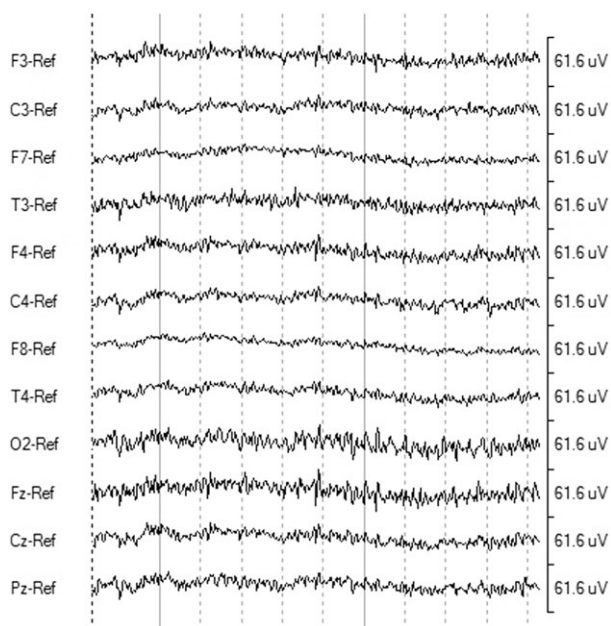


Fig 5. Example of a behavioral EEG finding. An 11-year-old intact female Bull Terrier presenting with daily trance episodes, often triggered by gentle touch. Unremarkable referential montage while dog is frozen in place showing -30 to $34 \mu\text{V}$ activity with dominant frequencies ranging 17 to 25 Hz. Sampling rate: 200 Hz. Paper speed: 8 s/page. Sensitivity: $7 \mu\text{V}$. High-frequency filter: 70 Hz. Low-frequency filter: 1 Hz. Horizontal scale: 1 s/solid line, 200 ms/dashed line. Vertical scale: $61.6 \mu\text{V}/\text{division}$.

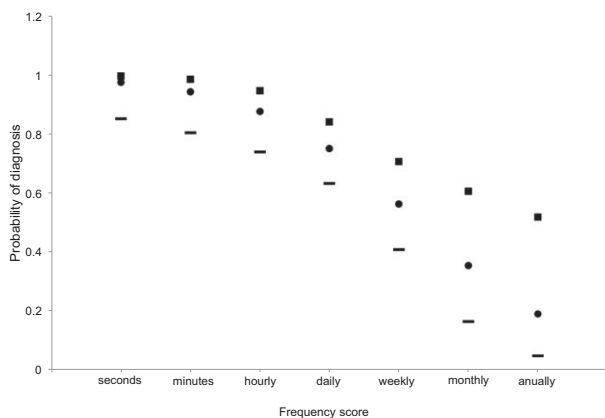


Fig 6. Odds of successful diagnosis by frequency of events (circles). Squares: upper 95% confidence interval. Dashes: lower 95% confidence interval.

cortex (such as a thalamic source), or poor synchronization of the involved neuronal population.³³ In the present study, 33 cases recorded visible behavioral events without associated epileptiform discharges on EEG during the events or the remainder of the recording. These cases were counted as successful recordings due to the capture of the events of interest, but an unknown number could have been misclassified as nonepileptic as a result of the apparently unremarkable EEG. Likewise, an unknown number of the 23 inconclusive cases (with unremarkable video-EEG recordings) could have been

misclassified. Until we establish strong correlations between the semiology and the EEG findings for epilepsies in dogs, comparable to the human epilepsies, an estimate of this error is not possible.

Another limitation of the present study's recording technique is that it does not produce artifact-free recordings. The main artifacts that were observed were due to muscle (electromyographic), eye, ear, oral, facial, and whole body movement. Topical application of lidocaine is not helpful in reducing muscle artifact.³⁴ Once clinical seizures are apparent, the EEG recording can be obscured by movement artifact. On the ideal recording, EEG events would become apparent and evolve before the clinical signs. However, the recording quality with the present study's technique is sufficient for clinical interpretation. This technique successfully characterized a generalized absence seizure syndrome with myoclonic jerks in the Rhodesian Ridgeback breed and in a Chihuahua (the latter was unsedated but not wireless).^{35,36} Despite the electromyographic contamination of the background rhythms, the generalized 4 Hz spike-and-wave ictal pattern was easily recognized.

The Chihuahua case example would be hard to classify under the seizure definition based solely on clinical semiology that was recently proposed by the International Veterinary Epilepsy Task Force, but is reminiscent of the situation in children in which absence seizures may remain unrecognized unless EEG is recorded.^{4,5} As with historical and ongoing efforts to classify human epilepsies, these proposals are a work in progress. It is acknowledged that EEG would assist in defining focal versus generalized seizures as this is challenging on video or description alone.^{2,3,5} For humans, decades of video-EEG have allowed improvement in the reliability of semiology for localizing seizure onset.³⁷

Other improvements in veterinary epileptology will follow with more common clinical use of EEG in the future. Consensus on standardized veterinary EEG protocols will allow the definition of veterinary electroclinical epileptic syndromes, with associated updates to terminology and classification. Such definitions will benefit etiological investigations based on stricter phenotyping of the epileptic population. Advances in technology will support the development of long-term ambulatory (video-)EEG, where an instrumented dog is recorded in its home environment, similar to the cardiologist's Holter monitor. Stratification of therapeutic trials by the type of epilepsy might improve outcomes and prognosis.

This study provides a description of the high diagnostic success of a novel wireless video-EEG technique in unsedated dogs presenting with behavioral events when investigating the question, "is it an epileptic seizure?" Diagnostic success appeared better than that reported in human pediatric epileptology by a similar technique. Diagnostic success was positively associated with higher frequency of the events documented in medical records, but not with increasing length of video-EEG recording. Clinicians should consider video-EEG recording for diagnosis in unsedated dogs presenting with behavioral events of unknown etiology.

Table 2. Recently reported diagnostic yield of veterinary EEG.

Reference	Inclusion Criteria	Dogs	Main Recording Method	Mean Duration (min)	Success (%)
Berendt et al. ¹⁸	Recurrent epileptic seizures (not inflammatory or extracranial)	23	Sedation (acepromazine + pethidine)	30–45	65
Brauer et al. ¹⁹	Idiopathic and symptomatic epilepsy	89	General anesthesia (propofol + rocuronium bromide)	Not stated	26
Jaggy et al. ²⁰	Idiopathic epilepsy	37	General anesthesia (medetomidine + propofol)	25	86
Jeserevics et al. ²¹	Epileptic seizures + Finnish Spitz	15	Sedation (medetomidine)	20	20
This study	Transient paroxysmal events	81	Unsedated	221	72

Min, minutes.

Footnotes

^a Trackit MK3 EEG/Polygraphy Recorder with Video, Lifelines Neurodiagnostic Systems, Inc., Troy, IL.

^b When the Trackit was first obtained, impedances were compared with the OVC's previous Stellate Harmonie machine (Natus Medical Inc., Pleasanton, CA), by switching the electrode plugs from one machine's jackbox to the other. It was found that where the Harmonie reported impedances below 5 k Ω , the Trackit reported the same electrodes as below 30 k Ω . Therefore, tolerances were increased for the Trackit. These data are unpublished.

^c Persyst 12, Persyst Development Corporation, San Diego, CA.

^d SAS 9.3, SAS Institute Inc., Cary, NC.

Acknowledgments

Lotta K. Koskinen, Katriina Tiira, Petra Jaakonsaari, and Eija Seppälä are thanked for their assistance with the selection of dogs for recording. Alasdair James is thanked for his assistance with the preparation of the figures.

Grant support: Equipment grant from the Canada Foundation for Innovation and Ontario Ministry of Research and Innovation (30953) (FJ). Travel grant from the Munich University Society (AF). Research grants from the Jane and Aatos Erkkö Foundation, ERCStG (260997), ERA-Net Neuron and the Academy of Finland (HL).

Conflict of Interest Declaration: Authors declare no conflict of interest.

Off-label Antimicrobial Declaration: Authors declare no off-label use of antimicrobials.

References

- Chandler KE. Canine epilepsy: What can we learn from human seizure disorders? *Vet J* 2006;172:207–217.
- De Risio L, Bhatti S, Muñana KR, et al. International veterinary epilepsy task force consensus proposal: Diagnostic approach to epilepsy in dogs. *BMC Vet Res* 2015;11:148.
- Packer RMA, Berendt M, Bhatti S, et al. Inter-observer agreement of canine and feline paroxysmal event semiology and classification by veterinary neurology specialists and non-specialists. *BMC Vet Res* 2015;11:39.

4. Berg AT, Berkovic SF, Brodie MJ, et al. Revised terminology and concepts for organization of seizures and epilepsies: Report of the ILAE Commission on Classification and Terminology, 2005-2009. *Epilepsia* 2010;51:676–685.

5. Berendt M, Farquhar RG, Mandigers PJJ, et al. International veterinary epilepsy task force consensus report on epilepsy definition, classification and terminology in companion animals. *BMC Vet Res* 2015;11:182.

6. Steiss JE. A survey of current techniques in veterinary electrodiagnostics: EEG, spinal evoked and brainstem auditory evoked potential recording. *Vet Res Commun* 1988;12:281–288.

7. Redding RW. A simple technique for obtaining an electroencephalogram of the dog. *Am J Vet Res* 1964;65:854–861.

8. Fox MW. Postnatal development of the EEG in the dog. I. Introduction and EEG techniques. *J Small Anim Pract* 1967;8:71–76.

9. Watemberg N, Tziperman B, Dabby R, et al. Adding video recording increases the diagnostic yield of routine electroencephalograms in children with frequent paroxysmal events. *Epilepsia* 2005;46:716–719.

10. Watemberg N, Lerman-Sagie T, Kramer U. Diagnostic yield of electroencephalograms in infants and young children with frequent paroxysmal eye movements. *J Child Neurol* 2008;23:620–623.

11. James FMK, Allen DG, Bersenas AME, et al. Investigation of the use of three electroencephalographic electrodes for long-term electroencephalographic recording in awake and sedated dogs. *Am J Vet Res* 2011;72:384–390.

12. Jasper HH. The ten twenty electrode system of the international federation. *Electroencephalogr Clin Neurophysiol* 1957;10:371–375.

13. Uriarte A, Maestro Saiz I. Canine versus human epilepsy: Are we up to date? *J Small Anim Pract* 2016;57:115–121.

14. Hasegawa D. Diagnostic techniques to detect the epileptogenic zone: Pathophysiological and presurgical analysis of epilepsy in dogs and cats. *Vet J* 2016;215:64–75.

15. Schomer DL. Ambulatory EEG telemetry: How good is it? *J Clin Neurophysiol* 2006;23:294–305.

16. Nordli DR. Usefulness of video-EEG monitoring. *Epilepsia* 2006;47(Suppl 1):26–30.

17. McGonigal A. Use of short term video EEG in the diagnosis of attack disorders. *J Neurol Neurosurg Psychiatr* 2004;75:771–772.

18. Berendt M, Høgenhaven H, Flagstad A, Dam M. Electroencephalography in dogs with epilepsy: Similarities between human and canine findings. *Acta Neurol Scand* 1999;99:276–283.

19. Brauer C, Kästner SBR, Rohn K, et al. Electroencephalographic recordings in dogs suffering from idiopathic and symptomatic epilepsy: Diagnostic value of interictal short time EEG protocols supplemented by two activation techniques. *Vet J* 2012;193:185–192.

20. Jaggy A, Bernardini M. Idiopathic epilepsy in 125 dogs: A long-term study. Clinical and electroencephalographic findings. *J Small Anim Pract* 1998;39:23–29.
21. Jeserevics J, Viitmaa R, Cizinauskas S, et al. Electroencephalography findings in healthy and Finnish Spitz dogs with epilepsy: Visual and background quantitative analysis. *J Vet Intern Med* 2007;21:1299–1306.
22. Renzel R, Baumann CR, Poryazova R. EEG after sleep deprivation is a sensitive tool in the first diagnosis of idiopathic generalized but not focal epilepsy. *Clin Neurophysiol* 2016;127:209–213.
23. Holmes GL. Epilepsy in children. In: Samuels MA, Feske SK, eds. *Office Practice of Neurology*, 2nd ed. Philadelphia, PA: Elsevier Science; 2003:923–928.
24. Holliday TA, Williams DC. Interictal paroxysmal discharges in the electroencephalograms of epileptic dogs. *Clin Tech Small Anim Pract* 1998;13:132–143.
25. Abubakr A, Ifeayni I, Wambacq I. The efficacy of routine hyperventilation for seizure activation during prolonged video-electroencephalography monitoring. *J Clin Neurosci* 2010;17:1503–1505.
26. Velis D, Plouin P, Gotman J, et al. Recommendations regarding the requirements and applications for long-term recordings in epilepsy. *Epilepsia* 2007;48:379–384.
27. Mendez OE, Brenner RP. Increasing the yield of EEG. *J Clin Neurophysiol* 2006;23:282–293.
28. Brauer C, Kästner SBR, Schenk HC, et al. Electroencephalographic recordings in dogs: Prevention of muscle artifacts and evaluation of two activation techniques in healthy individuals. *Res Vet Sci* 2011;90:306–311.
29. Holmes MD, Dewaraja AS, Vanhatalo S. Does hyperventilation elicit epileptic seizures? *Epilepsia* 2004;45:618–620.
30. Pellegrino F, Sica R. Canine electroencephalographic recording technique: Findings in normal and epileptic dogs. *Clin Neurophysiol* 2004;115:477–487.
31. Lüders HO, Engel J, Munari C. General principles. In: Engel Jr J, *Surgical Treatment of the Epilepsies*, 2nd ed. New York, NY: Raven Press; 1993:137–153.
32. Lüders HO, Najm I, Nair D, et al. The epileptogenic zone: General principles. *Epileptic Disord* 2006;8(Suppl 2):S1–S9.
33. Alarcon G, Guy CN, Binnie CD, et al. Intracerebral propagation of interictal activity in partial epilepsy: Implications for source localisation. *J Neurol Neurosurg Psychiatr* 1994;57:435–449.
34. Ward J, James FMK, Monteith G. The effect of topical lidocaine on muscle artefacts in awake canine electroencephalogram recordings. *Vet J* 2016;213(C):6–8.
35. Wielander F, Sarviaho R, James FMK, et al. Generalized myoclonic epilepsy with photosensitivity in juvenile dogs caused by a defective DIRAS family GTPase 1. *Proc Natl Acad Sci USA* 2017;114:2669–2674.
36. Poma R, Ochi A, Cortez MA. Absence seizures with myoclonic features in a juvenile Chihuahua dog. *Epileptic Disord* 2010;12:138–141.
37. So EL. Value and limitations of seizure semiology in localizing seizure onset. *J Clin Neurophysiol* 2006;23:353–357.

Supporting Information

Additional Supporting Information may be found online in the supporting information tab for this article:

Table S1. Summary table of study data, including signalment, presenting complaint, EEG findings, and medications.