

# Comparative Evaluation of Efficacy between Recombinant Human Bone Morphogenetic Protein-2 Impregnated with Absorbable Sponge and Platelet-Rich Fibrin in the Treatment of Grade II Furcation Defects: A Randomized Controlled Trial

## Abstract

**Aim and Objectives:** The objective of the study was to clinically and radiographically compare and evaluate the regenerative potential of recombinant human bone morphogenetic protein-2 (RhBMP-2) impregnated with absorbable collagen sponge and platelet-rich fibrin (PRF) in the treatment of Grade II furcation defects. **Patients and Methods:** Thirty-two subjects were randomly assigned to each of the following groups: bone morphogenetic protein (BMP) group and PRF group, with one defect/subject. Sixteen Grade II furcation defects were treated with RhBMP-2 impregnated with absorbable collagen sponge in the BMP group and the remaining 16 defects were treated with PRF in the PRF group. Clinical and radiographic parameters which were evaluated at baseline, postoperative 1 week, 3 months, and 6 months were probing pocket depth, clinical attachment level, scoring of plaque index, and gingival index, and the bone fill was evaluated using Digital Subtraction technique and morphometric area analysis with ImageJ® software. **Results:** RhBMP-2 in absorbable collagen sponge was effective in increasing the bone fill in Grade II furcation defects when compared to PRF alone ( $P = 0.05$ ). In relation to clinical parameters, both the groups showed no statistical significance between them. **Conclusion:** The unique regenerative potential of RhBMP-2 impregnated with absorbable collagen sponge makes it a potential agent to be used as a graft material for the treatment of Grade II furcation defects.

**Keywords:** Absorbable sponge, Grade II furcation, platelet-rich fibrin, recombinant human bone morphogenetic protein-2

## Introduction

The furcation area of a molar represents a unique periodontal site with specific anatomic and pathogenic characteristics and important clinical and therapeutic implications.<sup>[1]</sup> The unique morphology of the root complex in the furcal region of multirooted teeth favors the progression of destructive periodontitis lesions when the furcation entrance is reached by the subgingival biofilm and the resulting chronic inflammation. Along with horizontal progression of attachment loss, the pocket has a lateral extension toward the interior of the furcation, as well as a vertical extension along the root.<sup>[1]</sup>

Furcation involvement is, therefore, a risk factor for the progression of further attachment loss, and at the same time, its

complex anatomic morphology makes it difficult, if not impossible, to debride this area properly during routine periodontal instrumentation, thus reducing the efficacy of periodontal therapy.<sup>[2]</sup> According to the literature, molars are more at risk for loss than other teeth, reason being furcation involvement.<sup>[2-4]</sup>

Multiple approaches have been used to resolve furcation defect including autografts, demineralized freeze-dried bone allografts, xenografts, barrier membranes, and combinations of membranes and bone grafts. However, they had their set of drawbacks and showed heterogeneous results in case of Grade II and III furcations.<sup>[5]</sup> Although these regenerative materials are still being used today, the introduction of biomimetic agents such as enamel matrix derivatives, platelet-rich

**Kidambi Sneha,  
Kacharla Sowjanya,  
Varanasi Vaishnavi,  
Rampalli Viswa  
Chandra**

*Department of Periodontology,  
Sri Venkata Sai Institute of  
Dental Sciences, Mahabubnagar,  
Telangana, India*

**Submitted :** 19-Sep-2020  
**Revised :** 01-Oct-2020  
**Accepted :** 31-Oct-2020  
**Published :** 21-Dec-2021

*Address for correspondence:  
Dr. Kidambi Sneha,  
Department of Periodontology,  
Sri Venkata Sai Institute of  
Dental Sciences, Appanapally,  
Mahabubnagar - 509 001,  
Telangana, India.  
E-mail: kidambi.sneha@gmail.  
com*

### Access this article online

**Website:**  
[www.contempclindent.org](http://www.contempclindent.org)

**DOI:** 10.4103/ccd.ccd\_828\_20

### Quick Response Code:



**How to cite this article:** Sneha K, Sowjanya K, Vaishnavi V, Chandra RV. Comparative evaluation of efficacy between recombinant human bone morphogenetic protein-2 impregnated with absorbable sponge and platelet-rich fibrin in the treatment of Grade II furcation defects: A randomized controlled trial. *Contemp Clin Dent* 2021;12:419-25.

This is an open access journal, and articles are distributed under the terms of the Creative Commons Attribution-NonCommercial-ShareAlike 4.0 License, which allows others to remix, tweak, and build upon the work non-commercially, as long as appropriate credit is given and the new creations are licensed under the identical terms.

For reprints contact: WKHLRPMedknow\_reprints@wolterskluwer.com

fibrin (PRF), several growth factor (GF) applications, and bone morphogenetic proteins have given a new promise for better outcomes in furcation treatment.<sup>[5,6]</sup>

As furcation defects are noncontained defects to an extent, the use of biologicals has an important limitation, that is, because of their liquid or gel-like consistency, any space-making effect is prevented and therefore the regenerative potential of such materials may be limited in furcation lesions. Hence, there is always a need for the introduction of newer materials for the resolution of furcation defects with increased predictability.<sup>[7]</sup>

Specific bone formation substances are needed to activate the nonspecific mesenchymal tissue with the aid of a scaffold.<sup>[8]</sup> Bone morphogenetic proteins (BMPs) are members of the transforming GF- $\beta$  superfamily of polypeptides. Among the BMP family members, BMP-2 has been shown to stimulate osteogenic differentiation of mesenchymal progenitor cells. They stimulate angiogenesis and also aid in the migration, proliferation, and differentiation of the cells of the mesenchyme into chondroblasts and osteoblasts. Regeneration of new periodontal tissues was reported at a concentration of 1.5 mg/cc.<sup>[9]</sup>

Although recombinant human bone morphogenetic protein-2 (RhBMP-2) by itself was shown to be sufficient to induce bone, the osteoinductive potency of RhBMP-2 is significantly increased when implanted within a biomaterial carrier. The carrier can provide a three-dimensional scaffold for osteogenic cell infiltration and transformation with a localized and controlled release of the GF and can define a volume for newly formed mineralized tissue. The RhBMP-2 allied with a collagen foam carrier in intrabony defects (IBDs) in dogs has proven an increase in the rate of bone formation without side effects such as ankylosis or apical bone resorption.<sup>[10,11]</sup>

It is well established that PRF contains soluble GFs that not only stimulate tissue healing but also aid in bone regeneration. When platelets in fibrin matrix are activated, GFs release and stimulate the mitogenic response in the bone periosteum during normal wound healing for repair of the bone.<sup>[12]</sup>

The aim of the present study is to compare the efficacy of RhBMP-2 in absorbable sponge with a proven material, that is, PRF in Grade II furcation defects in terms of radiographic bone fill, clinical attachment level (CAL), and probing pocket depth (PPD). Grade II furcation defects have been chosen for the testing of regenerative materials as they contained defects and have a chance of complete defect fill, which, in turn, addresses the efficacy and regenerative potential of the material used (RhBMP-2).

## Patients and Methods

### Sample size calculation

proportional power calculation, used to determine the sample size, revealed that a minimum of 16 subjects/group

at a power level of 0.80 and a significance level of 0.05 were required to discern a clinical difference of 1 mm at standard deviation (SD) of 0.1 mm between the two groups.

### Trial design, participants, and eligibility criteria

The study was designed as a single-blind, randomized controlled clinical trial wherein the regenerative potential of RhBMP-2 and PRF was evaluated in Grade II furcations clinically and radiographically.

Thirty-two subjects were selected (16/group) from the outpatient section of the Department of Periodontology, SVSIDS, Mahabubnagar, Telangana. Systemically healthy male and female patients of the age group of 20–55 years, with Grade II furcation involvement and PPD of  $\geq 5$  mm after initial therapy, were included in the study. Medically compromised patients, subjects who underwent radiotherapy or chemotherapy in the past 12 months, patients having uncontrolled periodontal disease, and current smokers were excluded from the study.

### Interventions

#### *Standardization of vertical probing depth and horizontal probing depth*

Vertical probing depth (VPD) was recorded using UNC-15 color-coded periodontal probe and acrylic stent, and horizontal probing depth (HPD) was recorded with Nabers probe at baseline and at the end of 3 and 6 months. An alginate impression was taken, and custom acrylic stent limited to the occlusal 2/3 of the clinical crown was used as a fixed reference position (i.e., junction of vertical groove and lower border of the stent). A groove was prepared in the stent at the site of interest to standardize the probing angulation when recording the parameters.

#### *Presurgical protocol*

All the patients underwent Phase-I therapy, which included scaling and root planing (SRP), occlusal adjustment, and oral hygiene instructions. Based on the outcomes obtained after the Phase 1 therapy, surgery was planned after 1 month.

#### *Preparation of recombinant human bone morphogenetic protein-2 in absorbable sponge*

20  $\mu\text{g}$  of lyophilized Human Bone Morphogenetic Protein-2 (ACRO<sup>®</sup> Biosystems, Beijing, China) was reconstituted in sterile 100  $\mu\text{g}/\text{ml}$  20 mM acetic acid. 1  $\mu\text{g}/\text{ml}$  mixture was made by dissolving the reconstituted mixture into 1 ml of 10 mM Na-butyrate solution (Pro Lab Marketing<sup>®</sup> Pvt Ltd, New Delhi, India). 5 batches of 1  $\mu\text{g}/\text{ml}$  RhBMP-2 were prepared at a time and were stored at  $-20^{\circ}\text{C}$  for up to 48 h. Subsequently, 5 ml of the solution was dissolved in a solvent mixture (ethanol: propylene glycol: water in the ratio of 50:30:20). Triethanolamine was added to adjust the pH to above 7.4. The solution was prepared to a concentration of approximately 0.5  $\mu\text{g}/\text{ml}$ . The collagen

sponge is impregnated with RhBMP-2 at a concentration of 0.5 µg/ml/1 cm<sup>3</sup> and was stored at 4°C.<sup>[10,12]</sup> This RhBMP-2 impregnated with collagen sponge was then dispensed at the site of interest in the study.

#### *Preparation of platelet-rich fibrin*

For the preparation of PRF, patient's venous blood is collected into 10 ml glass tube or glass-coated plastic tube and centrifuged at 2700 rpm for 12 min, which leads to two different layers in the test tube: the upper PRF and the lower RBC portion. The formed PRF clot could then be removed from the glass tube and compressed into a membrane-like layer and used as required in the defects.<sup>[11]</sup>

#### *Surgical phase*

After the administration of local anesthesia, a full-thickness mucoperiosteal flap was elevated and the defect site was degranulated with curettes and irrigated thoroughly. RhBMP-2 impregnated with absorbable collagen sponge material was placed in the furcation defect in the BMP group (test group). Similar surgical procedure was performed in the PRF group (control group), where PRF was placed and stabilized in the defect. The flaps were then approximated with 3-0 silk sutures [Figure 1]. Then, the periodontal pack was placed over the site. Suture removal was done 10 days after the surgery.

#### **Outcomes**

##### *Digital subtraction technique and morphometric area analysis*

The radiograph obtained at 3 and 6 months was subtracted from the radiograph taken at the baseline using commercially available image processing software (Adobe Photoshop® 6.0, Adobe Systems, San Jose, USA). To reduce the brightness and contrast variations, both the images were adjusted based on the levels and the curves

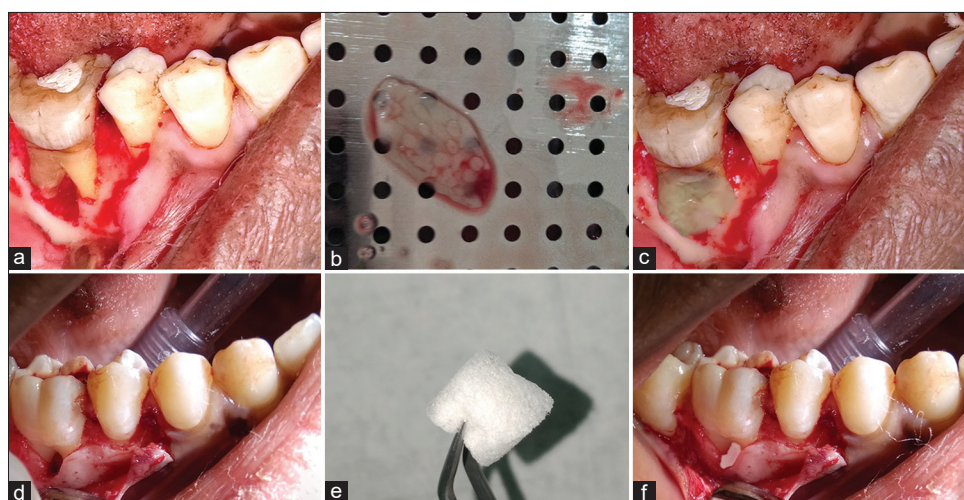
in the software. Before digital subtraction, both the radiographs were moved in appropriate directions as needed to reduce geometric distortion. These images were then superimposed and subtracted by selecting the image > calculation > exclusion > new channel tools. The excluded residual bone height was outlined using the polygonal lasso tool, and the layer was copied and saved as a separate Joint Photographic Expert Group document at low compression.<sup>[13]</sup>

After digital subtraction, the digitized and excluded residual bone height was transferred to open source software for area calculation (ImageJ®, Research Services Branch, NIH, Bethesda, Maryland, USA) for area calculation. The layer was converted into a grayscale image, and the measurement scale was set to account for any magnification/reduction of the radiograph because of the radiovisiography. The area of the layer was calculated (in mm<sup>2</sup>) by initially enclosing the entire area with the rectangular selection tool and then by using analyze > analyze particles tool [Figure 2].<sup>[13]</sup>

##### *Vertical probing depth, horizontal probing depth, plaque index, and gingival index*

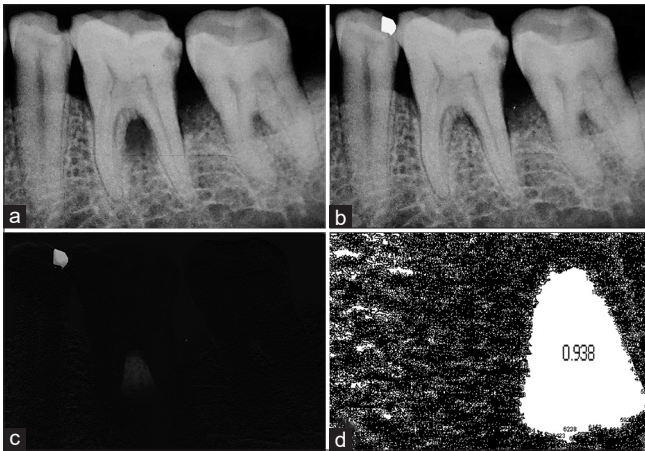
VPD and HPD were recorded at the baseline and at the end of 3 and 6 months using a UNC-15 color-coded periodontal probe and Nabers probe, respectively. Plaque index (PI) was recorded using Turesky modification of Quigley–Hein index preoperatively at the baseline and 1 week and 3 and 6 months postoperatively. Scoring is as follows: Score 0, no plaque; Score 1, isolated areas of plaque at gingival margin; Score 2, thin band of plaque at gingival margin ( $\leq 1$  mm); Score 3, plaque covering up to 1/3 of the tooth surface; Score 4, plaque covering between 1/3 and 2/3 of the tooth surface; and Score 5, plaque covering  $\geq 2/3$  of the tooth surface.

Gingival index (GI) was recorded using Loe and Silness GI at the baseline and 1 week and 3 and 6



**Figure 1:** In both the groups (a and d), full-thickness mucoperiosteal flaps were elevated and the defect site was degranulated with the curettes. Recombinant human bone morphogenetic protein-2 impregnated with absorbable collagen sponge material and PRF (b and e) were placed and stabilized in the defects (c and f), respectively





**Figure 2:** The radiographs obtained at designated postoperative time period (b) was subtracted (c) from the radiograph taken at the baseline (a) using commercially available image processing software. The digitized and excluded residual bone height was transferred to another open source software for area calculation (d)

months postoperatively: Score 0, normal gingiva, no inflammation, no discoloration, and no bleeding; Score 1, mild inflammation, slight color change, mild alteration of gingival surface, and no bleeding; Score 2, moderate inflammation, erythema, swelling, and bleeding on probing or when pressure applied; and Score 3, severe inflammation, severe erythema and swelling, tendency toward spontaneous hemorrhage, and some ulceration.

### Statistical analysis

The data were analyzed with Statistical Package for the Social Sciences (SPSS) for Windows 26.0 (IBM SPSS, Armonk, New York, USA). The descriptive data showed mean and SD and were used for comparison between the groups. The observed data were analyzed using independent samples *t*-test for comparing equality of means. Mann–Whitney U-test was used for comparing ordinal data between two groups. Friedman test for ordinal data and repeated measures ANOVA for continuous data were used to compare data of the same group at different time intervals. Confidence intervals were set at 95% and the values of  $P < 0.05$  were interpreted as statistically significant.

### Observations and Results

All the participants ( $n = 32$ ; BMP,  $n = 16$ ; PRF,  $n = 16$ ) completed study-related interventions. Seven participants (four from BMP and three from PRF group) withdrew after the intervention phase. Hence, statistical analysis was limited to 25 subjects (BMP,  $n = 12$ ; PRF,  $n = 13$ ). A few adverse events such as swelling and minor bleeding episodes were conservatively managed in the postoperative healing phase.

#### Intragroup comparisons

##### Vertical probing depths

The mean PPDs (in mm) in the BMP group were  $5.6333 \pm 1.03355$ ,  $3.317 \pm 0.6519$ , and  $3.028 \pm 0.4574$

at the baseline and at the end of 3 and 6 months, respectively ( $P = 0.0001$ ). The mean PPDs (in mm) in the PRF group were  $6.0391 \pm 1.87195$ ,  $3.700 \pm 0.9284$ , and  $3.482 \pm 0.8987$  at the baseline and at the end of 3 and 6 months, respectively ( $P = 0.0001$ ). The intragroup comparison of reduction in PPDs when compared baseline to 3 and 6 months was statistically significant ( $P < 0.05$ ) in both the treatment groups.

##### Horizontal probing depths

The mean CAL (in mm) in the BMP group was  $4.983 \pm 1.1470$ ,  $3.283 \pm 0.9618$ , and  $3.094 \pm 0.9327$  at the baseline and at the end of 3 and 6 months, respectively ( $P = 0.0001$ ). The mean CAL (in mm) in the PRF group was  $5.682 \pm 2.1535$ ,  $4.100 \pm 1.2861$ , and  $4.200 \pm 1.2814$  at the baseline and at the end of 3 months and 6 months, respectively ( $P = 0.001$ ). The intragroup comparison of HPD when compared baseline to 3 and 6 months was statistically significant ( $P < 0.05$ ) in both the treatment groups.

##### Plaque index

The mean ranks of PI scores in the BMP group were 3.36, 2.19, 2.28, and 2.17 ( $P = 0.0001$ ) and in the PRF group were 3.14, 2.23, 2.59, and 2.05 ( $P = 0.006$ ) at the baseline, at 1 week, and at the end of 3 and 6 months postoperatively, respectively. The intragroup comparison of the mean ranks of PI scores when compared baseline to the end of 3 and 6 months was statistically significant ( $P < 0.05$ ) in both the treatment groups.

##### Gingival index

The mean ranks of GI scores in the BMP group were 3.42, 2.22, 2.50, and 1.86 ( $P = 0.0001$ ) and in the PRF group were 3.32, 2.23, 2.41, and 2.05 ( $P = 0.001$ ) at the baseline, at 1 week, and at the end of 3 and 6 months postoperatively, respectively. The intragroup comparison of the mean ranks of GI scores when compared baseline to the end of 3 and 6 months was statistically significant ( $P < 0.05$ ) in both the treatment groups.

##### Bone fill

The change in mean bone fill (in  $\text{mm}^2$ ) when compared baseline to 3 and 6 months in the BMP group was  $8.68 \pm 2.87$ ,  $9.22 \pm 3.22$ , and  $12.38 \pm 2.09$  ( $P = 0.03$ ) and in the PRF group was  $8.92 \pm 3.98$ ,  $9.20 \pm 2.67$ , and  $11.78 \pm 4.22$ , respectively ( $P = 0.001$ ). This intragroup gain in bone fill when compared baseline to the end of 3 months and 6 months was statistically significant ( $P < 0.05$ ) in both the treatment groups.

#### Intergroup comparisons

##### Vertical probing depth, horizontal probing depth, plaque index, and gingival index

No significant differences were observed between the two groups for VPD at different time intervals [Table 1].

At baseline, there was no significant difference in HPD between the two groups. However, the difference was statistically significant ( $P = 0.012$ ), with BMP group showing better CAL than PRF group at 6 months. No significant differences were observed between the two groups for PI and GI at different time intervals.

### Bone fill

In radiographic analysis, the BMP group showed a statistically significant ( $P < 0.05$ ) and higher bone fill over the PRF group at 6 months [Table 2].

### Pairwise comparisons

#### Vertical probing depth

The mean difference of VPDs was statistically significant ( $P < 0.05$ ) in the BMP group from baseline to 3 months ( $2.317 \pm 0.232$ ; [ $P = 0.0001$ ]) and from baseline to 6 months ( $2.606 \pm 0.200$ ; [ $P = 0.0001$ ]). The mean difference of probing depths was statistically significant ( $P < 0.05$ ) in the PRF group from baseline to 3 months ( $2.339 \pm 0.304$ ; [ $P = 0.0001$ ]) and from baseline to 6 months ( $2.557 \pm 0.327$ ; [ $P = 0.0001$ ]).

#### Horizontal probing depth

The mean difference of HPD was statistically significant ( $P < 0.05$ ) in the BMP group from baseline to 3 months ( $1.700 \pm 0.240$ ; [ $P = 0.0001$ ]) and from

baseline to 6 months ( $1.889 \pm 0.263$ ; [ $P = 0.0001$ ]). The mean difference of CAL was statistically significant ( $P < 0.05$ ) in the PRF group from baseline to 3 months ( $1.582 \pm 0.451$ ; [ $P = 0.017$ ]) and from baseline to 6 months ( $1.482 \pm 0.428$ ; [ $P = 0.018$ ]).

### Discussion

BMPs have unique functions in bone growth, including embryonic skeletal development and postnatal bone remodeling.<sup>[9]</sup> It serves as a vehicle in carrying cells involved in tissue regeneration and has sustained release of GFs in a period between 1 and 4 weeks, stimulating the environment for wound healing in a significant amount of time.<sup>[10]</sup> PRF induces cell proliferation of osteoblasts, periodontal ligament cells, and GFs during a 3-day culture period and suppressed oral epithelial cell growth, which may be beneficial for periodontal regeneration.<sup>[7]</sup>

Many carrier systems have been used in the past, which differed in their affinity and binding with the BMPs and resulted in different release kinetics of BMPs. Absorbable collagen sponges (ACS) have been evaluated in numerous *in vivo* models and clinical trials and it was found that they retained the highest amount of implanted dose, and this initial retention did not depend on RhBMP-2 concentration.<sup>[12]</sup> Foreign-body cellular reaction to a carrier, pore size and geometry, mechanical strength, and biodegradation rate were all suggested as important carrier properties.<sup>[12]</sup>

In the present study, on intragroup comparison, there was a significant increase in bone fill from baseline to 3 months and 6 months in both BMP ( $P = 0.03$ ) and PRF ( $P = 0.001$ ) groups. The bone fill was significantly increased ( $P < 0.05$ ) from baseline to 6 months in the BMP group ( $8.68 \pm 2.87$ – $12.38 \pm 2.09$ ) compared to the PRF ( $8.92 \pm 3.98$ – $11.78 \pm 4.22$ ) group. This increase in bone fill in the BMP group can be attributable to the osteoinductive property of bone morphogenetic protein-2.<sup>[10,12]</sup>

In a study by Vandana and Prakash,<sup>[14]</sup> the clinical and radiographic efficacy of autologous PRF and (RhBMP-2) was compared in the treatment of IBDs. No significant difference was seen in CAL gain in PRF and RhBMP-2 groups. However, the percentage of original defect resolved was significantly greater in the BMP group ( $41.1\% \pm 19.2\%$ ) compared to the PRF group ( $26.75\% \pm 6.03\%$ ).<sup>[9]</sup> This is in accordance with the present study, where, in intergroup comparison, CAL showed no significant difference between test and control at baseline to 3 months, but at 6 months, there was a significant difference between the two groups ( $P = 0.012$ ), with PRF group showing more CAL gain than the test group. The reason for this is PRF shows greater effect in soft and hard tissue regeneration. Sánchez *et al.*<sup>[15]</sup> stated that the PRF when used as a membrane for guided tissue regeneration as a grafting material creates an improved space-making effect, which facilitates cell events

**Table 1: Intergroup comparison of vertical and horizontal probing depths between study groups at different time intervals**

	Group	Mean±SD	t	P
VPD baseline	Test	5.633±1.034	-0.660	0.520 <sup>†</sup>
	Control	6.039±1.872		
VPD 3 months	Test	3.317±0.652	-1.200	0.247 <sup>†</sup>
	Control	3.700±0.928		
VPD 6 months	Test	3.028±0.457	-1.557	0.143 <sup>†</sup>
	Control	3.482±0.899		
HPD baseline	Test	4.983±1.147	-0.993	0.338 <sup>†</sup>
	Control	5.682±2.154		
HPD 3 months	Test	3.283±0.962	-1.952	0.061 <sup>†</sup>
	Control	4.100±1.286		
HPD 6 months	Test	3.094±0.933	-2.687	0.012*
	Control	4.200±1.281		

\*Significant; <sup>†</sup>Not significant. VPD: Vertical probing depth; HPD: Horizontal probing depths; SD: Standard deviation

**Table 2: Intergroup comparison of bone fill between study groups at different time intervals**

Bone fill	Group	Mean±SD	P
Baseline to 3 months	Test	9.22±3.22	0.06 <sup>†</sup>
	Control	9.20±2.67	
Baseline to 6 months	Test	12.38±2.09	0.04*
	Control	11.78±4.22	

\*Significant; <sup>†</sup>Not significant. SD: Standard deviation

that are favorable for periodontal regeneration leading to mineralized tissue formation.

However, when the bone fill was compared between the two groups, the BMP group showed more significant increase than the PRF group at 6 months ( $P = 0.04$ ), whereas, from baseline to 3 months, there was no significant difference. This indicates that BMP accelerated the mineralization and maturation process of the newly formed bone than that of PRF.<sup>[12]</sup>

Plaque control is an important factor, which influences the long-term success of the regenerative material and the clinical parameters.<sup>[16]</sup> Because the patients were on a regular follow-up, the reduction in plaque score, gingival score, PD, and the gain in CAL was maintained up to a period of 6 months. The intragroup comparison showed a highly significant difference from baseline to 3 to 6 months in both the groups for the clinical parameters, i.e., GI, PI, CAL, and PPD ( $P < 0.001$ ), whereas the intergroup comparison showed no statistical difference.

Kaur and Bathla<sup>[17]</sup> assessed the regenerative capacity of Grade II furcation with Gengigel® in conjunction with PRF, and through surgical reentry after 6 months, it was observed that the combined approach resulted in significant furcation defect fill on reevaluation at 6 months. This is in accordance with the present study where the PRF group showed significant bone fill from baseline to 6 months. PRF organizes as a dense fibrin scaffold for the migration of stem cells and exhibits slow release of GFs (transforming GF-1 $\beta$ , platelet-derived GF-AB, and vascular endothelial GF) and glycoproteins (thrombospondin-1), which modulate the regeneration process, resulting in the formation of new cementum, periodontal ligament, and alveolar bone.

Collagen sponges are usually sterilized with ethylene oxide before soaking the sponge in the BMP solution, and this can affect the GF release kinetics or the protein's bioactivity.<sup>[6]</sup> The foremost function of a carrier is to maintain the factor at the site of implantation and thus enhance its local concentration.<sup>[18]</sup> It is loaded with a BMP solution before surgical implantation. BMPs are soluble, and if delivered in a buffer solution, their clearance is rapid. <5% dose remains at the application site, whereas combinations of the proteins with gelatin foam or collagen showed increased retention. It acts as a scaffold promoting early vascularization and osteoinduction and provides osteogenic cells, is biocompatible, and has the ability to adapt to bone.<sup>[19]</sup>

Howell *et al.*<sup>[20]</sup> and Sigurdsson *et al.*<sup>[21]</sup> have observed that RhBMP2 in ACS for alveolar bone augmentation resulted in limited regeneration due to the failure of the ACS to adequately support the supraalveolar wound space and therefore was combined with hydroxyapatite graft material. However, in the present study, as the selected defects with Grade II furcations were contained defects, the ACS

could incorporate the entire defect and the clinical and radiographic outcomes showed complete defect fill.

Retention of RhBMP-2 within carriers after 3 h was variable among the carriers (range, 75%–10%), with collagenous sponges retaining the highest fraction of implanted dose. The collagen matrix retains 65% of the BMPs during initial impregnation and releases it in two phases: an initial phase within hours of implantation and a second phase that depends on nature and geometrical characteristics.<sup>[22,23]</sup>

The concentration of naturally occurring BMP within the matrix of human bone is 1 mg/g bone (Urist *et al.* 1983), which is several orders of magnitude lower than the concentrations applied in clinical studies. Normally, high concentrations of BMPs are required (i.e., 100–1000 ng/ml) at the local site to produce periodontal regeneration (Yamaguchi A). Approximately 10 kg of bovine bone yields only 2  $\mu$ g of BMP.<sup>[23]</sup> The partially purified recombinant BMPs consist of 0.5–115  $\mu$ g to produce cartilage formation within 7 days and bone formation within 14 days.<sup>[24]</sup>

In the present study, we did not come across any complications using RhBMP-2. This might be due to the low concentration of RhBMP-2 (0.5  $\mu$ g/ml/1 cm<sup>3</sup>) or due to the careful handling of the material such as using it in a sterile environment, storing the material in sterile conditions, properly performed surgical procedures with complete coverage of the defect area, and no exposure of the regenerative material.<sup>[25,26]</sup>

From the present study, it can be inferred that both RhBMP-2 in absorbable sponge and PRF are effective in treating Grade II furcation defects as they both lead to the improvement in clinical parameters and increase in the bone fill with minimal postoperative complications.

Being primarily a morphogen responsible for hard tissue regeneration, the effect of BMP-2 on soft tissues is unclear. However, Wikesjö *et al.* have observed that enhanced bone augmentation and soft tissue healing were observed when RhBMP2 was combined with a polyglycolic acid/trimethylene carbonate membrane.<sup>[10]</sup> While the healing of soft tissues takes place within a period of few weeks, the hard tissue healing which depicts the regeneration of cementum, bone, and periodontal ligament requires a longer time period to study the outcomes effectively. Hence, a longer follow-up is suggestive for further research on hard tissue healing potential of RhBMP-2 in furcation defects. Apart from the shorter follow-up period, the other limitations of this study are there are no biomarker assays used for the evaluation of soft and hard tissue changes as this was solely a clinical study.

#### Financial support and sponsorship

Nil.



## Conflicts of interest

There are no conflicts of interest.

## References

- Sanz M, Jepsen K, Eickholz P, Jepsen S. Clinical concepts for regenerative therapy in furcations. *Periodontol* 2000 2015;68:308-32.
- Dannewitz B, Krieger JK, Hüsing J, Eickholz P. Loss of molars in periodontally treated patients: A retrospective analysis five years or more after active periodontal treatment. *J Clin Periodontol* 2006;33:53-61.
- Loos B, Nylund K, Claffey N, Egelberg J. Clinical effects of root debridement in molar and non-molar teeth A 2-year follow-up. *J Clin Periodontol* 1989;16:498-504.
- Huynh-Ba G, Kuonen P, Hofer D, Schmid J, Lang NP, Salvi GE. The effect of periodontal therapy on the survival rate and incidence of complications of multirooted teeth with furcation involvement after an observation period of at least 5 years: A systematic review. *J Clin Periodontol* 2009;36:164-76.
- Del Fabbro M, Bortolin M, Taschieri S, Weinstein R. Is platelet concentrate advantageous for the surgical treatment of periodontal diseases? A systematic review and meta-analysis. *J Periodontol* 2011;82:1100-11.
- Ehrenfest DM, Rasmusson L, Albrektsson T. Classification of platelet concentrates: From pure platelet-rich plasma (P-PRP) to leucocyte- and platelet-rich fibrin (L-PRF). *Trends biotechnol* 2009;27:158-67.
- Sharma A, Pradeep AR. Autologous platelet-rich fibrin in the treatment of mandibular degree II furcation defects: A randomized clinical trial. *J Clin Periodontol* 2011;82:1396-403.
- Lee J, Stavropoulos A, Susin C, Wikesjö UM. Periodontal regeneration: Focus on growth and differentiation factors. *Dent Clin North Am* 2010;54:93-111.
- King GN, Cochran DL. Factors that moderate the effects of bone morphogenetic protein induced periodontal regeneration: A critical review. *J Periodontol* 2002;73:925-36.
- Wikesjö UM, Guglielmoni P, Promsudthi A, Cho KS, Trombelli L, Selvig KA, *et al.* Periodontal repair in dogs: Effect of rhBMP-2 concentration on regeneration of alveolar bone and periodontal attachment. *J Clin Periodontol* 1999;26:392-400.
- Uludag H, D'Augusta D, Palmer R, Timony G, Wozney J. Characterization of rhBMP-2 pharmacokinetics implanted with biomaterial carriers in the rat ectopic model. *J Biomed Mater Res* 1999;46:193-202.
- Cortese A, Pantaleo G, Borri A, Caggiano M, Amato M. Platelet-rich fibrin (PRF) in implant dentistry in combination with new bone regenerative technique in elderly patients. *Int J Surg Case Rep* 2016;28:52-6.
- Yellarthi PK, Rampalli VC, Anumala N, Devaraju RR. Assessments of bone fill following regenerative periodontal therapy by image subtraction using commercially available software. *J Indian Acad Oral Med Radiol* 2014;26:13-8.
- Vandana LK, Prakash S. Comparative evaluation of autologous platelet-rich fibrin and recombinant human bone morphogenetic protein-2 in the treatment of human periodontal intrabony defects: A randomized, controlled clinical and radiographic study. *Dent Med Res* 2017;5:9-16.
- Sánchez AR, Sheridan PJ, Kupp LI. Is platelet-rich plasma the perfect enhancement factor? A current review. *Int J Oral Maxillofac Implants* 2003;18:93-103.
- Goldman MJ, Ross IF, Goteiner D. Effect of periodontal therapy on patients maintained for 15 years or longer. A retrospective study. *J Periodontol* 1986;57:347-53.
- Kaur J, Bathla SC. Regenerative potential of autologous platelet-rich fibrin with and without amnion membrane in the treatment of Grade-II furcation defects: A clinicoradiographic study. *J Indian Soc Periodontol* 2018;22:235-42.
- Mehta DB, Deshpande NC, Dandekar SA. Comparative evaluation of platelet-rich fibrin membrane and collagen membrane along with demineralized freeze-dried bone allograft in Grade II furcation defects: A randomized controlled study. *J Indian Soc Periodontol* 2018;22:322-7.
- Sasikumar KP, Elavarasu S, Gadagi JS. The application of bone morphogenetic proteins to periodontal and peri-implant tissue regeneration: A literature review. *J Pharm Bioallied Sci* 2012;4:S427-30.
- Howell TH, Fiorellini J, Jones A, Alder M, Nummikoski P, Lazaro M, *et al.* A feasibility study evaluating rhBMP-2/absorbable collagen sponge device for local alveolar ridge preservation or augmentation. *Int J Periodontics Restorative Dent* 1997;17:124-39.
- Sigurdsson TJ, Lee MB, Kubota K, Turek TJ, Wozney JM, Wikesjö UM. Periodontal repair in dogs: Recombinant human bone morphogenetic protein-2 significantly enhances periodontal regeneration. *J Periodontol* 1995;66:131-8.
- Holinger JO, Schmitt JM, Buck DC, Shannon R, Joh SP, Zegzula HD, *et al.* Recombinant human bone morphogenetic protein 2 and collagen for bone regeneration. *J Biomed Mater Res* 1998;43:356-64.
- Friess W, Uludag H, Foskett S, Biron R, Sargeant C. Characterization of absorbable collagen sponges as recombinant human bone morphogenetic protein-2 carriers. *Int J Pharm* 1999;185:51-60.
- Jung RE, Glauser R, Schärer P, Hämmerle CH, Sailer HF, Weber FE. Effect of rhBMP-2 on guided bone regeneration in humans. *Clin Oral Implants Res* 2003;14:556-68.
- Coomes AM, Mealey BL, Huynh-Ba G, Barboza-Arguello C, Moore WS, Cochran DL. Buccal bone formation after flapless extraction: A randomized, controlled clinical trial comparing recombinant human bone morphogenetic protein 2/absorbable collagen carrier and collagen sponge alone. *J Periodontol* 2014;85:525-35.
- Dragonas P, Palini C, Khan S, Gajendrareddy PK, Weiner WD. Complications associated with the use of recombinant human bone morphogenetic protein-2 in ridge augmentation: A case report. *J Oral Implantol* 2017;43:351-9.