

LETTER



Inhaled amphotericin B lipid complex for prophylaxis against COVID-19-associated invasive pulmonary aspergillosis

María Cruz Soriano¹, Gabriela Narváez-Chávez¹, Marina López-Olivencia¹, Jesús Fortún² and Raúl de Pablo^{3*} 

© 2021 Springer-Verlag GmbH Germany, part of Springer Nature

Dear Editor,

Recently, Prattes and colleagues [1] published in Intensive Care Medicine a high incidence of coronavirus disease 2019-associated invasive pulmonary aspergillosis (CAPA), according to 2020 ECMM/ISHAM consensus criteria [2], with a correspondingly high mortality rate. However, both the guidelines and a Taskforce report published recently [3] only considered host risk factors [3]. Many work-related aspergillosis outbreaks have been reported due to airborne contamination with *Aspergillus* spores [4]. Protective measures against environmental contamination must be taken when there is construction activity on-site in a hospital. Antifungal prophylaxis is not recommended in mechanically ventilated patients affected by coronavirus disease 2019 (COVID-19) [3].

We implemented an active surveillance protocol for CAPA in mechanically ventilated patients with COVID-19 admitted to the intensive care unit (ICU). The protocol consisted of weekly assessment of galactomannan (GM), fungal culture, and calcofluor white microscopy from endotracheal aspirate for all patients. If test results were positive (GM cutoff > 0.9) or the patient suffered respiratory deterioration, a bronchoscopy with bronchoalveolar lavage (BAL) was performed. CAPA case definition utilized was in accordance with ECMM/ISHAM consensus criteria [2].

In April 2021, there was a CAPA outbreak within the ICU which was associated with remodeling carried out one floor below, despite protection measures having

been implemented. Eleven patients developed CAPA in 3 weeks, which represented an incidence of 22.4% (11/49). The predominant microbiological diagnostic tool was a BAL GM, which was positive in 90% of patients. In 72%, both culture and BAL GM were positive. Air environmental measurements were performed and levels higher than 10 cfu/m³ were considered positive.

In response to the outbreak, protective measures were intensified. All mechanically ventilated patients received 50 mg every 48 h of inhaled amphotericin B lipid complex (ABLC). The isolation rooms were cleaned and closed, and additional cleaning of workspaces and hallways was performed, with special emphasis on architectural isolation of the renovation work. Despite the persistence of airborne *Aspergillus* contamination during 34 consecutive days, no patient who received ABLC developed CAPA (Fig. 1). Interestingly, only two patients with bronchospasm, who did not receive ABLC, developed CAPA. The patients' characteristics, ICU pressure, and treatment over time did not change. A total of 45 patients received prophylaxis with inhaled ABLC. Of these, four (8.8%) suffered bronchospasm and in one patient, the effect was severe enough that a determination was made to suspend the prophylaxis. An additional 33.3% (15/45) experienced mechanical problems due to the buildup of the drug in the filter of the expiratory limb of the ventilator, but in all cases the issue was able to be solved by the nursing staff and caused no clinical impact on the patients.

We conclude that the application of a set of increased environmental protective measures and supplementary inhaled ABLC should be considered to control an outbreak of CAPA in mechanically ventilated patients with COVID-19. We agree with Koehler and colleagues [2],

*Correspondence: raul.depablo.uah@gmail.com

³ Intensive Care Department, Hospital Universitario Ramón y Cajal, Universidad de Alcalá, IRYCIS, Madrid, Spain

Full author information is available at the end of the article

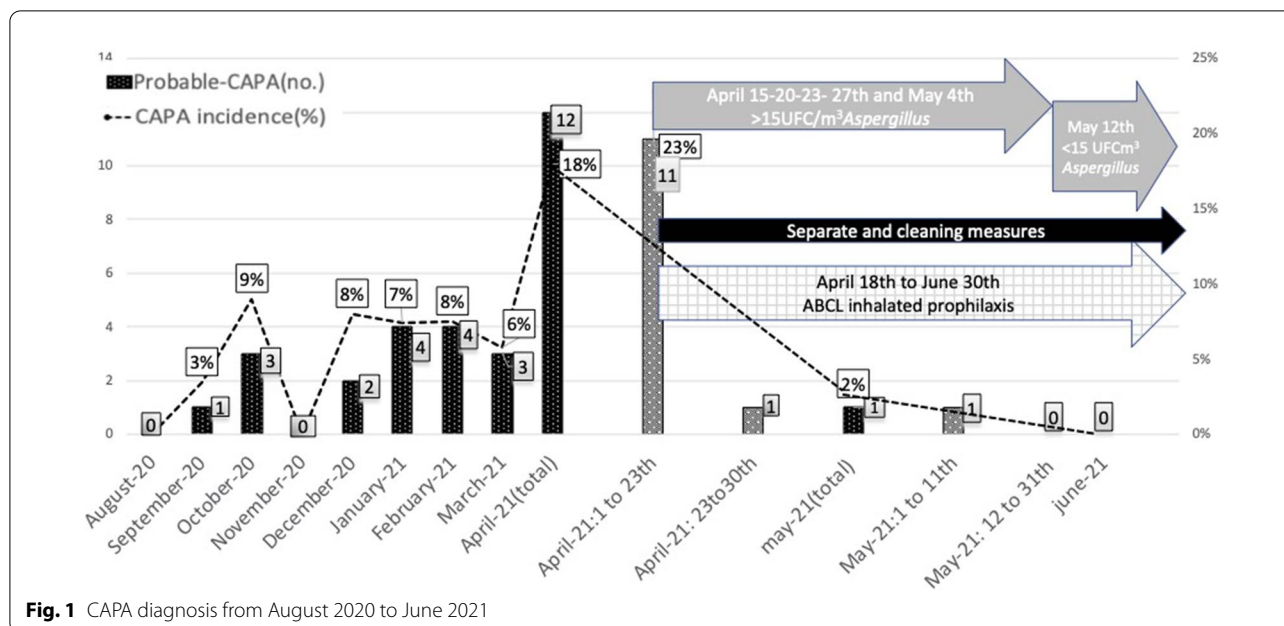


Fig. 1 CAPA diagnosis from August 2020 to June 2021

who suggest that the reported excess mortality might justify antifungal prophylaxis trials, similar to those proposed for patients with invasive aspergillosis [5]. Therefore, inhaled antifungal prophylaxis may be an effective option to reduce CAPA when its incidence is elevated.

Publisher's Note

Springer Nature remains neutral with regard to jurisdictional claims in published maps and institutional affiliations.

Accepted: 3 December 2021

Published online: 23 December 2021

Author details

¹ Intensive Care Department, Hospital Universitario Ramón y Cajal, Universidad de Alcalá, Carretera de Colmena Viejo, km 9,100, 28034 Madrid, Spain. ² Infectious Diseases Department, Hospital Ramón y Cajal, Instituto Ramón y Cajal de Investigación Sanitaria (IRYCIS), Madrid, Spain. ³ Intensive Care Department, Hospital Universitario Ramón y Cajal, Universidad de Alcalá, IRYCIS, Madrid, Spain.

Acknowledgements

We want to thank Preventive Medicine Service, Department of Microbiology and Pharmacy Service, Hospital Ramon y Cajal, Madrid, Spain and our Intensive Care nursing staff for their enormous labor.

Declarations

Conflicts of interest

The authors declare that they have no conflicts of interest.

Ethics approval

The study protocol was approved by the institutional Ethics and Clinical Research Committee.

References

- Prattes J, Wauters J, Giacobbe DR et al (2021) Diagnosis and treatment of COVID-19 associated pulmonary aspergillosis in critically ill patients: results from a European confederation of medical mycology registry. *Intensive Care Med.* <https://doi.org/10.1007/s00134-021-06471-6>
- Koehler P, Bassetti M, Chakrabarti A et al (2021) Defining and managing COVID-19-associated pulmonary aspergillosis: the 2020 ECMM/ISHAM consensus criteria for research and clinical guidance. *Lancet Infect Dis* 21:e149–e162. [https://doi.org/10.1016/S1473-3099\(20\)30847-1](https://doi.org/10.1016/S1473-3099(20)30847-1)
- Verweij PE, Brüggemann RJM, Azoulay E et al (2021) Taskforce report on the diagnosis and clinical management of COVID-19 associated pulmonary aspergillosis. *Intensive Care Med* 47:819–834. <https://doi.org/10.1007/s00134-021-06449-4>
- Fournel I, Sautour M, Lafon I et al (2010) Airborne aspergillus contamination during hospital construction works: efficacy of protective measures. *Am J Infect Control* 38:189–194. <https://doi.org/10.1016/j.ajic.2009.07.011>
- Verweij PE, Rijnders BJA, Brüggemann RJM et al (2020) Review of influenza-associated pulmonary aspergillosis in ICU patients and proposal for a case definition: an expert opinion. *Intensive Care Med* 46:1524–1535. <https://doi.org/10.1007/s00134-020-06091-6>