




# Pediatric flexible bronchoscopy: A single-center report

Valentina Agnese Ferraro MD  | Eugenio Baraldi MD  | Diana Stabinger MD |  
Andrea Zamunaro MD | Stefania Zanconato MD | Silvia Carraro MD 

Department of Women's and Children's Health, University of Padova, Padua, Italy

## Correspondence

Valentina Agnese Ferraro MD, Department of Women's and Children's Health, University of Padova, via Giustiniani 2, 35128 Padova, Italy.  
Email: [ferrarovalentina@hotmail.com](mailto:ferrarovalentina@hotmail.com)

## Abstract

**Introduction:** Pediatric flexible laryngotracheal bronchoscopy (FB) is an integral part of diagnostics and treatment at tertiary pediatric respiratory centers.

**Aim:** FBs performed between 2013 and 2018 at our Pediatric Allergy and Respiratory Medicine Unit of the Department of Women's and Children's Health at Padua University were examined in terms of the indications, findings, and adverse events.

**Materials and Methods:** The electronic medical records of pediatric patients who underwent FB at least once between 1 January 2013 and 31 December 2018 were considered. Patients' clinical data, indications for FB, anatomical findings, information derived from bronchoalveolar lavage (BAL) and bronchial brushing, and possible adverse events were analyzed.

**Results:** There were 447 pediatric FBs performed in 428 patients (aged from 1 month to 18 years) for diagnostic purposes (92.4%), to clear secretions (3.6%), or to monitor a known condition (4.0%). The main indications were recurrent lower respiratory tract infections (LRTI, 32.2%) and chronic wet cough (9.4%). Lower airway malacia was the most common abnormal finding in these two groups (36.1% and 28.6%, respectively). BAL bacterial culture was positive in 55 children (39.6%) with recurrent LRTI and in 25 (59.5%) with chronic wet cough, being *Haemophilus influenzae*, *Streptococcus pneumoniae*, and *Moraxella catarrhalis* the microorganisms most commonly isolated. FB proved a safe procedure and was well tolerated.

**Conclusions:** Pediatric FB is an essential tool at our tertiary pediatric respiratory center. It helps establish the anatomical conditions underlying several chronic respiratory conditions and any correlated microbiological findings, with a significant impact on further patient management.

## KEYWORDS

airway anatomy, bronchoscopy, lower airway malacia, pediatric flexible laryngotracheal bronchoscopy

## 1 | INTRODUCTION

Pediatric flexible laryngotracheal bronchoscopy (FB) is a highly versatile and effective diagnostic and therapeutic tool with an important role in pediatric respiratory medicine.<sup>1</sup> It was first described in 1968<sup>2</sup> and applied in the pediatric population 10 years later.<sup>3,4</sup> Nowadays, FB is an integral part of the management of neonates, infants, and children with various lung and airway diseases.<sup>5</sup> International recommendations on pediatric FB have been published by the European Respiratory Society (ERS)<sup>6</sup> and the American Thoracic Society<sup>7</sup> and describe the indications, the facilities, and equipment needed for the procedure, care of the instruments involved, techniques, and suggestions for sedation and patient management.

FB can be performed for diagnostic and/or therapeutic purposes. It enables an assessment of the airway's anatomical features and the collection of samples from the distal airways (bronchoalveolar lavage [BAL], bronchial brushing, bronchial biopsy) for pathological and microbiological examination. Indications for diagnostic FB<sup>6,7</sup> include stridor, persistent/recurrent wheezing, chronic cough (productive or otherwise), recurrent pneumonia, suspected foreign body aspiration, hemoptysis and pulmonary hemorrhage, suspected structural anomalies or endobronchial lesions, radiographic abnormalities (atelectasis, recurrent/persistent consolidations, atypical and unknown infiltrates, localized hyperinflation), monitoring of lung allograft or artificial airway, and obstructive sleep apnea. Indications for therapeutic FB<sup>6,7</sup> include restoring airway patency in cases of mucus plugs or blood clots, treating alveolar filling disorders (alveolar proteinosis and lipid pneumonia), controlling hemorrhage, dilating a stenotic airway, and bronchoscopic intubation.

Despite the publication of international recommendations,<sup>6,7</sup> the facilities and equipment available in different regions and the clinical uses made of FB still vary. The first survey on pediatric bronchoscopy in Europe<sup>8</sup> was published in 1997. Twenty years later, the ERS Pediatric Bronchology Group conducted a survey on the availability of pediatric bronchoscopy services and the methods used in European pediatric pulmonology centers.<sup>9</sup> In response, 198 centers reported performing a total of 56,145 bronchoscopies over a period of 3 years (2012–2014), averaging 74 FBs and 20 rigid bronchoscopies per center per year. Most procedures were prompted by radiographic abnormalities (48.5%), infections (48.5%), airway obstructions (39.4%), and cough (29.3%). General anesthesia was used for most patients, and complications were apparently rather infrequent.

The main aim of the present retrospective study was to examine all FBs performed between 2013 and 2018 at our Pediatric Allergy and Respiratory Medicine Unit, focusing on the indications, findings, and adverse events. FBs were grouped according to indications so that a general overview of the clinical reasons to perform a bronchoscopy in children together with the possible indication-related findings is provided.

## 2 | MATERIALS AND METHODS

This was a retrospective observational study. The sample included all children 0–18 years old attending the Pediatric Allergy and Respiratory Medicine Unit at the Department of Women's and Children's Health, University of Padua (Italy), who had at least one FB between January 1, 2013 and December 31, 2018. Patients' electronic medical records were examined in terms of demographic and clinical data, indications for FB, anatomical features, findings of BAL and bronchial brushing analysis (if any), adverse events possibly related to the procedure. The data were anonymized and recorded in a database.

FB was performed in a dedicated bronchoscopy suite, using Olympus bronchoscopes with outside diameters of 4.1 or 2.8 mm. Patients were placed under deep sedation/analgesia with intravenous midazolam, propofol, and/or ketamine. All treatments were administered with intravenous bolus (not with continuous infusion) and children could maintain ventilatory function, without external ventilatory support. Lidocaine was used as a topical anesthetic. All FBs were recorded. During the procedure, intrapharyngeal oxygen supplementation was provided for all patients. All FBs were performed by two of the present authors (E. B., who has 25 years of experience, and S. C. with 5 years of experience).

Airway malacia was diagnosed on visual inspection of the airway's shape and dynamics during spontaneous breathing. Malacia was defined as a collapse of at least 50% of the airway lumen.<sup>10,11</sup> Routine BAL fluid studies included differential cell counts and microbiological analyses. No endobronchial or transbronchial biopsies were performed, no foreign body was extracted, and none of the FBs were emergency procedures (which are managed by ear nose and throat specialists in operating rooms).

For the present study, FB-related adverse events were classified as mild or severe, the latter including desaturation <80% or <90% if associated with laryngospasm/bronchospasm, severe hypotension, pulmonary and/or endobronchial bleeding, need for mechanical ventilation, need for admission to the intensive care unit, need for cardiopulmonary resuscitation and/or death.<sup>12</sup>

Indications and findings were expressed in absolute and relative terms. The study was approved by the Ethics Committee of Padua General Hospital (Protocol No. 0048862).

### 2.1 | Definitions used for indications to FB

Recurrent lower respiratory tract infections (LRTIs):  $\geq 3$  episodes of LRTIs per year.<sup>13</sup>

Chronic wet cough: daily wet cough lasting more than 4 weeks.<sup>14</sup>

Tracheal and laryngeal cough: brassy and barking cough, respectively.<sup>15</sup>

Very frequent wheezing: wheezing in preschool-age children typically associated with upper respiratory tract infections, occurring at least 6–8 times per year.<sup>16</sup>

**TABLE 1** Indications for bronchoscopy

	n	%
<b>Diagnosis</b>		
Recurrent respiratory infections	144	32.2
Tracheal and/or laryngeal cough	101	22.6
Persistent or highly frequent wheezing	43	9.6
Chronic wet cough	42	9.4
Severe asthma	39	8.7
Stridor	39	8.7
Upper and lower airway hemorrhage	5	1.1
<b>Therapy</b>		
Secretion management in PCD	8	1.8
Persistent atelectasis	5	1.1
Secretion management in bronchiectasis (non-CF and non-PCD)	3	0.7
<b>Follow-up</b>		
Airway malacia or stenosis	8	1.8
Subglottic hemangioma	6	1.3
After foreign body removal	2	0.4
Vocal cord paresis	1	0.2
Upper airway hemorrhage	1	0.2
<b>Total</b>	<b>447</b>	<b>100</b>

Abbreviations: CF, cystic fibrosis; PCD, primary ciliary dyskinesia.

Persistent wheezing: wheezing in preschool-age children that persists in spite of the anti-asthma therapies administered.<sup>16</sup>

Severe asthma is asthma that requires Step 4 or 5 treatment (e.g., high-dose ICS/LABA), to prevent it from becoming “uncontrolled,” or asthma that remains “uncontrolled” despite this treatment.<sup>17</sup>

Stridor is a variably high-pitched respiratory sound, usually heard on inspiration, that indicates the narrowing of the larynx and/or (extrathoracic) trachea.<sup>18</sup>

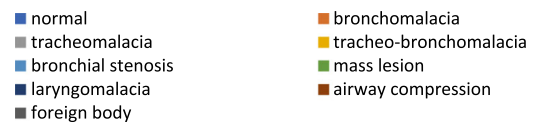### 3 | RESULTS

The retrospective analysis concerns 447 pediatric FBs performed in 428 patients aged from 1 month to 18 years. The indications for FB are listed in Table 1.

Results are grouped according to the indication for the exam.

#### 3.1 | Recurrent LRTIs and chronic wet cough

FB was performed to investigate recurrent LRTIs in 144 cases, including 74 males and 70 females with a median age of 5 years and

**FIGURE 1** Airway anatomy in cases with recurrent lower respiratory tract infections [Color figure can be viewed at [wileyonlinelibrary.com](http://wileyonlinelibrary.com)]**TABLE 2** Findings in cases with recurrent lower respiratory tract infections

	n	%
<b>Viral nucleic acid sequences in BAL</b>		
Negative	43	30.9
Rhinovirus	27	19.4
Rhinovirus + other virus	32	23.0
CMV	12	8.6
CMV + other virus	2	1.4
Adenovirus	12	8.6
Adenovirus + other virus	3	2.2
Coronavirus	2	1.4
Respiratory syncytial virus	2	1.4
Metapneumovirus	2	1.4
Influenza virus type B	1	0.7
Ebstein–Barr virus	1	0.7
<b>Bacterial culture of BAL</b>		
Negative	84	60.4
<i>Haemophilus influenzae</i>	18	13
<i>Streptococcus pneumoniae</i>	12	8.6
<i>S. pneumoniae</i> + <i>H. influenzae</i>	7	5.0
<i>Moraxella catarrhalis</i>	7	5.0
<i>Mycoplasma pneumoniae</i>	4	2.9
<i>Pseudomonas aeruginosa</i>	3	2.2
<i>Streptococcus pyogenes</i>	2	1.4
<i>Staphylococcus aureus</i>	2	1.4

Abbreviations: BAL, bronchoalveolar lavage; CMV, cytomegalovirus.

9 months (interquartile range [IQR], 3 years and 6 months to 8 years and 6 months). In total, 81 (56.3%) of these patients had a normal airway anatomy, while the most common anatomical abnormalities in the remainder were bronchomalacia and tracheomalacia (Figure 1). One patient showed airway compression, prompting chest computed tomography with angiography (CTA), which enabled the diagnosis of a double aortic arch. Three patients had an endobronchial mass and were further investigated with biopsies, which revealed an inflammatory myofibroblastic tumor, a pulmonary carcinoid, and a nonspecific inflammatory lesion.

BAL was performed in 139 patients. The differential cell count in BAL fluid, performed in 126 cases, was normal in 79 children (62.7%) and showed an increased percentage of neutrophils (>5%) in 47 (37.3%). The results of BAL microbiological analyses are shown in Table 2.

Prompted by a clinical suspicion of primary ciliary dyskinesia (PCD), 75 patients underwent bronchial or nasal brushing to analyze ciliary ultrastructure using transmission electron microscopy (TEM). The ciliary ultrastructure was suggestive of PCD in 3 cases, normal in 71 cases, and not evaluable in 1.

In 42 children (22 males, median age of 6 years [IQR, 4–9]), FB was performed to investigate chronic cough.

Twenty-nine children (69%) had a normal airway anatomy and 13 (30.1%) had airways malacia or stenosis (two tracheomalacia, eight bronchomalacia, two tracheo-bronchomalacia, one bronchial stenosis). BAL was collected in all 42 cases and revealed a normal differential cell count in 17 children (40.5%) and an increased percentage of neutrophils (>5%) in 25 children (59.5%). The search for respiratory viruses by PCR was positive in 26 cases (61.9%): Rhinovirus was found alone in seven, and together with other virus in four (cytomegalovirus, metapneumovirus, adenovirus, respiratory syncytial virus, and coronavirus). BAL bacterial culture was positive in 25 children (59.5%), the most common microorganisms isolated being *Haemophilus influenzae* (15 children) and *Streptococcus pneumoniae* (8 children), followed by *Moraxella catarrhalis* (two patients).

Ultrastructure analysis of the nasal/bronchial respiratory mucosa with TEM was performed in 28 patients with chronic wet cough, and anomalies suggestive of PCD were found in 3, the sample was not evaluable in 5, and a normal ultrastructure was found in 20.

### 3.2 | Tracheal and/or laryngeal cough

FB was performed in 101 children (59 males, median age: 6 years [IQR, 4 years 9 months to 10 years 3 months]) to investigate tracheal and/or laryngeal cough, and 57 (56.4%) revealed an abnormal airway anatomy (Table 3). In four cases, a pulsatile or fixed airway compression was further investigated through chest CTA or chest magnetic resonance imaging (MRI). Two of these children showed a normal anatomy, one had a right aortic arch, and one a Kommerell diverticulum. One child had an endotracheal mass lesion, which was not biopsied because the patient was lost to follow-up.

**TABLE 3** Airway anatomy in patients with tracheal cough

	n	%
Airway anatomy		
Normal	44	43.6
Lower airways		
Tracheomalacia	18	17.8
Trachea-bronchomalacia	16	15.8
Bronchomalacia	13	12.9
Airway compression	4	4.0
Bronchial stenosis	2	2.0
Mass lesion	1	1.0
Tracheal diaphragm	1	1.0
Upper and lower airways		
Laryngo- or pharyngo-tracheomalacia	2	2.0

### 3.3 | Persistent or very frequent wheezing

FB was performed in 43 patients (29 males, median age: 13 months [IQR, 9 months to 5 years]) to investigate persistent or very frequent wheezing. Fifteen children (34.9%) had a normal airway anatomy, 26 (60.5%) had malacia or airway stenosis of the airways (22 tracheo- and/or broncho-malacia, three pharyngo- and/or laryngo-malacia, 1 tracheal stenosis) and two (4.6%) had a foreign body in the airways.

### 3.4 | Severe asthma

FB was performed in 39 patients with severe asthma (28 males, median age: 10 years [IQR, 9 years to 13 years 3 months]). Most patients (33, 84.6%) had a normal airway anatomy, three had bronchomalacia, one tracheomalacia, one bronchial stenosis, and one a suspected airway compression (further investigated using chest CTA, which showed no vascular anomalies). BAL collected in 38 cases showed a normal differential cell count in 32 (84.2%) and an increased percentage of eosinophils in one.

### 3.5 | Stridor

FB was performed to investigate stridor in 39 cases (24 males, median age: 9 months [IQR, 3–18 months]). Thirty-three (84.6%) showed an abnormal airway anatomy, with laryngomalacia the most frequent finding (21 patients, 53.8%), and the lower airways also showed trachea- and/or broncho-malacia in seven of them. Three patients had a laryngeal cleft, one had vocal cord paresis, and one had a subglottic hemangioma.

### 3.6 | Upper and lower airway hemorrhage

Five patients underwent FB for recurrent episodes of hemoptysis. Airway anatomy was normal in all cases, and no blood was found in the upper respiratory or lower respiratory tracts in four, while one with idiopathic hemosiderosis had visible active bleeding.

#### 3.6.1 | Adverse events

The mild adverse events encountered were one case of urticaria after propofol administration (an 11-year-old male with severe asthma), treated with chlorphenamine and systemic steroids; nine cases of transient cough and/or stridor during the FB, which had been indicated for wheezing (in three children), laryngotracheal cough (in three), severe asthma (in two) and stridor (in one).

The following four severe adverse events during or immediately after the FB were recorded.

- A 14-year-old female who underwent FB for stridor experienced laryngospasm with desaturation ( $\text{SatO}_2 < 90\%$ ), and was treated with nebulized epinephrine, systemic steroids, and increased oxygen supplementation.
- An 8-year-old female who underwent FB for recurrent respiratory infections had bronchospasm with several episodes of desaturation ( $\text{SatO}_2 < 90\%$ ) during the procedure, and was treated with albuterol, bag-mask ventilation, and increased oxygen supplementation.
- A 4-year-old male who underwent FB for tracheal cough developed respiratory distress with bronchospasm and desaturation ( $\text{SatO}_2 < 90\%$ ), and was treated with albuterol, systemic steroids, bag-mask ventilation, and increased oxygen supplementation.
- A 6-year-old male who underwent FB for tracheal cough developed severe respiratory distress with desaturation ( $\text{SatO}_2 < 90\%$ ), that proved unresponsive to bag-mask ventilation, requiring endotracheal intubation and admission to the intensive care unit. He was extubated a few hours later. The child was diagnosed with adenoid hypertrophy and laryngo-tracheomalacia.

Four patients were not included in the present report because FB had to be interrupted due to severe respiratory distress, laryngospasm, or bronchospasm with desaturation ( $\text{SatO}_2 < 90\%$ ) immediately after sedation. All four children were bag-mask ventilated, and treated with systemic steroids, nebulized adrenalin, salbutamol, and increased oxygen supplementation. In one case, severe respiratory distress appeared right after propofol injection and an allergic reaction to propofol was suspected. In the other three cases, laryngospasm/bronchospasm appeared right after bronchoscope introduction and it was interpreted as an exaggerated airway reactivity to the mechanical stimulation caused by the bronchoscope. Only in one of these cases, the bronchoscopy was rescheduled after a course of systemic steroid, and no anatomical anomalies were detected.

None of the patients died during the procedure. No FB-related respiratory deterioration required cardiopulmonary resuscitation.

## 4 | DISCUSSION

This report describes the 447 FBs performed at our Pediatric Allergy and Respiratory Medicine Unit over 6 years, mainly for a diagnostic purpose (92.4%). In a minority of cases, FB was used to clear secretions (3.6%) or monitor a previously identified condition (4.0%). The diagnostic FBs were performed largely (41.6%) to investigate recurrent LRTI or chronic wet cough. Deep sedation/analgesia was administered and generally well tolerated, with severe adverse events reported in eight children.

Recurrent LRTI and chronic wet cough can be presenting symptoms of a chronic respiratory disease. Recent ERS guidelines<sup>19,20</sup> suggest airway endoscopy to investigate chronic wet cough persisting after 4 weeks of appropriate antibiotics. FB is recommended in children with LRTI not responding to antibiotic treatment if it is impossible to sample the lower respiratory tract noninvasively.<sup>21,22</sup> Lower airway malacia was the most frequent abnormality identified in our study sample, confirming previous reports. Gokdemir et al.<sup>23</sup> found airway malacia the most common abnormality in children with recurrent pneumonia, and Boogaard et al.<sup>10</sup> reported recurrent LRTI in 60 (63%) out of 96 patients with primary airway malacia. Likewise, Chang et al.<sup>14,24</sup> also found airway malacia the most frequent abnormality in children with chronic wet cough. Malacia disorders are characterized by excessive collapsibility of the trachea and/or bronchi, due to a disproportionate laxity of the wall or impaired cartilage integrity.<sup>11</sup> Endoscopy is the gold standard for diagnosing airway malacia but has potential limitations due to the subjective assessment of lumen changes or to bronchoscope possibly occluding or distorting the airway.<sup>11</sup> The pathogenetic relationship between airway malacia and LRTI or chronic wet cough remains unclear. It has been suggested that juxtaposition of the airway walls induce recurrent vibrations and mucosal irritation, and the narrower airway prevents clearance of secretions, thus predisposing to distal infections.<sup>25-28</sup>

From a microbiological standpoint, BAL bacterial cultures were positive in 39.5% of patients with recurrent LRTI and 59.5% of those with chronic wet cough. Interestingly, in the subgroup of children with airway malacia in 40% of cases bacteria were isolated from BAL, supporting the possible pathogenetic relationship between this anatomic abnormality and the persistence of secretions in the lower respiratory tract. The microorganisms most often isolated were *H. influenzae*, *S. pneumoniae*, and *M. catarrhalis*. These findings are consistent with data published by De Schutter et al.<sup>21</sup> on children with recurrent pneumonia and by Wong et al.<sup>29</sup> concerning children with chronic wet cough. Our results are also in keeping with the microbiological data reported by Chang et al.,<sup>24,30</sup> who listed *S. pneumoniae*, *H. influenzae*, and *M. catarrhalis* as the most common microorganisms isolated in children with chronic wet cough. The detection of potentially pathogenetic bacteria might influence the

therapeutic management of children with recurrent LRTI or chronic wet cough. In all the included cases, bacterial isolations in BAL were carefully considered and, when clinically appropriate, a targeted course of antibiotic therapy was prescribed.

On the contrary, the detection of respiratory viruses in 69.1% of children with recurrent LRTIs and 61.9% of children with chronic wet cough, should be cautiously interpreted. Previous authors reported a similar proportion of viruses in children with protracted bacterial bronchitis (PBB),<sup>31</sup> while others questioned the possible pathogenetic role of viruses, finding comparable rate of viral detection in children with PBB and in healthy children.<sup>32</sup> Therefore, no firm conclusion can be drawn on the pathogenetic role of viruses in this clinical context.

FB is recommended for children with persistent, frequently recurring or atypical wheezing to examine the underlying anatomy.<sup>33,34</sup> Previous studies demonstrated that nearly one in two such children have central airway malacia.<sup>28,35,36</sup> In our sample, 63.4% of wheezing patients had airway malacia, confirming that weakness of the trachea and mainstem bronchi makes the airways more susceptible to collapse during expiration, causing airflow limitation and wheeze.<sup>11</sup> It is, therefore, important to use FB to study children with recurrent/persistent wheezing who fail to respond to conventional therapy, as a diagnosis of airway malacia could provide the rationale for limiting the use of drugs with potential side effects like inhaled steroids treatment.<sup>36</sup>

Noteworthy, airway malacia emerged in a significant number of cases as an anatomical aspect related to chronic respiratory symptoms. This finding underlies the importance of bronchoscopy given that malacia can only be diagnosed through the direct inspection of the airways.

In some patients presenting even with common symptoms, FB can lead to unexpected diagnoses and have a significant impact on their further treatment and prognosis.<sup>37,38</sup> In our study sample, FB revealed a foreign body in the airways of two children with persistent wheezing unresponsive to salbutamol and systemic steroids treatment, and one with recurrent LRTI, despite no history suggestive of aspiration. FB identifies an endobronchial mass in another three patients investigated due to recurrent LRTI involving the same lung lobe. In further two patients with tracheal cough and one with recurrent LRTI, a vascular ring was suspected on FB, and imaging confirmed a right aortic arch, a Kommerell diverticulum and a double aortic arch. It is common in such cases for FB to show extrinsic pulsatile compression of the trachea, while a chest CTA or MRI are required for a more precise diagnosis.<sup>39</sup>

The role of bronchoscopy in cases of severe asthma is still debated. On the one hand, sceptics focus on the risk of an invasive procedure proving clinically pointless; on the other, supporters emphasize the irreplaceable role of FB in the differential diagnosis of severe asthma.<sup>40</sup> When assessing children with asthma symptoms that are difficult to control, pediatric pulmonologists have to establish whether they really have asthma by excluding all the other conditions that may mimic asthma.<sup>16,17,41</sup> Several comorbidities of asthma or alternative diagnoses, such as

trachea- and broncho-malacia, central airway obstruction and/or compression, foreign body, or congenital airway malformations, can only be detected by FB.<sup>17</sup> In our cohort of patients with severe asthma who underwent FB, the majority (84.6%) had a normal airway anatomy, while 5 (12.8%) had central airway malacia or stenosis.

BAL analysis can also provide useful information in children with severe asthma, helping to elucidate the asthma endotype.<sup>40</sup> Unfortunately, this analysis was unreliable in most of our severe asthma patients because the BAL procedure was conducted while they were treated with high doses of steroids.

From a safety standpoint, FB was well tolerated by most of our patients with severe asthma: only 4 (10.3%) had mild adverse events and none had any severe adverse events.

Although pediatric bronchoscopy is known to be a generally safe procedure, serious and even fatal adverse events have been described, related mostly to patients' diseases before the procedure.<sup>12,42,43</sup> FB was well tolerated by our study sample as a whole. Ten children (2.2%) had mild adverse events, four children (0.9%) had severe adverse events after completing the FB, and in four cases (0.9%), not included in this analysis, it was impossible to perform FB due to adverse events occurring immediately after sedation. The most common mild adverse event was transient cough and/or stridor, mainly affecting patients with recurrent or very frequent wheezing, laryngotracheal cough, or severe asthma. The most frequent severe adverse event was respiratory distress with severe desaturation, which in one case necessitated intubation and monitoring for few hours in the intensive care unit.

Today pediatric pulmonologists strive to understand their patients' potential risk factors for FB-related adverse events, to prevent their occurrence.<sup>43,44</sup>

Adverse events can certainly be minimized if each patient's indications and clinical status are carefully examined, and appropriate anesthesia and monitoring during the procedure is assured.<sup>43</sup> In our setting, patients underwent a complete assessment the day before undergoing FB, and the procedure was postponed if their clinical status could not ensure a safe procedure (if they showed signs or symptoms, for instance, of acute infection, acute bronchospasm, or fever). FBs were performed in deep sedation with children breathing spontaneously throughout the procedure. During and after sedation/analgesia, patients were monitored in a dedicated room to promptly manage any possible adverse events.

## 5 | CONCLUSIONS

In conclusion, flexible laryngeal and tracheal bronchoscopy is an essential tool at our tertiary pediatric respiratory center. In most cases, it helps establish the anatomical condition underlying a number of chronic respiratory disorders and possibly correlated microbiological findings, with a significant impact on patients' further management.

## ACKNOWLEDGMENTS

The authors are grateful to Caterina Agosto, Franca Benini, Antuan Divisic, Francesca Rusalen, working in Pediatric Pain and Palliative Care Service, Department of Women's and Children's Health, University Hospital Padua, who have been responsible for sedation/analgesia during FB.

## CONFLICT OF INTERESTS

The authors declare that there are no conflict of interests.

## AUTHOR CONTRIBUTIONS

**Valentina Agnese Ferraro:** Data curation (lead); formal analysis (lead); writing—original draft (lead). **Eugenio Baraldi:** Writing—review and editing (equal). **Diana Stabinger:** Data curation (supporting); formal analysis (supporting); writing—review and editing (supporting). **Andrea Zamunaro:** Data curation (supporting); writing—review and editing (supporting). **Stefania Zanconato:** Conceptualization (lead); formal analysis (equal); supervision (lead); writing—review and editing (lead). **Silvia Carraro:** Conceptualization (lead); data curation (equal); formal analysis (equal); supervision (lead); writing—review and editing (lead).

## DATA AVAILABILITY STATEMENT

The data that support the findings of this study are available on request from the corresponding author. The data are not publicly available due to privacy or ethical restrictions.

## ORCID

Valentina Agnese Ferraro  <https://orcid.org/0000-0002-9840-8519>

Eugenio Baraldi  <https://orcid.org/0000-0002-1829-3652>

Silvia Carraro  <https://orcid.org/0000-0003-2284-1225>

## REFERENCES

- Nicolai T. Pediatric bronchoscopy. *Pediatr Pulmonol.* 2001;31(2):150-164.
- Ikeda S, Yanai N, Ishikawa S. Flexible bronchofiberscope. *Keio J Med.* 1968;17(1):1-16.
- Wood RE, Sherman JM. Pediatric flexible bronchoscopy. *Ann Otol Rhinol Laryngol.* 1980;89(5 Pt 1):414-416.
- Wood RE, Fink RJ. Applications of flexible fiberoptic bronchoscopes in infants and children. *Chest.* 1978;73(5 suppl):737-740.
- Sachdev A, Chhawchharia R. Flexible fiberoptic bronchoscopy in pediatric practice. *Indian Pediatr.* 2019; 56(7):587-593.
- Midulla F, de Blic J, Barbato A, et al. Flexible endoscopy of paediatric airways. *Eur Respir J.* 2003;22(4):698-708.
- Faro A, Wood RE, Schechter MS, et al. Official American Thoracic Society technical standards: flexible airway endoscopy in children. *Am J Respir Crit Care Med.* 2015;191(9):1066-1080.
- Barbato A, Magarotto M, Crivellaro M, et al. Use of the paediatric bronchoscope, flexible and rigid, in 51 European centres. *Eur Respir J.* 1997;10(8):1761-1766.
- Schramm D, Yu Y, Wiemers A, et al. Pediatric flexible and rigid bronchoscopy in European centers—availability and current practice. *Pediatr Pulmonol.* 2017;52(11):1502-1508.
- Boogaard R, Huijsmans SH, Pijnenburg MWH, Tiddens HAWM, de Jongste JC, Merkus PJFM. Tracheomalacia and bronchomalacia in children: incidence and patient characteristics. *Chest.* 2005; 128(5):3391-3397.
- Wallis C, Alexopoulou E, Antón-Pacheco JL, et al. ERS statement on tracheomalacia and bronchomalacia in children. *Eur Respir J.* 2019; 54(3):1900382.
- Carlens J, Fuge J, Price T, et al. Complications and risk factors in pediatric bronchoscopy in a tertiary pediatric respiratory center. *Pediatr Pulmonol.* 2018;53(5):619-627.
- de Benedictis FM, Bush A. Recurrent lower respiratory tract infections in children. *BMJ.* 2018; 362:k2698.
- Chang AB, Oppenheimer JJ, Weinberger MM, et al. Management of children with chronic wet cough and protracted bacterial bronchitis: CHEST guideline and expert panel report. *Chest.* 2017;151(4):884-890.
- Chang AB, Oppenheimer JJ, Irwin RS, CHEST Expert Cough Panel. Managing chronic cough as a symptom in children and management algorithms: CHEST guideline and expert panel report. *Chest.* 2020; 158(1):303-329.
- 2019 GINA Main Report [Internet]. Global Initiative for Asthma—GINA. <https://ginasthma.org/gina-reports/>. Accessed July 23, 2019.
- Chung KF, Wenzel SE, Brozek JL, et al. International ERS/ATS guidelines on definition, evaluation and treatment of severe asthma. *Eur Respir J.* 2014;43(2):343-373.
- Pfleger A, Eber E. Assessment and causes of stridor. *Paediatr Respir Rev.* 2016;18:64-72.
- Morice AH, Millqvist E, Bieksiene K, et al. ERS guidelines on the diagnosis and treatment of chronic cough in adults and children. *Eur Respir J.* 2020;55(1):1901136.
- Kantar A, Chang AB, Shields MD, et al. ERS statement on protracted bacterial bronchitis in children. *Eur Respir J.* 2017;50(2):1602139.
- De Schutter I, De Wachter E, Crokaert F, et al. Microbiology of bronchoalveolar lavage fluid in children with acute nonresponding or recurrent community-acquired pneumonia: identification of nontypeable *Haemophilus influenzae* as a major pathogen. *Clin Infect Dis.* 2011;52(12):1437-1444.
- de Blic J, Midulla F, Barbato A, et al. Bronchoalveolar lavage in children. ERS Task Force on bronchoalveolar lavage in children. European Respiratory Society. *Eur Respir J.* 2000;15(1):217-231.
- Gokdemir Y, Cakir E, Kut A, et al. Bronchoscopic evaluation of unexplained recurrent and persistent pneumonia in children. *J Paediatr Child Health.* 2013;49(3):E204-E207.
- Chang AB, Oppenheimer JJ, Weinberger M, Rubin BK, Irwin RS. Children with chronic wet or productive cough—treatment and investigations: a systematic review. *Chest.* 2016;149(1):120-142.
- Santiago-Burruchaga M, Zalacain-Jorge R, Vazquez-Cordero C. Are airways structural abnormalities more frequent in children with recurrent lower respiratory tract infections? *Respir Med.* 2014; 108(5):800-805.
- Zgherea D, Pagala S, Mendiratta M, Marcus MG, Shelov SP, Kazachkov M. Bronchoscopic findings in children with chronic wet cough. *Pediatrics.* 2012;129(2):e364-e369.
- Kompare M, Weinberger M. Protracted bacterial bronchitis in young children: association with airway malacia. *J Pediatr.* 2012; 160(1):88-92.
- De Baets F, De Schutter I, Aarts C, et al. Malacia, inflammation and bronchoalveolar lavage culture in children with persistent respiratory symptoms. *Eur Respir J.* 2012;39(2):392-395.
- Wong OY, Marchant JM, Yerkovich ST, Chang AB. Predictors of time to cough resolution in children with chronic wet cough treated with antibiotics after bronchoscopy. *Pediatr Pulmonol.* 2019;54(12): 1997-2002.
- Chang AB, Upham JW, Masters IB, et al. Protracted bacterial bronchitis: the last decade and the road ahead. *Pediatr Pulmonol.* 2016;51(3):225-242.

31. Wurzel DF, Marchant JM, Yerkovich ST, et al. Prospective characterization of protracted bacterial bronchitis in children. *Chest*. 2014;145(6):1271-1278.
32. Wang Y, Hao C, Ji W, et al. Detecting respiratory viruses in children with protracted bacterial bronchitis. *Respir Med*. 2019; 151:55-58.
33. Ren CL, Esther CR Jr., Debley JS, et al. Official American Thoracic Society Clinical Practice Guidelines: diagnostic evaluation of infants with recurrent or persistent wheezing. *Am J Respir Crit Care Med*. 2016;194(3):356-373.
34. Hayden L, Boyer D, Hysinger EB, et al. Flexible airway endoscopy in children. *Ann Am Thorac Soc*. 2015; 12(12):1873-1875.
35. Boesch RP, Baughn JM, Cofer SA, Balakrishnan K. Trans-nasal flexible bronchoscopy in wheezing children: diagnostic yield, impact on therapy, and prevalence of laryngeal cleft. *Pediatr Pulmonol*. 2018;53(3):310-315.
36. Baraldi E, Donegà S, Carraro S, Farina M, Barbato A, Cutrone C. Tracheobronchomalacia in wheezing young children poorly responsive to asthma therapy. *Allergy*. 2010;65(8):1064-1065.
37. Foltran F, Ballali S, Rodriguez H, et al. Inhaled foreign bodies in children: a global perspective on their epidemiological, clinical, and preventive aspects. *Pediatr Pulmonol*. 2013;48(4):344-351.
38. Roby BB, Drehner D, Sidman JD. Pediatric tracheal and endobronchial tumors: an institutional experience. *Arch Otolaryngol Head Neck Surg*. 2011;137(9):925-929.
39. Backer CL, Mongé MC, Popescu AR, Eltayeb OM, Rastatter JC, Rigsby CK. Vascular rings. *Semin Pediatr Surg*. 2016;25(3):165-175.
40. Januska MN, Goldman DL, Webley W, et al. Bronchoscopy in severe childhood asthma: irresponsible or irreplaceable? *Pediatr Pulmonol*. 2020;55(3):795-802.
41. Hoch H, Kattan M, Szeffler SJ. Challenges in managing difficult-to-treat asthma in children: stop, look, and listen. *Pediatr Pulmonol*. 2020;55(3):791-794.
42. Jin F, Mu D, Chu D, Fu E, Xie Y, Liu T. Severe complications of bronchoscopy. *Respiration*. 2008;76(4):429-433.
43. de Blic J, Marchac V, Scheinmann P. Complications of flexible bronchoscopy in children: prospective study of 1,328 procedures. *Eur Respir J*. 2002;20(5):1271-1276.
44. Terkawi RS, Altirkawi KA, Terkawi AS, Mukhtar G, Al-Shamrani A. Flexible bronchoscopy in children: utility and complications. *Int J Pediatr Adolesc Med*. 2016;3(1):18-27.

**How to cite this article:** Ferraro VA, Baraldi E, Stabinger D, Zamunaro A, Zanconato S, Carraro S. Pediatric flexible bronchoscopy: a single-center report. *Pediatric Pulmonology*. 2021;56:2634-2641. <https://doi.org/10.1002/ppul.25458>