

Conventional 2.0 mm miniplates versus 3-D plates in mandibular fractures

Access this article online
Website: www.amsjournal.com
DOI: 10.4103/2231-0746.119231
Quick Response Code: 

Bipin S. Sadhwani, Sonal Anchlia

Department of Oral and Maxillofacial Surgery, Government Dental College and Hospital, Ahmedabad, Gujarat, India

Address for correspondence:

Dr. Bipin S. Sadhwani, Department of Oral and Maxillofacial Surgery, Government Dental College and Hospital, Asarwa, Ahmedabad - 380 016, Gujarat, India.
E-mail: drbipinsadhwani@gmail.com

ABSTRACT

Aim: To compare and evaluate the treatment outcome and postoperative complications in mandibular fractures using 2- and 3-dimensional miniplates. **Materials and Methods:** This study consisted of a sample of 28 patients (40 fracture sites) divided randomly but equally (single-blind control trial study) into two groups. Each group contains 14 patients (20 similar fracture sites in each group). Group 1 was treated with open reduction and internal fixation using 3-dimensional (3-D) miniplates. Group II was treated using 2-dimensional (2-D) 2-mm miniplates. **Results:** Out of 14 patients treated by conventional 2-mm miniplates, 2 patients developed occlusal discrepancy, another 2 had postoperative mobility at fracture site, and 1 developed plate failure and subsequent infection, which was treated by removal of the plate under antibiotic coverage. One patient treated by 3-dimensional plates had tooth damage. **Statistical Analysis:** Chi-square test. **Conclusion:** The results of this study suggested that the treatment of mandibular fractures (symphysis, parasymphysis, and angle) with 3-dimensional plates provided 3-dimensional stability and carried low morbidity and infection rates. The only probable limitations of 3-dimensional plates were excessive implant material due to the extra vertical bars incorporated for countering the torque forces.

Keywords: 3-Dimensional miniplates, conventional 2.0-mm miniplates, mandible fracture

INTRODUCTION

There are two fundamentally different philosophies for the treatment of mandible fracture using plates and screws:

- Concept of rigid fixation: Spiessl^[1] introduced compression plates, which were fixed along the lower border of fractured mandible using bicortical screws. Compression plates rigidly fixed the fractured bone segments sufficiently to prevent inter-fragmentary movement and provide healing by primary intention. Difficulty in adaptation, bulk of the plates, scar formation due to extraoral approach, and increased chances of nerve injury were their disadvantages
- Concept of semi-rigid fixation: Champy *et al.*,^[2] defined

the “ideal lines of osteosynthesis” based on experiments of GEBOAS (Group of Research in Bones and Joint Biomechanics of Strasbourg). Champy revolutionized intraoral fixation by innovating and modifying the Michelet *et al.*'s^[3] technique of osteosynthesis. It consisted of mono-cortical, juxta alveolar, and subapical osteosynthesis without compression and intermaxillary fixation using miniaturized malleable plates. Small size of the plate, easy adaptability, easy placement, and use of intraoral approach led to increased use of mono-cortical plates in maxillofacial surgery.^[4]

However, Luhr and AO/ASIF^[5] advocates felt that miniplates did not offer adequate stabilization of the fractures, thereby

necessitating the need of further inter-maxillary fixation. Farmand and Dupoirieux^[6] presented 3-D plates with quadrangular shape formed by joining two mini-plates with interconnecting crossbars. Because of the quadrangular configuration of the plates, they provided good stability and resistance to torsional forces. Easy use, good resistance against torque forces, and compact form of the plates were some of their advantages.

Considering the above, this study was carried out to compare the conventional 2-mm miniplates and 3-D miniplates in terms of treatment outcome, stability, duration of surgery, and complications of treatment of mandible fractures.

MATERIALS AND METHODS

This was a prospective study consisting of a sample size of 28 patients (18 males and 10 females) with undisplaced as well as displaced mandible fractures conducted at Govt. Dental College and Hospital, Ahmedabad. Exclusion criteria for study were comminuted, malunited, and infected fractures as well as mandibular coronoid and condylar fractures. All patients were within the age group of 18-60 years, excluding medically compromised patients.

The patients were divided randomly (single-blind control trial study) into two groups of 20 patients each, but the number of patients of each type were divided equally. Group I was treated with open reduction and internal fixation (ORIF) using 3-D miniplates and Group II were treated with conventional 2-mm (2-D) stainless steel miniplates. Also, 2-mm, 4-hole with gap conventional 2-D and 6-hole with gap 3-D stainless steel miniplates were used. Three-dimensional designs were formed by joining two 2-D miniplates with interconnecting vertical crossbars. Then, 2 × 8 mm and 2 × 10 mm stainless steel self-tapping screws were used to fix the plates. The diameter of head of screw was 2.8 mm with countersinking of the head corresponding to the 30-degree beveled hole in the plate [Figure 1].

Reduction and fixation of fracture segments was done intraorally under GA, except in some inaccessible angle fractures where transbuccal approach was used. In Group I patients, fixation of the 3-D plates was done in the following manner: In the symphysis/parasymphysis region, the upper crossbar of 3-D plates was placed in subapical position of teeth, and injury to dental roots was avoided using mono-cortical screws. In the region posterior to mental foramen, 3-D plates was placed in such a way that upper cross bar was between root apex and inferior alveolar nerve. In the region of angle, 3-D plate was placed in such way that vertical strut was perpendicular to external oblique ridge. Here, we showed a preoperative and postoperative series of photographs and radiographs of right parasymphysis fracture fixed with 3-D plates [Figures 2-6].

In Group II patients, fixation of conventional 2-D miniplates was done along the osteosynthesis lines as described by Champy. Postoperative intermaxillary fixation was avoided and done only if required or when occlusion was deranged. Postoperative X-ray

was taken to evaluate reduction and fixation of fracture. Here, we showed a preoperative and postoperative series of photographs and radiographs of right parasymphysis fracture fixed with 2-D plates [Figures 7-11].

RESULTS

Patients of both groups were evaluated for malunion, non-union, damage to root by screw, implant failure, infection at site, neurosensory deficit, occlusal discrepancy, and postoperative mobility at fracture site.

DISCUSSION

In our study, interpersonal violence accounted for 14.28% of the cases, fall injury accounts for 28.58% of cases of mandible fracture [Table 1] road traffic accidents were responsible for the majority of cases (57.14%) of mandible fractures. This is in accordance with the study by Bormann *et al.*^[7] [Table 1]. Out of 28 patients in our study, 18 were male (64.29%) and 10 (35.71%) were female Table 2. This male dominance was also reported by Haug *et al.*^[8] The age group most commonly affected was 21-30 years (40%). Eight patients had bilateral mandible fracture and 12 had unilateral fracture. The most common site of mandible fracture was parasymphysis (35%) and angle (35%), followed by body (20%) and symphysis (10%) [Table 3, Graph 1].

Among patients in Group II, in 1 patient, there was intraoral exposure of plate and intraoral pus discharge at left lower-third molar region. X-ray OPG of patient shows fractured 2-D miniplate at the left angle [Figure 12]. This complication was treated by removal of implant, intraorally under higher antibiotic coverage. No incidence of plate failure was reported in Group I patients, which coincides with the report by Guimond *et al.*,^[9] on fixation of mandible angle fracture with 3-D plates [Table 4]. Fracture of mandibular angle is associated with highest incidence of postsurgical infection of all mandible fractures reported by Lizuka and Lindquist.^[10,11]

In the angle region where horizontal and vertical rami of mandible meet and where powerful elevator muscles are attached to the ramus, strong distractive forces are created; therefore, to counteract these forces, a strong fixation device is required. In this study, the advantage of 3-D plating system over conventional 2-D miniplates comes from the fact that the screws of the 3-D plates are placed in the box configuration on both sides of the fracture rather than on a single line. Also, a broad platform is created that may increase the resistance to the torsional forces along the axis of the plate. This theory coincides with the study of Alkan *et al.*^[12]

One case of tooth damage at the symphysis region was reported among Group I patients. Vitality testing of the injured tooth was done. Endodontic treatment was carried out for the management of injured tooth. The damage occurred due to the larger size of 3-D plate and insufficient vertical height of anterior mandible. Advantage of conventional 2-D miniplates over 3-D miniplates is their small size and easy adaptability, which minimizes the chances of tooth damage [Table 4].

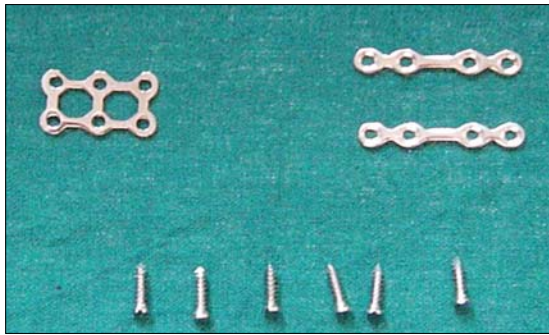


Figure 1: Conventional 2.0-mm S.S miniplates and 3-D S.S plates used in the mandible fracture

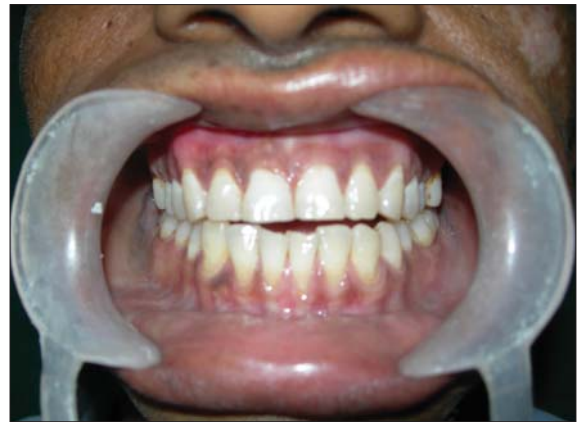

Figure 2: Preoperative photograph of patient with right parasymphysis fracture showing deranged occlusion

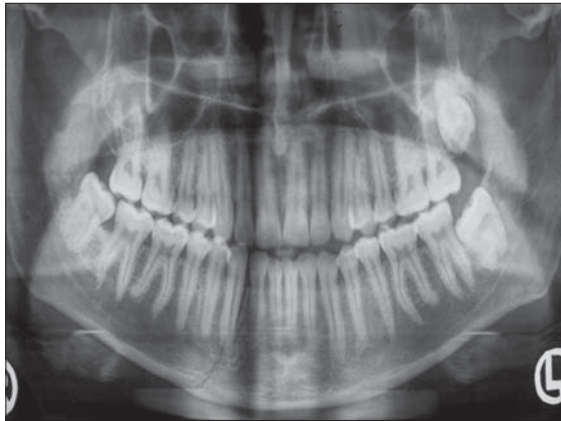

Figure 3: Preoperative OPG show right parasymphysis fracture between right lateral incisor and canine with fracture line runs downward and backward

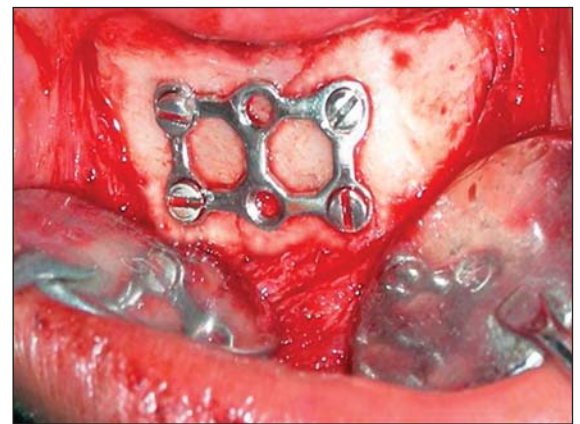


Figure 4: Intraoperative photograph of patient showing reduction and fixation of right parasymphysis fracture site using 2.0-mm, 6-hole, 3-D plates via intraoral degolving incision (Group 1)

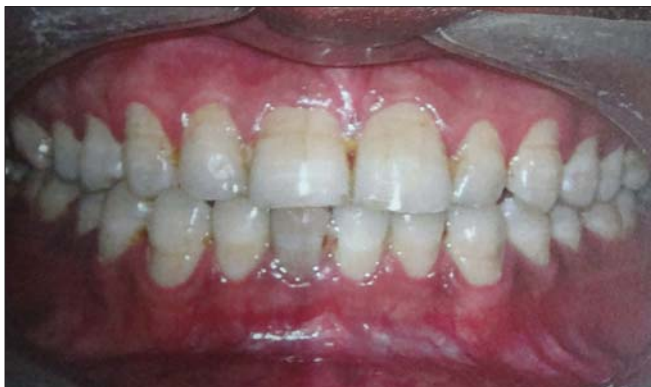

Figure 5: Postoperative photograph of patient with right parasymphysis fracture showing perfect occlusion

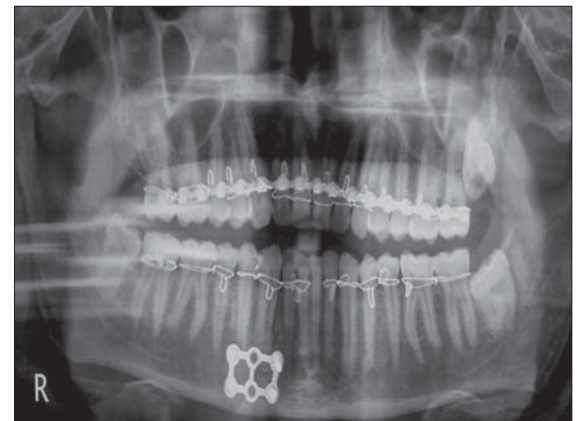


Figure 6: Postoperative OPG showing reduction and fixation of right parasymphysis fracture with 2.0-mm, 6-hole, 3-D plates

The occlusion of patients was checked preoperatively and during the follow-up stages after surgery. Among Group II, 2 patients (both displaced parasymphysis + angle fractures) developed postoperative occlusal discrepancy, which was corrected by postoperative inter-maxillary fixation for 4 weeks. None of the patients of Group I developed occlusal discrepancy [Table 4]. According to Champy, when only one linear conventional plate is applied at the external oblique ridge in cases

of mandibular angle fracture, torsional and bending forces usually cause movement along the axis of the plate with bucco-lingual splaying and gap formation at the inferior border, respectively. This coincides with the study of Gutwald *et al.*,^[13] on angle fracture using various fixation devices. Also, 3-D plates, because

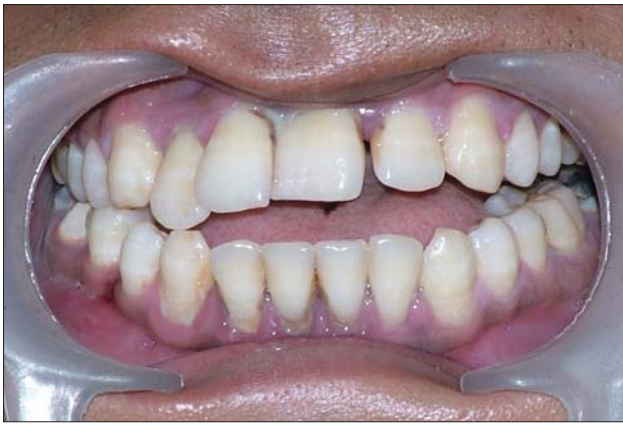

Figure 7: Preoperative photograph of patient with right parasymphysis fracture between right lateral incisor and canine showing anterior and left-posterior open bite

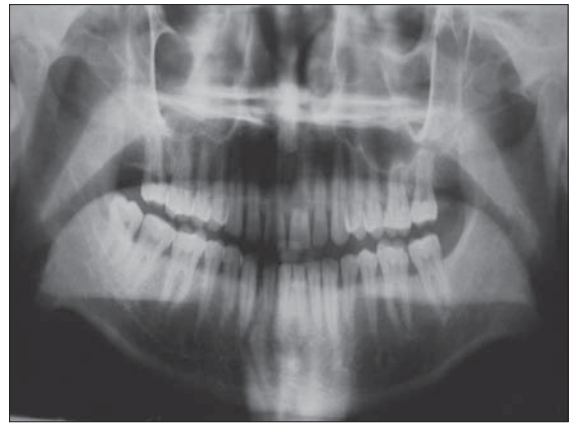

Figure 8: Preoperative OPG show right parasymphysis fracture between right lateral incisor and canine with fracture line runs downward and forward

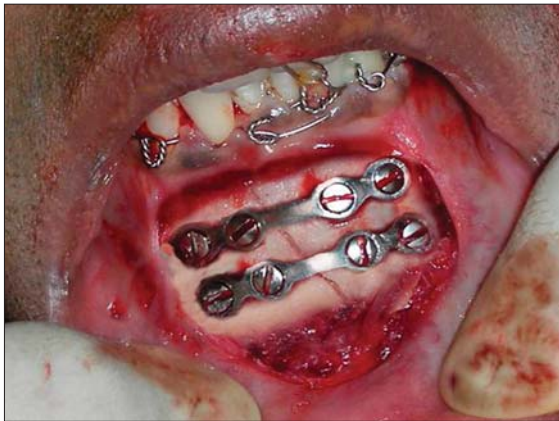


Figure 9: Intraoperative photograph of patient showing reduction and fixation of right parasymphysis fracture site with conventional 2.0-mm, 4-hole with gap miniplates placed along Champy's line of osteosynthesis through intraoral degloving incision

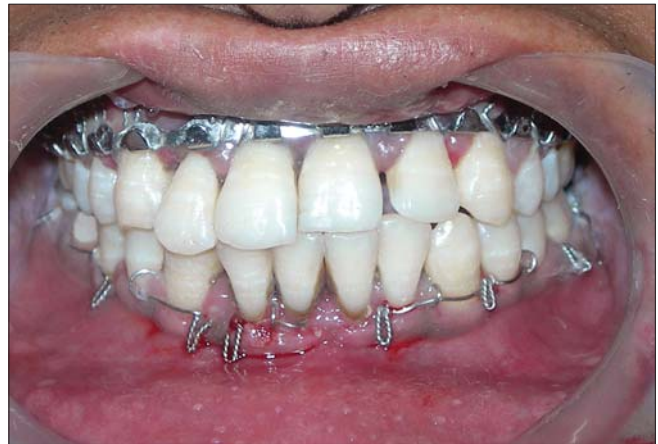

Figure 10: Postoperative photograph of patient with right parasymphysis fracture showing perfect occlusion

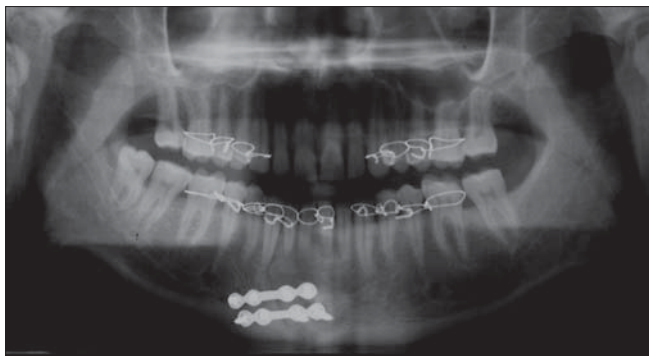


Figure 11: Postoperative OPG shows reduction and fixation of right parasymphysis fracture with 2.0-mm miniplates, 4-hole with gap miniplates, and restoration of occlusion

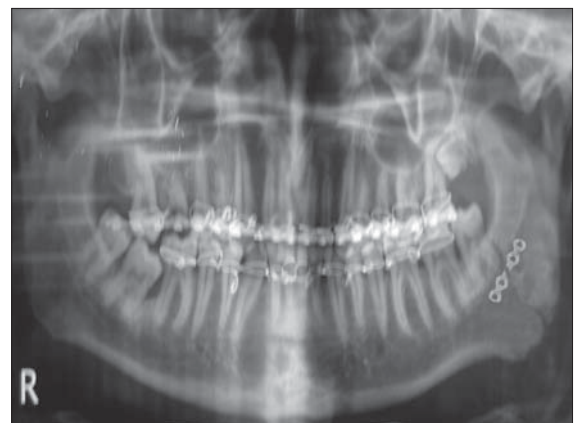

Figure 12: X-ray OPG shows fractured 2.0-mm conventional plate at left angle

of a box-like configuration, provide rigid fixation of fractures that prevent bucco-lingual splaying and gap formation at the fracture site and subsequent occlusal discrepancy; this is the advantage of 3-D miniplates over 2-D miniplates.

Mobility of fractured segments was evaluated in both groups: In Group II, 2 patients (one symphysis and other angle + parasymphysis fracture) had immediate postoperative mobility present at the fracture site, which was corrected by

Table 1: Pattern of etiology of fracture in the present study

Etiology	No. of patients	Percentage
Road traffic accident	16	57.14
Fall	8	28.58
Interpersonal violence	4	14.28
Total	28	100

Our study road traffic accident was the most common cause of mandible fracture (57.14%) and interpersonal violence was least common cause of mandible fracture (14.28%)

Table 2: Gender distribution of patients

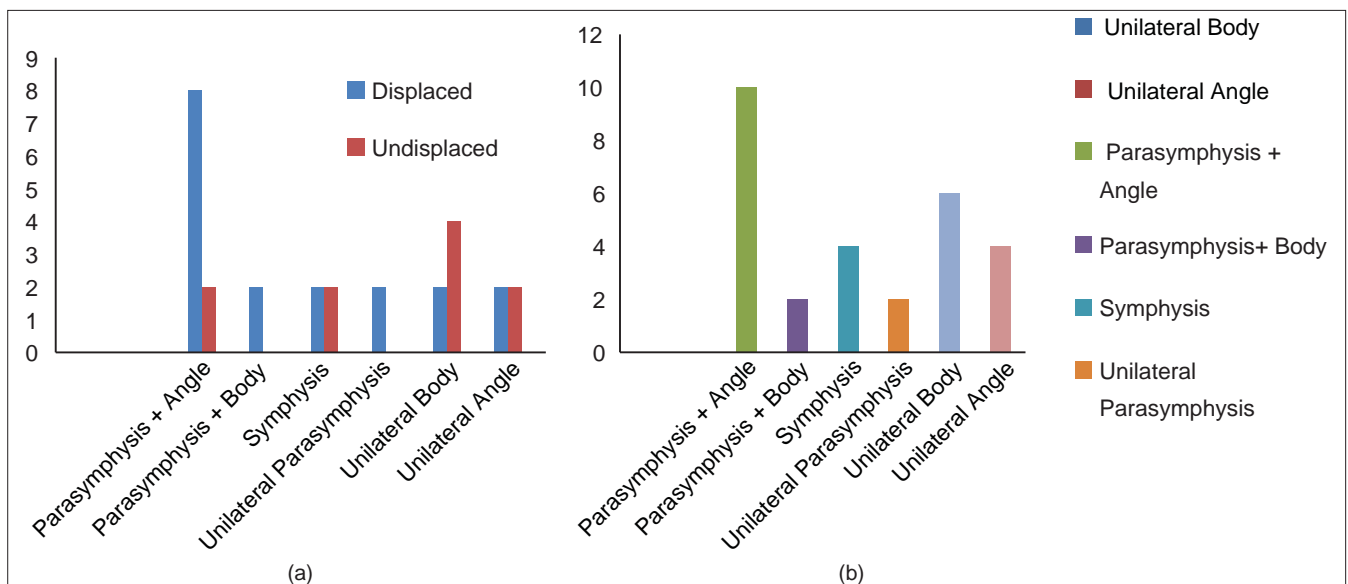
Gender	No. of patients	Percentage
Male	18	64.29
Female	10	35.71
Total	28	100

Our study maximum number of patients were male (64.29%) while female constitute only (35.71%) of total number of cases. Male:female ratio was 1.8:1

Table 3: Distribution of fracture site, favorability of fracture site, methods of fixation of fracture site

Site of fracture	Patients	Favorability of fracture		Method of fixation			
		(DL)	(UN-DL)	Conventional 2-D plates (4 hole with gap)		3-D plates	
				DL	UN-DL	DL	UN-DL
Parasymphysis + angle	10	8	2	4	1	4	1
Parasymphysis + body	2	2	0	1	0	1	0
Symphysis	4	2	2	1	1	1	1
Unilateral parasymphysis	2	2	0	1	0	1	0
Unilateral body	6	2	4	1	2	1	2
Unilateral angle	4	2	2	1	1	1	1

Out of 28 patients in 16 patients (53%) mandible fracture was displaced and in 12 patients (47%) mandible fracture was undisplaced



Graph 1: (a, b) Distribution of fracture site, favorability of fracture site, and methods of fixation of fracture site

postoperative inter-maxillary fixation for 4 weeks. In Group I, none of patients had immediate postoperative mobility present at the fracture site [Table 4]. According to Andrew *et al.*, as 3-D plates are square or rectangular units, they provide increased torsional stability. Also, as the symphysis fractures are under greater degree of torsional strain than any other area of the mandible, 3-D plates provide higher stability in this region.

Duration of surgery was measured from incision to closure of wound. The operating time required for the placement of 3-D plates in the angle region was 20-min extra as compared to

intraoral placement of single conventional 2-D miniplate. This finding coincides with the study of Feledy *et al.*,^[14] who conducted a study on the time taken for the treatment of angle fractures. In the body region, difference was not significant, average time of 7 min more was taken by 3-D plates; whereas, in the symphysis and parasymphysis region, 20 min more was taken for 3-D plate fixation than for 2-D miniplates.

In our study, not a single patient treated by 3-D plate developed infection or plate failure, which is not in accordance with Zix *et al.*,^[15] who reported 1 patient with fractured 3-D plate

Table 4: Comparison of complication between group I and group II

Complications	Group I (3-D plates) 20 fracture site		Group II (2-D plates) 20 fracture site	
	No. of fracture site	%	No. of fracture site	%
Plate failure	0	0	1 patient	6.6
Tooth damage	1 patient	6.6	0	0
Infection	0	0	1 patient	6.6
Occlusal discrepancy	0	0	2 out of 15 patients	13.3
Postoperative mobility	0	0	2 out of 15 patients	13.3
Malunion	0	0	0	0
Non-union	0	0	0	0
Postoperative neurosensory deficit	0	0	0	0

This is a highly significant difference between the two groups as Chi-square of this table ($\chi^2=43$) so $P<0.05$ at 95% confidence interval. In our study occlusal discrepancy and postoperative mobility were the most common complications in Group II patients (13.3%), followed by infection at fracture site (6.6%) and implant failure (6.6%). One patient of Group I had tooth damage (6.6%). No other complication was noted in Group I patients. None of the patients of Group I and Group II developed malunion, non-union, or neuro sensory deficit

that occurred due to reduced inter-fragmentary cross-sectional bone surrounding the fracture site after extraction of molar tooth in angle region, leading to higher torsional forces. Also, an infection rate of 6.6% was reported by Parmar *et al.*^[16] Implant failure (4.54%) and postoperative neurosensory deficit (4.54%) was recorded by Goyal *et al.*^[17] Fixation of mandibular angle fractures with single conventional miniplates at the upper border is associated with complications like infection, malocclusion, and mobility of fracture segments, as studied by Singh *et al.*^[18] Parallel reports has been found in literature in several type of clinical situation.^[19,20]

CONCLUSION

The 3-D plating system has advantages over conventional 2-D miniplates. Quadrangle geometry of plate assures a 3-D stability of fracture sites as it offers good resistance against torque forces, thereby avoiding the need for inter-maxillary fixation, ensuring early restoration of mandibular function, and reduced rate of infection at fracture site postoperatively. Simplicity, malleability, low profile, ease of application, and reduced infection rate are its advantages over conventional 2-D miniplates.

Based on the above, it can be concluded that, to minimize the rate of postoperative complications, for fractures of symphysis, displaced parasymphysis and angle and bilateral mandible fractures, 3-D plates could be a better option than conventional 2-mm miniplates. The small sample size and limited follow-up could be considered as the limitations of this study.

REFERENCES

1. Spiessl B. Rigid internal fixation of fractures of lower jaw. *Reconstr Surg Traumatol* 1972;13:124-40.
2. Champy M, Pape HD. The strasbourg miniplate osteosynthesis. In: Kruger E, Schilli W, editors. *Oral and Maxillofacial Traumatology*. vol. 2. Berlin: Quintessence; 1986. p. 19-43.
3. Michelet FX, Deymes J, Dessus B. Osteosynthesis with miniaturized screwed plates in maxilla-facial surgery. *J Maxillofac Surg* 1973;1:79-84.
4. Cawood JJ. Small plate osteosynthesis of mandibular fractures. *Br J Oral Maxillofac Surg* 1985;23:77-91.
5. Luhr HG. Vitallium Luhr systems for reconstructive surgery of the facial skeleton. *Otolaryngol Clin North Am* 1987;20:573-606.

6. Farmand M, Dupoirieux L. The value of 3-dimensional plates in maxillofacial surgery. *Rev Stomatol Chir Maxillofac* 1992;93:353-7.
7. Bormann KH, Wild S, Gellrich NC, Kokemüller H, Stühmer C, Schmelzeisen R, *et al.* Five-year retrospective study of mandibular fractures in Freiburg, Germany: Incidence, etiology, treatment, and complications. *J Oral Maxillofac Surg* 2009;67:1251-5.
8. Haug RH, Prather J, Indrasano AT. An epidemiologic survey of facial fractures and concomitant injuries. *J Oral Maxillofac Surg* 1990;48:926-32.
9. Guimond C, Johnson JV, Marchena JM. Fixation of mandibular angle fractures with a 2.0-mm 3-dimensional curved angle strut plate. *J Oral Maxillofac Surg* 2005;63:209-14.
10. Iizuka T, Lindquist C. Rigid internal fixation of fracture in angular region of mandible: An analysis of factors contributing to different complications. *Plast Reconstr Surg* 1993;91:265-71.
11. Balaji SM. Condylar fractures – open vs closed reduction: Review of 39 cases. *J Maxillofac Oral Surg* 2003;2:16-84.
12. Alkan A, Celebi N, Ozden B, Bas B, Inal S. Biomechanical comparison of different plating techniques in repair of mandibular angle fractures. *Oral Surg Oral Med Oral Pathol Oral Radiol Endod* 2007;104:752-6.
13. Gutwald R, Alpert B, Schmelzeisen R. Principle and stability of locking plates. Presented at 67th meeting of Keio Medical Society. Tokyo; July 15, 2002.
14. Feledy J, Caterson EJ, Steger S, Stal S, Hollier L. Treatment of mandibular angle fracture with a matrix miniplate: A preliminary report. *Plast Reconstr Surg* 2004;114:1711-6.
15. Zix J, Lieger O, Iizuka T. Use of straight and curved 3-dimensional titanium miniplates for fracture fixation of mandibular angle. *J Oral Maxillofac Surg* 2007;65:1758-63.
16. Parmar S, Meanat S, Raghani M, Kapadia T. Three dimensional miniplates rigid fixation in fracture mandible. *J Maxillofac Oral Surg* 2007;6:14.
17. Goyal M, Marya K, Chawla S, Pandey R. Mandibular osteosynthesis: Comparative evaluation of two different fixation system using 2.0 mm titanium miniplates and 3-D locking plates. *J Maxillofac Oral Surg* 2011;10:32-7.
18. Singh RK, Pal US, Agrawal A, Singh G. Single miniplate osteosynthesis in angle fracture. *Natl J Maxillofac Surg* 2011;2:47-50.
19. Dayi E, Omezli MM. Review of biomechanical experimental studies on different plating techniques of mandibular condyle fractures. *Ann Maxillofac Surg* 2011;1:48-52
20. Rai A. Comparison of single vs double noncompression miniplates in the management of subcondylar fracture of the mandible. *Ann Maxillofac Surg* 2012;2:141-5.

Cite this article as: Sadhwani BS, Anchlila S. Conventional 2.0 mm miniplates versus 3-D plates in mandibular fractures. *Ann Maxillofac Surg* 2013;3:154-9.

Source of Support: Nil, **Conflict of Interest:** None declared.