



## Short Communication

# Coronary sinus as a site for stable temporary atrial pacing to tide over premature ventricular complex–triggered recurrent ventricular fibrillation in a patient with severe left ventricular dysfunction after coronary bypass surgery

Aniruddha Vyas <sup>a,\*</sup>, Yash Lokhandwala <sup>b</sup>

<sup>a</sup> Cardiologist, Medanta Hospital Indore, India

<sup>b</sup> Cardiologist, Holy Family Hospital & Research Center, Mumbai, India

## ARTICLE INFO

## Article history:

Received 12 March 2018

Accepted 25 July 2018

Available online 21 August 2018

## ABSTRACT

Use of atrial pacing has been known, yet underutilized tool for effective temporary pacing whenever needed early after cardiac surgery. The reasons may be frequent failures of epicardial wires (fixed over atria intra-operative) leading to loss of capture. Endocardial atrial pacing sites for temporary pacing are unstable and hence continuous pacing with acceptable thresholds is impossible. We describe a case of ischemic cardiomyopathy and severe left ventricle systolic dysfunction who required atrial pacing post coronary artery bypass grafting (CABG) surgery for around 48–72 hours starting 4th day post operation when he had multiple episodes of ventricular fibrillation (VF) needing many defibrillation shocks. VF episodes were triggered by premature ventricular complexes (PVC) falling on as R on T. Episodes were refractory to anti-arrhythmic drugs and general anesthesia. These PVC were successfully overdriven by atrial pacing by fluoroscopically placing pacing lead in coronary sinus. This led to complete suppression of PVC induced VF for next 48–72 hours while the antiarrhythmic drugs were continued. Subsequently the patient was discharged in stable state. Atrial pacing, though quite valuable during the post-operative period after cardiac surgery, is underutilized, especially when pacing through surgically placed epicardial wire fails. This report is helpful in drawing attention towards coronary sinus (CS) as an alternate site for achieving stable, temporary atrial pacing during the post-operative period. This site can also be utilized for short term dual chamber pacing if required in post-operative state using transvenous CS site for atrial pacing and intraoperatively placed epicardial wire for ventricular pacing.

© 2018 Cardiological Society of India. Published by Elsevier B.V. This is an open access article under the CC BY-NC-ND license (<http://creativecommons.org/licenses/by-nc-nd/4.0/>).

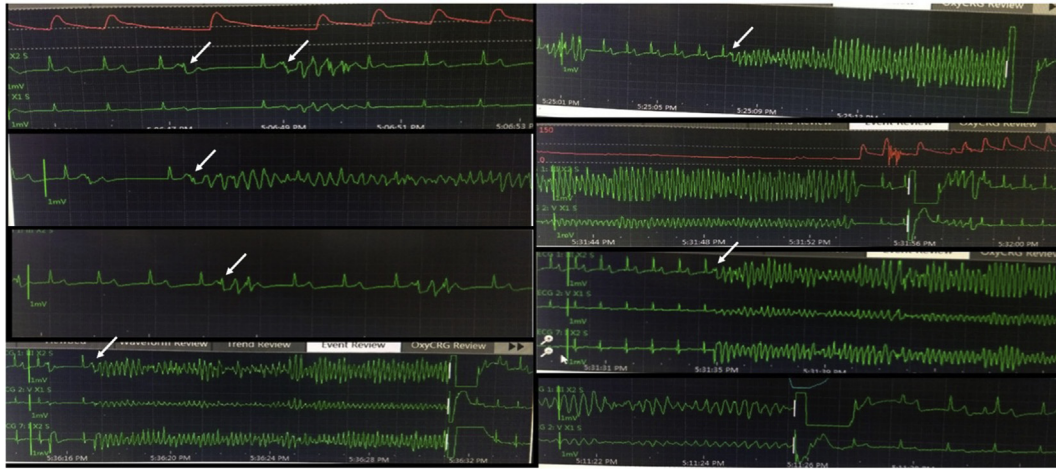
A 45-year-old gentleman presented with recent anterior wall myocardial infarction (AWMI). The baseline electrocardiogram showed changes suggestive of evolved AWMI, and the echocardiogram showed severe left ventricle (LV) dysfunction with an ejection fraction of 0.3. The coronary angiogram revealed critical triple-vessel disease for which he underwent off-pump coronary artery bypass graft (CABG) surgery.

After an initial uneventful recovery, he had recurrent episodes of ventricular fibrillation (VF) requiring multiple defibrillation shocks on the fourth day after CABG. He was given intravenous amiodarone, lignocaine, metoprolol, and magnesium sulfate in usual

protocols and doses. He was put on mechanical ventilation with general anesthesia. Despite this, he continued to have recurrent VF requiring multiple defibrillation shocks (27 in a span of 3 hours!). All episodes were triggered by short-coupled premature ventricular complexes (PVCs) with R-on-T phenomenon (Fig. 1). Ventricular overdrive pacing by the epicardial pacing wire placed during CABG failed to suppress the PVCs and subsequent VF. Epicardial wire for atrial pacing was not capturing even at maximum outputs. Transesophageal echo did not show any new regional wall motion abnormality to suggest new-onset ischemic insult. The patient was shifted to catheterization laboratory for temporary atrial pacing as an attempt to suppress the PVCs. Patient already had a right internal jugular (triple lumen) venous line in situ, so femoral access was sought. Continuous pacing through a lead placed in the right atrium was not possible due to unstable position of the lead in the right atrial (RA) cavity with resultant intermittent loss of capture;

\* Corresponding author. Cardiologist, Medanta Hospital Indore, India.

E-mail addresses: [draniruddhavyas@gmail.com](mailto:draniruddhavyas@gmail.com) (A. Vyas), [yashlokhandwala@hotmail.com](mailto:yashlokhandwala@hotmail.com) (Y. Lokhandwala).




**Fig. 1.** Monitor images of rhythm recordings showing multiple episodes of ventricular fibrillation (VF) requiring defibrillation shocks. All the episodes were triggered by similar morphology short-coupled PVC (white arrow) triggering VF as R-on-T phenomenon.

this occurred despite positioning it in the RA appendage. Hence, the pacing lead was positioned in coronary sinus (CS). The non-deflectable temporary pacing lead could not be negotiated directly, and hence, it was advanced after first placing a deflectable decapolar electrophysiology (EP) catheter in CS and then advancing the temporary lead as a “buddy technique” (Fig. 2, left upper panel). Then, the EP catheter was withdrawn (Fig. 2, left lower panel). Stable continuous left atrial capture was confirmed with acceptable pacing threshold. The patient was put on overdrive atrial pacing at the rate of 110/min. This led to complete suppression of PVC and subsequent VF (Fig. 2, right panel). The patient was kept on mechanical ventilation and general anesthesia for 24 hours and then extubated after weaning over next 36 hours. The atrial pacing rate was reduced slowly at every 4-hour intervals till spontaneous sinus

rhythm persisted, without PVCs. The temporary pacing lead was withdrawn after 72 hours. He was anticoagulated with subcutaneous enoxaparin for deep vein thrombosis prophylaxis during the period of temporary pacing. His remaining hospital stay was uneventful. He was discharged in a stable state.

The PVCs that precede VF initiation have been believed to be the mechanism that triggers VF episodes in arrhythmic storm, and VF recurrence has been avoided by suppressing these PVC by either drugs/pacing/ablation.<sup>1</sup> Analysis of Multicenter Automatic Defibrillator Implantation Trial II-type patients revealed that PVCs triggered 77% of VF episodes, in contrast to a short-long-short sequence found in 23% of patients.<sup>2</sup> Usually surviving Purkinje fibers with shortened action potential duration or reduced amplitude, depolarized membrane potentials, and reduced  $V_{max}$  are



**Fig. 2.** Left upper panel (left anterior oblique fluoroscopic view) shows placement of temporary pacing lead with help of deflectable decapolar electrophysiology catheter as a buddy technique. Left lower panel (left anterior oblique fluoroscopic view) shows after withdrawing decapolar and position of pacing lead in CS. CS, coronary sinus. Right panel shows continuous stable atrial pacing and complete suppression of PVC-triggered VF.

thought to be the source of automatic foci for PVC triggering VF in such scenarios. Polymorphic ventricular tachycardia (VT)/VF in these patients is triggered and possibly maintained by activity originating from the distal Purkinje arborization localized to the border zone of the myocardial infarction (MI) in which tissue heterogeneity is particularly marked. Interestingly, the Purkinje tissue cells have been demonstrated to be able to survive transmural infarction in experimental models, leading to speculation that their proximity to the endocardium allows exposure to cavitary blood. These surviving Purkinje fibers crossing the border zone of the infarct demonstrate heightened automaticity, triggered activity, and supernormal excitability, which, when coupled with prolongation of the action potential duration in this region may result in the necessary milieu for polymorphic VT. At times, reperfusion injury after revascularization is responsible for such arrhythmia. Electrolyte imbalance (especially hypokalemia), hypothermia, and inotropic support may be other causes responsible for ventricular arrhythmia in postoperative state.<sup>3</sup>

If antiarrhythmic drugs and sedation fail to suppress Purkinje-related PVC triggering VF in the early post-MI period, temporary overdrive pacing may be a reasonable simpler alternative to emergency ablation strategies targeting PVC. By overdrive atrial pacing, an automatic focus of PVC may be captured and suppressed or exit block achieved by making the surrounding myocardium refractory. However, the obvious prerequisite for using atrial pacing to suppress ventricular arrhythmias is 1:1 atrio-ventricular (AV) conduction at fast rates, and once this is met, it can be extremely useful in refractory VF triggered by PVCs to reduce the need for recurrent defibrillation while waiting for drug therapy to take effect. Even in patients for whom 1:1 AV conduction is not possible, dual chamber AV sequential overdrive pacing using transvenous CS site and surgically placed epicardial ventricular wire can be tried. Overdrive atrial or a dual-chamber pacing appears superior in this respect to isolated ventricular pacing for two reasons: (i) overdrive ventricular pacing may itself become a source for triggering recurrent ventricular arrhythmia and (ii) ventricular pacing leads to suboptimal cardiac outputs compared with atrial pacing which is more physiological.

Atrial pacing in the early postoperative period may also be helpful in overdrive suppression of atrial flutter/tachycardia or using it as hemodynamically superior AV sequential dual-chamber pacing over isolated ventricular pacing whenever required for bradycardia/heart blocks. Hence, its routine use in almost all (but especially in those with LV dysfunction, high risk of AV block, atrial or ventricular arrhythmias) patients with cardiac surgery is relevant.

The Achilles heel in temporary RA transvenous pacing is unstable position and failure of continuous capture; latter may lead to intermittent PVC triggering VF. Positioning the pacing lead inside the CS has to be careful, and the advancement should be rather passive with beat-to-beat movement of lead, even slight forceful maneuver may lead to CS dissection, especially at the site of valve. For continuous atrial capture, the lead should be fluoroscopically ensured to be in main body of CS; sometimes, a venogram with an Amplatz Left (AL1) catheter may be helpful for delineating CS anatomy. For the same reason, lead placements into a venous branch and hence inadvertent ventricular capture or oversensing of ventricular signals have to be avoided. The CS can be a safe non-traumatic site for stable temporary atrial transvenous (jugular/femoral) pacing, ensuring continuous capture for as long as 72 hours as has been shown in this case with complete suppression of PVCs and resultant VF.

#### Conflict of interest

All authors have none to declare.

#### References

1. Muñoz JJS, Alberola AG, Sánchez JM, et al. Premature ventricular complexes as a trigger for ventricular fibrillation. *Rev Esp Cardiol.* 2010;63:798–801.
2. Moss AJ, Zareba W, Hall JW, et al. Prophylactic implantation of a defibrillator in patients with myocardial infarction and reduced ejection fraction. *N Engl J Med.* 2002;346:877–883.
3. Pinto RP, Romerill DB, Nasser WK, Schier JJ, Surawicz B. Prognosis of patients with frequent premature ventricular complexes and nonsustained ventricular tachycardia after coronary artery bypass graft surgery. *Clin Cardiol.* 1996;19:321–324.