

# Smartwatch detection of ventricular tachycardia: Case series



Joseph Burke, MD,<sup>\*†</sup> Mark C.P. Haigney, MD,<sup>‡</sup> Ryan Borne, MD,<sup>†</sup> Mori J. Krantz, MD<sup>\*†</sup>

From the <sup>\*</sup>Denver Health Medical Center, Denver, Colorado, <sup>†</sup>School of Medicine, University of Colorado, Aurora, Colorado, and <sup>‡</sup>Cardiology Division, Department of Medicine, Uniformed Services University, Bethesda, Maryland.

## Introduction

Worldwide sales of wearable smartwatches have grown at an annual rate exceeding 20%, with 500 million connected devices currently active in 2020 and projected to exceed 1 billion by 2022.<sup>1</sup> The integration of photoplethysmographic (PPG) sensors into smartwatches has accelerated widespread community-based heart rate monitoring. More recent versions of smartwatches combine the PPG sensor—which can detect pulse rate and regularity only—with an actual 1-lead electrocardiogram that allows the recording of lead I. These features, in combination with rhythm analysis algorithms within the device itself, provide explicit results directly to the consumer. This has created an emerging paradigm in population-based heart rhythm monitoring.

Most notably, the Apple Heart Study<sup>2</sup> demonstrated the ability of PPG technology to screen an asymptomatic population for occult atrial fibrillation, with at least theoretic implications for downstream treatment. To date, however, there is a paucity of scientific evidence to support the use of wearable devices for the detection of either symptomatic or malignant arrhythmias. Only 1 previous report has documented the identification of ventricular tachycardia (VT) using an Apple Watch.<sup>3</sup> Herein, we describe 2 cases of symptomatic VT diagnosed using smartwatch technology and confirmed during subsequent electrophysiologic evaluation. To our knowledge, there is no clinical guideline focused on the interpretation and suggested provider actions for symptomatic arrhythmias detected by external smartwatches. The evaluation and reporting of this case series was reviewed and designated exempt from panel review by the Colorado Multiple Institution Review Board (COMIRB 20-0645) for human subjects research.

**KEYWORDS** Apple Watch; Arrhythmia; Photoplethysmographic sensor; Smartwatch; Ventricular tachycardia  
(Heart Rhythm Case Reports 2020;6:800–804)

**Funding:** This research did not receive any specific grant from funding agencies in the public, commercial, or not-for-profit sectors. **Conflicts of Interests:** The authors have no declarations related to this work to disclose. **Address reprint requests and correspondence:** Dr Mori J. Krantz, Denver Health Medical Center, 777 Bannock St, MC 0960, Denver, CO 80204. E-mail address: [mori.krantz@dhha.org](mailto:mori.krantz@dhha.org).

## Case reports

### Case 1

A 60-year-old previously healthy police officer presented with chest discomfort associated with palpitations and light-headedness. He was on a routine patrol in his cruiser at 6 AM when these symptoms started abruptly and persisted for approximately 25 minutes. His Apple Watch recorded a wide complex tachycardia concerning for VT (Figure 1A) and a representative example sinus rhythm (Figure 1B). The paramedics confirmed a rapid tachycardia by pulse; however, by the time a 12-lead surface electrocardiogram (ECG) was performed he was in normal sinus rhythm with T-wave inversions in leads V<sub>1</sub>–V<sub>3</sub> with superior axis ventricular premature complexes (VPC) inconsistent with a right ventricular (RV) outflow tract origin. Coronary angiography demonstrated no evidence of epicardial coronary artery disease. The patient was discharged on metoprolol with a plan to obtain a formal outpatient event monitor to corroborate the putative arrhythmia detected by the smartwatch.

Two weeks later he was rehospitalized with identical symptoms. Telemetry monitoring demonstrated frequent salvos of wide complex tachycardia. Gadolinium-enhanced cardiac magnetic resonance imaging revealed major criteria for arrhythmogenic RV cardiomyopathy, including RV dilation and reduced systolic function with evidence of regional dyskinesia involving the basal-inferior free wall.

The patient subsequently underwent electrophysiology study in which left bundle, left superior axis VT was induced with programmed ventricular stimulation (Figure 2A). Electrophysiologic mapping and radiofrequency ablation terminated VT at the RV inferior base and rendered it noninducible. Electroanatomic mapping was also performed showing abnormal bipolar and unipolar voltage maps (Figure 2B and C). Finally, isoproterenol was infused at a dose of 45 mcg/min, inducing 3 distinct polymorphic ventricular couplets and >5 different VPC morphologies. Based on the 2010 revised Task Force criteria,<sup>4</sup> the patient fulfilled a definitive diagnosis of arrhythmogenic RV cardiomyopathy based upon the cardiac magnetic resonance imaging, ECG findings, and VT with a left bundle superior axis. He underwent implantable defibrillator insertion. The patient has not

## KEY TEACHING POINTS

- Current-generation commercially available wearable technologies, such as the Apple Watch, can detect clinically significant cardiac arrhythmias such as atrial fibrillation. This report demonstrates utility in diagnosing symptomatic ventricular tachycardia.
- As the penetration of wearable technologies increases, physicians including primary care providers and cardiologists could potentially make clinical decisions based upon these data.
- Smartwatches are currently not a replacement for conventional ambulatory rhythm monitoring for asymptomatic surveillance or to make “symptom-rhythm” correlation until noninferiority studies and false-negative/positive rates are reliably established.

experienced further symptoms suggestive of arrhythmia, nor has he reported detection of event recordings on his smartwatch, though he continues to wear it daily on patrol.

### Case 2

A 63-year old male recreational airplane pilot with a history of bileaflet mechanical aortic valve replacement performed 1 decade previously in the setting of bacterial endocarditis presented in 2014 with intermittent palpitations and feelings of an irregular heartbeat. He was subsequently diagnosed with paroxysmal atrial fibrillation and underwent successful catheter ablation. Echocardiography post-ablation demonstrated preserved left ventricular systolic function with a left ventricular ejection fraction of 55% and normally functioning aortic valve prosthesis. He had recurrent symptomatic paroxysmal atrial fibrillation 3 years later and underwent repeat catheter ablation.

Six months following repeat ablation, the patient developed rapid palpitations associated with near syncope. After Holter monitoring failed to capture a symptomatic event, his cardiologist recommended he purchase a smartwatch for home monitoring. Recurrence of his symptoms resulted in a recording suggestive of a wide complex tachycardia and labeled by the device algorithm as “ventricular tachycardia” (Figure 3). Subsequently, Holter monitoring confirmed the presence of a 9% VPC burden and episodes of nonsustained VT. Given that Federal Aviation Authority guidelines require a VPC burden of 2% or less, he underwent successful catheter ablation of an anterolateral papillary muscle focus.

### Discussion

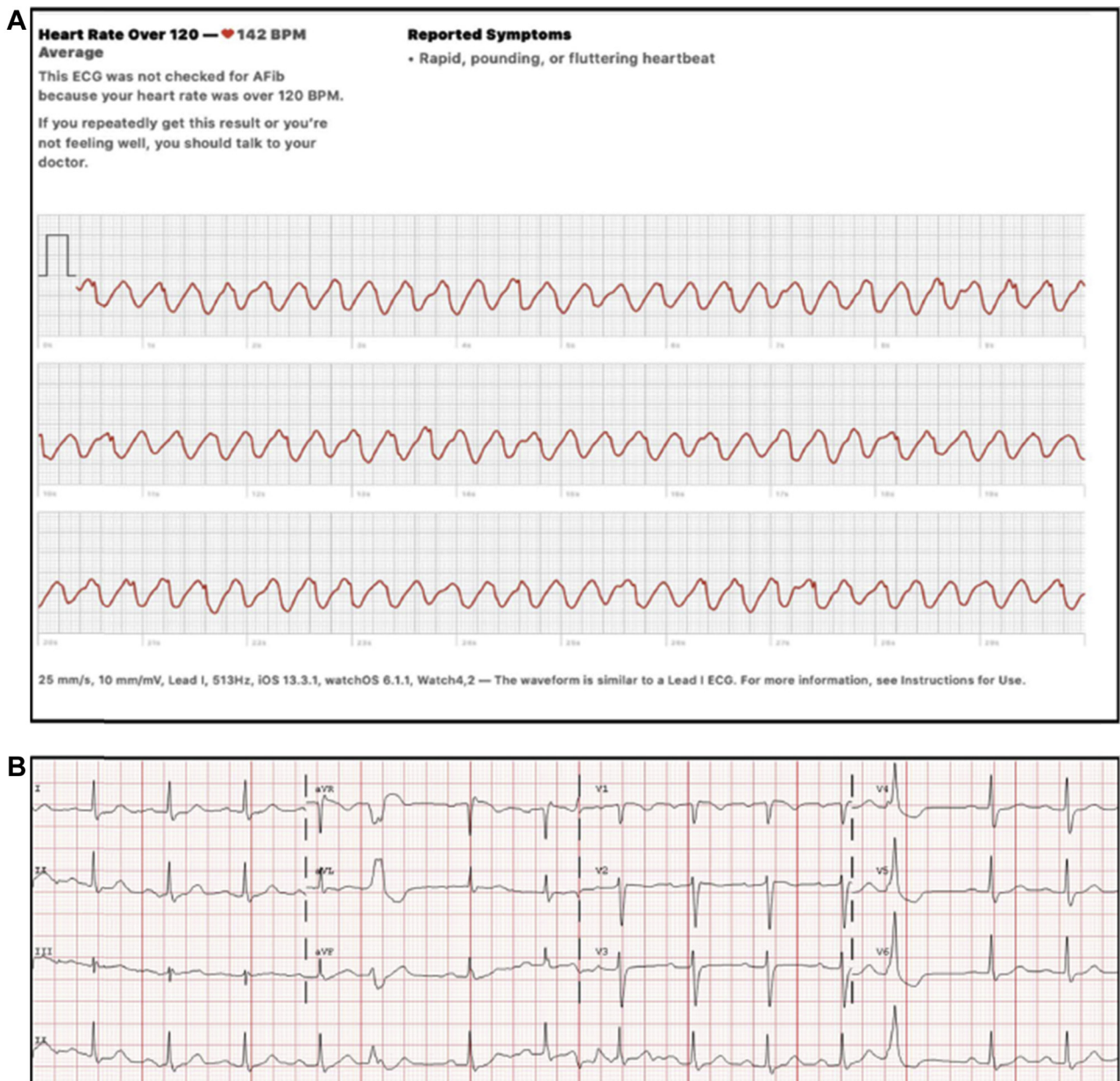
To our knowledge, this is the first published series of smartwatch-detected VT where detailed electrophysiologic

evaluation including electroanatomic ventricular mapping and ablation were performed. In both cases, the device allowed “symptom-rhythm correlation,” which had previously proven elusive. We believe these cases illustrate the potential benefits of this technology, which at the very least prompted patients to seek care; however, significant caveats must be raised.

The smartwatch device offers 2 approaches to the identification of rhythm abnormalities. The first is a PPG sensor, which employs a light-emitting and light-sensitive diode to photometrically detect blood flow. This function allows continuous surveillance of heart rate and inter-beat interval to detect irregularity or tachycardia. In a very large study, the device successfully detected rhythm irregularity in 0.5%, of which approximately 34% proved to have asymptomatic atrial fibrillation.<sup>2</sup> The positive predictive value, however, even among subjects over the age of 65 years, was a modest 0.6 (97.5% confidence interval, 0.56–0.64). Importantly, there was no attempt to determine the false-negative rate, as only individuals with abnormal findings were offered confirmatory electrocardiographic remote-monitoring patches. Given that these results suggest a prevalence of 3.2% in the over-65-year cohort, it is possible that the device missed half of cases based on epidemiologic estimates of the prevalence in the general population.<sup>5</sup> With regard to atrial fibrillation, failure to detect asymptomatic events may lead to inappropriate reassurance of patients and physicians and failure to institute anticoagulation.

The second function provided by the smartwatch is a single-lead ECG capture. Operation of the ECG requires the subject to activate the program and to touch the electrode on the device with the opposite hand. As shown in the cases described herein, the resulting recording may be of sufficient quality to make a provisional arrhythmia diagnosis in addition to changes in the QRS axis (the waveform on the Apple Watch is similar to precordial lead 1). The important point, however, is that activation of the ECG required the subject’s awareness of a symptom and the ability to perform at least 2 steps. As demonstrated by the subsequent Holter in the second patient, the subject was having a relatively high burden of ventricular arrhythmia, something not identified by the device’s PPG sensor and critical for Federal Aviation Authority clearance.

Smartwatch technology is therefore an adjunct to conventional rhythm monitoring. It allows patients to monitor their symptoms, but cannot replace conventional patch recorders. In our experience, symptoms are not always a reliable guide to identifying the presence or absence of significant arrhythmias. Episodes of nonsustained VT or atrial fibrillation, for instance, may not always be symptomatic. It is therefore potentially hazardous to rely solely upon symptom-driven monitoring to identify clinically significant arrhythmias. Finally, the incidence of artifact using the smartwatch ECG, to our knowledge, is unknown.



**Figure 1** Apple Watch recording of symptomatic ventricular tachycardia. **A:** Apple Watch recording demonstrating a regular, wide complex tachycardia. The patient reported symptoms of rapid, pounding, or fluttering heartbeat. **B:** Apple Watch recording in sinus rhythm without symptoms.

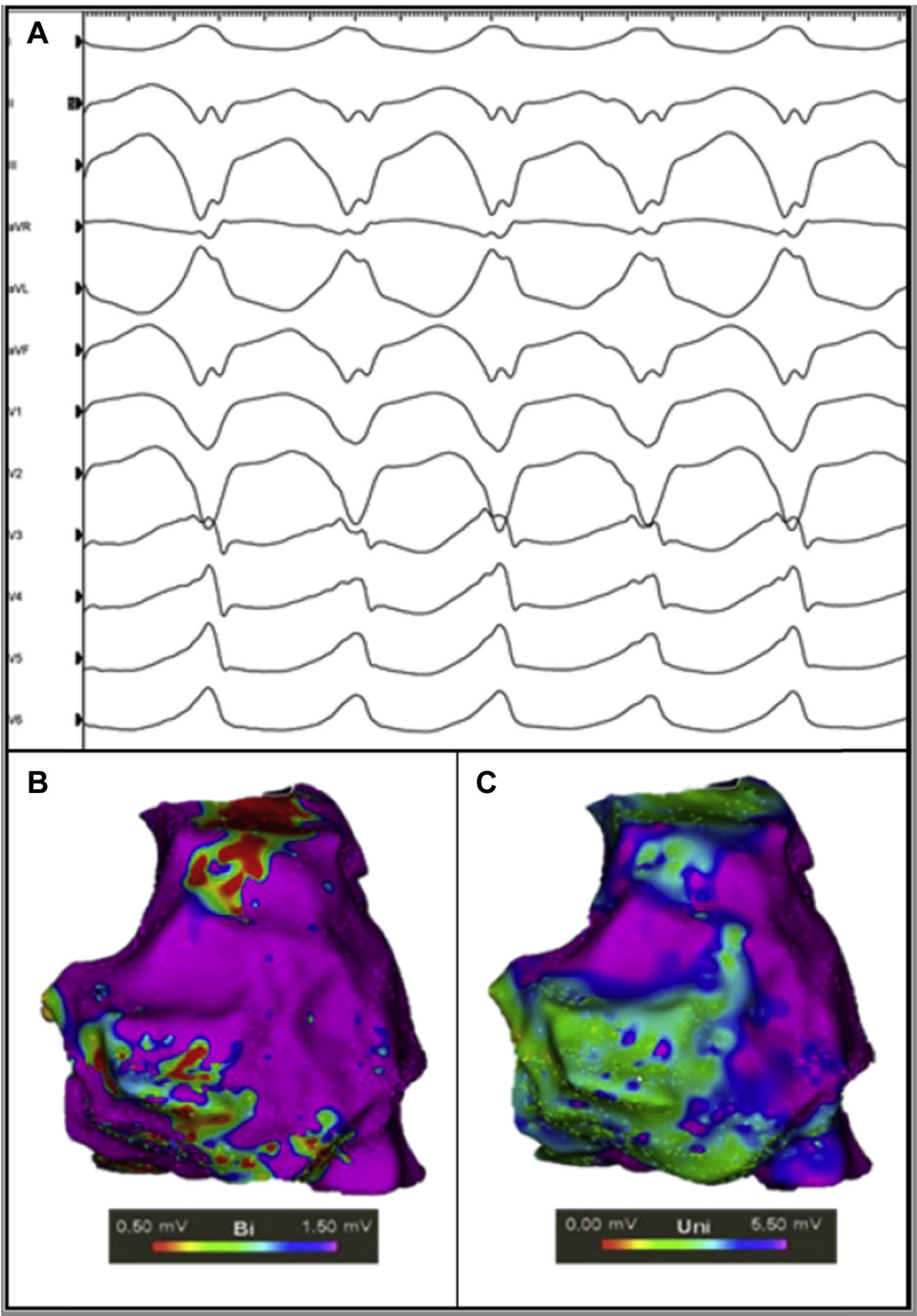
## Conclusions

This series highlights that the detection of symptomatic arrhythmias, even potentially malignant VT, will increasingly be brought to the attention of cardiology specialists. Detection by the Apple Watch of cardiac ischemia,<sup>6</sup> supraventricular tachycardia,<sup>7</sup> and atrial fibrillation<sup>2</sup> has been described but, to date, has not been endorsed as a diagnostic rhythm detection approach by the Heart Rhythm Society<sup>8</sup> or American and European Societies of Cardiology. With the ever-increasing penetration of wearable monitors in the general population, there will be a large volume of data available to physicians to help diagnose and manage arrhythmias in their patients. The average American, particularly among the

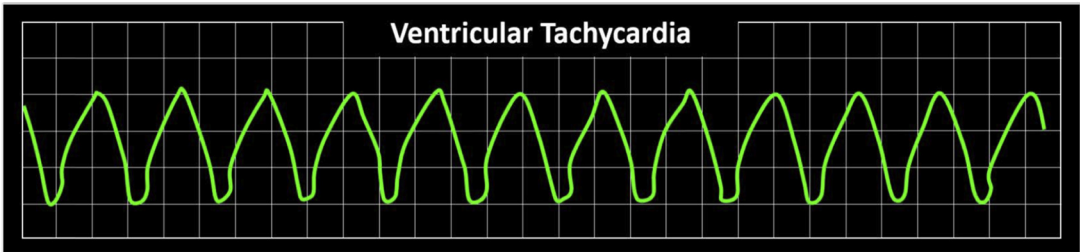
millennial generation, appears to be perpetually “connected” via internet and social media and to utilize a myriad of digital platforms. Currently 83% of Americans owns a smartphone,<sup>1</sup> and many devices provide the ability to monitor footsteps, caloric expenditure, blood pressure, and heart rhythm.

We suspect that clinicians with limited technology savvy might benefit from a consensus statement on the platforms, sensor quality, and comparability between wearable smart devices and FDA-approved medical monitoring platforms, including Holter monitor as a gold standard. Whether existing publicly available proprietary software algorithms for rhythm assessment are appropriate for clinical adjudication is not established. Moreover, the comparability to internally





**Figure 2** Inducible ventricular tachycardia (VT) during electrophysiology study. **A:** Inducible VT with a left bundle branch, superior axis, meeting major criteria for arrhythmogenic right ventricular cardiomyopathy and matching the wide complex tachycardia recording obtained from the Apple Watch in [Figure 1](#). **B,C:** Bipolar (**B**) and unipolar (**C**) electroanatomic voltage maps of the right ventricle in the right anterior oblique projection. A larger region of abnormal voltage (green) is displayed on the unipolar voltage map at the basal-mid right ventricular free wall.



**Figure 3** Ventricular tachycardia recorded on smartwatch. Representative rhythm obtained by the patient during symptoms, with device output describing the arrhythmia.

implanted heart rhythm monitoring systems is an area for clarification. Future studies addressing these uncertainties seem clearly warranted.

## References

1. Statista. Number of connected wearable devices worldwide by region from 2015 to 2022. Available at <https://www.statista.com/statistics/490231/wearable-devices-worldwide-by-region/>. Accessed March 27, 2020.
2. Perez MV, Mahaffey KW, Hedlin H, et al. Large-scale assessment of a smartwatch to identify atrial fibrillation. *N Engl J Med* 2019;381:1909–1917.
3. Ringwald M, Crich A, Beysard N. Smart watch recording of ventricular tachycardia: Case study. *Am J Emerg Med* 2020;38:849.e3–849.e5.
4. Marcus FI, McKenna WJ, Sherrill D, et al. Diagnosis of arrhythmogenic right ventricular cardiomyopathy/dysplasia: proposed modification of the Task Force criteria. *Circulation* 2010;121:1533.
5. Feinberg WM, Blackshear JL, Laupacis A, Kronmal R, Hart RG. Prevalence, age distribution, and gender of patients with atrial fibrillation. Analysis and implications. *Arch Intern Med* 1995;155:469–473.
6. Ángel Cobos Gil M. Novel use of Apple Watch 4 to obtain 3-lead electrocardiogram and detect cardiac ischemia. *Perm J* 2020;24. <https://doi.org/10.7812/TPP/19.202>. Epub 2020 Jan 24.
7. Hwang J, Kim J, Choi K-J, et al. Assessing accuracy of wrist-worn wearable devices in measurement of paroxysmal supraventricular tachycardia heart rate. *Korean Circ J* 2019;49:437–445.
8. Slotwiner D, Varma N, Akar JG, et al. HRS Expert Consensus Statement on remote interrogation and monitoring for cardiovascular implantable electronic devices. *Heart Rhythm* 2015;12:e69–e100.