

CASE REPORT

Intraosseous calcifying epithelial odontogenic tumor in a case with multiple myeloma

Shanmuga Priya S, Ravikumar A¹, Krishnarathnam K², Rajendiran S

Departments of Pathology and ¹ENT, ²Consultant Hematologist, Sri Ramachandra University, Porur, Chennai - 600 116, India

Address for correspondence:

*Dr. Shanmuga Priya S,
Department of Pathology,
Sri Ramachandra University,
Porur, Chennai - 600 116, India.
E-mail: nikhila166@hotmail.com*

DOI: 10.4103/0973-029X.48742

ABSTRACT

Calcifying epithelial odontogenic tumor (CEOT), also known as Pindborg tumor, is a rare benign odontogenic tumor of locally aggressive behavior. It is more common in the posterior part of the mandible of adults, typically in the fourth to fifth decades. Its origin as well as its true malignant potential is not clearly known. It usually starts as a painless swelling and is often concurrent with an impacted tooth. A case of CEOT in a 55-year-old man with multiple myeloma is presented. Clinical, radiological, and pathologic findings are discussed.

Key words: Amyloid, calcifying epithelial odontogenic tumor, maxilla, multiple myeloma

INTRODUCTION

Nearly 200 cases of calcifying epithelial odontogenic tumor have been reported in literature since Pindborg described it as a separate pathologic entity in 1955. It has been identified under different denominations, such as, ameloblastoma of unusual type with calcification, calcifying ameloblastoma, malignant odontoma, cystic complex odontoma, and has also been considered as a variant of simple ameloblastoma.^[1] The eponym Pindborg tumor was first introduced to the literature in 1967, to describe this interesting and unique odontogenic tumor. The calcifying epithelial odontogenic tumor is a benign odontogenic tumor of epithelial origin that accounts for approximately 1% of all odontogenic tumors.^[1] It is more common in the posterior part of the mandible of adults in the fourth to fifth decades.^[2] There is no gender predilection. It is characterized by squamous epithelial cells, calcifying masses, and homogeneous acellular material admixed with the tumor epithelium and stroma that have been identified as amyloid.^[3] The origin of this neoplasm is not clearly known, although it is generally accepted to be derived from oral epithelium, reduced enamel epithelium, stratum intermedium or dental lamina remnants.^[1-3] The differential diagnosis for CEOT should include adenomatoid odontogenic tumor (AOT), calcifying odontogenic cyst (COC), ameloblastic fibro odontoma (AFO), odontoma, and in our case amyloidoma. This article describes a case of CEOT involving the left maxilla associated with multiple myeloma in a middle-aged patient. The correlations between clinical, radiological, and histological patterns are discussed and a brief review of the literature is presented.

CASE REPORT

A 55-year-old man presented at the ENT Department of

Sri Ramachandra University with a one-and-a-half year history of painless left nasal swelling. It was hard in consistency, gradually increasing in size to attain the current size of 4 cm. He was diagnosed to have multiple myeloma stage IIIa in 2004, for which he underwent chemotherapy for a year. He again developed back pain and left hip pain for which he took radiotherapy. He underwent functional endoscopic sinus surgery for sinusitis at another institution. He had a fall in 2008, and underwent left bipolar hemiarthroplasty and left lateral rhinotomy for the nasal mass. Computed tomography (CT) imaging of the maxillofacial region revealed a rounded heterogeneous mass over the left side of the nasal dorsum and frontal process of the left maxilla. The lesion contained areas of amorphous calcifications and ossifications [Figure 1]. Bone marrow aspirate and biopsy were consistent with a diagnosis of multiple myeloma (36% plasma cells). Protein electrophoresis

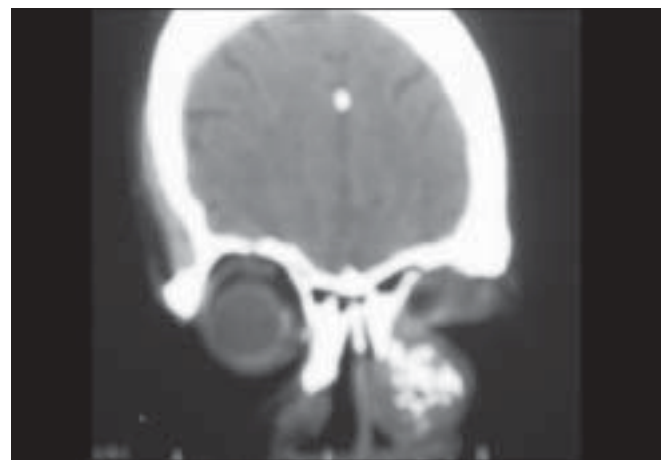


Figure 1: CT imaging of the maxillofacial region shows a heterogeneous mass over the left side of the nasal dorsum and frontal process of the left maxilla

and immunofixation confirmed the myeloma band. The tumor was enucleated under general anesthesia. Intra-operatively, a mass was found to be over the left side of the dorsum of the nose and the frontal process of the maxilla was eroded. Specimens were sent for pathological examination.

Histopathological examination revealed a well-circumscribed neoplasm, predominantly made up of acellular eosinophilic material, arranged as nodules, with extensive calcification and ossification [Figure 2, Figure 3]. Increased number of osteoclast type of giant cells was noted admixed with the acellular material [Figure 4]. Occasionally individual and cords of squamoid cells were seen with nuclear pleomorphism [Figure 5, Figure 6]. No mitotic activity was evident. Plasma cells were not present. Congo red stained the acellular material, confirming the amyloid nature [Figure 7]. The acellular material was negative for cytokeratin stain by immunohistochemistry. With these features, a differential diagnosis of amyloidoma and CEOT was entertained. The presence of extensive calcification, ossification, osteoclast type of giant cells, and occasional atypical squamoid cells, strongly favored a diagnosis of CEOT.

DISCUSSION

Pindborg, in 1955, first categorized this tumor as a distinct histopathological entity. Previously, the uncertainty regarding the histological characteristics of CEOT was reflected in the variety of terms for the disease, including unusual ameloblastoma, cystic odontoma, and adenoid adamantinoma. Pindborg tumor is a rare, benign, but locally aggressive odontogenic tumor,^[1] which accounts for less than 1% of all odontogenic tumors.^[2,3] Most investigators believe that the tumor cells originate from the stratum intermedium of the normal dental germ.^[4,5] This idea is based on the morphological similarity of the tumor cells to the normal cells of the stratum intermedium, and high activity of alkaline phosphatase and adenosine triphosphate.^[5] CEOT occurs most commonly between 20 and 60 years of age with the mean age around 40 years. The distribution among men and women is equal. Most investigators agree that the central type is usually located in the premolar and molar regions with a mandibular to maxillary ratio of 2:1 or 3:1.^[6] The literature reports that this intraosseous tumor usually manifests as a painless swelling that causes slow bone expansion. When located in the maxilla, patients may sometimes complain of nasal stuffiness, epistaxis, and headache.^[1] Few (5%) extra osseous cases have been described, all of which have been involved peripherally in the anterior maxillary or mandibular gingiva.^[7-9] Fifty-two percent of the reported cases have been associated with an unerupted or embedded tooth. In the index case no tooth was associated. There is a wide variation in the clinical, radiological, and histological aspects. The tumor most commonly appears as either a diffuse or a well-circumscribed unilocular radiolucent area. In some cases, the lesion becomes multilocular with a honeycomb pattern. In others, multiple radio-opacities are seen within the radiolucent area. Some tumors are amyloid

rich, while others demonstrate epithelial predominance. Calcification is characteristic, but noncalcifying variants also occur. Lack of calcification is more common in extraosseous tumors. There are two cases of noncalcifying variants of CEOT reported so far. Clear cell variants can also occur. There is no doubt that the epithelial cells of CEOT are of squamous epithelial origin, as is manifested by their morphological and immunohistochemical characteristics.^[5] An amyloid deposit is well documented in association with squamous cell carcinoma at different locations namely; skin, vagina, uterine cervix, and nasopharynx. Some reports have indicated that the squamous cell carcinoma associated with amyloid is immunoreactive for cytokeratin, and amyloid is regarded as the degradation product of keratin. It is also known that in primary cutaneous amyloidosis, the amyloid is derived from filamentous degeneration of keratin filaments. Therefore, it is reasonable to regard all these findings, including CEOT amyloid, as similar expressions of the same process, that is, filamentous degeneration of keratin and conversion into amyloid. With this view and since Pindborg tumor is an odontogenic tumor, one draws back to previous suggestions that the CEOT amyloid is somehow connected to enamel formation, which is related to keratin.^[10]

Another idea that emerges from the analysis of the cytokeratin staining pattern of amyloid is the concept of aging. This thought is based on several observations, among which is the resemblance between the cytokeratin staining pattern of the amyloid and the epithelial gland-like structures of the tumor. It seems that the tumor passes through various stages of development, commencing with epithelial degeneration and conversion of keratin filaments into amyloid. At first, the amyloid is periodic acid-Schiff-negative and stains positively for cytokeratin. However as it ages and the amyloid deposits coalesce into globules, the amyloid loses its immunoreactivity for cytokeratin and becomes PAS-positive. At this stage, the amyloid also mineralizes and gives rise to calcifications that exhibit the Liesegang ring phenomenon. The idea of aging has been proposed in the past, but it gains a new dimension now that it relies on more facts. However the relative significance and contribution of keratin and basement membrane protein to the development of CEOT-associated amyloid are still not clear. It is for future studies to reveal this and other secrets concerning this rare and unique tumor.

The closest differential diagnosis of CEOT in the present case is amyloidoma of the bone,^[11] which is a rare condition characterized by the massive destructive deposition of AL amyloid in bones. Interestingly, the present case also carried a diagnosis of multiple myeloma. Although extensive amyloid was present, plasma cells were not seen in the maxillary lesion. This along with the other features, mentioned wide supra, favored a diagnosis of CEOT. The literature search depicts 200 cases of CEOT in the jaw and only two cases in case of amyloidoma. None of the CEOT was associated with any history of plasma cell neoplasm. Table 1 depicts the




Figure 2: Photomicrograph showing acellular eosinophilic material arranged as nodules with ossification (H and E, 20x)




Figure 3: Photomicrograph showing acellular eosinophilic material arranged as nodules with extensive calcification (H and E, 20x)

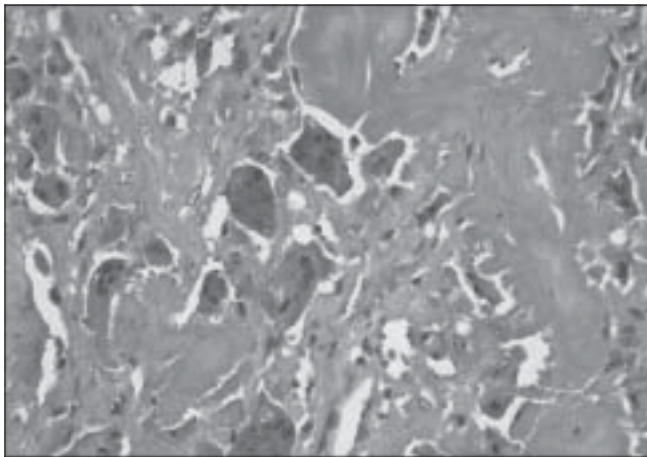


Figure 4: Photomicrograph showing osteoclast type of giant cells admixed with acellular material (H and E, 20x)

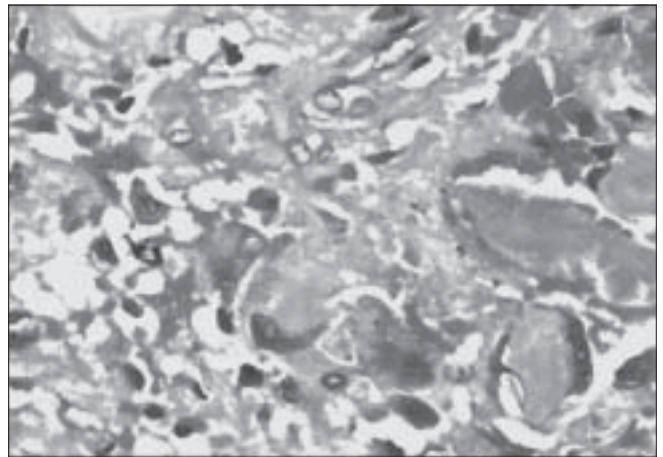


Figure 5: Photomicrograph showing cords of squamoid cells with nuclear pleomorphism (H and E, 20x)

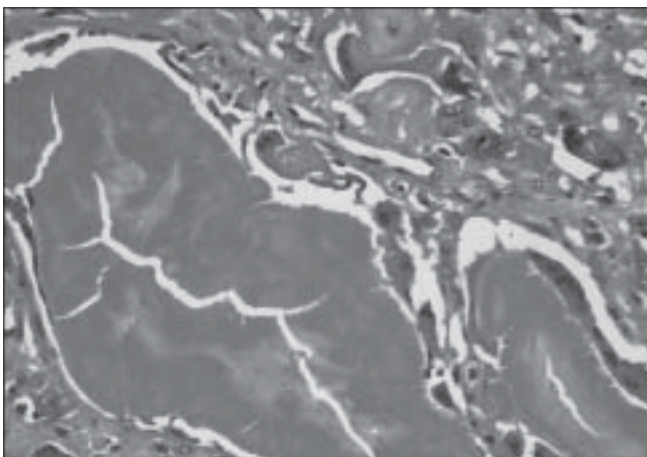


Figure 6: Photomicrograph showing cords of squamoid cells with nuclear pleomorphism and acellular material (H and E, 40x)

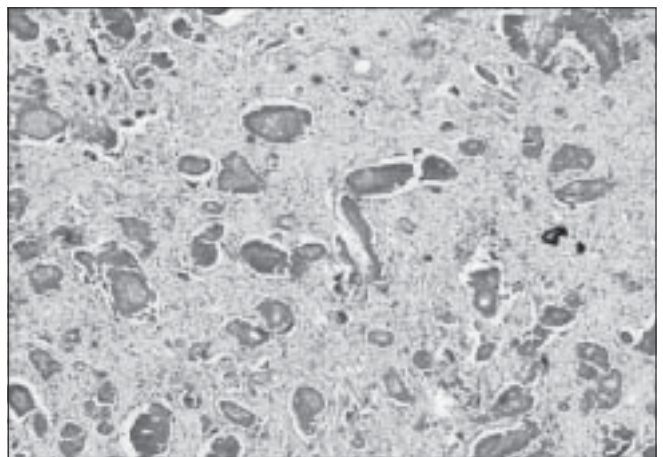


Figure 7: Photomicrograph showing acellular material arranged as nodules (Congo red, 20x)

Table 1: Differences between CEOT and amyloidoma

Features	CEOT	Amyloidoma
Epithelial cells	Present	Infrequent/absent
Giant cells	Osteoclastic type	Foreign body type
Calcifications	Frequent	Rare
Ossifications	Frequent	Rare
Plasma cells	Absent	Present
Amyloid	Present	Present

differences between amyloidoma and CEOT.

The deposits in amyloidoma proved to be composed of AL amyloid showing KMNo4-resistant congophilia. Immunohistochemistry showed Immunoglobulin IgG (lambda), IgG (kappa), and IgM (lambda) monoclonality of the plasma cells, and lymphoid infiltrate.

The treatment for CEOT has ranged from simple enucleation or curettage to radical and extensive resection, such as, hemimandibulectomy or hemimaxillectomy. In the present case lateral rhinotomy was done. The prognosis of CEOT is good with infrequent recurrence. Malignant behavior is extremely rare; only two cases have been reported in the literature so far.^[12] Although it has not been established in the literature, five years should be the absolute minimum follow-up necessary to assess the behavior of this type of odontogenic tumor. Overall, a range of clinical, imaging, and histopathological findings should be used to help in the diagnosis of CEOT and to evaluate its extension to different sites.

REFERENCES

1. Deboni MC, Naclério-Homem Mda G, Pinto Junior DS, Traina AA, Cavalcanti MG. Clinical, radiological and histological features of calcifying epithelial odontogenic tumor: Case report. *Braz Dent J* 2006;17:171-4.
2. Kaplan I, BuchnerA, Calderon S, Kaffe I. Radiological and

clinical features of calcifying epithelial odontogenic tumor. *Dentomaxillofac Radiol* 2001;30:22-8.

3. Cheng YS, Wright JM, Walstad WR, Finn MD. Calcifying epithelial odontogenic tumor showing microscopic features of potential malignant behaviour. *Oral Surg Oral Med Oral Pathol Oral Radiol Endod* 2002;93:287-95.
4. Bouckaert MM, Roubenheimer EJ, Jacobs FJ. Calcifying epithelial odontogenic tumor with intracranial extension: Report of a case and review of literature. *Oral Surg Oral Med Oral Pathol Oral Radiol Endod* 2000;90:656-62.
5. Philipson HP, Reichart PA. Calcifying epithelial odontogenic tumor: Biological profile based on 181 cases from the literature. *Oral Oncol* 2000;36:17-26.
6. Houston GD, Fowler CB. Extrasosseous calcifying epithelial odontogenic tumor: report of two cases and review of the literature. *Oral Surg Oral Med Oral Pathol Oral Radiol Endod* 1997;83:577-83.
7. Ng KH, Siar CH. A clinic pathological and immunohistochemical study of the calcifying epithelial odontogenic tumor (Pindborg tumor) in Malaysians. *Laryngol J Otol* 1996;110:757-62.
8. Baunsgaard P, Lontoft E, Sorensen M. Calcifying epithelial odontogenic tumor: An unusual case. *Laryngoscope* 1983;93:635-8.
9. Wood NK, Goaz PW. Differential diagnosis of oral and maxillofacial lesions 5th ed. St.Louis: Mosby Year book; 1997. p. 428-31.
10. Aviel-Ronen S, Liokumovich P, Rahima D, Polak-Charcon S, Goldberg I, Horowitz A. The amyloid deposit in calcifying epithelial odontogenic tumor is immunoreactive for cytokeratins. *Arch Pathol Lab Med* 1999;124:872-6.
11. Pambuccian SE, Horyd ID, Cawte T, Huvos AG. Amyloidoma of bone: A plasma cell neoplasm: Report of three cases and review of the literature. *Am J Surg Pathol* 1997;21:179-86.
12. Veness MJ, Morgan G, Collins AP, Walker DM. Calcifying epithelial odontogenic tumor with malignant transformation and metastatic spread. *Head Neck* 2001;23:692-6.

Source of Support: Nil, **Conflict of Interest:** None declared.