

# Diagnosis and Management of Primary Prostatic Signet Ring Cell Carcinoma: Single-Center Experience

American Journal of Men's Health  
March-April 1–8  
© The Author(s) 2022  
Article reuse guidelines:  
sagepub.com/journals-permissions  
DOI: 10.1177/15579883221087839  
journals.sagepub.com/home/jmh



Pu Li<sup>1\*</sup>, Zihan Zhou<sup>2\*</sup>, Meiling Bao<sup>3\*</sup>, Jie Li<sup>1</sup>, Xiaoxin Meng<sup>1</sup>,  
Bianjiang Liu<sup>1</sup>, and Min Tang<sup>1</sup> 

## Abstract

The purpose of the study was to retrospectively summarize the diagnosis and management of 10 primary prostatic signet ring cell carcinoma (PPSRCC) cases in our center. Ten PPSRCC patients diagnosed at the First Affiliated Hospital of Nanjing Medical University from November 2014 to December 2020 were included. Clinical characteristics, image features, therapeutic procedures, histological diagnosis, and outcomes were retrospectively analyzed. All patients received prostate-specific antigen (PSA) examination preoperatively. Nine of them accepted multiparametric magnetic resonance imaging (mpMRI) due to elevated PSA value, and further biopsied. Among them, five patients were diagnosed as prostatic adenocarcinoma and the other four cases were found a mixture of signet ring cell carcinoma (SRCC) and adenocarcinoma. Furthermore, gastrointestinal endoscope and abdominal computed tomography (CT) did not find SRCC originating in gastrointestinal tract. Therefore, these cases were considered to be PPSRCC. Nine patients accepted laparoscopic or robot-assisted RP. Only one patient with normal PSA adopted transurethral resection of the prostate. Postoperative pathological results confirmed SRCC mixed with prostatic adenocarcinoma in nine cases, and only one patient with pure SRCC. After surgery, nine patients received adjuvant hormone therapy, one of which accepted radiotherapy simultaneously. The patient with pure SRCC did not accept any adjuvant therapy postoperatively. During a mean follow-up of 31.9 months, only four patients were alive without disease progression. In summary, PPSRCC is a rare malignant tumor with few specific symptoms, rapid disease progression, and poor prognosis and is frequently accompanied by high-grade prostatic adenocarcinoma patterns. There is still no clear and effective strategy to improve the prognosis.

## Keywords

primary prostatic signet ring cell carcinoma, diagnosis, treatment, prognosis

Received November 28, 2021; revised February 25, 2022; accepted February 28, 2022

## Introduction

Signet ring cell carcinoma (SRCC) is a specific type of mucinous adenocarcinoma that occurs mostly in the gastrointestinal tract. Primary prostatic signet ring cell carcinoma (PPSRCC) is rare and highly malignant and has been classified as a subtype of high-grade adenocarcinoma rather than a separate histological diagnosis. Uyama and Moriwaki (1979) first described this disease. So far, about 100 cases have been reported in relevant literatures, accounting for about 2.5% of prostate adenocarcinoma (Hashimoto et al., 2011). Most of the patients are middle-aged and elderly men. The clinical

symptoms of PPSRCC are similar to those of typical poorly differentiated prostate cancer, mainly including frequent urination, urgent urination, dysuria, and lower abdominal pain. Classical type has a worse prognosis compared with prostatic adenocarcinoma (Kuroda et al., 1999).

Herein, we retrospectively analyzed the clinical manifestation, therapeutic procedures, histological diagnosis, and outcomes of 10 PPSRCC cases treated in our center from 2014 to 2020. Moreover, we performed a brief literature review to the diagnosis and management of PPSRCC to provide a comprehensive understanding of this uncommon tumor.



## Materials and Methods

### Patients

Ten patients with SRCC of prostate were diagnosed by postoperative pathology in the First Affiliated Hospital of Nanjing Medical University from November 2014 to December 2020. We retrospectively reviewed our experience in diagnosis and treatment. We summarized and compared the age, clinical symptoms, radiographic findings, pathological findings, therapeutic method, and prognosis of these patients. All procedures carried out in this study were in line with the Declaration of Helsinki (Revised 2013) and this study was approved by the Ethics Committee of the First Affiliated Hospital of Nanjing Medical University (No. 2020-SR-148) and written informed consent for publication of the patients' information and images was entirely obtained.

### Imaging and Pathological Examination

All the 10 patients received prostate-specific antigen (PSA) test, as well as multiparametric magnetic resonance imaging (mpMRI). Prostate needle biopsy was adopted in nine cases preoperatively. Postoperative routine histopathology and immunohistochemistry were conducted among all cases.

### Radionuclide Bone Scan

Seven patients with preoperative PSA value over 20 ng/mL received radionuclide bone scan. During follow-up, patients with PSA recurrence or bone pain also accepted radionuclide bone scan.

### Treatment and Follow-Up

Nine patients underwent laparoscopic or robot-assisted radical prostatectomy (RP), among whom seven patients with preoperative PSA value over 20 ng/mL accepted pelvic lymph node dissection, and one patient with urethral margin positive underwent adjuvant radiotherapy (RT), intensity-modulated radiation therapy (IMRT) specifically

(72 Gy to urethral margin, bilateral seminal vesicles and positive lymph node area, 50 Gy to bilateral pelvic lymph node region) 5 days per week for 6 weeks. All these nine patients underwent adjuvant hormone therapy (HT)-maximal androgen blockage (MAB), including luteinizing hormone-releasing hormone agonist (LHRH-a; goserelin acetate, 10.8 mg, subcutaneous, per 3 months) plus bicalutamide (50 mg, po, qd). For patients with poor therapeutic response or biochemical recurrence, second-line abiraterone or enzalutamide was recommended to replace bicalutamide. Besides, transurethral resection of the prostate (TURP) was performed in the other case. All patients acquired complete postoperative follow-up every 3 months. We regularly evaluated PSA value and testosterone level every 3 months; chest, abdomen, and pelvic computed tomography (CT) scan every half year; and radionuclide bone scan for patients with bone metastasis once a year.

### Statistical Analysis

All the data were analyzed by Microsoft Excel, with a mean value and standard deviation (*SD*). Kaplan–Meier curve was drawn with Graphpad prism v8.

## Results

### Characteristics of Subjects

Table 1 showed the general characteristics of the 10 cases. From November 2014 to December 2020, there were 1,148 cases of prostate cancer diagnosed in our center, including 10 PPSRCC. The average age was 67.8 (51–79) years. Five patients came to see the doctor because of dysuria. The other cases had no obvious symptoms and were further examined due to elevated PSA. Prostatic biopsy confirmed nine cases of prostatic adenocarcinoma, of which four were mixed with SRCC. All 10 cases were diagnosis with PPSRCC as there was no evidence of gastrointestinal SRCC. Among the 10 patients, six were in Clinical Stage IV and four lower than III when diagnosed. Nine patients accepted laparoscopic or robot-assisted RP. Only one patient adopted TURP, whose preoperative PSA value was normal and was diagnosed

<sup>1</sup>Department of Urology, The First Affiliated Hospital of Nanjing Medical University, Nanjing, Jiangsu, China

<sup>2</sup>Department of First Clinical Medical College of Nanjing Medical University, Nanjing, Jiangsu, China

<sup>3</sup>Department of Pathology, The First Affiliated Hospital of Nanjing Medical University, Nanjing, China

\*Pu Li, Zihan Zhou, and Meiling Bao have contributed equally to this work.

### Corresponding Authors:

Bianjiang Liu, Department of Urology, The First Affiliated Hospital of Nanjing Medical University, No. 300 Guangzhou Road, Nanjing, Jiangsu, China.

Email: bjliu@njmu.edu.cn

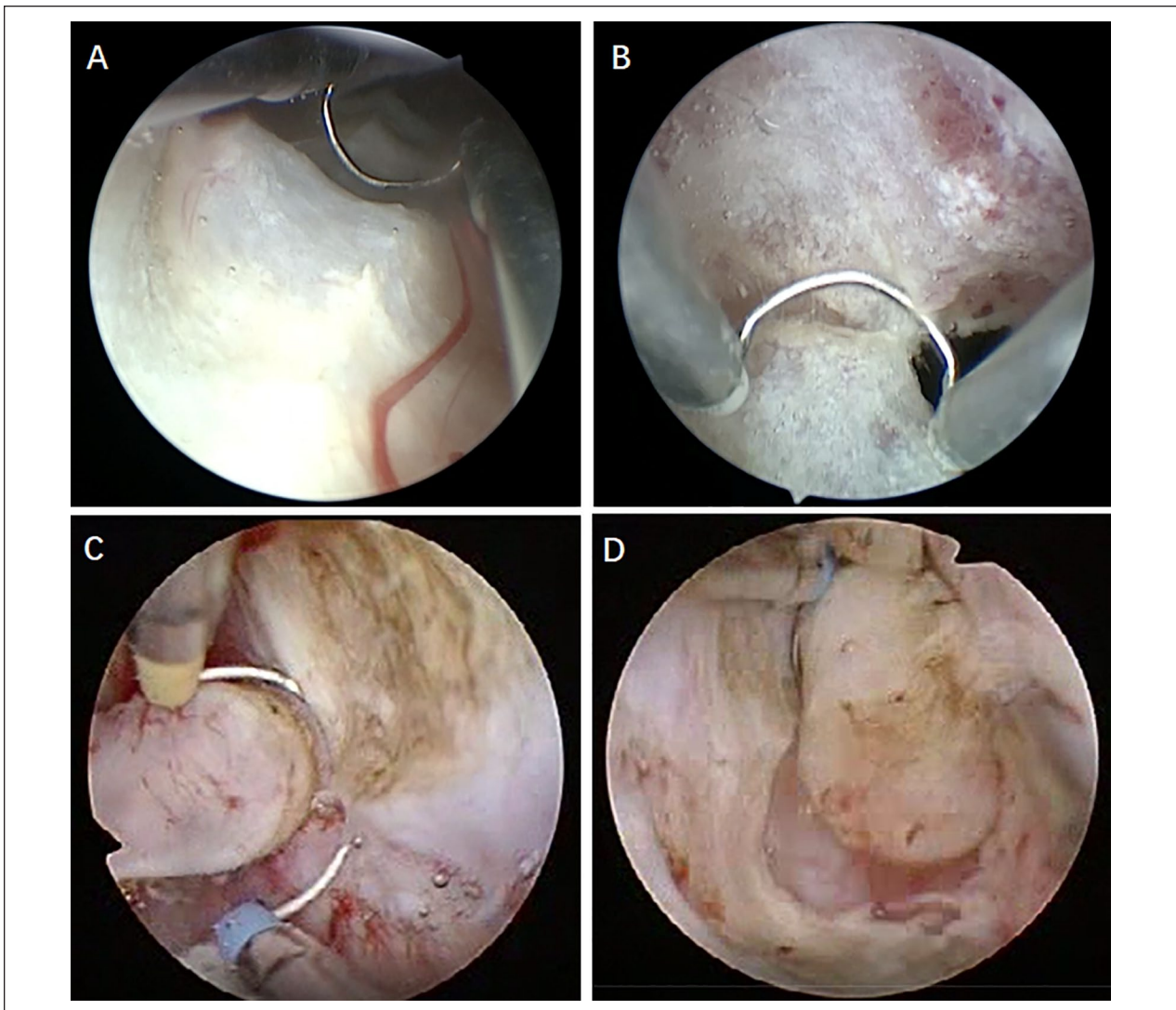
Min Tang, Department of Urology, The First Affiliated Hospital of Nanjing Medical University, No. 300 Guangzhou Road, Nanjing, Jiangsu 210000, China.

Email: mintang@njmu.edu.cn

**Table 1.** Characteristics of the 10 PPSRCC Patients.

No.	Age (years)	Symptoms	Preoperative PSA value (ng/mL)	PI-RADS score	Prostate volume (mL)	PSA density (ng/mL <sup>2</sup> )	Prostate biopsy	Evidence of gastrointestinal SRCC	Clinical stage	Treatment	Pathological diagnosis	Follow-up (months)	Alive or not
1	51	None	21.4	4	65	0.33	Prostatic adenocarcinoma, Gleason4+3	None	cT3bN1M0	RP + MAB	SRCC + PCa, Gleason4+4	25	No
2	67	Dysuria	11.6	4	36	0.32	Prostatic adenocarcinoma, Gleason4+3	None	cT3aN1M0	RP + RT + MAB	SRCC + PCa, Gleason4+3	18	No
3	68	Dysuria	66.68	5	120	0.55	Prostatic adenocarcinoma, Gleason4+3	None	cT3bN0M0	RP + MAB	SRCC + PCa, Gleason4+3	55	Yes
4	79	None	30.19	4	46	0.66	Prostatic adenocarcinoma, Gleason4+3	None	cT3aN0M0	RP + MAB	SRCC + PCa, Gleason4+5	51	Yes
5	70	Dysuria	20	4	55	0.36	Prostatic adenocarcinoma, Gleason4+5 SRCC	None	cT3bN0M0	RP + MAB	SRCC + PCa, Gleason4+5	55	Yes
6	68	None	25.2	5	76	0.33	Prostatic adenocarcinoma, Gleason4+5 SRCC	None	cT3aN1M1b	RP + MAB	SRCC + PCa, Gleason4+5	20	No
7	74	None	35.12	4	42	0.84	Prostatic adenocarcinoma, Gleason5+4 SRCC	None	cT2cN1M0	RP + MAB	SRCC + PCa, Gleason5+4	30	No
8	69	None	21.35	4	50	0.43	Prostatic adenocarcinoma, Gleason4+4 SRCC	None	cT2cN1M0	RP + MAB	SRCC + PCa, Gleason4+5	22	No
9	68	Dysuria	4.45	4	45	0.1	Prostatic adenocarcinoma, Gleason4+5	None	cT3aN1M0	RP + MAB	SRCC + PCa, Gleason5+5	29	No
10	64	Dysuria	0.452	2	60	0.01	None	None	cT1bN0M0	TURP	SRCC	14	Yes

Note. PPSRCC = primary prostatic signet ring cell carcinoma; PSA = prostate specific antigen; PI-RADS = Prostate Imaging-Reporting and Data System; SRCC = signet ring cell carcinoma; RP = radical prostatectomy; MAB = maximal androgen blockade; PCa = prostate cancer; RT = radiotherapy; TURP = transurethral resection of the prostate.



**Figure 1.** Intraoperative Appearance of PPSRCC and BPH Via TURP. PPSRCC: Transparent and Tremelloid Gland Tissue Lacking Blood Supply at (A) 7 o'clock and (B) 12 o'clock. BPH: Gray or Faint Yellow, and Nodular Gland Tissue at (C) 3 o'clock and (D) 5 o'clock

Note. PPSRCC = primary prostatic signet ring cell carcinoma; BPH = benign prostate hyperplasia; TURP = transurethral resection of the prostate.

as benign prostate hyperplasia (BPH) before surgery. During the operation, we can visually see the transparent and tremelloid gland tissue lacking blood supply, which seemed obviously different from common appearance of prostate hyperplasia glands (gray or faint yellow, nodular, and rich in blood supply; Figure 1). After surgery, nine patients received adjuvant HT, one of whom accepted RT simultaneously. The other one patient did not accept any adjuvant therapy.

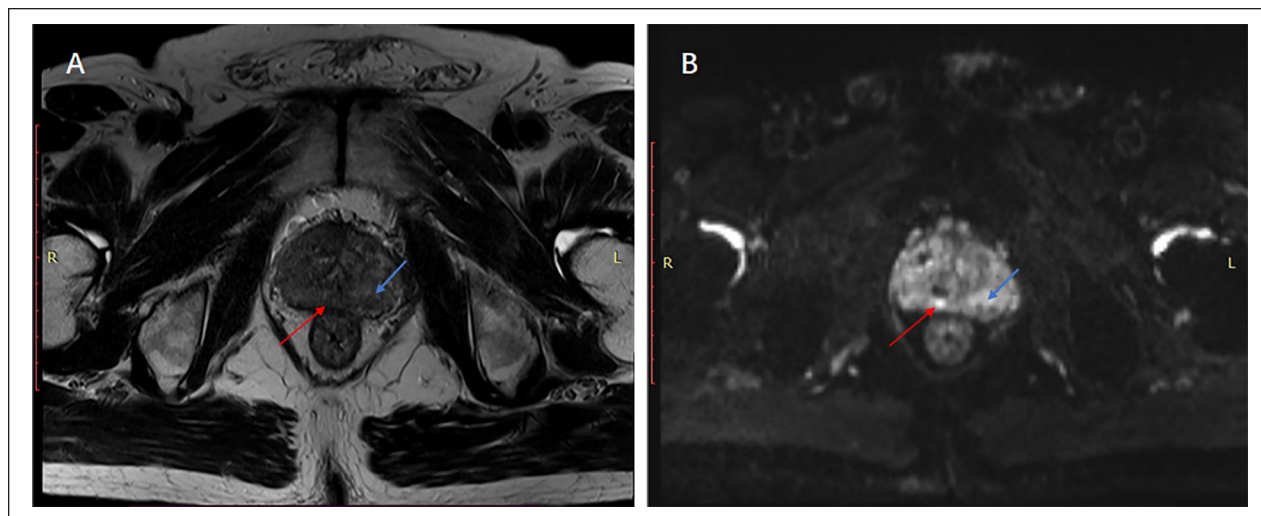
### Imaging Examination

All of the 10 patients received mpMRI before surgery. The mpMRI showed lower signal mass with indistinct margins in the peripheral zone (6/9) and central gland (3/9) of

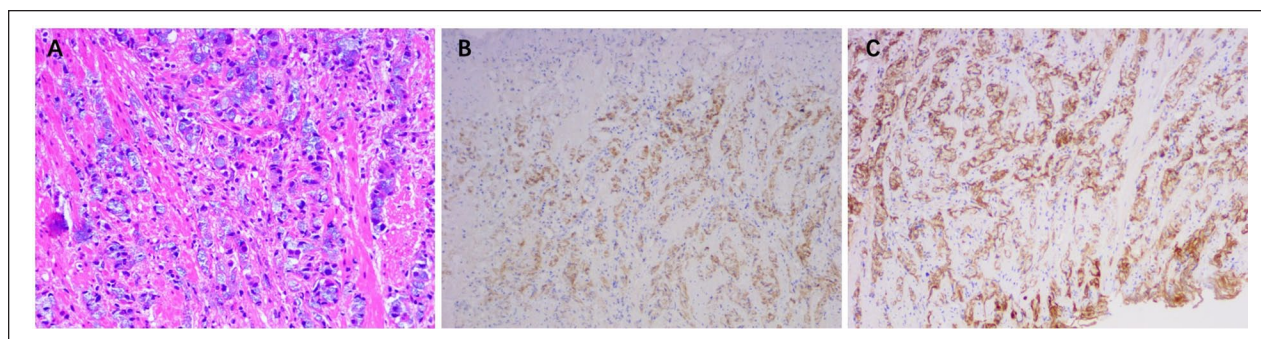
T2-weighted imaging in nine patients. Furthermore, in diffusion-weighted imaging the lesions appeared higher degree of diffusion restriction and/or mixed signals (Figure 2). Prostate Imaging-Reporting and Data System (PI-RADS) score ranged from 4 to 5 in these patients. The mpMRI findings of these nine cases suggested prostate adenocarcinoma, and another one patient was considered to be BPH with PI-RADS score of 2. There were no specific manifestations of SRCC.

### Pathological Examination

The diagnosis of PPSRCC is mainly based on pathological diagnosis. Transperineal prostate biopsy was performed in nine patients mentioned above. Among them,



**Figure 2.** Representative Images of mpMRI (Patient 7). (A) mpMRI Showed Two Lower Signal Masses (Red and Blue Arrows) With Indistinct Margins in the Peripheral Zone of T2-Weighted Imaging. (B) The Lesions Appeared Higher Degree of Diffusion Restriction (Red Arrow) and Mixed Signal (Blue Arrow) in Diffusion-Weighted Imaging  
 Note. mpMRI = multi-parametric magnetic resonance imaging.



**Figure 3.** Representative Histopathology Findings of the Resected Specimen of PPSRCC. (A) Specimen With Hematoxylin and Eosin Staining of Tumor Cells (Magnification,  $\times 200$ ); the Tumor Cells Show Strong and Diffuse Cytoplasmic Immunopositivity for (B) PSA and (C) PAP (Magnification,  $\times 100$ )  
 Note. PPSRCC = primary prostatic signet ring cell carcinoma; PSA = prostate specific antigen; PAP = prostate acid phosphatase.

five patients were diagnosed as prostatic adenocarcinoma and the other four cases were found a mixture of SRCC and adenocarcinoma. Before operation, gastrointestinal endoscope was performed to exclude metastasis from the gastrointestinal tract to the prostate due to the signet ring cell component. Pancreas and other abdominal organs were evaluated by a CT scan, and no pathological signs were found. Therefore, we considered these cases to be PPSRCC. Postoperative pathological results confirmed SRCC mixed with prostatic adenocarcinoma with high Gleason score in nine cases, and only one patient with pure SRCC. Under light microscopy, signet ring cells were diffusely infiltrated in the stroma of the prostate in all the 10 patients in this group. The cells were round in shape and the cytoplasm was rich and transparent. The crescent-shaped nuclei were

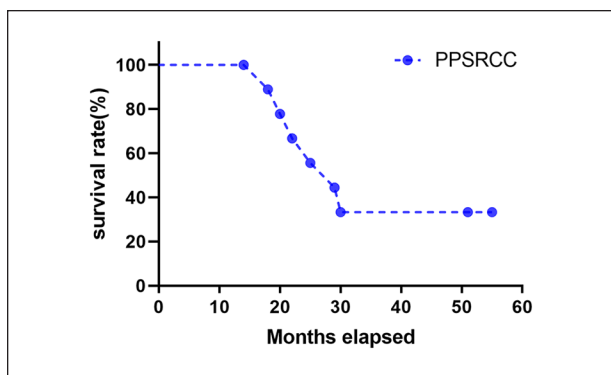
squeezed to one side by vacuoles in the cytoplasm (Figure 3).

### Radionuclide Bone Scan

Seven patients received radionuclide bone scan preoperatively. Among them, only one case was found suspicious bone metastasis in two ribs, and the other six patients with no signs of bone metastasis. During follow-up, two patients with PSA recurrence or bone pain accepted radionuclide bone scan and were found multiple bone metastasis.

### Follow-Up and Prognosis

During a mean follow-up of 31.9 (14–55) months, all the 10 patients accepted regular CT scan of chest, abdomen



**Figure 4.** The Kaplan–Meier Curve for the Cancer-Specific Survival of 10 Patients

and pelvic, PSA value, and testosterone-level reexamination. The patient who received adjuvant RT suffered from frequent urination, urgency, and diarrhea during RT period, and these symptoms disappeared about 3 weeks after RT. Among patients who accepted adjuvant HT (MAB), six patients responded well initially, but biochemical or clinical recurrence happened 5 to 15 (median = 11) months later. Then, abiraterone or enzalutamide was prescribed to replace bicalutamide. Partial response was achieved in four of these six patients, but the treatment failed again soon. Due to poor physical condition, financial burden, or other objective factors, these patients refused further salvage therapies. Eventually, these six patients died during follow-up because of poor therapeutic response upon second-line HT and further tumor recurrence or multiple bone metastasis. The patient who was treated by TURP did not accept any adjuvant therapy and was still alive without disease progression. The other three patients are also still in the follow-up with initial MAB (Figure 4).

## Discussion

SRCCs are most common in the gastrointestinal tract. Therefore, when SRCC is detected in the prostate, endoscopy, colonoscopy, and abdominal CT scan are required to rule out metastasis of gastrointestinal tumors. In this study, no gastrointestinal pathological signs were detected in 10 patients, so they were finally diagnosed as PPSRCC. PPSRCC is a kind of rare, poorly differentiated, highly malignant tumor with poor prognosis. Warner et al. (2010) statistically reported 29,783 cases of prostate cancer, including nine cases of PPSRCC. According to their report, the mean onset age was 68 years old, and six of them were in Clinical Stage IV, which had already developed distant metastasis when detected. Views on survival of patients with PPSRCC are divided. Fujita et al. (2004) calculated that the 1-year survival rate of PPSRCC

patients was 82%, and the 5-year survival rate only 11.7%. They suggested that only disease stage at diagnosis was related to the survival rate, but had nothing to do with the serum PSA level nor the treatment method applied. Saito and Iwaki (1999) described 17 cases of PPSRCC and found the 5-year survival rate was 0. Warner et al. (2010) showed an average survival of 29 months. In our study, 1-year and 3-year survival rate of these patients were 100% and 33.3% separately. Five-year survival rate cannot be evaluated due to short follow-up time. Guerin and colleagues (1993) suggested that SRCC should be classified as a variant of high-grade adenocarcinoma rather than a separate histological clarification. It was reported that prognosis was only related to the stage of PPSRCC at diagnosis. Therefore, the relatively better prognosis in our study is probably associated with lower clinical stage of PPSRCC when diagnosed.

To date, there are no clear diagnostic criteria for PPSRCC. The diagnosis of this disease mainly depends on pathological examination. Epstein and Lieberman (1985) believed that the diagnosis could only be established when the signet ring cell component accounted for more than 25% of the whole tumor, and the metastases outside the prostate were excluded. There are many reasons for the signet ring morphology of cells, most of which are due to the formation of intracellular lumen, and the invagination of cancer cell membrane is the basis of the formation of some intracellular lumen. A few of them accumulated in cells due to PSA and prostate acid phosphatase (PAP). Very few are caused by accumulation of mucus or fat inside the cell. In this study, signet ring cells accounted for more than 30% of the prostatic tumors in every patient (data not shown) and the mixed prostatic adenocarcinoma was high-grade. Postoperative pathological results showed that the Gleason score was more than 8 in seven patients and most of them were accompanied by nerve infiltration. It is reported that immunohistochemical detection of PPSRCC usually showed positive PSA and PAP and negative carcinoembryonic antigen (CEA) in the cytoplasm of cancer cells (Saito & Iwaki, 1999). They stated that the positive rate of PSA and PAP in prostate SRCC cancer tissues was as high as 81.8% (9/11). Alline and Cohen (1992) reported that the positive rates of PSA and PAP in prostate SRCC cancer tissues were 71.4% and 66.7%, respectively, whereas the positive rates of CEA, Alcian blue (AB), and Periodic acid–Schiff (PAS) were relatively low. In our study, the positive rate of PSA and PAP were 80% (8/10) and 70% (7/10) separately and the negative rate of CEA was 90% (9/10), which were consistent with literature reports.

Because PPSRCC is so rare, there is no standard treatment yet. The 10 patients in this group were mainly treated with RP and hormone therapy (HT). According to the literature, the current treatment for PPSRCC is similar

to the traditional treatment for prostate adenocarcinoma and mainly includes RP, HT, RT, and chemotherapy. Warner et al. (2010) believed that the effect of HT alone was limited, whereas HT + RP and HT + RT were more effective. Similarly, in Yoshimura et al.'s (1996) report, patients with PPSRCC survived 100 months after initiation of HT + RT without any evidence of tumor progression during their follow-up. Lilleby et al. (2007) presented that at 12 months after initiation of HT + RT combination therapy, one of their patients was able to control the disease without distant metastasis. Gök et al. (2018) reported that a patient who received HT + RT combined treatment also achieved a survival of 16 months without disease progression. Gu et al. (2009) reported 23 PPSRCC cases that were treated with RP + HT and HT + RT. Eight patients died due to tumor metastasis after 6 to 42 months of survival, five patients had elevated PSA after 12 to 21 months, and three patients were lost to follow-up. Therefore, it is not difficult to find that effect of HT + RT or HT + RP therapy is not yet clear. In addition, Roldán et al. (2012) have achieved success in chemotherapy of gastrointestinal SRCC. Hashimoto et al. (2011) reported a patient with PPSRCC who received chemotherapy with estrogen mustard, docetaxel, carboplatin, and other drugs, and died due to liver metastasis 16 months later. Roldán et al. (2012) considered that chemotherapeutic therapy is also feasible but needs further study. In our study, a total of eight patients were treated with RP + HT in the treatment process, among whom five patients died due to tumor progression or multiple bone metastasis 18 to 30 months after initiation of RP + HT, and the other three patients were still survived during follow-up. One patient was treated with RP + RT + HT, but the postoperative survival was less than 24 months, probably because of highly malignant prostatic adenocarcinoma.

To some extent, several limitations of this article should be considered. First, the study included a limited number of cases with limited information and we could not do any comparable analysis. Second, patients are regionally concentrated in China's Jiangsu province. Therefore, more experience from colleagues in different regions and medical institutions will contribute to the diagnosis and treatment of PPSRCC and differentiate it from ordinary prostate adenocarcinoma.

## Conclusion

Overall, PPSRCC is an extremely rare malignant tumor with few specific symptoms, highly malignancy, rapid disease progression, poor prognosis, and low 5-year survival rate. PPSRCC is frequently accompanied by high-grade prostate adenocarcinoma patterns. There is no clear and effective strategy for dealing with PPSRCC yet. Comprehensive treatment, including radical resection of

prostate cancer, endocrine therapy, or RT, might be meaningful attempt, which needed more clinical trials to confirm.

## Declaration of Conflicting Interests

The author(s) declared no potential conflicts of interest with respect to the research, authorship, and/or publication of this article.

## Data Accessibility Statement

The data sets generated during and/or analyzed during the current study are not publicly available, but are available from the corresponding author on reasonable request.

## Ethical Statement

The authors are accountable for all aspects of the work in ensuring that questions related to the accuracy or integrity of any part of the work are appropriately investigated and resolved. All procedures performed in this study were in accordance with the Declaration of Helsinki (as revised in 2013) and this study was approved by the Ethics Committee of the First Affiliated Hospital of Nanjing Medical University (No. 2020-SR-148) and written informed consent for publication of the patients' information and images was entirely obtained.

## Funding

The author(s) disclosed receipt of the following financial support for the research, authorship, and/or publication of this article: This work was supported by the National Natural Science Foundation of China (Grant No. 81600514), Jiangsu Province Postdoctoral Research Support Project (Grant No. 2021K595C), Jiangsu Science and Technology Association Young Science and Technology Talents Lifting Project (082), Nanjing Postdoctoral Research Support Project (Grant No. 2021BSH204), Open project of Key Laboratory of Children's Major Disease Research (Grant No. JKLP202104), and Open project of Jiangsu Health Development Research Center (Grant No. JSKD2021005).

## ORCID iD

Min Tang  <https://orcid.org/0000-0002-8350-5148>

## References

- Alline, K. M., & Cohen, M. B. (1992). Signet-ring cell carcinoma of the prostate. *Archives of Pathology & Laboratory Medicine*, 116(1), 99–102.
- Epstein, J. I., & Lieberman, P. H. (1985). Mucinous adenocarcinoma of the prostate gland. *The American Journal of Surgical Pathology*, 9(4), 299–308.
- Fujita, K., Sugao, H., Gotoh, T., Yokomizo, S., & Itoh, Y. (2004). Primary signet ring cell carcinoma of the prostate: Report and review of 42 cases. *International Journal of Urology*, 11(3), 178–181.
- Gök, A., Tuygun, C., Akmansu, M., Uslu, A. A., Kartal, I. G., Sandikçi, F., Karabacak, O. R., Sağnak, A. L., Topaloğlu, H., & Ersoy, H. (2018). Primary signet ring cell carcinoma

- of the prostate: A rare case report. *Journal of Clinical Medicine*, 7(8), Article 218.
- Gu, C. Y., Wu, D. L., & Huang, S. S. (2009). Diagnosis and treatment of signet ring cell carcinoma of the prostate. *Chinese Journal of Urology*, 30(7), 487–489.
- Guerin, D., Hasan, N., & Keen, C. E. (1993). Signet ring cell differentiation in adenocarcinoma of the prostate: A study of five cases. *Histopathology*, 22(4), 367–371.
- Hashimoto, Y., Imanishi, K., Okamoto, A., Sasaki, A., Saitoh, H., Wada, R., Yamamoto, H., Koie, T., & Ohyama, C. (2011). An aggressive signet ring cell carcinoma of the prostate in a Japanese man. *Case Reports in Oncology*, 4(3), 517–520.
- Kuroda, N., Yamasaki, I., Nakayama, H., Tamura, K., Yamamoto, Y., Miyazaki, E., Naruse, K., Kiyoku, H., Hiroi, M., & Enzan, H. (1999). Prostatic signet-ring cell carcinoma: Case report and literature review. *Pathology International*, 49(5), 457–461.
- Lilleby, W., Axcrona, K., Alfsen, G. C., Urnes, T., & Hole, K. H. (2007). Diagnosis and treatment of primary signet ring cell carcinoma of the prostate. *Acta Oncologica*, 46(8), 1195–1197.
- Roldán, A. M., Núñez, N. F., Grande, E., García, A. Á., & Antón-Aparicio, L. M. (2012). A primary signet ring cell carcinoma of the prostate with bone metastasis with impressive response to FOLFOX and cetuximab. *Clinical Genitourinary Cancer*, 10(3), 199–201.
- Saito, S., & Iwaki, H. (1999). Mucin-producing carcinoma of the prostate: Review of 88 cases. *Urology*, 54(1), 141–144.
- Uyama, T., & Moriwaki, S. (1979). Papillary and mucus-forming adenocarcinomas of prostate. *Urology*, 13(4), 432–434.
- Warner, J. N., Nakamura, L. Y., Pacelli, A., Humphreys, M. R., & Castle, E. P. (2010). Primary signet ring cell carcinoma of the prostate. *Mayo Clinic Proceedings*, 85(12), 1130–1136.
- Yoshimura, K., Fukui, I., Ishikawa, Y., Maeda, H., Yamauchi, T., & Kawai, T. (1996). Locally-confined signet-ring cell carcinoma of the prostate: A case report of a long-term survivor. *International Journal of Urology*, 3(5), 406–407.