

# Evaluation of the Initial Optical Coherence Tomography Parameters in Anticipating the Final Visual Outcome of Central Retinal Vein Occlusion

Muhammet Derda Ozer<sup>1</sup>, Muhammed Batur<sup>1</sup>, Selma Mesen<sup>1</sup>, Serek Tekin<sup>1</sup>, Erbil Seven<sup>1</sup>

<sup>1</sup>Department of Ophthalmology, Faculty of Medicine, Van Yuzuncu Yil University, Tusba, Van, Turkey

## Abstract

**Purpose:** To evaluate the predictive and associated factors in determining the visual outcome in patients having central retinal vein occlusion (CRVO)-related macular edema (ME).

**Methods:** The charts of the patients who were treated due to CRVO-related visual disturbance were reviewed. The optical coherence tomography (OCT) images of eyes were analyzed, and disorganization of retinal inner layers (DRILs), ellipsoid zone (EZ) and external limiting membrane (ELM) disruption length, hyper-reflectivity of retinal inner layer (HRIL) existence, baseline and final visual acuity (VA), subfoveal thickness (SFT), subretinal fluid (SRF), and injection numbers were noted. The regression and correlation analyses were applied.

**Results:** Thirty eyes of thirty patients were included in the study. The mean follow-up time was  $17.5 \pm 11$  (8–47) months. The mean baseline VA was  $1.4 \pm 0.7$  (0.2–3.1) logMAR. A total of 87 intravitreal injections were applied for the treatment of ME during the follow-up. The initial mean central subfield thickness was  $795 \pm 264$  (1470–398)  $\mu\text{m}$ . HRIL and SRF were observed in 16 and 23 eyes at the initial visit, respectively. The final mean VA was  $1.2 \pm 0.9$  (0.1–3.1) logMAR. At the final visit, additional OCT parameters were evaluated. The mean DRIL length was  $463 \pm 324$   $\mu\text{m}$ . The mean disruption length of EZ and ELM was  $367 \pm 247$   $\mu\text{m}$  and  $414 \pm 327$   $\mu\text{m}$ , respectively. The final mean SFT was  $290 \pm 91$   $\mu\text{m}$ . SRF presence at the initial visit was found to be associated with elongated EZ and ELM disruption length at the final visit ( $P = 0.03$  and  $P = 0.04$ , respectively). On linear regression analyses, none of the baseline features (SRF, SFT, and HRIL) except baseline poor best corrected visual acuity were found to be predictive in anticipating the final visual outcome ( $P = 0.04$ ). On linear bivariate analysis, the final poor visual outcome was found to be affected by EZ disruption length of  $\geq 500$   $\mu\text{m}$  at the last visit ( $P = 0.02$ ).

**Conclusion:** Baseline VA was the only predictive factor in anticipating the final visual outcome. At the final visit, extensive disruption length of EZ in the subfoveal area was associated with a poor visual outcome.

**Keywords:** Central retinal vein occlusion, Disorganization of retinal inner layers, Macular edema, Optical coherence tomography, Subretinal fluid

**Address for correspondence:** Muhammet Derda Ozer, Department of Ophthalmology, Faculty of Medicine, Van Yuzuncu Yil University, Tusba, Van 65080, Turkey. E-mail: muhammetderda@gmail.com

**Submitted:** 28-Jul-2019; **Revised:** 21-Oct-2019; **Accepted:** 10-Nov-2019; **Published:** 23-Mar-2020

## INTRODUCTION

Retinal vein occlusion (RVO) is the second most common retinal vascular disease in the world.<sup>1</sup> Nearly 0.7%–2% of individuals over the age of 40 are struggling with RVO worldwide.<sup>1,2</sup> The

primary factor that leads to visual deterioration in these patients is macular edema (ME).<sup>1</sup> Currently, treatment options for those with ME due to RVO include intravitreal anti-vascular

This is an open access journal, and articles are distributed under the terms of the Creative Commons Attribution-NonCommercial-ShareAlike 4.0 License, which allows others to remix, tweak, and build upon the work non-commercially, as long as appropriate credit is given and the new creations are licensed under the identical terms.

**For reprints contact:** reprints@medknow.com

**How to cite this article:** Ozer MD, Batur M, Mesen S, Tekin S, Seven E. Evaluation of the initial optical coherence tomography parameters in anticipating the final visual outcome of central retinal vein occlusion. *J Curr Ophthalmol* 2020;32:46-52.

### Access this article online

Quick Response Code:



**Website:**  
www.jcurrophthalmol.org

**DOI:**  
10.4103/JOCO.JOCO\_47\_20

endothelial growth factor (anti-VEGF) and intravitreal dexamethasone implant (Ozurdex®) injections. After initial treatment, additional injections may be required if there is a recurrence of ME or a decrease in visual acuity (VA).<sup>3</sup>

The leading cause of visual disturbance in the world is diabetic ME (DME).<sup>4</sup> Similar to RVO-related ME, it is treated with anti-VEGFs and steroids. However, the functional results could be limited in contrast to anatomic success rates. There are several optical coherence tomography (OCT) parameters that have been found to be related to poor vision in vascular eye diseases.<sup>5-8</sup> More recently, disorganization of retinal inner layers (DRILs) has been found to be significantly related to VA in individuals suffering from DME.<sup>8-11</sup> In uveitic ME, DRIL also reported to have a significant negative impact on VA.<sup>12</sup> A few studies have been conducted on the association of DRIL with VA in patients having RVO.<sup>7,10,13</sup> A more recent report comprising 53 eyes with central RVO (CRVO) and 83 eyes with branch RVO (BRVO) revealed a significant association of DRIL with VA.<sup>14</sup> However, in all of these reports, the association between DRIL and VA was not adequately evaluated in eyes having CRVO.

This study was conducted on a particular patient group with CRVO who were treated with either intravitreal anti-VEGF or an intravitreal dexamethasone implant, which was then followed up for at least 8 months. The association of DRIL, ellipsoid zone (EZ) and external limiting membrane (ELM) disruption length, cone outer segment tip (COST) visibility and the prediction value of initial VA, the existence of subretinal fluid (SRF), and hyper-reflectivity of retinal inner layers (HRIL) on final VA outcome were assessed.

## METHODS

This is a retrospective study. Patients who have had CRVO and applied to Van Yuzuncu Yil University, Faculty of Medicine, between 2013 and 2017, were retrospectively evaluated. Approval from the institutional ethics board was obtained prior to performing this study. Study-related procedures were performed upon receipt of consent from the patients. All procedures performed in studies involving human participants were in accordance with the ethical standards of the institutional and/or National Research Committee and the 1964 Helsinki Declaration and its later amendments or comparable ethical standards. The study was approved by the Surgical and Pharmaceutical Research Ethics Board, Van Yuzuncu Yil University, Dursun Odabas Faculty of Medicine.

A chart review was conducted, and the following features were defined as the inclusion criteria for the study: (1) cases in which the CRVO diagnosis was made initially at our clinic; (2) absence of any type of intravitreal injections before admission to the clinic; (3) well-documented pre- and post-injection OCT images in high resolution; (4)  $\geq 50$  years of age; and (5) at least 8 months of follow-up.

Exclusion criteria were as follows: (1) ill-defined OCT images due to media opacities; (2) prior intravitreal treatment

of any kind at baseline; (3) individuals with poor treatment compliance; (4) presence of diabetic retinopathy (DRP), exudative or non-exudative age-related macular degeneration, and a macular hole on the fellow eye; (6) presence of glaucoma; and/or (7) intraocular surgery of any kind other than phacoemulsification at least 3 months before admission and prior to the incidence.

A total of 74 eyes of 74 patients qualified for the chart review, and thirty eyes of thirty patients met the enrollment criterion. All patients had undergone complete ophthalmic examination comprising best corrected visual acuity (BCVA) employing the Snellen chart, bio-microscopic anterior segment examination along with intraocular pressure measurement with Goldmann applanation tonometry, dilated fundus examination, and spectral-domain OCT (Spectralis HRA + OCT; Heidelberg Engineering, Heidelberg, Germany) examination at every visit. During the statistical analysis, VAs were converted to logMAR equivalents. Poor visual outcome was defined as  $< 20/200$  and  $> 1.0$  logMAR BCVA on the Snellen chart.

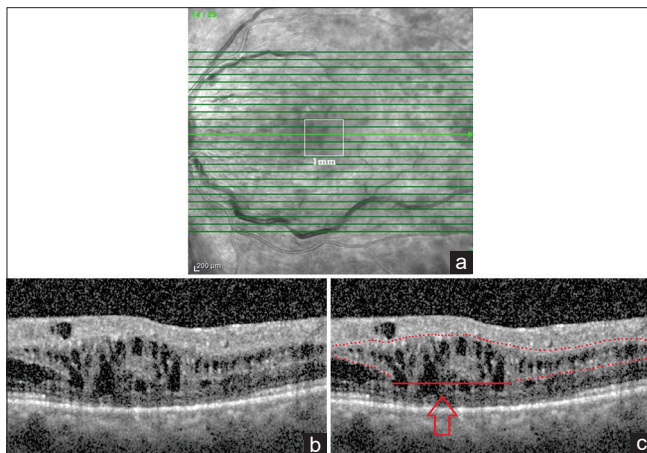
The treatment protocol was determined by the retina specialist (M.B.) of the institute. All patients were treated according to the pro-re-nata protocol. After the first three consecutive intravitreal anti-VEGF injections, the patients were treated with either intravitreal anti-VEGF drugs or an intravitreal dexamethasone implant according to the existence or recurrence of ME during follow-up examinations. After the first three consecutive anti-VEGF injections, the follow-up visit intervals were adjusted according to the patient's availability. Hence, the Ozurdex implantation was preferred for patients who were not able to come for monthly follow-up visits. In addition, despite that the social insurance of the country covers the price of only two dexamethasone intravitreal implant injections per year, it was not possible to employ an intravitreal dexamethasone implant in 3-month intervals. Therefore, the time intervals between the dexamethasone implant injections were filled with anti-VEGF injections if treatment was necessary. Central subfield thickness (CST) in the Early Treatment Diabetic Retinopathy Study (ETDRS) was used to measure macular thickness. Fundus fluorescein angiography (FFA) was used in the distinction of ischemic and non-ischemic nature of the vein occlusion. FFA was used to evaluate the peripheral ischemia status after resolution of retinal hemorrhagia or after the first consecutive anti-VEGF injections. When retinal capillary dropout and neovascularization was realized elsewhere, retinal laser photocoagulation was applied to the ischemic areas. For analysis, the initial and most recent clinical condition of the patients was evaluated. BCVA, age, gender, number of injections made, the follow-up time, ischemia existence, and comorbidities were noted.

OCT parameters at the baseline and the final visit were taken into account. OCT images were obtained from a 30° area centered on the fovea. This area was scanned with 25 B-scans, with an average of 16 automated real-time images per scan in

high-resolution mode by an experienced operator. For analysis, a 1-mm<sup>2</sup> area centered on the foveal depression was selected, and three consecutive B-scans were taken into account in which the scan was passing through the foveal center, which was selected as the midline scan along with one B-scan immediately above and below the midline scan. Two independent graders who were blind to the BCVA and other clinical information reviewed the entire macular scan of the OCT, and a third reviewer resolved any discrepancy. The average measurement was used for quantitative analysis.

A 1-mm<sup>2</sup> area centered on the foveal depression was evaluated for the presence of the following features: (1) length of the DRIL; (2) COST visibility; (3) EZ disruption length; (4) ELM disruption length; (5) presence of an epiretinal membrane (ERM) or vitreomacular traction; and (6) SRF presence and HRIL. The measurements were obtained from the three consecutive scans, the average value was calculated for statistical analysis, and all measurements were in micrometers.

DRIL was evaluated according to previous reports and was defined as the horizontal extent of the disorganization of the boundaries between the ganglion cell-inner plexiform layer complex, inner nuclear layer, and outer plexiform layer [Figure 1].<sup>8</sup> The CST in the ETDRS grid was used to determine macular thickness. SRF was defined as the retinal elevation over a non-reflective cavity with minimal shadowing of the underlying tissue. HRIL was defined as the hyper-reflectivity of the ganglion cell layer observed during the initial visit that was obscuring the differentiation of the



**Figure 1:** (a) A 1-mm<sup>2</sup> area centered on the foveal depression was selected, and three consecutive B-scans were taken into account, in which the scan passing through the foveal center was selected as the midline scan along with one B-scan immediately above and below. (b) Optical coherence tomography (OCT) image of a patient in order to demonstrate disorganization of retinal inner layer (DRIL) measurement. (c) OCT images of the same patient showing the measurement of DRIL, which was defined as the horizontal extent of the disorganization of the boundaries between the ganglion cell-inner plexiform layer complex, inner nuclear layer, and outer plexiform layer. The normal architecture is shown by consecutive red dots, and DRIL is pointed by red line and upward red arrow

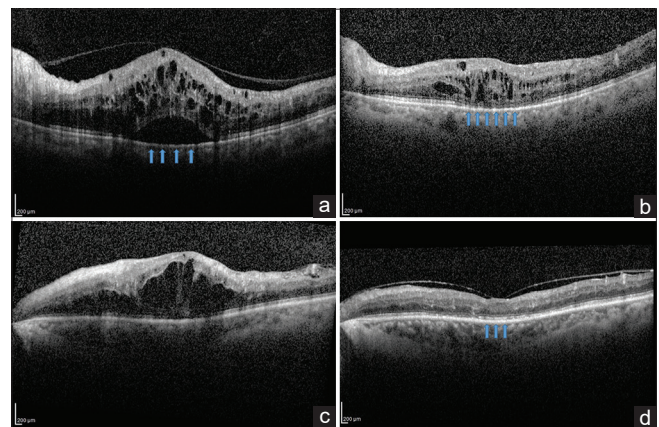
inner retinal layer boundaries along with increased ganglion layer thickness [Figures 2 and 3].

All measurements were presented in mean  $\pm$  standard deviation. After checking the normal distribution using the Kolmogorov–Smirnov test, descriptive analyses were performed. Bivariate general linear model analyses were performed to establish the association of BCVA outcomes with final-visit OCT parameters, and variables that were significantly associated with BCVA were then determined.

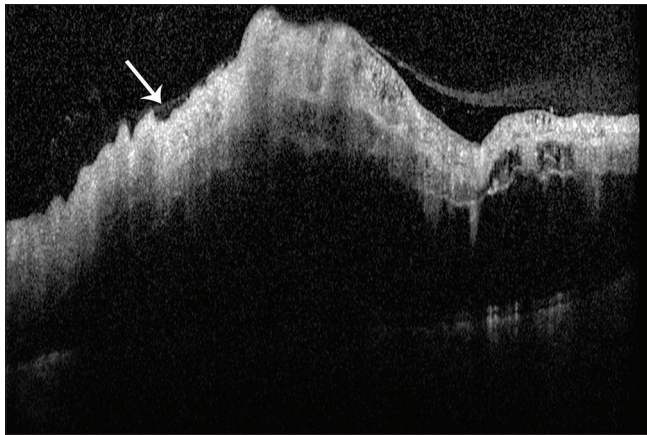
In addition, linear regression analyses were performed to determine the cause–effect relationship. If the distribution was normal, a Student’s *t*-test would have been utilized to compare the mean values among the groups. If the distribution was found to be abnormal, the Mann–Whitney U-test would be the test of choice. Statistical analyses were performed using SPSS version 22 (SPSS Inc. Chicago, IL., USA).  $P < 0.05$  was accepted as a statistically significant rate.

## RESULTS

A total of thirty eyes of thirty patients were included in the study. The mean age of the participants was  $63 \pm 8$  (50–76) years. Eighteen (60%) were male and 12 (40%) were female. The mean follow-up time was  $17.5 \pm 11$  (8–47) months. The right eye was affected in 16 participants. All the patients had been diagnosed with hypertension elsewhere. The mean baseline BCVA was  $1.4 \pm 0.7$  (0.2–3.1) logMAR. During the follow-up period, FFA revealed that 13 of the 30 eyes (26%) had retinal ischemia and neovascularization elsewhere, which required laser photocoagulation. A total of 87 intravitreal injections were administered for the treatment of ME during the follow-up. In all eyes, at least one Ozurdex<sup>®</sup> injection ( $1.5 \pm 0.8$ , range 1–4) was performed. The mean baseline CST was  $795 \pm 264$  (1470–398)  $\mu$ m. HRIL and



**Figure 2:** (a) The blue arrows are showing subretinal fluid (SRF). (b) The optical coherence tomography (OCT) of the same patient. After resolution of the SRF and macular edema (ME), the disruption of the ellipsoid zone (EZ) can be noticed at the 12<sup>th</sup>-month visit. The blue arrows are showing EZ disruption beneath the foveola. (c) The initial OCT of another patient that has no SRF. (d) At the end of the 12 months of follow-up, EZ is intact (see the blue arrows)



**Figure 3:** The white arrow is showing hyper-reflectivity of retinal inner layers (HRIL). Note the increased thickness of the ganglion cell layer along with hyper-reflectivity

SRF were observed in 16 and 23 eyes at the initial visit, respectively.

The final mean BCVA was  $1.2 \pm 0.9$  (0.1–3.1) logMAR. At the final visit, additional OCT parameters were evaluated. DRIL was observed in 22 eyes. The mean DRIL length was  $463 \pm 324 \mu\text{m}$ . The mean disruption length of EZ and ELM was  $367 \pm 247 \mu\text{m}$  and  $414 \pm 327 \mu\text{m}$ , respectively. COST visibility was determined in six eyes, and ERM was observed in six eyes. The final mean subfoveal thickness (SFT) was  $290 \pm 91 \mu\text{m}$ . The demographical, clinical, and OCT features of the group are summarized in Table 1.

The initial OCT findings were classified according to SRF, and the existence of HRIL in these groups was evaluated in relation to their final BCVA outcome, EZ and ELM disruption length at the last visit, injection number, and DRIL length. The presence of SRF at the initial visit was found to be associated with elongated EZ and ELM disruption length at the final visit ( $P = 0.03$  and  $P = 0.04$ , respectively). HRIL was also evaluated, and the presence of HRIL at the baseline did not have any effect on the evaluated parameters at the final visit [Table 2].

Based on results of the linear regression analyses, none of the baseline features (SRF, SFT, and HRIL) except baseline poor BCVA were found to be predictive of the final visual outcome ( $P = 0.04$ ). Based on the linear bivariate analysis, the final poor visual outcome was found to be affected by an EZ disruption length  $\geq 500 \mu\text{m}$  at the last visit ( $P = 0.02$ ). Other parameters were also analyzed, and there was no statistically significant predictive value that could be used to predict a poor visual outcome [Table 3].

## DISCUSSION

The objective of this study was to determine whether there is a link between the last-visit OCT parameters and final visual outcome. In addition, the impact of baseline OCT parameters on the last BCVA was evaluated. The study was conducted on a particular patient group who had CRVO-related ME.

**Table 1: Clinical characteristics of the studied eyes**

Demographical/clinical/OCT features	Mean $\pm$ SD
Age (years)	63 $\pm$ 8
Gender	
Male	18
Female	12
Laterality	
Right	16
Left	14
Comorbidities	
HT	29
HT + HL	1
Baseline BCVA (logMAR)	1.4 $\pm$ 0.7
Final BCVA (logMAR)	1.2 $\pm$ 0.9
Initial OCT parameters	
SFT ( $\mu\text{m}$ )	795 $\pm$ 264
HRIL (+/-)	16/14
SRF (+/-)	23/7
OCT parameters at the final visit	
DRIL length ( $\mu\text{m}$ )	463 $\pm$ 324
EZ disruption length ( $\mu\text{m}$ )	367 $\pm$ 247
ELM disruption length ( $\mu\text{m}$ )	414 $\pm$ 327
COST visibility (+/-)	6/24
ERM (+/-)	6/24
SFT ( $\mu\text{m}$ )	290 $\pm$ 91
CME (+/-)	5/25
Number of injections	87
Aflibercept	10
Ranibizumab	25
Dexamethasone	52
Follow-up period (months)	17.5 $\pm$ 11

OCT: Optical coherence tomography, HT: Hypertension, HL: Hyperlipidemia, BCVA: Best corrected visual acuity, LogMAR: Logarithm of the minimum angle of resolution, SFT: Subfield thickness, HRIL: Hyper-reflectivity of retinal inner layers, SRF: Subretinal fluid, DRIL: Disorganization of retinal inner layers, EZ: Ellipsoid zone, ELM: External limiting membrane, ERM: Epiretinal membrane, COST: Cone outer segment tips, CME: Cystoid macular edema, SD: Standard deviation

Recently, DRIL has become popular as an OCT parameter for the evaluation of DME.<sup>8-11</sup> It was stated that the disruption rate of the retinal inner segments in patients having center-involved DME was more critical than EZ and ELM disruption rates in determining poor visual outcome. The definition of DRIL and the revelation of its impact on VA encouraged researchers to evaluate the effects of DRIL in the other vascular disorders of the eye, such as BRVO and CRVO. Most study groups examined with respect to this subject were composed of a mixed group of patients in terms of diagnosis. However, to date, there have been no studies that directly analyzed the association between DRIL and VA in eyes with CRVO, and only three previous studies have included eyes with ME due to CRVO in their patient group.<sup>7,10,14</sup> Radwan *et al.* evaluated 23 eyes with ME due to diseases other than DRP comprising four eyes having CRVO, and they did not identify a significant association between DRIL and VA. They could not have applied statistical analyses on eyes having CRVO due to the

**Table 2: Summary of the effects of subretinal fluid and presence of hyper-reflectivity of retinal inner layer on the final outcomes**

Clinical and OCT parameters at final visit	Baseline OCT features	Data (+/-)	P
EZ disruption length at final visit ( $\mu\text{m}$ )	SRF (+)/SRF (-)	422 $\pm$ 249/188 $\pm$ 131	0.03*
	HRIL (+)/HRIL (-)	432 $\pm$ 232/294 $\pm$ 251	0.92*
ELM disruption length at final visit ( $\mu\text{m}$ )	SRF (+)/SRF (-)	517 $\pm$ 293/76 $\pm$ 168	0.04*
	HRIL (+)/HRIL (-)	507 $\pm$ 293/308 $\pm$ 341	0.50*
Injection number	SRF (+)/SRF (-)	3 $\pm$ 1.6/2.7 $\pm$ 1.5	0.70*
	HRIL (+)/HRIL (-)	2.94 $\pm$ 1.6/2.93 $\pm$ 1.5	0.95*
DRIL length at final visit ( $\mu\text{m}$ )	SRF (+)/SRF (-)	482 $\pm$ 325/397 $\pm$ 338	0.74*
	HRIL (+)/HRIL (-)	540 $\pm$ 303/374 $\pm$ 335	0.40*

\*Multiple linear regression analyses. OCT: Optical coherence tomography, EZ: Ellipsoid zone, ELM: External limiting membrane, DRIL: Disorganization of retinal inner layers, SRF: Subretinal fluid, HRIL: Hyper-reflectivity of retinal inner layers

**Table 3: Bivariate general linear model<sup>#</sup> and linear regression analyses\* of optical coherence tomography parameters**

OCT parameters affecting final BCVA	Coefficients <sup>a</sup>	P
Baseline BCVA		<b>0.04*</b>
Baseline SRF		0.09*
Baseline HRIL		0.69*
Baseline SFT		0.15*
Peripheral retinal ischemia status (+/-)		0.08 <sup>#</sup>
DRIL presence at final visit (+/-)		0.55 <sup>#</sup>
DRIL length (<500 $\mu\text{m}$ vs. $\geq$ 500 $\mu\text{m}$ )		0.63 <sup>#</sup>
ELM disruption length (<500 $\mu\text{m}$ vs. $\geq$ 500 $\mu\text{m}$ )		0.93 <sup>#</sup>
EZ disruption length (<500 $\mu\text{m}$ vs. $\geq$ 500 $\mu\text{m}$ )		<b>0.02<sup>#</sup></b>
COST visibility (+/-)		0.36 <sup>#</sup>
Gender (male/female)		0.33 <sup>#</sup>
Laterality (right/left)		0.18 <sup>#</sup>

<sup>a</sup>Dependent variable: The final BCVA. OCT: Optical coherence tomography, BCVA: Best corrected visual acuity, SRF: Subretinal fluid, HRIL: Hyper-reflectivity of retinal inner layers, SFT: Subfield thickness, DRIL: Disorganization of retinal inner layers, ELM: External limiting membrane, EZ: Ellipsoid zone, COST: Cone outer segment tips, <sup>#</sup>Bivariate general linear model, \*Linear regression analyses,  $P < 0.05$  is considered statistically significant

small number of patients in the patient group.<sup>10</sup> In a study by Balaratnasingam *et al.* to reveal the predictive factors associated with VA in a patient group comprising 38 eyes with DME, 27 eyes with DRP but without DME, 19 eyes with ME due to BRVO, and 11 eyes with ME due to CRVO found that foveal avascular zone area, age, and EZ disruption length were significant predictors of VA in contrast to DRIL.<sup>7</sup> In addition to that, Mimouni *et al.* evaluated 136 eyes with RVO, including 83 eyes with BRVO and 53 eyes with CRVO, and found a decreasing trend of DRIL during the follow-up period of patients who had RVO and were treated with intravitreal anti-VEGF for center-involved ME. They stated that initial long DRIL had restricting effects on vision improvement rates during follow-up examinations. Finally, they emphasized that the reduction in DRIL at 4 months predicted BCVA at 8 months in their patient group.<sup>14</sup> In our study, at the final visit, DRIL length and the other variables seen on OCT images displayed

no effect on the final BCVA except for EZ disruption lengths that exceeded 500  $\mu\text{m}$ .

A total of thirty eyes were enrolled in this study, which had CRVO-related ME and were treated with anti-VEGF and an intravitreal dexamethasone implant. According to the results of this study, to predict a poor visual outcome based on regression analysis, the presence of HRIL and SRF at the baseline visit was not found to be important in the patient group ( $P = 0.69$  and  $P = 0.09$ , respectively). It was previously reported that SRF had no effects on the final visual outcome in patients having CRVO.<sup>15</sup> However, after this determination, SRF was found in patients with CRVO more often than previously thought (56% vs. 81%).<sup>16</sup> Our patient group had a similar percentage of SRF at the initial visit with the last mentioned study (78%).<sup>16</sup>

In addition, the results of this study indicated that the presence of SRF at the initial visit was strongly predictive of EZ and ELM disruption length at the final visit, thus indirectly leading to a poor visual outcome. This outcome was explained by the photoreceptor degeneration that occurred due to separation from the underlying retinal pigment epithelium. Thus, SRF may have an indirect effect on the final visual outcome by elongating EZ disruption length. If the EZ disruption length exceeded 500  $\mu\text{m}$ , the results of this study strongly suggest that it will have a significant negative impact on the final BCVA, which also suggests that researchers should pay more attention to the presence of SRF and the retinal outer layer integrity rather than DRIL when treating ME due to CRVO. In the present study, the final-visit SFT showed no significant association with the final BCVA. As Kurashige *et al.* suggested, the results of this study also indicated that total foveal retinal thickness at the baseline had no significant association with the final VA, whereas the thickness and integrity of the foveal outer retina, especially EZ, had a significant association with last-visit BCVA.<sup>5,17-19</sup>

In literature, several reports have suggested that the increased foveal avascular zone is associated with poor VA and elongated EZ disruption in eyes with ME due to RVO.<sup>7,20</sup> Our study focused on OCT parameters and did not evaluate the macular ischemia status of the eyes. However, the HRIL of the eyes having CRVO-related ME were assessed in this study, and a

predictive value for the presence of HRIL on the final visual outcome was not found.

As described earlier, due to inner capillary layer ischemia, the ganglion cell layer thickens and the reflectivity of the inner nuclear layer increases, especially in central retinal artery occlusion.<sup>21</sup> This circumstance was also eligible for CRVO, but the degree of reflectivity in the inner retina after acute CRVO varied in contrast to uniform hyper-reflectivity, which is demonstrated in acute central retinal artery occlusion.<sup>21,22</sup> To solve this variability, Mehta *et al.* utilized the ImageJ program (<http://imagej.nih.gov/ij/>; provided in the public domain by the National Institutes of Health, Bethesda, MD, USA) to quantify optical intensity ratios and found an increased correlation with higher inner retinal layer reflectivity and poor visual outcomes in a patient group having CRVO.<sup>23</sup> The hyper-reflectivity was more practically, though subjectively, evaluated. A 30° area centered on the fovea was evaluated, and the increased ganglion layer thickness and increased inner retinal layer reflectivity that obscure inner retinal layer boundaries were defined as HRIL. Based on comparison analysis, the presence of HRIL at the initial visit was found to have no effect on the final OCT parameters. When its predictive value was analyzed, it was also statistically insignificant. We considered that the lack of quantitative measurement of HRIL in our study would have led to this outcome.

Our study has some limitations. First, this was a retrospective study with a small number of participants. The findings of our study should be confirmed with a prospective study, and the aforementioned OCT parameters should be evaluated along with foveal angiographic findings, which were obtained by OCT angiography and FFA. Furthermore, it was only possible to identify the presence of SRF, HRIL, and SFT based on the baseline OCT images due to difficulty in determining the other OCT parameters because of shadowing. This can be overcome by using swept-source OCT in forthcoming research. Hence, it was not possible to analyze the predictive value of the DRIL alterations to the final visual outcome during the follow-up.

On the other hand, our study did reveal certain strengths. We included patients older than 50 who had CRVO-related ME to handle the etiologic dilemma. In addition, we excluded patients that had DRP, exudative and/or non-exudative age-related macular degeneration, and a macular hole on the fellow eye.

In conclusion, CRVO is a severe and vision-threatening condition that requires significant attention. Baseline VA is the best and only predictive factor in anticipating the final visual outcome. In addition, the presence of SRF may elongate the disruption length of EZ, and if the disruption length of EZ exceeds 500 µm in the subfoveal 1-mm<sup>2</sup> area, it will lead to a poor visual outcome at the final visit, and the existence of baseline HRIL did not appear to have value in predicting the final visual outcome.

#### **Financial support and sponsorship**

Nil.

#### **Conflicts of interest**

There are no conflicts of interest.

#### **REFERENCES**

1. Wong TY, Scott IU. Clinical practice. Retinal-vein occlusion. *N Engl J Med* 2010;363:2135-44.
2. Klein R, Klein BE, Moss SE, Meuer SM. The epidemiology of retinal vein occlusion: The Beaver Dam Eye Study. *Trans Am Ophthalmol Soc* 2000;98:133-41.
3. Campochiaro PA, Heier JS, Feiner L, Gray S, Saroj N, Rundle AC, *et al.* Ranibizumab for macular edema following branch retinal vein occlusion: Six-month primary end point results of a phase III study. *Ophthalmology* 2010;117:1102-120.
4. Wong TY, Sun J, Kawasaki R, Ruamviboonsuk P, Gupta N, Lansingh VC, *et al.* Guidelines on diabetic eye care: The international council of ophthalmology recommendations for screening, follow-up, referral, and treatment based on resource settings. *Ophthalmology* 2018;125:1608-22.
5. Ota M, Tsujikawa A, Murakami T, Kita M, Miyamoto K, Sakamoto A, *et al.* Association between integrity of foveal photoreceptor layer and visual acuity in branch retinal vein occlusion. *Br J Ophthalmol* 2007;91:1644-9.
6. Domalpally A, Peng Q, Danis R, Blodi B, Scott IU, Ip M, *et al.* Association of outer retinal layer morphology with visual acuity in patients with retinal vein occlusion: SCORE Study Report 13. *Eye (Lond)* 2012;26:919-24.
7. Balaratnasingam C, Inoue M, Ahn S, McCann J, Dhrami-Gavazi E, Yannuzzi LA, *et al.* Visual acuity is correlated with the area of the foveal avascular zone in diabetic retinopathy and retinal vein occlusion. *Ophthalmology* 2016;123:2352-67.
8. Sun JK, Lin MM, Lammer J, Prager S, Sarangi R, Silva PS, *et al.* Disorganization of the retinal inner layers as a predictor of visual acuity in eyes with center-involved diabetic macular edema. *JAMA Ophthalmol* 2014;132:1309-16.
9. Sun JK, Radwan SH, Soliman AZ, Lammer J, Lin MM, Prager SG, *et al.* Neural retinal disorganization as a robust marker of visual acuity in current and resolved diabetic macular edema. *Diabetes* 2015;64:2560-70.
10. Radwan SH, Soliman AZ, Tokarev J, Zhang L, van Kuijk FJ, Koozekanani DD. Association of disorganization of retinal inner layers with vision after resolution of center-involved diabetic macular edema. *JAMA Ophthalmol* 2015;133:820-5.
11. Das R, Spence G, Hogg RE, Stevenson M, Chakravarthy U. Disorganization of inner retina and outer retinal morphology in diabetic macular edema. *JAMA Ophthalmol* 2018;136:202-8.
12. Grewal DS, O'Sullivan ML, Kron M, Jaffe GJ. Association of disorganization of retinal inner layers with visual acuity in eyes with uveitic cystoid macular edema. *Am J Ophthalmol* 2017;177:116-25.
13. Nakano E, Ota T, Jingami Y, Nakata I, Hayashi H, Yamashiro K. Disorganization of the retinal inner layers after anti-VEGF treatment for macular edema due to branch retinal vein occlusion. *Ophthalmologica* 2018;240:229-34.
14. Mimouni M, Segev O, Dori D, Geffen N, Flores V, Segal O. Disorganization of the retinal inner layers as a predictor of visual acuity in eyes with macular edema secondary to vein occlusion. *Am J Ophthalmol* 2017;182:160-7.
15. Catier A, Tadayoni R, Paques M, Erginay A, Haouchine B, Gaudric A, *et al.* Characterization of macular edema from various etiologies by optical coherence tomography. *Am J Ophthalmol* 2005;140:200-6.
16. Ozdemir H, Karacorlu M, Karacorlu S. Serous macular detachment in central retinal vein occlusion. *Retina* 2005;25:561-3.
17. Kurashige Y, Tsujikawa A, Murakami T, Miyamoto K, Ogino K, Muraoka Y, *et al.* Changes in visual acuity and foveal photoreceptor integrity in eyes with chronic cystoid macular edema associated with retinal vein occlusion. *Retina* 2012;32:792-8.
18. Murakami T, Tsujikawa A, Ohta M, Miyamoto K, Kita M, Watanabe D, *et al.* Photoreceptor status after resolved macular edema in branch retinal vein occlusion treated with tissue plasminogen activator. *Am J*

- Ophthalmol 2007;143:171-3.
19. Ota M, Tsujikawa A, Murakami T, Yamaike N, Sakamoto A, Kotera Y, *et al.* Foveal photoreceptor layer in eyes with persistent cystoid macular edema associated with branch retinal vein occlusion. *Am J Ophthalmol* 2008;145:273-80.
  20. Kang JW, Yoo R, Jo YH, Kim HC. Correlation of microvascular structures on optical coherence tomography angiography with visual acuity in retinal vein occlusion. *Retina* 2017;37:1700-9.
  21. Chen H, Xia H, Qiu Z, Chen W, Chen X. Correlation of optical intensity on optical coherence tomography and visual outcome in central retinal artery occlusion. *Retina* 2016;36:1964-70.
  22. Rahimy E, Kuehlewein L, Sadda SR, Sarraf D. Paracentral acute middle maculopathy: What we knew then and what we know now. *Retina* 2015;35:1921-30.
  23. Mehta N, Lavinsky F, Gattoussi S, Seiler M, Wald KJ, Ishikawa H, *et al.* Increased inner retinal layer reflectivity in eyes with acute CRVO correlates with worse visual outcomes at 12 months. *Invest Ophthalmol Vis Sci* 2018;59:3503-10.