

## USE OF BIOCERAMICS IN FILLING BONE DEFECTS

Carlos Antônio Garrido<sup>1</sup>, Tania Clarete Fonseca Vieira Sales Sampaio<sup>2</sup>

**ABSTRACT**

*Objective: To present the results from using biological ceramics for filling bone defects resulting from post-traumatic or orthopedic injuries. Methods: Thirty-six patients with bone defects caused by trauma or orthopedic injury were evaluated. Nineteen patients were male (52.8%) and 17 were female (47.2%). Their ages ranged from 19 to 84 years, with a mean of 45.7 years and median of 37 years. Only patients with defects that required at least five grams of biological ceramic were included. Eighteen cases were classified as orthopedic: bone defects were observed in 11 cases of total hip arthroplasty; one case of primary total hip arthroplasty, due to coxarthrosis; five cases of femoral or tibial open wedge osteotomy; and one case of tarsal arthrodesis. There were 18 cases of trauma-related defects; uninfected pseudarthrosis, eight cases; recent fractures of the tibial plateau with compression of the spongy bone, three cases; and exposed fractures treated with external fixators, seven cases. The surgical technique consisted of curetting and debriding the injury until bone suitable for grafting was found. Biological ceramic was then used to fill the defect and some kind of fixation was applied. Results: Among the 36 patients evaluated, it was seen that 35 (97.2%) presented integration of the biological ceramic, while one case of open fracture treated with external fixation had poor integration of the biological ceramic. Conclusion: Treatment of bone defects of orthopedic or post-traumatic etiology using a phosphocalcium ceramic composed of hydroxyapatite was shown to be a practical, effective and safe method.*

**Keywords** – Bone and bones/injuries; Biocompatible materials; Ceramics; Durapatite

**INTRODUCTION**

Grafts are very necessary for correcting bone defects, which may have the aim of providing support, filling empty spaces or speeding up the biological repair of deficiencies in the bone framework.

Faced with situations requiring bone replacement, orthopedic surgeons can use autografts (autogenous or autologous grafts), homografts (homogenic or allogenic grafts) or heterografts (xenografts or heterologous or alloplastic grafts).

With regard to graft classification<sup>(1)</sup>, grafts are defined as autogenous when the tissue is transferred from one position to another, in the same individual, which consequently does not provoke any immune reaction after the transplantation; these grafts can consist of either cortical or medullary bone. Homogenous grafts consist of tissues grafted between individuals of the same species with non-identical genes, which may be fresh bone

or it may be conserved in a bone bank. These grafts are treated by means of freeze-drying, autoclaving, chemical preservation or irradiation so that they become free from cell activity<sup>(2)</sup>. Heterografts<sup>(1)</sup> are grafts made between individuals of different species. The use of bovine bones falls into this category. In the case of alloplastic grafts, an inert foreign body is implanted into the tissue, such as calcium phosphate, hydroxyapatite and bioceramics, among other types.

The biology of each of these grafts varies and may supply one or more of the essential components of osteogenesis, osteoinduction and osteoconduction<sup>(3)</sup>. The term osteogenesis denotes the cellular elements of the graft that survive the transplantation and are actively producing new bone. Nonetheless, although some cells in the graft may survive the transfer, the main sources of cells for this phase are the osteogenic and osteoprogenitor cells of the host. In osteoinduction, all materials are capable of inducing the transformation

1 – MSc and PhD in Orthopedics from Unifesp. Orthopedist and Head of the Residence Service, Hospital São Bento Cardioclínica S/A.

2 – MSc in Rehabilitation from Unifesp; PhD in General Pathology from UFMG. Resident Physician in Orthopedics and Traumatology, Hospital São Bento Cardioclínica S/A.

Work performed at Hospital São Bento Cardioclínica S/A.

Correspondence: Tania Clarete Fonseca Vieira Sales Sampaio, Rua Miguel Abras 11, Serra, 30220-160 Belo Horizonte, MG. E-mail: tania@sportsmed.com.br.

We declare that there is no conflict of interests in this article

of undifferentiated mesenchymal cells into osteoblasts or chondroblasts, thereby increasing bone growth or possibly forming bone where it is not expected. This mechanism has been recognized as dependent on several factors, including a specific protein: bone morphogenetic protein (BMP). Both cortical bone grafts and spongy bone grafts contain BMP in their matrix<sup>(4)</sup>. An osteoconducting matrix acts as a framework, and this occurs when a type of material (frequently inorganic) allows bone apposition on preexisting bone, thus requiring the presence of differentiated bone and mesenchymal cells. Osteoconductive material under soft tissue will not produce bone neoformation. Ideally, grafts should present a characteristic known as osseointegration, which is the chemical capacity to adhere to bone surfaces, without an intermediate layer of fibrous tissue<sup>(5)</sup>.

Autogenous spongy bone grafts are considered to be the gold standard because of their osteoconductivity, osteoinductiveness, osteogenic potential, absence of histocompatibility differences and incapacity to transmit infectious diseases. This standard graft has its own quota of problems, such as inadequate quantity (especially in children), donor site morbidity and potential complications such as pain, hematoma and infection<sup>(6,7)</sup>. To surmount these problems, biological alternatives have been used, particularly homografts and heterografts. However, limitations relating to ready availability, high cost, disease transmission and immunogenicity problems have accelerated the search for synthetic materials and inert biomaterials as alternatives. Calcium hydroxyapatite (HA) and  $\beta$  tricalcium phosphate ( $\beta$ -TCP), which belong to the calcium phosphate ceramic family, are biocompatible osteoconductive materials that offer a chemical environment and surface that are suitable for new bone formation<sup>(8-11)</sup>. Their efficacy as substitutes for autologous grafts to fill bone defects has been proven by several clinical and experimental studies<sup>(12-14)</sup>.

In bone reconstruction, grafts can be structural or non-structural. Structural grafts are used after major resection or segmental failures, and a graft with the structural capacity to reconstruct the bone defects is needed. Non-structural grafts are generally used to correct cavity defects: they do not have the capacity to withstand compressive forces and require complementary fixation.

The aim of this study was to present the results from using bioceramics to fill bone defects resulting from traumatic lesions and in situations of orthopedic etiology.

## SAMPLE AND METHODS

A prospective study was conducted in which 36 patients with bone defects of post-traumatic or orthopedic etiology were evaluated. The operations were conducted between May 2007 and November 2008. The mean duration of clinical and radiological follow-up was two years and the minimum was one year. All the patients underwent the surgical treatment using bioceramics at Hospital São Bento Cardioclínica, Belo Horizonte, Minas Gerais.

There were 19 male patients (52.8%) and 17 female patients (47.2%). Their ages ranged from 19 to 84 years, with a mean of 45.7 years and median of 37 years. Only patients with defects that required a minimum of five grams of bioceramics were included.

The bone defects were divided into two distinct groups: orthopedic (O) and post-traumatic (T). Eighteen cases were classified as orthopedic: these bone defects were observed in 11 cases of revision of total hip arthroplasty, one case of primary total hip arthroplasty due to coxarthrosis, five cases of open wedge femoral or tibial osteotomy and one case of tarsal arthrodesis. There were 18 cases of post-traumatic defect: eight cases of uninfected pseudarthrosis, three cases of recent fractures of the tibial plateau with compression of spongy bone and seven cases of exposed fractures that were treated with external fixation.

The surgical technique used in the group of orthopedic defects (O) consisted of curetting and debriding the lesion until bone that appeared suitable for grafting was found. Bioceramic was then used to fill the defect. This procedure was used during the arthroplasty revision surgery. In the cases of open wedge osteotomy, the wedge opening was filled with bioceramic and fixed with an angled plate. In the case of tarsal arthrodesis, after introducing the bioceramic, plaster cast immobilization was used.

In the operations on the group of post-traumatic defects (T), for the cases of tibial plateau fractures, in which there was a sunken appearance after fracture reduction, the bioceramic was placed as a graft to sustain the reduction that had been achieved and fill the empty space; the fractures were fixed using an L-shaped plate and screws. In treating the cases of pseudarthrosis, the deformities were corrected by removing the fibrosis from the focus and filling the bone defect with bioceramic. In general, a plate and screw were used for fixation.

Independent of etiology, the bone defects consisted of segmental and cavity types. The segmental bone defects were described in radiographic examinations as defects in which solution of continuity of the bone had occurred. On the other hand, the cavity defects did not present solution of continuity of the bone.

The size of the segmental bone defects was assessed from the radiographic examinations. Since the defects were irregular, with poorly defined edges, the measurements on the defect started with the largest dimension and a summed scale to the nearest 0.5 cm was used. The size of the bone defect was found to range from 3.5 cm to 1.0 cm, with a mean of 2.0 cm.

The size of the cavity defects was not measured because of the irregularities and difficulties in the volumetric measurements.

The bioceramic used was phosphocalcium ceramic composed of porous absorbable hydroxyapatite, with a mean grain size  $\leq 10$  MESH (MESH consists of the number of holes in a linear inch). The grain diameter was around 2.5 mm, found on the market under the name HAP-91<sup>®</sup> (JHS Laboratório Químico Ltda.).

The patients were evaluated clinically and radiologically. Cases were considered to have been resolved if they presented integration of the bioceramic, absence of pain, joint movement and functional capacity. It was not possible to biopsy the region treated. All the cases analyzed were radiographed before the operation, immediately after the operation and at a later time after the operation (minimum of six months). The criteria for

the final clinical and radiological assessment took two points into consideration:

- Deficient integration of the bioceramic; and
- Integration of the bioceramic.

## RESULT

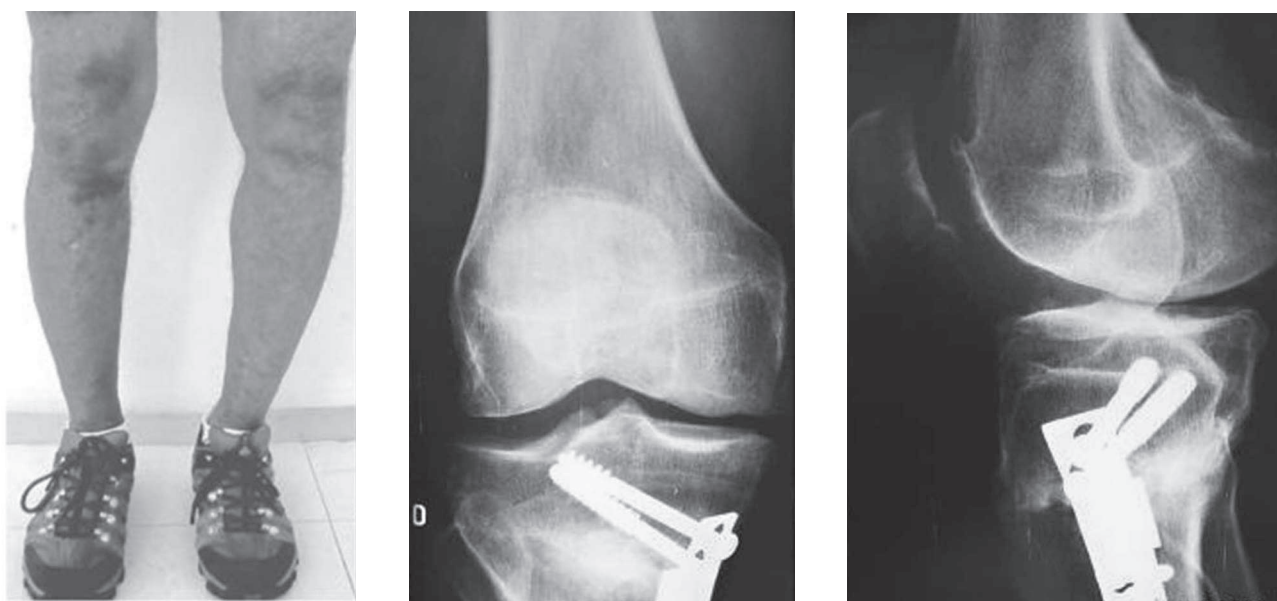Among the 36 patients evaluated, it was observed that 35 (97.2%) presented integration of the bioceramic and these cases were considered resolved. One case of an exposed fracture treated with external fixation presented deficient integration of the bioceramic, and new surgery involving grafting from the iliac crest was needed.

Figures 1, 2, 3 and 4 illustrate the process of bioceramic integration.

## DISCUSSION

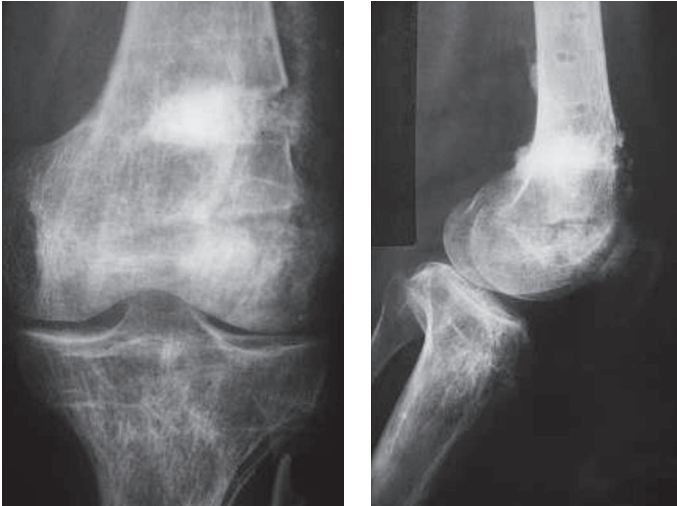
In orthopedics, bone defects are becoming increasingly frequent, mainly because of increasing incidence of high-energy accidents and arthroplasty revision. Their correction thus represents a challenge<sup>(15)</sup>. There are several alternatives for treating these bone defects, including the use of autogenous or homogenous bone grafts, combined with research and development on bone tissue replacement material, which presents the main advantages of avoiding the need to undertake a second surgical procedure to obtain the graft and diminishing the cost of storage in specific bone banks.

Autogenous grafts are the reference standard because of their basic characteristics and their osteoconductive,



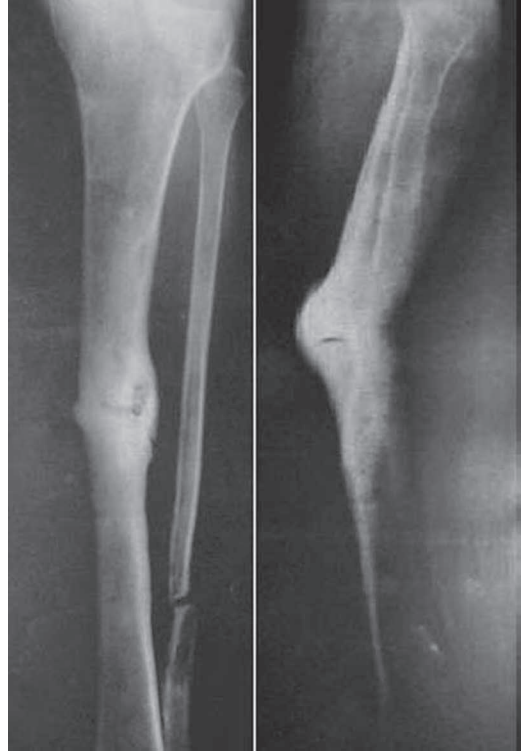Source: Photo from the files of Hospital São Bento Cardioclínica – BH/MG

**Figure 1** – Correction of tibial deformity using bioceramic

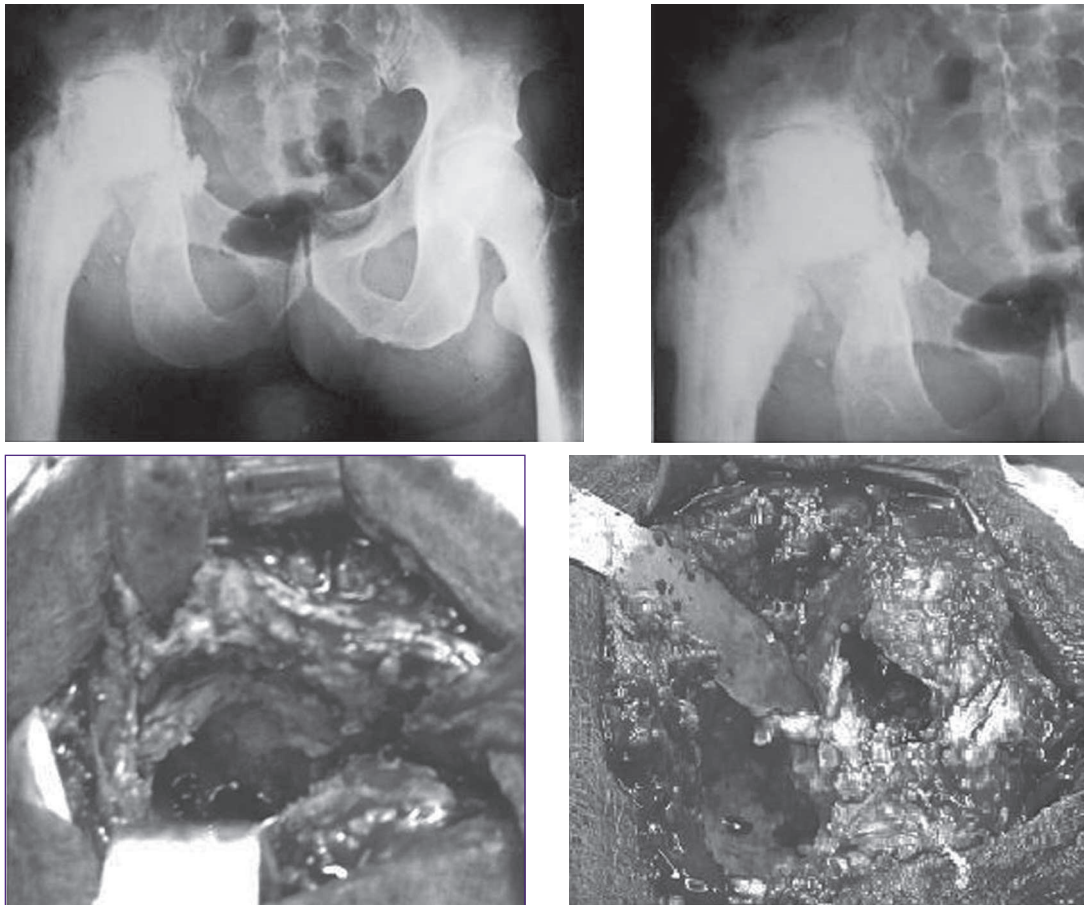


Source: Photo from the files of Hospital São Bento Cardioclínica – BH/MG  
**Figure 2** – Correction of femoral deformity using bioceramic.

osteoinductive and osteogenic properties. However, they have limitations resulting from donor site morbidity, considerable risk of infection and other limiting factors such as pain, reabsorption, loss of volume, need for new intervention, greater duration of surgery, greater bleeding and limited quantity.



Source: Photo from the files of Hospital São Bento Cardioclínica – BH/MG  
**Figure 4** – Treatment of tibial pseudarthrosis using bioceramic



Source: Photo from the files of Hospital São Bento Cardioclínica – BH/MG  
**Figure 3** – Sequela from loosening of a total hip prosthesis. It was necessary to remove the prosthesis and correct the acetabular bone defect with bioceramic and a spacer. Nine months later, bone formation was confirmed and a new prosthesis was inserted.

Homografts and heterografts are alternatives, but they generate disease transmission and tissue rejection risks.

One of the alternatives that seem increasingly promising is to use alloplastic materials. These not only have a filling function but also have the capability of leading towards structuring the area for the time required, thus enabling the bone regeneration process. For this, these materials need to have certain three-dimensional architectural characteristics, with surface topography, roughness and porosity, among other features, given that the induction process is geometry-dependent<sup>(16)</sup>.

Hydroxyapatite has been an alternative for use in bone defect repairs for the last 20 years. Recent developments have led to interest in the potential of porous hydroxyapatite as a synthetic bone graft<sup>(17)</sup>. In the present study, a totally metabolized phosphocalcium ceramic biomaterial known as absorbable porous hydroxyapatite was used. The crystalline salts deposited in the organic matrix of the bone were mainly composed of calcium and phosphates, and their structure was essentially that of hydroxyapatite. This material, which was placed next to the bone, functioned as a support for bone tissue regeneration. Thus, it allowed the regeneration tissue to grow within its physical structure because of the presence of pores, thus avoiding encapsulation due to fibrous connective tissue and increasing the speed of tissue growth. Synthetic calcium phosphate bone grafts have both osseointegration and osteoconductive properties. Osseointegration results from formation of a layer of hydroxyapatite after implantation. The  $\text{Ca}^{2+}$  and  $\text{PO}_4^{2-}$  ions needed to establish this layer are derived from the implant and the surrounding bone. The paths of both of these ions have been traced in serum and urine, without any significant rise in serum levels. From this, it can be concluded that they are treated as part of the pool of normal ions in the body. They

have an excellent record of biocompatibility, without any reports of systemic toxicity<sup>(18)</sup>.

The mechanical properties of hydroxyapatite do not make it appropriate for load-bearing applications. For this, fixation is required, along with a period of protection<sup>(16)</sup>. We did not use the bioceramic as a structural graft: its density does not allow bone formation inside it. Containment of the bioceramic is more difficult in segmental bone defects, since stable fixation is needed until bone consolidation has been achieved. Hence, we used the bioceramic in small segmental defects.

All the patients with bone defects of orthopedic cause evolved well, without interurrences, and bioceramic integration occurred. Out of the 18 patients with post-traumatic bone defects, only one presented deficient integration of the bioceramic, for which a new operation together with grafting from the iliac crest was needed.

Hydroxyapatite combined with bone marrow aspirate, because of its osteogenic property, has been used in several studies on bone regeneration, and good results have been demonstrated<sup>(13,14,19)</sup>.

Ceramics offer desirable characteristics such as biocompatibility for use as bone implants, chemical inertness in biological mediums and hardness, but they have low resistance to traction<sup>(20)</sup>. It needs to be emphasized that technical care is extremely important, in order to avoid extravasation of the bioceramic granules, given that they could cause abrasion and catastrophic failure because of their hardness.

## CONCLUSION

Treatment of bone defects of post-traumatic or orthopedic etiology was shown in this study, through the use of phosphocalcium ceramic composed of hydroxyapatite, to be a practical, effective and safe method.

## REFERENCES

- Costa OR, Veinstein FJ. Injertos oseos em regeneración periodontal. *Rev Asoc Odont Argent.* 1994;82(2):117-25.
- Fossum TW. *Cirurgia de pequenos animais.* São Paulo: Roca; 2002. p. 792 – 9; 848– 53.
- Misch CE, Dietsch F. Bone-grafting materials in implant dentistry. *Implant Dent.* 1993;2(3):158-67.
- Martinez SA, Walker T. Bone grafts. *Vet Clin North Am Small Anim Pract.* 1999;29(5):1207-19.
- Costantino PD, Friedman CD. Synthetic bone graft substitutes. *Otolaryngol Clin North Am.* 1994;27(5):1037-74.
- Giannoudis PV, Divinopoulos H, Tsiridis E. Bones substitutes: an update. *Injury.* 2005;36:S20.
- Finkemeier CG. Bone-grafting and bone-graft substitutes. *J Bone Joint Surg Am.* 2002;84(3):454-64.
- Jarcho M. Calcium phosphate ceramics as hard tissue prosthetics. *Clin Orthop Relat Res.* 1981;(157):259-78.
- Natarajan M, Dhanapal R, Kumaravel S, Selvaraj R, Uvaraj NR. The use of bovine calcium hydroxyapatite in filling defects following curettage of benign bone tumours. *Indian J Orthop.* 2003;37:192-4.
- Matsumine A, Myoui A, Kusuzaki K, Araki N, Seto M, Yoshikawa H, Uchida A. Calcium hydroxyapatite ceramic implants in bone tumour surgery. A long-term follow-up study. *J Bone Joint Surg Br.* 2004;86(5):719-25.
- Reddy R, Swamy MK. The use of hydroxyapatite as a bone graft substitute in orthopaedic conditions. *Indian J Orthop.* 2005;39(1):52-4.

12. Miranda ES, Cardoso FTS, Medeiros Filho JF, Barreto MDR, Teixeira RMM, Wanderley AL, et al. Estudo experimental comparativo no uso de enxerto ósseo orgânico e inorgânico no reparo de fraturas cirúrgicas em rádio de coelhos. *Acta Orthop Bras*. 2005;13(5):245-8.
13. Saikia KC, Bhattacharya TD, Bhuyan SK, Talukdar DJ, Saikia SP, Jitesh P. Calcium phosphate ceramics as bone graft substitutes in filling bone tumor defects. *Indian J Orthop*. 2008;42(2):169-72.
14. Bansal S, Chauhan V, Sharma S, Maheshwari R, Juyal A, Raghuvanshi S. Evaluation of hydroxyapatite and beta-tricalcium phosphate mixed with bone marrow aspirate as a bone graft substitute for posterolateral spinal fusion. *Indian J Orthop*. 2009;43(3):234-9.
15. Oonishi H, Iwaki Y, Kin N, Kushitani S, Murata N, Wakitani S, Imoto K. Hydroxyapatite in revision of total hip replacements with massive acetabular defects: 4- to 10-year clinical results. *J Bone Joint Surg Br*. 1997;79(1):87-92.
16. Azevedo VVC, Chaves SA, Bezerra DC, Costa ACFM. Materiais cerâmicos utilizados para implantes. *Revista Eletrônica de Materiais e Processos*. 2008; 3(1):31-9.
17. Hing KA, Best SM, Bonfield W. Characterization of porous hydroxyapatite. *J Mater Sci Mater Med*. 1999;10(3):135-45.
18. Moore WR, Graves SE, Bain GI. Synthetic bone graft substitutes. *ANZ J Surg*. 2001;71(6):354-61.
19. Zabeu JLA, Mercadante MT. Substitutos ósseos comparados ao enxerto ósseo autólogo em cirurgia ortopédica – Revisão sistemática da literatura. *Rev Bras Ortop*. 2008; 43(3):59-68.
20. Olsson DC, Pippi NL, Tognoli GK, Raiser AG. Comportamento biológico de matriz scaffold acrescida de células progenitoras na reparação óssea. *Ciência Rural*. 2008; 38(8):2403-12.