

Restrictive strabismus and gaze-evoked oculocardiac reflex following pterygium repair with fibrin glue

SAGE Open Medical Case Reports
Volume 10: 1–3
© The Author(s) 2022
Article reuse guidelines:
sagepub.com/journals-permissions
DOI: 10.1177/2050313X221122459
journals.sagepub.com/home/sco



Luai T Eldweik^{ID} and Shaikha Aljneibi

Abstract

Oculocardiac reflex is a phenomenon caused by traction applied to the extraocular muscles, or pressure on the globes. The afferent stimulus travels via the ophthalmic branch of cranial nerve V, and the efferent stimulus travels via cranial nerve X, which can cause severe bradycardia and potentially hypotension, atrioventricular block, ventricular ectopy, and rarely asystole. Oculocardiac reflex is different from vasovagal syncope which has another pathway, and is triggered by pain or emotional upset, that results in failure of autoregulation of blood pressure. Ophthalmologists often observe oculocardiac reflex intraoperatively upon manipulation of extraocular muscles during strabismus surgeries. We report a case with a previously undescribed complication following pterygium autograft with fibrin glue stimulating oculocardiac reflex resulting in episodes of sudden bradycardia associated with light headedness and nausea.

Keywords

Oculocardiac reflex, pterygium surgery, strabismus, diplopia, fibrin glue

Date received: 23 May 2022; accepted: 2 August 2022

Introduction

The oculocardiac reflex (OCR), also known as Aschner phenomenon, is a dysrhythmic physiological response caused by traction applied to extraocular muscles or compression of the eyeball.¹ Bradycardia and syncope are most commonly encountered with this reflex. We report the development of diplopia and pronounced OCR in a young patient with history of recurrent pterygium following excision with conjunctival autograft using fibrin glue.

Case report

A 21-year-old male patient referred to neuro-ophthalmology services for further evaluation of new onset of various symptoms that developed following recent surgery done for recurrent pterygium on the right eye. The patient complained of constant binocular double vision on the right gaze only; in addition, he also admitted that either while sitting or standing, whenever he looked toward the right side for more than a few seconds, he started experiencing nausea and dizziness; these symptoms resolved after seconds when he moved his eyes back to the straight position. The past medical history is significant for recurrent nasal

pterygium removal twice in the right eye. In June 2019, he underwent the bare sclera technique for nasal pterygium surgery in the right eye. Then, 4 months prior to consultation, he underwent extended excision of a recurrent right nasal pterygium with scarring, and conjunctival autograft secured using fibrin glue (Tisseel VH; Baxter International, Deerfield, IL, USA). Clinical exam revealed visual acuity 20/25 in the right eye and 20/20 in the left eye. Pupils were symmetrical with normal reactivity to light and near. Sensorimotor testing showed –1 abduction deficit in the right eye (Figure 1(a)). Alternate prism cover test showed incomitant strabismus with 8PD esotropia in right gaze, and small exophoria in primary position, and left gaze. Slit-lamp biomicroscopy of the right eye showed conjunctival scarring with a vertical conjunctival fold (semilunar fold) anterior to the medial rectus (Figure 1(b)). Using a portable pulse oximeter, we checked the baseline heart rate which

Eye Institute, Cleveland Clinic Abu Dhabi, Abu Dhabi, United Arab Emirates

Corresponding Author:

Luai Eldweik, Eye Institute, Cleveland Clinic Abu Dhabi, C7-257 Swing Wing, Al Maryah Island, Abu Dhabi 112412, United Arab Emirates.
Email: Eldweil@ClevelandClinicAbuDhabi.ae



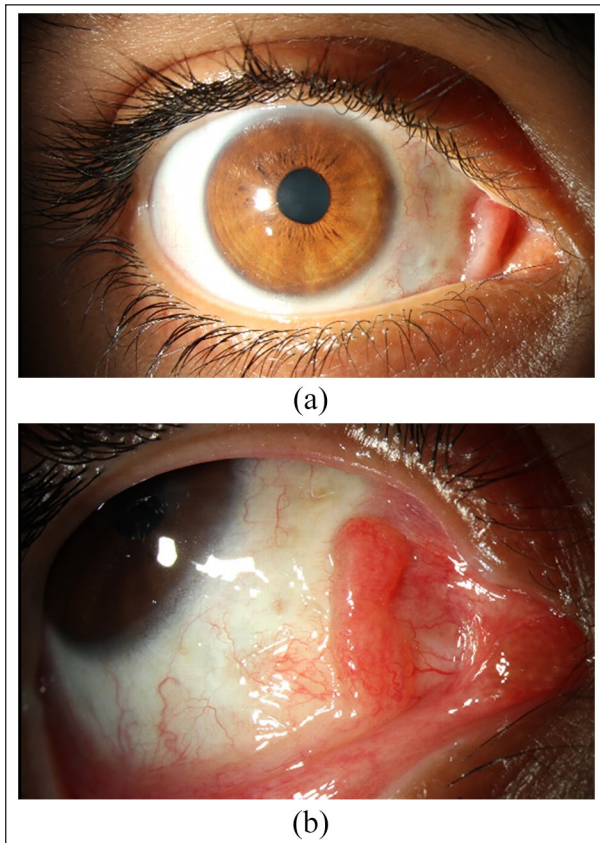


Figure 1. External photos obtained post-ptyerygium excision: (a) vertical semilunar conjunctival fold and (b) conjunctival scar anterior to medial rectus muscle with restriction of globe in contralateral gaze.

was 80–90 bpm, and it dropped to 55–60 bpm after looking to the right side for 10 s; this was reproducible many times during the visit. The sudden drop in the heart rate associated with vagal responses included dizziness and nausea. These findings were consistent with triggered OCR. We purposely avoided performing forced duction test as it may have induced further bradycardia; instead, we planned to perform forced ductions under general anesthesia with release of conjunctiva–perimuscular connective tissue adhesions, and ipsilateral medial rectus recession in case needed. However, the patient preferred to wait.

Discussion

Pterygium recurrence is the most common complication after its removal.² Conjunctival autografting is effective in preventing pterygium recurrence; this technique requires extended operative time due to fixation of conjunctival autograft. Usually, sutures are associated with postoperative discomfort, chronic inflammation, and granuloma formation. Cohen and McDonald first suggested fibrin glue is an alternative adhesive in 1993.³ Fibrin glue is a blood-derived product with two biologic components: fibrinogen and thrombin. Within seconds after mixing the components,

thrombin activates fibrinogen, an adhesive network is formed. Within days, the two components are digested, and this results in formation of a strong network between the transplant and the underlying tissue.³ Fibrin glue fixation requires a shorter operation time, and associated with less recurrence rate compared to the use of sutures, but its drawbacks include hypersensitivity reactions and potential risk for dehiscence.⁴

Postoperative diplopia is a complication that increases with pterygium recurrence. The number of previous pterygium excision surgeries can range from 1 to 3 surgeries in patients who develop strabismus.⁵ It may result from direct trauma or disinsertion of extraocular muscle. In addition, scar tissue formation, conjunctival loss, and obliteration of the fornix can also result in limited ocular rotation to contralateral gaze. Furthermore, these patients may also have an underlying predisposition to inflammatory cytokines that caused them to develop the recurrent pterygia in the first place.

In our patient, the nausea and dizziness were very unusual and difficult to explain by the double vision. When the patient was asked to provoke his symptoms by looking to the opposite direction a few times, there was profound rapid drop in his resting heart rate in each time, indicating stimulation of the OCR. Typically, bradycardia OCR is triggered by quick traction on extraocular muscles even with minimal force.⁶ However, this is not unique to the muscles, as cases of OCR upon conjunctival traction, dissection, and closure have been reported.⁷ We believe that previous scarring, and its location on top of the medial rectus, played a major role in this outcome. On the other hand, the use of fibrin glue to affix the graft might also contributed to this too, by providing an initial framework that resulted in the formation of more adhesions between the medial rectus and the overlying Tenon's capsule and conjunctiva, and also to the underlying sclera. In a case series of patients with postoperative restrictive strabismus following pterygium excision surgery, half of the patients had a graft placement with fibrin glue.⁸ During the treatment of the resulting diplopia, the same group found that securing the new grafts with sutures as opposed to glue this resulted in less inflammatory response. However, it is important to know the limitations related to the retrospective nature of this study and the small sample size. Therefore, the role of using fibrin glue in our patient remains unclear.

The correction of resulting strabismus in our patient would have included a combination of releasing scar tissue and possible medial rectus recession on adjustable suture, and given the history of OCR, special considerations should be followed including intraoperative use of anesthetic drops, limiting conjunctival manipulation, and considering cardiac monitoring and supine positioning, during adjustment.

We acknowledge the limitations of this case report including the lack of follow-up, and final closure. This case report describes a patient with atypical clinical presentation, to highlight the devastating effect of profound and repeatable OCR, and the potential of upright syncope.

Conclusion

With the high volume of pterygium excision, ophthalmologist should be aware of this complication. Avoiding bare sclera technique is recommended as it is associated with higher recurrence risk. Proper dissection of scar tissue and adhesions while operating on top or next to extraocular muscle and the judicious use of fibrin glue could lower the chances of postoperative complications.

Authorship

The author meets the current ICMJE criteria for Authorship.

Declaration of conflicting interests

The author(s) declared no potential conflicts of interest with respect to the research, authorship, and/or publication of this article.

Funding

The author(s) received no financial support for the research, authorship, and/or publication of this article.

Ethical approval

Our institution does not require ethical approval for reporting individual cases or case series.

Informed consent

Written informed consent was obtained from the patient for anonymized patient information to be published in this article.

Patient Consent

Written informed consent was obtained from the patient for anonymized patient information to be published in this article.

ORCID iD

Luai T Eldweik  <https://orcid.org/0000-0002-6504-646X>

References

1. Dunville LM, Sood G and Kramer J. *Oculocardiac reflex*. Treasure Island, FL: StatPearls Publishing, 2020, <https://www.ncbi.nlm.nih.gov/books/NBK499832/>
2. Nuzzi R and Tridico F. How to minimize pterygium recurrence rates: clinical perspectives. *Clin Ophthalmol* 2018; 12: 2347–2362.
3. Cohen RA and McDonald MB. Fixation of conjunctival autografts with an organic tissue adhesive. *Arch Ophthalmol* 1993; 111(9): 1167–1168.
4. Basmak H, Gursoy H, Cakmak AI, et al. Tissue adhesives as an alternative for conjunctival closure in strabismus surgeries. *Strabismus* 2011; 19(2): 59–62.
5. Ela-Dalman N, Velez FG and Rosenbaum AL. Incomitant esotropia following pterygium excision surgery. *Arch Ophthalmol* 2007; 125(3): 369–373.
6. Arnold RW. The oculocardiac reflex: a review. *Clin Ophthalmol* 2021; 15: 2693–2725.
7. Loewinger J, Friedmann-Neiger I, Cohen M, et al. Effects of atracurium and pancuronium on the oculocardiac reflex in children. *Anesth Analg* 1991; 73(1): 25–28.
8. Baxter SL, Nguyen BJ, Kinori M, et al. Identification and correction of restrictive strabismus after pterygium excision surgery. *Am J Ophthalmol* 2019; 202: 6–14.