

# Nasopharyngeal diffuse large B-cells lymphoma causing acute airway obstruction amid COVID-19 crisis: an anaesthetist's nightmare

Tat Boon Yeap,<sup>1</sup> Ming Kai Teah ,<sup>2</sup> Yen Ju Joanne Quay,<sup>2</sup> Melvin Teck Fui Wong<sup>2</sup>

<sup>1</sup>Medicine Based Disciplines Department, Faculty of Medicine and Health Sciences, Universiti Malaysia Sabah, Kota Kinabalu, Malaysia

<sup>2</sup>Department of Anaesthesia and Intensive Care Unit, Hospital Queen Elizabeth, Kota Kinabalu, Sabah, Malaysia

**Correspondence to**  
Dr Tat Boon Yeap;  
boontat@ums.edu.my

Accepted 19 January 2021

## SUMMARY

Acute stridor is often an airway emergency. We present a valuable experience handling an elderly woman who was initially treated as COVID-19 positive during the pandemic in November 2020. She needed an urgent tracheostomy due to nasopharyngeal (NP) diffuse large B-cell lymphoma causing acute airway obstruction. Fortunately, 1 hour later, her NP swab real-time PCR test result returned as SARS-CoV-2 negative. This interesting article depicts the importance of adequate preparations when handling potentially infectious patients with anticipated difficult airway and the perioperative issues associated with it.

## BACKGROUND

The WHO issued a pandemic alert on COVID-19 on 11 March 2020.<sup>1</sup> It has swept across the entire globe and caused major economic slowdown and health issues. Governments have imposed strict health guidelines to protect the public, especially the healthcare workers (HCW).

We share our valuable perioperative management on a patient who presented with acute stridor due to nasopharyngeal (NP) diffuse large B-cell lymphoma (DLBCL). She was initially treated as COVID-19 positive due to her originating from a location with high risk of COVID-19 exposure and concurrent respiratory symptoms. She underwent a successful tracheostomy. We highlight our experience in handling her anticipated difficult airway against the background of COVID-19 transmission-based isolation precautions.

## CASE PRESENTATION

A 62-year-old woman, with a comorbidity of hypertension, presented to our centre with a problem of bilateral neck swelling for 1-week duration, which was progressively increasing in size. It was associated with dysphagia, hoarseness of voice and stridor of 2 days. She claimed to have a weight loss of more than 20 kg over 4 months and loss of appetite. She also had runny nose with anosmia but denied fever.

On examination, she was alert with dry oral mucosa, emaciated and tachypnoeic with audible loud stridor. Her blood pressure was 110/72 mmHg, pulse rate at 98 beats/min and oxygen saturation (SpO<sub>2</sub>) at 97% on room air. Oral examination showed Mallampati 3 with bulging peritonsillar walls and uvula deviated to the left side.

## INVESTIGATIONS

- ▶ NP swab RT-PCR for COVID-19 results were unavailable prior to emergency tracheostomy.
- ▶ Bedside flexible laryngoscope showed distorted laryngeal structures with a huge mass appearing from the right piriform fossa, compressing on the vocal cords, causing it to be slit-like but mobile (figure 1).
- ▶ Chest X-ray showed minimal haziness at right lower zone of lung, but the trachea was centrally located with no neck masses seen.
- ▶ A CT of the neck had to be abandoned due to the impending total airway obstruction.
- ▶ Her baseline blood investigations showed hyponatraemia at 128 mmol/L (normal values: 135–145 mmol/L), hypokalaemia at 2.9 mmol/L (normal values: 3.5–5.0 mmol/L), hypomagnesaemia at 0.6 mmol/L (normal values at 1.0–1.2 mmol/L) and hypercalcaemia at 2.7 mmol/L (normal values: 2.0–2.5 mmol/L).
- ▶ Her arterial blood gas showed compensated respiratory acidosis.

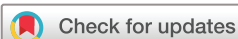## DIFFERENTIAL DIAGNOSIS

Our differential diagnoses at this juncture were large oropharyngeal or parapharyngeal tumor, neck abscess and lymphoma.

## TREATMENT

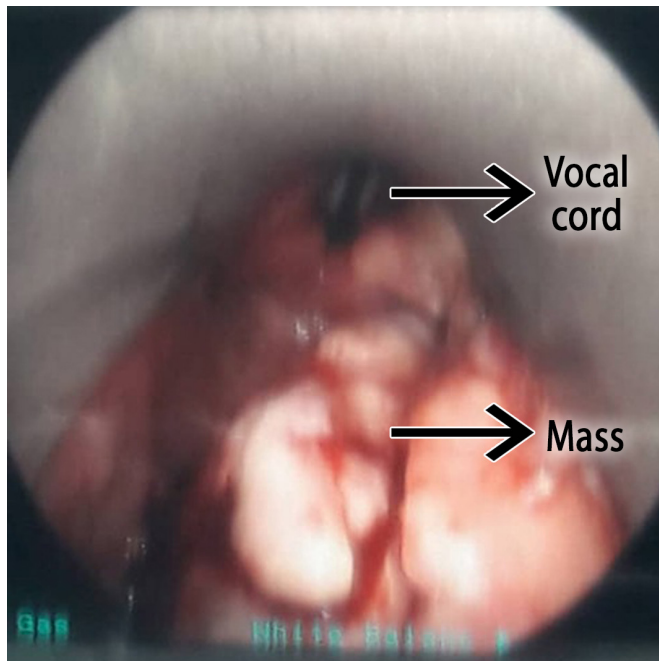
Due to the impending airway obstruction, the patient was posted for an urgent tracheostomy and airway examination in the operating theatre, taking into consideration that the result of her NP swab RT-PCR for COVID-19 was still unavailable.

At this point of writing, COVID-19 pandemic in Malaysia was still rampant. Thus, immense preparation was carried out to protect the safety of the HCW involved. As such, the anaesthetic plan was to have a tracheostomy done under local anaesthesia (LA) with minimal interruption to the patient's physiological reserves and haemodynamics. She was gently positioned on the operating table to avoid worsening of stridor, which could complicate laryngospasm and total airway obstruction. Bupivacaine 0.5% with epinephrine 1:100 000 (total dosage 75 mg) was infiltrated into the tissues at the level of second and third tracheal rings. Our team of experienced otorhinolaryngology (ORL) surgeons successfully performed the tracheostomy and a 7.5 mm cuffed tracheostomy tube was inserted. General anaesthesia was subsequently administered to facilitate airway assessment. The tidal volume



© BMJ Publishing Group Limited 2021. No commercial re-use. See rights and permissions. Published by BMJ.

**To cite:** Yeap TB, Teah MK, Quay YJ, et al. *BMJ Case Rep* 2021;**14**:e241008. doi:10.1136/bcr-2020-241008



**Figure 1** Anterior view of the bedside flexible laryngoscope showing a huge nasopharyngeal mass originating from the right side. The vocal cord was compressed and slit like.

and airway pressures were achieved within normal values. Fluid boluses and electrolytes replacement were administered intraoperatively.

Bronchoscopy and oesophagoscopy were normal. Direct laryngoscopy showed a large mass originating from right pyriform sinus, compressing on the vocal cord. There was a huge mass seen, which originated from the foramen of Rossemuller with no pus present. It was friable to touch with contact bleeding. Multiple tissue samples were obtained for histopathological examination (HPE). The procedure was uneventful; thus, the patient was sent back to ward on a tracheostomy mask running 40% oxygen. She was weaned down to room air on the next day and her RT-PCR swab for COVID-19 returned as SARS-CoV-2 negative.

#### OUTCOME AND FOLLOW-UP

A postoperative CT of the thorax, abdomen, pelvis and brain showed no distant metastasis. The HPE result showed tumour cells having large, irregular nuclei with scant to moderate amount of pinkish cytoplasm. The nuclei were hyperchromatic to vesicular with some cells exhibiting more than one nucleolus. Mitosis was brisk with atypical forms seen with areas of necrosis. Immunohistochemical study showed that tumour cells were strong and diffusely positive for CD20+, ECL 6+ and MUM 1+. This concluded the diagnosis of large B cells lymphoma of the nasopharynx.

The patient underwent a successful radical neck dissection 2 weeks later and chemotherapy. She recuperated well and would be followed up in the clinic on a monthly basis.

#### DISCUSSION

This is a significant case for discussion. First, this patient presented with signs of an acute impending airway obstruction needing an urgent intervention in the setting of the COVID-19 global pandemic. Second, this was an uncommon NP DLBCL.

At the point of writing, the world has been hit by the deadly COVID-19 pandemic with no proven vaccine in sight. Economic growth has halted, and large amounts of monies have been invested to protect HCW and patients. Malaysia was not spared of this crisis.<sup>2</sup> Our health ministry issued strict guidelines in managing patients with confirmed and potential COVID-19 undergoing surgeries. All hospitalised patients are screened via NP swab RT-PCR to detect COVID-19. As there are many community screenings in Sabah, some 1800 km to the east of Kuala Lumpur, it takes 3–5 days for the results to be released. Patients needing life-saving surgeries will have to be treated as COVID-19 positive and isolation precautions are made mandatory in operating theatres.<sup>3 4</sup>

Stridor is caused by an abnormal airflow and signifies an impending upper airway obstruction at the level of supraglottis, glottis or trachea. Common causes are epiglottitis, retropharyngeal or parapharyngeal abscesses, enlarging oropharyngeal/parapharyngeal carcinoma or foreign body aspiration. They cause acute narrowing of the upper airway thus limiting oxygen flow to the lungs. It is commonly an emergency and the airway must be urgently secured by way of intubation or tracheostomy. Acute stridor should be managed in a coordinated manner in the operating theatre by an experienced anaesthetist with the ORL team. The principle of management is to gently secure the airway, avoid total obstruction, prevent severe hypoxaemia and cardiorespiratory embarrassment. This can be achieved by either awake fiberoptic intubation, induction with inhalational agents without muscle relaxants followed by video laryngoscopy, or tracheostomy under LA.

In the setting of COVID-19, aerosol generating procedures such as intubation and oesophagoscopy are extremely risky to HCW. Thus, every effort is focused to minimise contracting COVID-19 by shortening the duration of the proceduralist's exposure to the patient's airway and donning adequate personal protective equipment (PPE).<sup>4</sup> In our scenario, we were walking on a thin line—to successfully secure the patient's airway and protect ourselves against COVID-19. A highly skilled anaesthetist was present to handle the airway together with the most experienced ORL surgeon. The patient was briefed and coaxed to understand the situation to avoid discomfort and airway trauma. In this case, we opted to secure the airway by mode of tracheostomy under LA. This was carefully decided after taking into account the very large mass seen in the supraglottis; we were worried that the endotracheal tube might not easily enter the vocal cord or there might be a mass extending below it. We also feared of causing contact bleeding from the tumour, which would cause aspiration pneumonitis.

We faced several difficulties while managing this challenging case. Double and sometimes, triple layers of PPE made it difficult for us to communicate and we had to speak loudly to convey our messages. Owing to the use of thick face masks, shields and jump suit, it was difficult for us to feel for the patient's veins or visualise the patient's airway. The surgeons also had a hard time feeling for the patient's tracheal rings due to poor tactile response caused by the many layers of gloves worn. As our patient was having stridor, tachypnoeic and agitated, we had to reassure her repeatedly. The anaesthetic team was not keen to give opioids as analgesic agent which could have precipitated apnoea, chest wall rigidity and total airway obstruction. There were also difficulties in handling the anaesthetic machine, endoscopes and surgical

instruments as they were carefully coated with thick sterile disposable plastics to avoid contaminations.

NP lymphoma is an extremely rare extranodal haematological malignancy.<sup>5</sup> There are two subtypes of NP lymphoma—Hodgkin lymphoma and non-Hodgkin's lymphoma (NHL). The latter is the most common among Asians amounting to about 90% of lymphoma cases. DLBCL, a subtype of NHL, is the most common NP lymphoma with a higher male preponderance and affecting average age group of 59.6 years old.<sup>5–7</sup> Patients with NP lymphoma often present with signs and symptoms such as neck mass, nasal discharge, and epistaxis.<sup>6</sup> However, they may also present with B symptoms such as weight loss, fever and night sweats. These symptoms were present in our patient and had contributed to her dehydration and electrolytes imbalances. As Malaysia is endemic for nasopharyngeal carcinoma (NPC), it is crucial to differentiate it from NP lymphoma.<sup>8</sup> The only way is by clinical deduction and histological examination. Epstein Barr virus (EBV) has been linked to the pathogenesis of NPC. However, there are limited studies on

its role in NP lymphoma. The expression of EBV-encoded small RNAs is controversial in DLBCL.<sup>5</sup> In our patient, staining for EBV was not done due to financial constraints and the outcome of the results would not change the future management. The principles of management for patients with NP lymphoma include symptomatic surgical resection of tumour, commencement of arthracycline chemotherapy and radiotherapy.<sup>9</sup> According to Zou *et al*, the 5-year survival rates for DLBCL is 69.5%.<sup>10</sup>

**Acknowledgements** The authors would like to thank BMJ for allowing them to submit their manuscript. This is an interesting manuscript which occurred during the COVID-19 pandemic in Malaysia. They would like to share their valuable experiences handling it.

**Contributors** TBY, MTFW and YJJQ are the managing anaesthetists for this case. MKT is the coauthor of this manuscript.

**Funding** The authors have not declared a specific grant for this research from any funding agency in the public, commercial or not-for-profit sectors.

**Competing interests** None declared.

**Patient consent for publication** Obtained.

**Provenance and peer review** Not commissioned; externally peer reviewed.

This article is made freely available for use in accordance with BMJ's website terms and conditions for the duration of the covid-19 pandemic or until otherwise determined by BMJ. You may use, download and print the article for any lawful, non-commercial purpose (including text and data mining) provided that all copyright notices and trade marks are retained.

#### ORCID iD

Ming Kai Teah <http://orcid.org/0000-0002-3076-2116>

#### REFERENCES

- 1 WHO. Coronavirus disease (COVID-19) outbreak. Available: <https://www.euro.who.int/en/health-topics/health-emergencies/coronavirus-covid-19>
- 2 Elengoe A. COVID-19 outbreak in Malaysia. *Osong Public Health Res Perspect* 2020;11:93–100.
- 3 COVID-19 Malaysia. COVID-19 Malaysia updates, 2020. Available: <<http://covid-19.moh.gov.my/>>
- 4 Asahq.org. Coronavirus (2019-Ncov) COVID-19, 2020. Available: <<https://www.asahq.org/about-asa/governance-and-committees/asa-committees/committee-on-occupational-health/coronavirus>>
- 5 Hsueh C-Y, Yang C-F, Gau J-P, *et al*. Nasopharyngeal lymphoma: a 22-year review of 35 cases. *J Clin Med* 2019;8:jcm8101604 doi:10.3390/jcm8101604
- 6 Allam W, Ismaili N, Elmajjaoui S, *et al*. Primary nasopharyngeal non-Hodgkin lymphomas: a retrospective review of 26 Moroccan patients. *BMC Ear Nose Throat Disord* 2009;9:11.
- 7 Sun J, Yang Q, Lu Z. Distribution of lymphoid neoplasms in China: analysis of 4,638 cases according to the world Health organization classification. *Am J Clin Pathol* 2012;138:429–34.
- 8 Devi BC, Pisani P, Tang TS. High incidence of nasopharyngeal carcinoma in native people of Sarawak, Borneo island. *Cancer Epidemiology and Prevention Biomarkers* 2004;13:482–6.
- 9 Yamaguchi M, Miyazaki K. Current treatment approaches for NK/T-cell lymphoma. *J Clin Exp Hematop* 2017;57:98–108.
- 10 Zou G-R, Zhang Y-J, Xie F-Y, *et al*. [Prognosis and treatment strategies of primary B-cell and NK/T-cell nasopharyngeal non-Hodgkin's lymphoma at early stage]. *Ai Zheng* 2006;25:1543.

#### Patient's perspective

Having a near death experience in the time of COVID-19 is the worst nightmare for anyone. So much so that I was diagnosed with a tumour in my oral cavity, which turned out to be a nasopharyngeal lymphoma. I am very grateful to the doctors who had worked hard to save my life during the crisis. Most importantly, I am happy that neither myself nor the hospital teams were positive for COVID-19. I am glad that the hospital authorities took very good care of me during my acute hospitalisation. I hope to share this wonderful experience with readers all over the world via BMJ.

#### Learning points

- ▶ Considerable attention must be given while handling potentially infectious patients with the main aim on protecting healthcare worker.
- ▶ Patients who present with acute stridor is usually an airway emergency.
- ▶ Managing a patient with acute airway obstruction in a challenging environment is extremely difficult.
- ▶ Anaesthetists should be well trained in handling patients with COVID-19 with difficult airway.
- ▶ Nasopharyngeal diffuse large B-cell lymphoma is an extremely uncommon presentation of head and neck tumours with good prognosis.

Copyright 2021 BMJ Publishing Group. All rights reserved. For permission to reuse any of this content visit <https://www.bmj.com/company/products-services/rights-and-licensing/permissions/>  
BMJ Case Report Fellows may re-use this article for personal use and teaching without any further permission.

Become a Fellow of BMJ Case Reports today and you can:

- ▶ Submit as many cases as you like
- ▶ Enjoy fast sympathetic peer review and rapid publication of accepted articles
- ▶ Access all the published articles
- ▶ Re-use any of the published material for personal use and teaching without further permission

### **Customer Service**

If you have any further queries about your subscription, please contact our customer services team on +44 (0) 207111 1105 or via email at [support@bmj.com](mailto:support@bmj.com).

Visit [casereports.bmj.com](http://casereports.bmj.com) for more articles like this and to become a Fellow