

Available online at www.sciencedirect.com

ScienceDirect

journal homepage: www.elsevier.com/locate/radcr

Case Report

Bronchial artery pseudoaneurysm presenting with hoarseness: Diagnosis and endovascular management ☆☆☆

Eric Yu Wei Lo, MBBS, BMedSci, MSc^{a,*}, Nicholas Viiala, MBBS, FRCPA, FRACP^{b,e}, Jules Catt, MBBS (Hons), BSc, MPH, FRANZCR, EBIR^c, Bruce French, MBBS, FRACS^{a,d}

^a Department of Cardiothoracic Surgery, Liverpool Hospital, Elizabeth Street, Liverpool, NSW, 2170, Australia

^b Department of Haematology, Liverpool Hospital, Elizabeth Street, Liverpool, NSW, 2170, Australia

^c Department of Interventional Radiology, Liverpool Hospital, Elizabeth Street, Liverpool, NSW, 2170, Australia

^d University of Western Sydney, Liverpool, NSW, 2170 Australia

^e South Western Sydney Clinical School, University of NSW, Kensington, Australia

ARTICLE INFO

Article history:

Received 5 May 2022

Revised 17 July 2022

Accepted 23 July 2022

Keywords:

Cardiothoracic surgery

Intervention radiology

Dysphonia

ABSTRACT

Bronchial artery pseudoaneurysm is a rare entity which is diagnosed radiologically; with or without symptoms. Symptoms of phonation changes with bronchial artery pseudoaneurysm are yet to be reported. This article describes the case of a 56-year-old man who presented with a history of a hoarse voice. This was investigated with computed tomography of his chest which diagnosed a bronchial artery pseudoaneurysm under the arch of the aorta. He was subsequently treated with coil embolization. The original symptoms improved with this intervention. This case highlights the rare presentation of hoarseness of voice in this rare condition.

Crown Copyright © 2022 Published by Elsevier Inc. on behalf of University of Washington.

This is an open access article under the CC BY-NC-ND license

(<http://creativecommons.org/licenses/by-nc-nd/4.0/>)

Introduction

Bronchial artery pseudoaneurysm is a rare pathology that has been reported only in less than 1% of patients who underwent selective bronchial angiography [1]. Bronchial artery aneurysm or pseudoaneurysm is used interchangeably in the

literature [2]. Presentation of this pathology can include massive hemoptysis when the pseudoaneurysm has already ruptured [3], symptomatic large pseudoaneurysms that mimic mediastinal tumors with mass effect [1] and asymptomatic pseudoaneurysm found incidentally [1,4,5]. This case report describes a rare presentation of a left bronchial artery pseudoaneurysm and its management.

☆ Competing Interests: Nothing to declare.

☆☆ Funding: Nothing to declare.

* Corresponding author.

E-mail address: ericyuweilo@gmail.com (E.Y.W. Lo).

<https://doi.org/10.1016/j.radcr.2022.07.087>

1930-0433/Crown Copyright © 2022 Published by Elsevier Inc. on behalf of University of Washington. This is an open access article under the CC BY-NC-ND license (<http://creativecommons.org/licenses/by-nc-nd/4.0/>)

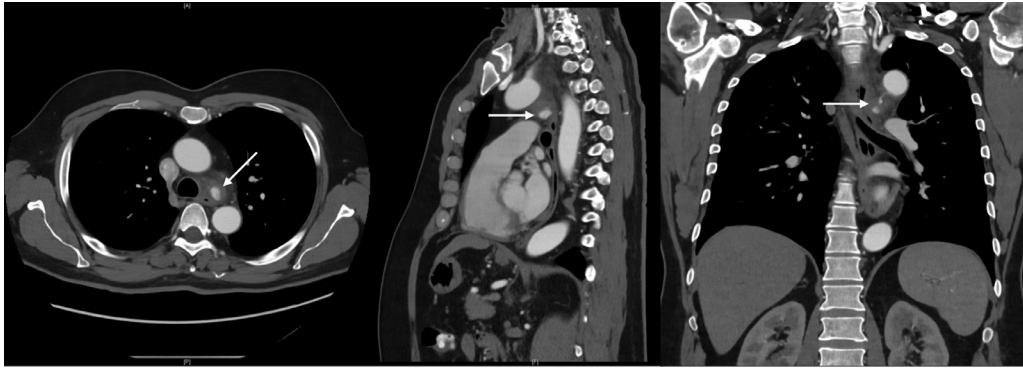


Fig. 1 – Contrast enhanced computed tomography of the chest (axial, sagittal, and coronal images) demonstrating the pseudoaneurysm originating from the distal arch with associated hematoma and fat stranding under the arch of the aorta; arrows locate the pseudoaneurysm.

Presentation

A 56-year-old man was seen routinely in the Haematology Outpatient Clinic for follow up of long standing mild-moderate idiopathic thrombocytopenia. A hoarse voice was noted and was explained to have been present for several weeks, previously attributed to bacterial laryngitis, and progressive despite oral antibiotic therapy. Further questioning in light of subsequent imaging results revealed an episode of choking while ingesting chicken four weeks prior to presentation.

The patient denied any cough, hemoptysis, nor any systemic features including fevers, sweats, rigors, or weight loss. There had been no recent interventions (including dental procedures) which may have caused bacteraemia.

To investigate this presentation, a computed tomography of the chest, abdomen and pelvis was performed and revealed a pseudoaneurysm of the bronchial artery from the under surface of the distal aortic arch. It was considered to be acute with presence of hematoma and surrounding fat stranding (Fig. 1).

Subsequently, the patient was reviewed by interventional radiology that urgently embarked upon coil embolization of the bronchial artery pseudoaneurysm via right femoral artery access (Fig. 2). From day one post intervention, it was noted that his initial presenting complaint was improving, with hoarseness of voice improved from before the procedure.

Direct visualization of the vocal cords by fine nasal endoscopy found a left vocal cord palsy with the left vocal cord fixed in a paramedian position with compensation from the right vocal cord. In concert with speech pathology, a plan to follow in the community to monitor recovery of left vocal cord palsy with the possibility for further intervention with botulinum toxin injection if required.

The cause of the pseudoaneurysm was sought. To rule out an infective cause, the following tests were performed and were negative: repeated empirical blood cultures, HIV, syphilis serology, Q fever testing, Phase 1 and 2 antibodies, *Coxiella burnetii*, and cryptococcal antigen testing, a transthoracic echocardiogram and positron emission tomography scan which both were negative for occult infection and other diseases, with the later demonstrating nonspecific inflammatory

change at the site of the pseudoaneurysm. Autoimmune vasculitides were screened for without any further diagnosis. At 3 months follow up, the patient had not developed further issues related to the bronchial artery pseudoaneurysm.

Discussion

This case presentation notably included a rare symptom of bronchial artery pseudoaneurysm due to mass effect. Previously dysphagic symptoms have been reported due to mimicry of mediastinal tumors and the mass effect on the esophagus [1]. Here, as an extension to that, the mass effect from the acute expanding pseudoaneurysm has compressed the recurrent laryngeal nerve as it has passed under the arch of the aorta, leading to the left vocal cord palsy and the clinical presentation of a hoarse voice. The majority of causes of vocal cord paralysis are encompassable in three groups: firstly, tumor related; secondly, surgical or traumatic; and finally idiopathic [6]. Phonation changes are the overwhelming majority of as the reason for referral and further investigation in patients with vocal cord paralysis [6]. As recommended, vocal cord paralysis is indicative of an underlying cause and these patients need an integrated investigation and management approach [6].

The gold standard for diagnosis of bronchial artery pseudoaneurysm is via multiphasic computed tomography [4]. Once diagnosed, it is recommended that immediate treatment is required as their progression to rupture is unpredictable and also unrelated to size [1,7].

Surgical management of ruptured bronchial pseudoaneurysm has previously been described via thoracotomy with the use of cardiopulmonary bypass [7]. Open identification and ligation and lung resection have been described and previously particularly in the hemodynamically unstable patient with large hemoptysis where bronchial artery pseudoaneurysm is diagnosed or suspected [7]. More contemporaneous reports have reiterated the safety and efficacy of transcatheter approaches to the incidental finding of bronchial artery pseudoaneurysm in the hemodynamically stable patient [1,4,8]. In patients with massive hemoptysis with active

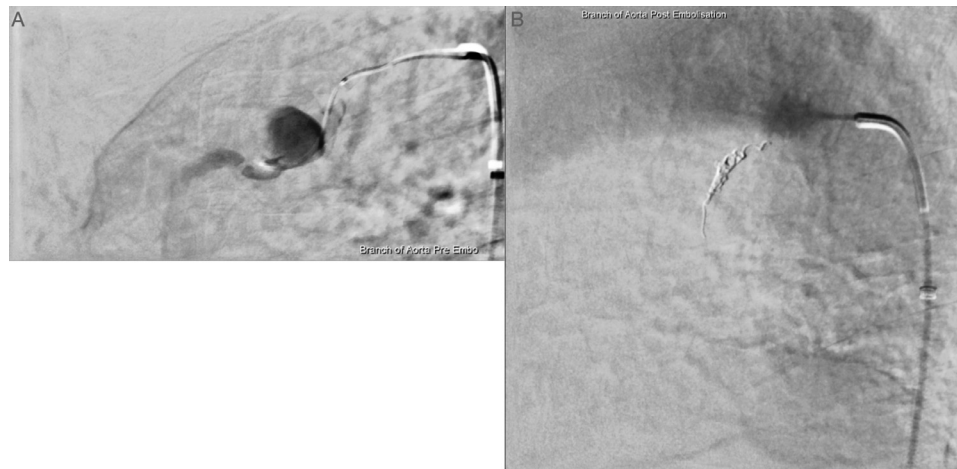


Fig. 2 – Digital subtraction angiography of the left bronchial artery pseudoaneurysm (A) pre-embolization and (B) postembolization.

bleeding from a ruptured bronchial artery pseudoaneurysm, bronchial artery angiogram, and embolization can be considered as the first line treatment [3]. This should be pursued with embolization with particles in the patient with massive hemoptysis.

Bronchial artery pseudoaneurysm is a rare pathology with potentially life threatening outcomes. Once diagnosed, intervention is indicated via a transcatheter approach due to the unpredictable progression. Furthermore, the common clinical presentation of phonation changes can have the rare but important cause of bronchial artery pseudoaneurysm that should be included in the differential diagnoses. This case highlights an unusual presentation of the entity and subsequent successful early intervention.

Patient consent

Informed and written consent for publication of their case was obtained from the patient.

REFERENCES

- [1] Tanaka K, Ihaya A, Horiuci T, Morioka K, Kimura T, Uesaka T, et al. Giant mediastinal bronchial artery aneurysm mimicking benign esophageal tumor: a case report and review of 26 cases from literature. *J Vasc Surg* 2003;38(5):1125–9. doi:[10.1016/s0741-5214\(03\)00707-9](https://doi.org/10.1016/s0741-5214(03)00707-9).
- [2] Yoon W, Kim JK, Kim YH, Chung TW, Kang HK. Bronchial and nonbronchial systemic artery embolization for life-threatening hemoptysis: a comprehensive review. *RadioGraphics* 2002;22(6):1395–409 2002/11/01. doi:[10.1148/rg.226015180](https://doi.org/10.1148/rg.226015180).
- [3] Ueda R, Kotani Y, Tsujimoto T. A ruptured bronchial artery aneurysm with massive haemoptysis. *BMJ Case Rep* 2017;2017. doi:[10.1136/bcr-2017-220392](https://doi.org/10.1136/bcr-2017-220392).
- [4] Bouardi NEL, Alami B, Mounceffe GE, Haloua M, Lamrani YA, Boubbou M, et al. Mediastinal bronchial artery aneurysm presenting as an incidental mediastinal mass: a rare finding. *Radiol Case Rep* 2021;16(10):2835–40 2021/08/01. doi:[10.1016/j.radcr.2021.06.076](https://doi.org/10.1016/j.radcr.2021.06.076).
- [5] Wilson SR, Winger DI, Katz DS. CT visualization of mediastinal bronchial artery aneurysm. *AJR Am J Roentgenol* 2006;187(5):W544–5. doi:[10.2214/AJR.06.0291](https://doi.org/10.2214/AJR.06.0291).
- [6] Seyed Toutouchi SJ, Eydi M, Golzari SE, Ghaffari MR, Parvizian N. Vocal cord paralysis and its etiologies: a prospective study. *J Cardiovasc Thorac Res* 2014;6(1):47–50. doi:[10.5681/jcvtr.2014.009](https://doi.org/10.5681/jcvtr.2014.009).
- [7] Kalangos A, Khatchatourian G, Panos A, Faidutti B. Ruptured mediastinal bronchial artery aneurysm: a dilemma of diagnosis and therapeutic approach. *J Thoracic Cardiovasc Surg* 1997;114(5):853–6. doi:[10.1016/S0022-5223\(97\)70094-1](https://doi.org/10.1016/S0022-5223(97)70094-1).
- [8] Le-Jun F, Sun Y, Fan Y, Jin S. The effect of transcatheter bronchial artery embolization in five patients with bronchial artery aneurysm. *Postepy w kardiologii interwencyjnej = Adv Intervent Cardiol* 2020;16(3):330–5 2020/09. doi:[10.5114/aic.2020.99269](https://doi.org/10.5114/aic.2020.99269).