

Long-Term Results of Transcatheter Closure of Patent Ductus Arteriosus in Infants Using Amplatzer Duct Occluder

Mostafa Behjati-Ardakani*¹, MD; Mohammad-Amin Behjati-Ardakani²; Seyed-Habibolla Hosseini³, MD; Noormohammad Noori⁴, MD

1. Yazd Cardiovascular Research Center, Shahid Sadoughi University of Medical sciences, Yazd, Iran
2. Baqiyatallah University of Medical Sciences, Tehran, Iran
3. Department of Anesthesiology, Shahid Sadoughi University of Medical Sciences, Yazd, Iran
4. Department of Pediatrics, Zahedan University of Medical Sciences, Zahedan, Iran

Received: Nov 12, 2012; Accepted: Apr 09, 2013; First Online Available: May 27, 2013

Abstract

Objective: Patent ductus arteriosus (PDA) is one of the most frequently seen congenital heart diseases. Its closure is recommended because of the risk of infective endocarditis, as well as morbidity and mortality in the long. The aim of this study was to assess the long term results of the transcatheter closure of PDA in infants using amplatzer duct occlude (ADO).

Methods: From May 2004 to September 2011, forty eight infants underwent transcatheter closure of PDA. A lateral or right anterior oblique view aortogram was done to locate PDA and to measure its size. Before discharge, repeat aortogram was performed to evaluate eventual residual shunt and to confirm the appropriate deployment of the ADO. Follow up evaluations were done with transthoracic echocardiography at discharge, 1 month, 6 months, 12 months and yearly thereafter.

Findings: The mean age of patients at procedure was 9.18 ± 2.32 (range 3 to 12) months, mean weight 6.73 ± 1.16 (range 4.5 to 10.1) kg. The PDA occluded completely in 20 out of the 48 patients. Twenty four patients had trivial or mild shunt and two patients had moderate residual shunt which disappeared in one patient within 24 hours and other patient with moderate shunt in 1 month. One patient (age 8 months) had mild LPA stenosis. The device embolization occurred in two patients, immediately after the procedure in one and during night in the other patient

Conclusion: The long term results suggested that transcatheter closure of PDA using Amplatzer duct occluder is a safe and effective treatment in infants less than 1 year of age with minimal complications.

Iranian Journal of Pediatrics, Volume 23 (Number 4), August 2013, Pages: 411-416

Key Words: Patent Ductus Arteriosus; Transcatheter Closure; Congenital Heart Defect

Introduction

Patent ductus arteriosus (PDA) is the second most common form of congenital heart defects^[1]. This accounts for approximately 5-10 percent of all congenital heart defects. In the modern era, the

true incidence may be as high as 1 in 500 term newborns later in infancy, because many cases with silent PDA are discovered incidentally by echocardiography done for other purposes^[2]. Since 1939, surgical correction has become a gold standard for the treatment of PDA^[3].

* Corresponding Author;

Address: Cardiovascular Research Center, Afshar Hospital, Jomhuri Boulevard, Yazd, Islamic Republic of Iran

E-mail: dr_behjati@yahoo.com

© 2013 by Pediatrics Center of Excellence, Children's Medical Center, Tehran University of Medical Sciences, All rights reserved.

Since the first description of transcatheter closure of PDA with an Ivalon plug by Porstmann et al^[4] several other devices such as Duct-occluder device (coil)^[5] and Amplatzer duct occluder (ADO)^[6] have been developed. Immediate, short, and intermediate term results of transcatheter closure of PDA with ADO have been well documented^[7-9].

The purpose of this study was to evaluate the results of long term follow up of transcatheter closure of PDA using ADO in infants.

Subjects and Methods

From May 2004 to September 2011, forty eight patients (19 boys and 39 girls) underwent transcatheter closure of PDA. Age at procedure ranged from 4 to 12 (mean 9.18 ± 2.32) months. Median weight was 7 (range 4.5 to 10.1) kg.

Infants selected for transcatheter closure had clinical and echocardiographic features of a moderate to large PDA and weighed ≥ 4.5 kg. The inclusion criteria were (1) patients aged less than 12 months and (2) patients with a moderate to large isolated PDA. Exclusion criteria were (1) PDA associated with any other congenital heart disease which could be corrected surgically; (2) patients with significant cardiac and non-cardiac co-morbidities that could impact clinical outcome of duct closure as well as those with evidence of severe congestive heart failure; (3) PDA with severe pulmonary artery hypertension and right-to-left shunt; (4) patients with window-type PDA; (4) patients weighing < 4.5 kg. These patients had one or more of the following: symptoms and signs of cardiac failure, pulmonary hypertension, failure to thrive, and recurrent pneumonia. All patients had signs of significant left to right shunting through PDA with left ventricular volume overload and left atrial enlargement on transthoracic echocardiography. Associated congenital cardiac anomalies observed included ventricular septal defect (2 patients), mild pulmonary stenosis (1 patient), double outlet right ventricle, pulmonary stenosis (1 patient) and atrial septal defect (1 patient). Two of the patients had a moderate residual shunt following surgical ligation.

Device and procedure

Informed written consent was obtained prior to procedure from the parents of all patients. Procedures were done under general anesthesia. Right and left cardiac catheterization was performed for hemodynamic assessment and shunt estimation. Prophylactic antibiotics with 30mg/kg cefazoline was administered at beginning of the procedure and two subsequent doses 8 hours apart and 100IU/kg of sodium heparin was administered to maintain activated clotting time more than 250 sec after catheterizing the femoral artery.

A descending aortogram in right anterior oblique or lateral view was done with a 4 or 5 French pigtail catheter to define the morphology, the aortic ampulla, length of the duct, size of the duct at narrowest part and the center of the PDA (Fig. 1).

Subsequently, a 0.032 inch (0.8 mm) exchange wire was placed across the ductus from the pulmonary artery using a 4 or 5 French multipurpose catheter. Over the wire a 6 or 7 French long sheath (AGA Medical Corporation) was introduced from the right or left femoral vein through the ductus into the descending aorta. The ADO was chosen 1-2 mm larger than the narrowest part of the PDA. Under fluoroscopy guidance, the device was introduced into the delivery sheath and advanced into the descending aorta, where the retention disk was deployed. Then, the sheath and delivery cable were pulled back until extruded in descending Aorta against the aortic end of PDA, while a gentle tension was

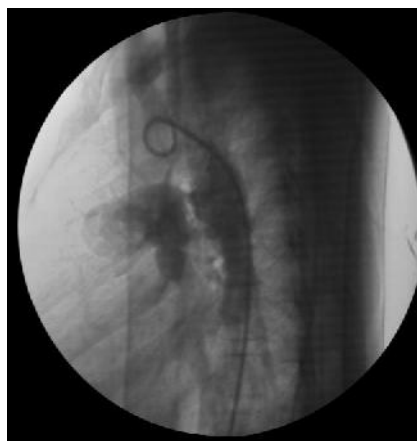

Fig. 1: Descending aortogram in lateral view showing medium sized patent ductus arteriosus

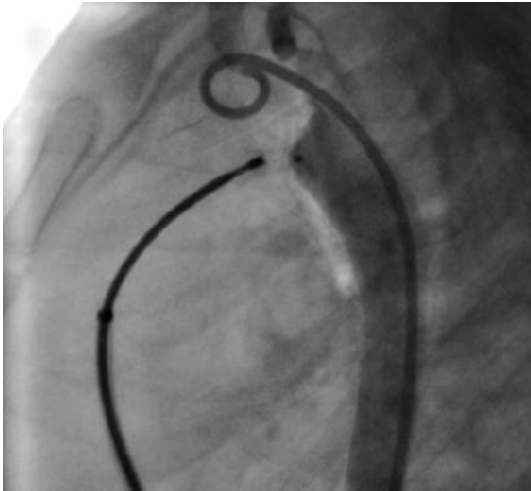


Fig. 2: Descending aortogram in lateral view before release of the amplatzer duct occlude showing no residual shunt and appropriate deployment of device

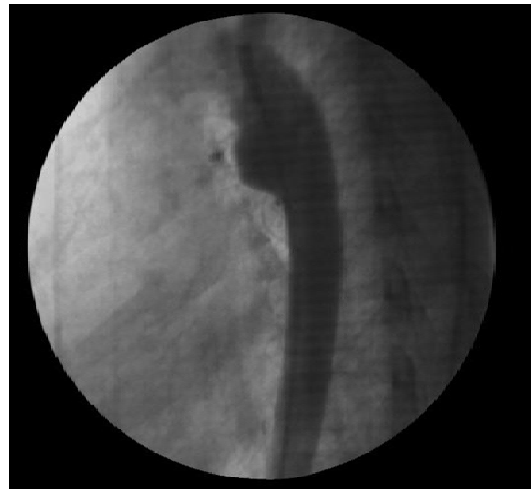

Fig. 3: Descending aortogram in lateral view after release of the amplatzer duct occlude showing complete occlusion and appropriate device position

maintained on delivery cable. The introducing sheath was withdrawn into the pulmonary artery to deploy the conical part of the ADO. With the device still attached to the cable, descending aortogram was performed to confirm proper device position and exclude aortic obstruction or significant residual shunt (Fig. 2).

The ADO was retracted into the delivery sheath if a significant shunt or aortic obstruction was detected. Once optimal position was confirmed, the device was released by counter-clockwise rotation of the delivery cable. Descending aortogram in lateral position before release of the device showed complete occlusion of PDA and appropriate device deployment (Fig. 2). A repeat angiogram was done 10 minutes after release to check for residual shunt or aortic obstruction. Fig. 3 shows descending aortogram in lateral view after release of the ADO showing complete occlusion and appropriate device position.

All patients were discharged on the next day after the procedure and given no medication. All patients had complete transthoracic echocardiographic studies before discharge, at 1, 6, and 12 months and then yearly thereafter. Endocarditis prophylaxis was discontinued at the six month's follow up if the duct was completely occluded.

Statistical analysis

Results are expressed as mean \pm SD, percentage, median and range. The data were analyzed with statistical program SPSS version 15.0.0 for

Windows. Continuous variables with normal distribution are expressed as mean [\pm standard deviation (SD)]. Continuous variables with inappropriate distribution are expressed as median.

Findings

The device was successfully deployed in 46 (95.8%) patients. Device embolization occurred in two (4%) patients. In one patient, distal embolization of device occurred immediately after the procedure. This device was successfully retrieved in catheterization laboratory and the patient underwent uneventful repeat device implantation for PDA occlusion. Another patient had a moderate shunt and device embolization in main PA and was referred for surgical removal and duct ligation.

Demographic and catheterization data of the patients undergoing transcatheter closure of PDA are listed in Table 1. In five patients, the devices were too small to close the defect; therefore, larger ADOs were implanted. Angiography at the end of the procedure demonstrated complete occlusion in 20 (41.6%) patients and residual shunt in 27 patients.

Among these twenty seven patients, twenty four had a trivial mesh leak shunt, one patient had

Table 1: Demographic and catheterization data of patients undergoing closure of PDA with amplatzer duct occluder

Parameter	Mean (Standard Deviation)	Median	Range
Age (month)	9.1 (3.2)	9.6	4-12
Weight (kg)	6.73 (1.16)	7	4.5-10.1
Mean PAP (mmHg)	31.96 (14.15)	29	10-70
QP/Qs	2.75 (0.85)	2.8	1.4-4.6
PDA size (mm)	5.7 (1.62)	5	3-9
Amplatzer duct occlude (mm)	5.29 (1.55)	4	4-10.1
Fluoroscopy Time (min)	6.23 (2.9)	6	2.7-17
Procedure Time (min)	48.68 (9.6)	49	28-67
Follow-up (mo)	37.9 (23.36)	33.4	13.7-89.8

PDA: Patent ductus arteriosus; PAP: Pulmonary Artery Pressure QP/QS: Pulmonary Blood Flow/ Systemic Blood Flow

small and two patients moderate shunt. On the following day, trivial mesh leak shunt disappeared completely in all cases. In one patient, there was a moderate residual shunt immediately 24 hours after procedure and complete occlusion was achieved 1 month after the procedure. Also in one patient who had small residual shunt, complete closure occurred within 24 hours after the procedure

Distal embolization of the device to main pulmonary occurred immediately after the procedure in one patient who had moderate residual shunt. This patient underwent surgical ligation after surgical removal of embolized device.

Mild left pulmonary stenosis (gradient ≤ 20 mmHg) via encroachment of device was detected in 1 patient. There was no evidence of obstruction of descending aorta as confirmed by angiography and Doppler-color echocardiography.

Thrombosis of right femoral artery or left femoral artery occurred in 6 and 2 patients respectively. Heparin infusion was used unsuccessfully in 3 patients. Streptokinase intravenous infusion (loading dose 10000 IU/kg over one hour followed by 10000 IU/kg for six hours) produced a successful and complete turn of pulse without sequelae in two patients. One other patient underwent femoral artery thrombectomy.

Mild inguinal hematoma occurred in two patients. One death (a 7-month old baby) occurred because of aspiration pneumonia five days after procedure. This patient had dextrocardia, large PDA, subsystemic PH, failure to thrive and congestive heart failure. Aspiration pneumonia occurred at home during bottle feeding. The patient was hospitalized, multiple antibiotics were administered and finally the patient died the same day due to fulminant pulmonary infection

and respiratory failure. Protrusion of ADO into descending aorta without obstruction occurred in 3 of 48 (6.25%) cases.

Follow up for short (one day to 6 months), intermediate (6 months - 12 months) and long period (>1 year) showed no significant complications such as device embolization or malposition, hemolysis, thrombus formation, thromboembolism and infectious endocarditis. Congestive heart failure, failure to thrive and recurrent pulmonary infection were significantly improved.

Discussion

This study reports the result of long term (37.9 ± 23.36 months, range 13.7 to 89.8 months) follow up in 46 infants who underwent transcatheter closure of PDA using Amplatzer duct occluder. Transcatheter closure of PDA is a well-established technique that has a low incidence of complication^[10]. Transcatheter closure of PDA with ADO has significantly improved the outcomes of the percutaneous closure of medium and large sized ducts^[11].

Several devices have been developed for PDA occlusion, currently, the only FDA-approved device for closure of PDA is the ADOI (AGA Medical Corporation, Golden Valley, Minnesota, USA). In our study USA made (AGA medical corporation, Golden Valley, Minnesota, USA, n=17) and China made (Starway Medical Supplies Ltd, n=31) forms of devices were used.

The ADOI is a self-expanding conical device with a single retention skirt and composed of a nitinol wire mesh with polyester fabric sewn into

the mesh to induce thrombosis; it received FDA approval in May 2003^[12].

The ADOI device has proved to be high effective in many reports^[8,13,16]. The major favorable features are easy implantation, small delivery sheath (5-8 Fr), possibility of retrieval, ability of repositioning before release of device, low complication and high rate of occlusion^[6,17,18].

Despite these advantages, transcatheter closure of PDA has rare complications, such as embolization, left pulmonary obstruction, descending aorta obstruction and femoral artery thrombosis^[7,19,20]. Late complications are more rarely described and only late embolization of device and hemolysis are reported^[21,22].

The result of our study of transcatheter PDA closure with ADO, with an occlusion rate of 95.7% at 24 hours, concur with results described in other reports^[23,24]. Although many patients had a residual shunt at the end of the procedure, only one patient had moderate residual shunt after 24 hours. This patient was found to have complete occlusion at 1-month follow up. The phenomenon demonstrates the advantages of plug type design of the ADO for occlusion of PDAs.

Faella and Hejazi ^[25] reported a large series of 360 patients with PDA occluded with the ADO. Closure was successful in all patients. Complication occurred in 6 patients: embolization 3, mild aortic obstruction due to large device in 1 patient and blood loss that required transfusion in 2 patients. Li JJ, et al^[22] reported the successful use of the ADO to occlude PDA over a long-term follow up of five years. According to this study, late complication occurred in 5 patients consisting of hemolysis in 3 patients and loss of the femoral artery in 2 patients. In our study no late complications such as embolization, hemolysis, left pulmonary artery or aortic obstruction occurred.

In our study, early device embolization occurred in one (2.1%) infant that required surgery. The reported rate of device embolization varies, between 0% to 3%^[26-30]. One patient required blood transfusion because of significant blood loss during procedure. Rarely, a left pulmonary (LPA) obstruction occurs after transcatheter closure using ADO^[12,25].

In current study, mild LPA obstruction (gradient <20 mmHg) occurred in one 8 months old patient. During follow up and with the

patient's growth, pressure gradient gradually decreased and normalized 25 months after the procedure. However in our study no late major complication such as stenosis in either the LPA or descending thoracic aorta, hemolysis and endocarditis occurred. This study confirmed effectiveness of transcatheter closure of PDA using ADO both early and during intermediate and long-term follow up the same results were described by other authors^[8,12,14,24,28,31].

A limitation of our study was its retrospective nature. Also, the learning curve for technique in the closure of PDA was not accounted for in the study.

Conclusion

Transcatheter closure of PDA with Amplatzer Duct Occluder in symptomatic infants is an effective and safe method for the treatment of medium to large PDA. The low incidence of complication and short hospital stay makes ADO ideal for transcatheter closure of medium to large PDA in infants. However, some complications including device embolization, left pulmonary stenosis and femoral artery thrombosis may have occurred in some cases.

Acknowledgement:

This study was supported by a grant from the Yazd cardiovascular research center. The authors wish to thank Dr MH Fallahzadeh for collecting data and statistical analysis. We also thank Sedigheh Bagheri and Aliakbar Ghafoori for preparation of the manuscript.

Conflict of Interest: None

References

1. Hammerman C. Patent ductus arteriosus. Clinical relevance of prostaglandins and prostaglandin inhibitors in PDA pathophysiology and treatment. *Clin Perinatol* 1995;22(2):457-79.
2. Lloyd TR, Beekman RH 3rd. Clinically silent patent ductus arteriosus. *Am Heart J* 1994;127(6):1664-5.

3. Mavroudis C, Backer CL, Gevitz M. Forty-six years of patent ductus arteriosus division at Children's Memorial Hospital of Chicago. Standards for comparison. *Ann Surg* 1994;220(3):402-9.
4. Porstmann W, Wierny L, Warnke H. Closure of persistent ductus arteriosus without thoracotomy. *Ger Med Mon* 1967;12(6):259-61.
5. Moore JW, Schneider DJ, Dimeglio D. The duct-occlud device: design, clinical results, and future directions. *J Interv Cardiol* 2001;14(2):231-7.
6. Masura J, Walsh KP, Thanopoulous B, et al. Catheter closure of moderate- to large-sized patent ductus arteriosus using the new Amplatzer duct occluder: immediate and short-term results. *J Am Coll Cardiol* 1998;31(4):878-82.
7. Butera G, De Rosa G, Chessa M, et al. Transcatheter closure of persistent ductus arteriosus with the Amplatzer duct occluder in very young symptomatic children. *Heart* 2004;90(12):1467-70.
8. Wang JK, Wu MH, Lin MT, et al. Transcatheter closure of moderate-to-large patent ductus arteriosus in infants using Amplatzer duct occluder. *Circ J* 2010;74(2):361-4.
9. Sivakumar K, Francis E, Krishnan P. Safety and feasibility of transcatheter closure of large patent ductus arteriosus measuring ≥ 4 mm in patients weighing ≤ 6 kg. *J Interv Cardiol* 2008;21(2):196-203.
10. Fernández Ruiz A, del Cerro Marín MJ, Rubio Vidal D, et al. Transcatheter closure of patent ductus arteriosus using the Amplatzer duct occluder: initial results and mid-term follow-up. *Rev Esp Cardiol* 2002;55(10):1057-62.
11. Thanopoulos BD, Tsaousis GS, Djukic M, et al. Transcatheter closure of high pulmonary artery pressure persistent ductus arteriosus with the Amplatzer muscular ventricular septal defect occluder. *Heart* 2002;87(3):260-3.
12. Pass RH, Hijazi Z, Hsu DT, et al. Multicenter USA Amplatzer patent ductus arteriosus occlusion device trial: initial and one-year results. *J Am Coll Cardiol* 2004;44(3):513-9.
13. Wang JK, Wu MH, Hwang JJ, et al. Transcatheter closure of moderate to large patent ductus arteriosus with the Amplatzer duct occluder. *Catheter Cardiovasc Interv* 2007;69(4):572-8.
14. Thanopoulos BV, Eleftherakis N, Tzannos K, et al. Further experience with catheter closure of patent ductus arteriosus using the new Amplatzer duct occluder in children. *Am J Cardiol* 2010;105(7):1005-9.
15. Choi DY, Kim NY, Jung MJ, et al. The results of transcatheter occlusion of patent ductus arteriosus: success rate and complications over 12 years in a single center. *Korean Circ J* 2010;40(5):230-4.
16. Shabbir M, Akhtar K, Maadullah, et al. Transcatheter closure of large sized patent ductus arteriosus using the amplatzer duct occluder device. *J Coll Physicians Surg Pak* 2009;19(5):275-8.
17. Al-Hamash SM, Wahab HA, Khalid ZH, et al. Transcatheter Closure of patent ductus arteriosus using Ado device: Retrospective study of 149 patients. *Heart Views* 2012;13(1):1-6.
18. Fernández Ruiz A, del Cerro Marín MJ, Rubio Vidal D, et al. Transcatheter closure of patent ductus arteriosus using the Amplatzer duct occluder: initial results and mid-term follow-up. *Rev Esp Cardiol* 2002;55(10):1057-62.
19. Vavuranakis M, Tzannos KA, Thanopoulos BD, et al. Severe hemolysis complicating transcatheter occlusion of a patent ductus arteriosus: the importance of elimination of residual flow. *Hellenic J Cardiol* 2007;48(6):373-6.
20. Galal MO. Advantages and disadvantages of coils for transcatheter closure of patent ductus arteriosus. *J Interv Cardiol* 2003;16(2):157-63.
21. McMullan DM, Moulick A, Jonas RA. Late embolization of Amplatzer patent ductus arteriosus occlusion device with thoracic aorta embedment. *Ann Thorac Surg* 2007;83(3):1177-9.
22. Li JJ, Li YF, Zhang ZW, et al. A follow up study on transcatheter closure of patent ductus arteriosus with Amplatzer duct occluder in children. *Zhonghua Er Ke Za Zhi* 2005;43(8):608-11.
23. Al-Motarreb A, Al-Hammadi M, Shamsan M, et al. Percutaneous transcatheter closure of patent ductus arteriosus using amplatzer duct occluder: First Yemeni experience. *Chin Med J (Engl)*. 2001; 114(5):456-8.
24. Masura J, Tittel P, Gavora P, et al. Long-term outcome of transcatheter patent ductus arteriosus closure using Amplatzer duct occluders. *Am Heart J* 2006;151(3):755.e7-755.e10.
25. Faella HJ, Hijazi ZM. Closure of the patent ductus arteriosus with the amplatzer PDA device: immediate results of the international clinical trial. *Catheter Cardiovasc Interv* 2000;51(1):50-4.
26. Al-Ata J, Arfi AM, Hussain A, et al. The efficacy and safety of the Amplatzer ductal occluder in young children and infants. *Cardiol Young* 2005; 15(3):279-85.
27. Ali Khan MA, al Yousef S, Mullins CE, et al. Experience with 205 procedures of transcatheter closure of ductus arteriosus in 182 patients, with special reference to residual shunts and long-term follow-up. *J Thorac Cardiovasc Surg* 1992;104(6):1721-7.
28. Jang GY, Son CS, Lee JW, et al. Complications after transcatheter closure of patent ductus arteriosus. *J Korean Med Sci* 2007;22(3):484-90.
29. Zhang Z, Qian M, Wang H, et al. Transcatheter closure in 354 pediatric cases of patent ductus arteriosus using five different devices. *Chin Med J (Engl)* 2001;114(5):456-8.
30. Behjati-Ardakani M, Forouzannia SK, Dehghani M, et al. Transcatheter closure of patent ductus arteriosus using the Amplatzer ductal occluder : early results and midterm follow-up. *J Tehran Heart Cent* 2008; 3(3):151-6.
31. Parra-Bravo R, Cruz-Ramírez A, Rebolledo-Pineda V, et al. Transcatheter closure of patent ductus arteriosus using the amplatzer duct occluder in infants under 1 year of age. *Rev Esp Cardiol* 2009; 62(8):867-74.