

Elastoplasty as a promising novel technique: Vertebral augmentation with an elastic silicone-based polymer



Alessandro Gasbarrini ^a, Riccardo Ghermandi ^a, Yunus Emre Akman ^{b, *}, Marco Girolami ^a, Stefano Boriani ^a

^a Istituto Ortopedico Rizzoli, Bologna, Italy

^b Metin Sabanci Baltalimani Bone Diseases Training and Research Hospital, Istanbul, Turkey

ARTICLE INFO

Article history:

Received 20 October 2016

Received in revised form

5 January 2017

Accepted 10 January 2017

Available online 13 February 2017

Keywords:

Elastoplasty

Vertebroplasty

Silicone

PMMA

Vertebral compression fracture

ABSTRACT

Objective: Percutaneous vertebroplasty with polymethylmethacrylate (PMMA) restores the stiffness and the strength of fractured vertebral bodies, but changes the pattern of the stress transfer. This effect may cause a secondary fracture of the adjacent vertebrae. Elastoplasty has emerged as a new technique to overcome this complication. The aim of this study is to retrospectively evaluate the clinical results of the elastoplasty procedure.

Materials and methods: Thirty nine patients (9 males, 30 females, 87 spinal levels) were clinically evaluated pre and postoperatively in terms of pain relief, leakage and silicone embolism. The mean age was 67 (range 38–84) years. The mean follow up period was 12.5 months. The patients were evaluated radiologically for the presence of adjacent level fractures postoperatively. Complications were recorded.

Results: The mean VAS score decreased from 7,5 to 3,5 during the last follow-up. Symptomatic silicone pulmonary embolism was not encountered in any patients. Leakage was observed in 5 (13%) cases. There was an adjacent level fracture in 1 case and another fracture which was not at the adjacent level in another one. A hematoma occurred in the needle entry site in a patient with thrombocytopenia (<70,000).

Conclusions: Elastoplasty is a safe, promising technique in the treatment of vertebral compression fractures (VCFs). Symptomatic silicone pulmonary embolism is not observed. The material's stiffness is close to intact vertebrae. Therefore, elastoplasty may be a good viable option in the treatment of VCFs as it cause less complications and can prevent adjacent level fractures.

Level of evidence: Level IV, therapeutic study.

© 2017 Turkish Association of Orthopaedics and Traumatology. Publishing services by Elsevier B.V. This is an open access article under the CC BY-NC-ND license (<http://creativecommons.org/licenses/by-nc-nd/4.0/>).

Introduction

Vertebroplasty (VP) which was first reported in 1987, is a minimally invasive technique performed to augment vertebral compression fractures (VCFs) with a filling material [typically polymethylmethacrylate (PMMA)].¹ Among the reported complications, there are subsequent fractures in both previously operated^{2–4} and in the adjacent vertebrae,^{5–7} possibly due to the addition of the material that is stiffer than the surrounding trabecular bone. Fahim et al suggested that aggressive cement

augmentation of the vertebral body may promote the endplate deflection fracture mechanism.⁸ Biomechanical and finite element studies demonstrated that vertebroplasty alters load transfer, resulting in increased stresses in adjacent endplates as well.^{9–11}

The application of augmentation materials, with stiffness close to intact vertebra, has been suggested to prevent subsequent fractures in VP.^{11,12} Elastoplasty performed with VK100 (BONWRX, Phoenix, AZ, USA), an elastic polysiloxane polymer (silicone) which is reported to show stiffness close to intact vertebrae,¹³ is a new alternative technique based on VP. As an hypothesis, with its similar mechanical properties to those of the trabecular bone of the vertebrae, VK100 may reduce the risk of subsequent fractures.

In the literature, there are very few studies on this novel technique.^{13–15} One of these studies is a biomechanical study comparing elastoplasty with PMMA,¹³ one is a retrospective clinical study with a relatively small patients group¹⁵ and the other is a study comparing two small patients groups regarding elastoplasty

* Corresponding author. Metin Sabanci Baltalimani Bone Diseases Training and Research Hospital, Rumelihisari Cd. No:62 34470 Sariyer, Istanbul, Turkey. Fax: +90 212 323 70 82.

E-mail address: yemreakman@gmail.com (Y.E. Akman).

Peer review under responsibility of Turkish Association of Orthopaedics and Traumatology.

and PMMA for kyphoplasty.¹⁴ With a larger group of patients and more spinal levels treated, the aim of our study is to evaluate the clinical outcomes of the patients in terms of pain relief in the short term after the augmentation of VCFs with elastoplasty using VK100 and to assess especially the complications and the presence of subsequent fractures which VK100 is suggested for as a better alternative to PMMA, thus to contribute to the literature regarding clinical data for the application of this novel promising technique in the treatment of VCFs.

Materials and methods

This study was approved by the Institutional Reviewal Board with reference number 00218263. All participants provided written informed consent.

Thirty nine patients (9 men, 30 women; mean age, 67 years; age range, 38–84 years) with VCFs who had undergone percutaneous elastoplasty using VK100 as the augmentation material, in a single institution were retrospectively reviewed. The mean follow up period was 12,5 (range 8–22) months. In 32 of the patients the VCFs were osteoporotic whereas in 7 of the patients the VCFs were due to multiple myeloma. The total number of the treated vertebral bodies was 87 (min 1–max 5). The mean number of the treated vertebral bodies was 2,2 per patient. The numbers of the distribution of the spinal levels treated are demonstrated in Fig. 1.

The procedure was performed under local anesthesia in 37 (95%) cases and the remaining 2 (5%) were operated under general anesthesia due to multiple level fractures. The mean duration of the surgeries was 45 (min 35–max 75) minutes. The procedure was

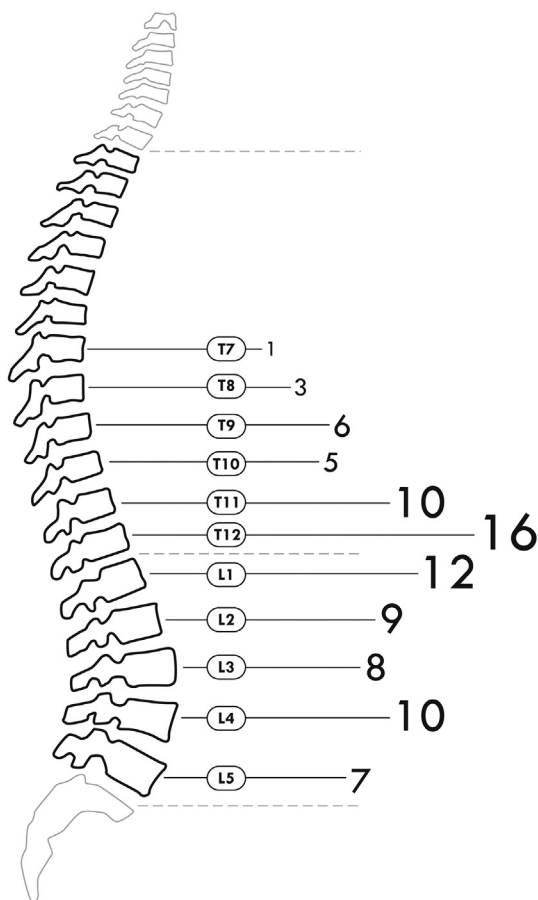


Fig. 1. The numbers of the distribution of the spinal levels treated.

performed through a unilateral transpedicular approach in 62 (71%) spinal bodies and through a bilateral transpedicular approach in 25 (19%) bodies.

The surgical indication for elastoplasty procedure was VCFs from T4 to L5, with ongoing pain after a 6 weeks of conservative treatment and clinical onset less than 12 months, confirmed by direct radiographies of the spinal column and if not evident on direct radiographies by the presence of edema on magnetic resonance imaging (MRI). All of the cases fulfilled the following conditions: (1) the patients did not have severe heart, lung or brain diseases and can lie prone for a duration of 1–2 h; (2) there were no symptoms associated with spinal cord or nerve root damages; (3) pain was continuous and could not be relieved by drug or physical therapy. Exclusion criteria were identified posterior wall defects, active local or systemic infection, vertebral canal occupation by a fragment of the vertebral body, active associated disorders or other that may interfere with correct assessment of quality of life and pain.

Surgical technique

Elastoplasty was carried out under fluoroscopy (Ziehm Imaging, Nurnberg, Germany) by experienced spine surgeons. Ten mL of lidocaine 1% (B. Braun, Melsungen, Germany) was infiltrated from the skin to the periosteum of the targeted vertebral pedicles. In our institution, routine core biopsies are routinely performed prior to VP/KP and elastoplasty procedures to identify the fracture as if it is a pathological fracture which may not be revealed by imaging modalities. Therefore, pathological samples were obtained with a 15G biopsy needle in all patients, before the injection procedure. Then, the procedures were performed using 10-gauge or 13-gauge needles of a vertebroplasty kit (Tsunami Medical, San Possidonio, Italy) through either a unilateral or a bilateral transpedicular approach. There was not a certain amount of VK100 to be planned to be injected and VK100 was injected inside the vertebral body until satisfactory filling was achieved or leakage outside the vertebral body was observed on fluoroscopy. Posterior 1/3 of the vertebral body was tried to be avoided to be filled. After the injection procedure, the patient was kept in prone position and the needles were kept inside the pedicle to avoid leakage for about 10 min until the hardening process of VK100 finished. The working time for VK100 is dependent on room or body temperature and is approximately 15 min from the beginning of the procedure to the end of the injection process in normal operating room and body temperature.

Postoperative care and follow up

The patients were autonomously ambulated on the day after surgery. Standard direct radiography and computerized tomography (CT) evaluation was performed 24 h after the procedure to check distribution and leakage. The patients were followed-up in 3 months intervals. During the follow-up, routine non-weight-bearing anteroposterior and lateral radiographies of the spinal column were performed. Lateral radiographies of a patient obtained in the preoperative, early postoperative periods and during the last follow-up are demonstrated in Fig. 2.

Peroperative and postoperative complications were noted.

Clinical results were evaluated with Visual Analogue Scale (VAS)¹⁶ preoperatively and during the last follow up.

Statistical analysis

Statistical evaluation was performed using SPSS for windows 21.0 software (SPSS Inc, Chicago, IL). The values of pre and

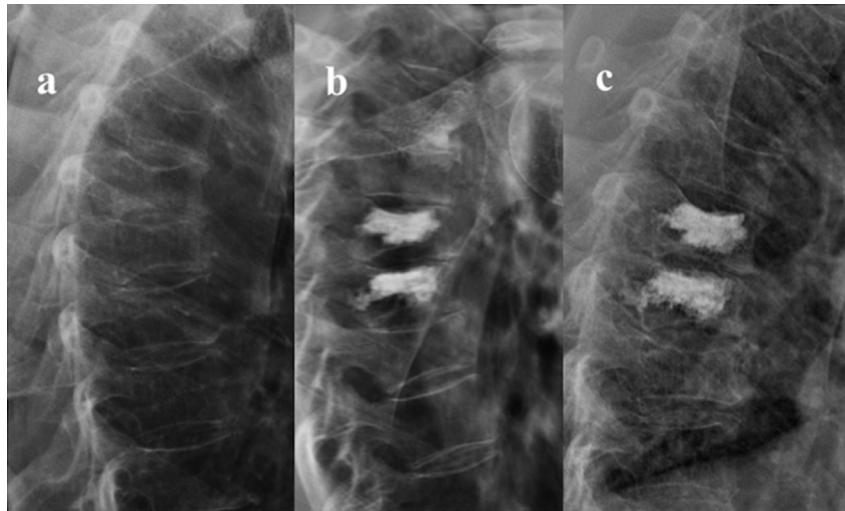


Fig. 2. Lateral radiographies of a 72 years old female patient in whom augmentation of T6 and T7 vertebrae was performed with elastoplasty due to osteoporotic VCFs. a) preoperative, b) early postoperative and c) during the last follow-up.

postoperative VAS were compared with Paired Samples t test. Significance level was set at 0,05.

Results

Cement leakage was noted in 5 (13%) patients. All leakages were inside the paravertebral soft tissues or veins. There were no intra or postoperative neurological or pulmonary complications. In no case the leakage was symptomatic and an additional intervention was required. We have not seen any embolisms with clinical relevance. In one case (a patient with trombocytopenia, <70,000), hematoma occurred under the needle entry site as a complication. The hematoma was resorbed without any intervention during the follow up. At 24 h after vertebroplasty, 26 (66%) patients reported a decrease in their pain scores by 50% or more. Within 24 h of the procedure, 12 (31%) patients quitted taking analgesics and the remaining 27 (69%) reduced the amount of analgesics they took by more than half. The mean VAS score decreased from $7,5 \pm 0,96$ (range 6–9) to $3,5 \pm 0,88$ (range 2–6) during the last follow-up. VAS score decreased in all patients postoperatively. There was statistically significant difference between pre and postoperative VAS scores ($p = 0,000$).

In one (2,5%) patient, subsequent level fracture and in another one (2,5%), fracture at a non-adjacent distant level were observed during the last follow up.

The patients' demographics and the results are summarized in Table 1.

Discussion

In the treatment of VCFs, VP and KP are considered the gold standard. However, both techniques have some serious drawbacks such as subsequent adjacent level fractures and neurological deficits due to the exothermic effect of PMMA polymerization. Thus, search for new augmentation materials to overcome this disadvantages go on. Elastoplasty is a technique performed with VK100 which is introduced for this purpose.

New osteoporotic vertebral compression fractures, in the months after VP, are reported in 7–63% of VP patients, up to 82% of these occur at the adjacent levels, with adjacent fractures occurring sooner than nonadjacent fractures; rates of recurrent fracture of the augmented vertebra itself range up to 63% in the literature.^{17–22} The

mechanism of adjacent level fractures was searched by several biomechanical studies.^{8,9,11,23,24} In their biomechanical study Fahim et al claimed that the endplate deflection fracture mechanism was the main factor for adjacent fractures after vertebroplasty and concluded that vertebroplasty altered the load transfer along the anterior spinal column.⁸ Similarly, Baroud et al hypothesized that excess deformation in the adjacent endplate essentially contributed to subsequent adjacent fractures.⁹ In addition, they hypothesized that the use of polymers combining high strength and low stiffness could minimize the stiffness and load shift, and therefore decrease the risk of subsequent fractures following VP. Thus, to avoid subsequent fractures, some solutions such as the application of low-modulus PMMA,^{25,26} prophylactic vertebroplasty of the adjacent vertebrae,^{7,27–30} and recently an elastic polysiloxane polymer (silicone) have been proposed. In their biomechanical study Schulte et al concluded that VK100 may be a viable option in the treatment of osteoporotic fractures and with its stiffness close to intact bone, it has the biomechanical potential to reduce the risk of subsequent adjacent fractures.¹³ In their retrospective study, which they compared VK100 with PMMA, Bornemann et al reported results supporting this data as they have found less additional fractures in the VK100 group. In accordance with the hypothesis suggested by Fahim et al and the results reported by Schulte et al and Bornemann et al, our study shows that elastoplasty performed with VK100 with its elastic modulus close to intact vertebrae¹³ helps to decrease the risk of subsequent adjacent fractures with only 1 (2,5%) fracture in an adjacent level and another one (2,5%) in a non-adjacent distant level, but no recurrent fracture of the augmented vertebra itself.

As well as a subsequent fracture, also the augmented vertebral body itself is more likely to be re-fractured than a vertebral body with regular PMMA with a material due to lower stiffness. Boger et al reported that lower vertebral body stiffness of low-modulus cement was related with higher failure strength.²⁵ In their biomechanical study, Nouda et al compared calcium phosphate cement (CPC), which provided less stiffness in the treated vertebral body, with PMMA and found a higher rate of fracture with CPC augmentation in the treated vertebrae.³¹ Similarly, the vertebral body augmented with VK100 has the potential risk that overall stiffness may not be restored due to its lower stiffness and as a result collapse and failure in the augmented vertebra may occur due to micro-motion within the vertebral body and changes in load distribution. Schulte et al also reported that the vertebral bodies

Table 1
Patients' demographics and the summary of the results.

n	39 (9 men, 30 women) patients
Mean age	67 (range, 38–84) years
Type of VCFs	Osteoporotic VCFs in 32 patients VCFs due to multiple myeloma in 7 patients
Mean follow-up period	12,5 (range 8–22) months
Total number of the treated vertebral bodies	87 (range 1–5)
Type of anesthesia	Local anesthesia in 37 (95%) patients General anesthesia in 2 (5%) patients
Type of transpedicular approach	Unilateral in 62 (71%) spinal bodies Bilateral in 25 (19%) spinal bodies
Cement leakage	Paravertebral in 5 (13%) patients
The mean VAS	Preoperative $7,5 \pm 0,96$ (range 6–9) Last follow up $3,5 \pm 0,88$ (range 2–6)
Fractures during the follow-up	Subsequent level fracture in one (2,5%) and non-adjacent distant level fracture in another one.

subsided significantly during repetitive loading. While this increased the overall stiffness at 5000 cycles, the vertebral bodies collapsed around 4 mm, about 10% of their initial height.¹³ Bornemann et al did not encounter any collapse in the VK100 augmented vertebrae after a mean follow up period of 12 months.¹⁴ Similarly, we did not found out any collapse of the vertebral bodies augmented with VK100 in our study.

In their systematic review of 69 clinical studies, Hulme et al have found the mean VAS score to decrease from 8,2 to 3,0 and found out that 87% of the patients have had pain relief after vertebroplasty or kyphoplasty.³² In their study with their first experience with elastoplasty in 12 patients, Urlings and van der Linden reported that the mean preoperative VAS score to decrease from 7,9 to 3 postoperatively.¹⁵ In only one patient, VAS did not decrease and remained constant as 8. Postoperative VAS results of 2 patients were not present, as these patients were deceased. In this report, elastoplasty seemed to be useful in decreasing VAS, however the authors did not interpret their pain outcomes. Bornemann et al reported that the use of VK100 was with reduction in VAS and ODI comparable to or slightly better to than PMMA usage, probably with minor additional fracture occurrence.¹⁴ In our series, the mean VAS score decreased from 7,5 to 3,5 VAS score decreased in all patients postoperatively. There was statistically significant difference between pre and postoperative VAS scores ($p = 0,000$). With these results, elastoplasty seems to be comparable with VP and KP regarding pain relief.

The risk of cement leakage in various series of VP and KP ranges between 3% and 80%^{33–37} with resultant neurological deficits such as radiculopathy and cord compression occurring in 0%–3,7% and 0% to 0,5%, respectively.^{32–35} In their systematic review, Hulme et al have evaluated 69 clinical studies and the mean leakage rate was 41%.³² All leakages were inside the paravertebral soft tissues or veins. In their study with VK100, Urlings and van der Linden reported a high leakage rate of 90% in 19 vertebral segments out of 21.¹⁵ In 67% of treated vertebrae, leakage occurred to the perivertebral venous plexus, whereas the leakage was into the paravertebral soft tissue. There was also leakage to the long back muscles through the puncture canal after removal of the needle (14%) and to the adjacent intervertebral disc (14%). In this study, only 17% of treated vertebrae showed no leakage. In their comparative study, Bornemann et al reported a leakage rate of 6,7 (1 patient out of 15) in the PMMA group and 13,3% (2 patients out of 15) in the VK100 group of their study. They claimed that there was no statistically significant difference between the groups. They did not specify the location of the leakages in both groups. In our study, there was a leakage rate of 13%. All leakages were inside the paravertebral soft tissues or veins in our study. Our results regarding

leakage is consistent with the literature data on cement leakage and the outcomes of the study performed by Bornemann et al.

Silicone pulmonary embolism is a serious complication of elastoplasty.¹⁵ Urlings and van der Linden has performed chest computerized tomography (CT) in the early postoperative period in ten of the 12 patients in whom they performed elastoplasty.¹⁵ They have detected silicone pulmonary embolism (SPE) in 60% (6/10) of these patients. However, only 1 of the 10 patients with detected SPE was symptomatic, as the others remained asymptomatic. On the contrary, Bournemann et al did not encounter any symptomatic SPE in the VK100 group in their study. In our study we also did not encounter clinically symptomatic SPE related with VK100 augmentation. Because there was no pulmonary symptom, we did not perform postoperative chest CT in our cases. Due to the low viscosity, we also suppose that SPE may occur during elastoplasty via perivertebral venous plexus. However, with the presence of no symptomatic cases, our study shows that SPE is not a clinical event similar with cement pulmonary embolism (CPE). In Vertos II study, all patients were asymptomatic at the time of CPE diagnosis verified by imaging studies.³⁷ This is because the cement fragments are distributed peripherally without a specific lobar localization. Studies conducted in patients with CPE show that cement deposits does not cause structural changes in the lung parenchyma and patients usually do not develop sequelae.³⁷ This is due to biologically inert behavior of cement, which is not causing inflammation in the lung parenchyma.³⁷ As it is a silicon based polymer, VK100 is also biologically inert and it is probable that SPE does not cause inflammation in the lung parenchyma through this mechanism. Thus, we believe that a close clinical follow-up is sufficient in most of the elastoplasty cases. Early postoperative chest radiographs and chest CT should be performed only if necessary in symptomatic cases.

Height restoration after vertebral augmentation is another important concern regarding both clinical and radiological outcomes. In their comparative study, Bornemann et al reported that augmentation with both PMMA and VK100 lead to significantly improved vertebral heights.¹⁴ However, they reported that height restoration of VK100 was not satisfactory when compared to PMMA augmentation after 12 months. Their study demonstrated a worse height restoration, but a more stable height over the follow-up period, in the VK100 group. Unfortunately, we did not evaluate height restoration after VK100 augmentation. The lack of the data regarding vertebral height restoration is a weak point of our study.

When compared with PMMA, VK100 has some certain advantages. Although VK100 hardens slower than PMMA, the hardening period of the material and the injection time can be adjusted by changing the temperature. The technique is more economical as the wider time window of processing the mixed substance and the possibility to adapt the amount of augmentation material make the multi level vertebral augmentation feasible using only a single kit for all levels. A further advantage of VK100, with its elasticity and reduced stiffness, is the possibility of introducing metallic materials such as pedicle screws or biopsy trocars inside it. Latter instrumentation of the augmented vertebra and biopsy for recurrences occurred anterior to the augmentation, in tumor cases, are viable with this feature. Also as the material is elastic, its space occupying effect is limited. With these features, even in case of leakage inside the spinal canal, the potential of neurological damage is low. With its lower viscosity, contrary to PMMA, it does not break the trabecule of the spongy bone but diffuse between them and interdigitate when it is hardened (Fig. 3). This effect provides enhanced bone adherence.¹⁴

The retrospective design of the study, the limited number of the patients, short follow up periods, the insufficiency of the radiological evaluation, the lack of data on VAS score changes over time,

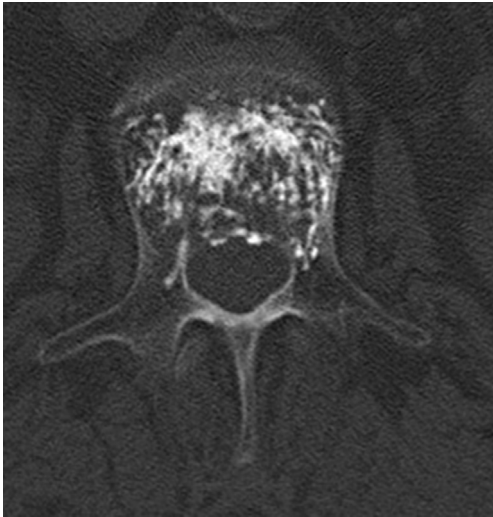

Fig. 3. Postoperative axial CT scan revealing the interdigitation of VK100 without destroying the trabecular structure.

functional scoring of the patients and the control groups are the main draw-backs of our study and preclude reaching a more definite judgment. Short follow up periods of the patients may be the reason for the low number of subsequent fractures as some impending fractures that may occur in the long term could be present. The heterogeneity of the patient group regarding the etiology and the number of the spinal levels treated may have led to misinterpretation of VAS scores. The demonstration of VAS changes over time would interpret the clinical outcome in a better view. The lack of the control groups and the retrospective design of the study are certain objections as some key statistics cannot be measured. As a result of the retrospective aspect, an accurate record-keeping of the clinical and the radiological outcomes was not present. Thus, randomized controlled trials with long-term follow-up periods are required for further evaluation of the elastoplasty technique. However, we believe that this is an important study as there are very few studies in the literature reporting on the results of elastoplasty technique using VK100 in the treatment of VCFs.

In conclusion, the results obtained in our study show that elastoplasty is a safe and promising technique to overcome some certain drawbacks of PMMA, in the augmentation of VCFs. Our study demonstrates that elastoplasty performed with VK100 is comparable to VP and KP in terms of pain relief. The rate of leakage appears to be comparable with that of VP and KP. Even if SPE occurs, it is asymptomatic. In the short term, it has been found promising regarding the avoidance of subsequent level fractures.

References

1. Galibert P, Deramond H, Rosat P, Le Gars D. Preliminary note on the treatment of vertebral angioma by percutaneous acrylic vertebroplasty. *Neurochirurgie*. 1987;33(2):166–168.
2. Heo DH, Chin DK, Yoon YS, Kuh SU. Recollapse of previous vertebral compression fracture after percutaneous vertebroplasty. *Osteoporos Int*. 2009;20(3):473–480.
3. Yoshii T, Ueki H, Kato T, Tomizawa S, Okawa A. Severe kyphotic deformity resulting from collapses of cemented and adjacent vertebrae following percutaneous vertebroplasty using calcium phosphate cement. A case report. *Skelet Radiol*. 2014;43(10):1477–1480.
4. Lin WC, Lee YC, Lee CH, et al. Refractures in cemented vertebrae after percutaneous vertebroplasty: a retrospective analysis. *Eur Spine J*. 2008;17(4):592–599.
5. Harrop JS, Prpa B, Reinhardt MK, Lieberman I. Primary and secondary osteoporosis' incidence of subsequent vertebral compression fractures after kyphoplasty. *Spine (Phila Pa 1976)*. 2004;29(19):2120–2125.

6. Han SL, Wan SL, Li QT, et al. Is vertebroplasty a risk factor for subsequent vertebral fracture, meta-analysis of published evidence? *Osteoporos Int*. 2015;26(1):113–122.
7. Trout AT, Kallmes DF. Does vertebroplasty cause incident vertebral fractures? A review of available data. *AJNR Am J Neuroradiol*. 2006;27(7):1397–1403.
8. Fahim DK, Sun K, Tawackoli W, et al. Premature adjacent vertebral fracture after vertebroplasty: a biomechanical study. *Neurosurgery*. 2011;69(3):733–744.
9. Baroud G, Nemes J, Heini P, Steffen T. Load shift of the intervertebral disc after a vertebroplasty: a finite-element study. *Eur Spine J*. 2003;12(4):421–426.
10. Nagaraja S, Awada HK, Dreher ML. Vertebroplasty increases trabecular microfractures in elderly female cadaver spines. *Osteoporos Int*. 2015;26(7):2029–2034.
11. Polikeit A, Nolte LP, Ferguson SJ. The effect of cement augmentation on the load transfer in an osteoporotic functional spinal unit: finite-element analysis. *Spine (Phila Pa 1976)*. 2003;28(10):991–996.
12. Kim JM, Shin DA, Byun DH, Kim HS, Kim S, Kim HI. Effect of bone cement volume and stiffness on occurrences of adjacent vertebral fractures after vertebroplasty. *J Korean Neurosurg Soc*. 2012;52(5):435–440.
13. Schulte TL, Keiler A, Riechelmann F, Lange T, Schmoelz W. Biomechanical comparison of vertebral augmentation with silicone and PMMA cement and two filling grades. *Eur Spine J*. 2013;22(12):2695–2701.
14. Bornemann R, Rommelspacher Y, Jansen TR, Sander K, Wirtz DC, Pflugmacher R. Elastoplasty: a silicon polymer as a new filling material for kyphoplasty in comparison to PMMA. *Pain Physician*. 2016;19(6):E885–E892.
15. Urlings TA, van der Linden E. Elastoplasty: first experience in 12 patients. *Cardiovasc Interv Radiol*. 2013;36(2):479–483.
16. Price DD, McGrath PA, Rafii A, Buckingham B. The validation of visual analogue scales as ratio scale measures for chronic and experimental pain. *Pain*. 1983;17(1):45–56.
17. Blasco J, Martinez-Ferrer A, Macho J, et al. Effect of vertebroplasty on pain relief, quality of life, and the incidence of new vertebral fractures: a 12-month randomized follow-up, controlled trial. *J Bone Min Res*. 2012;27(5):1159–1166.
18. Hierholzer J, Fuchs H, Westphalen K, Baumann C, Sotosch C, Schulz R. Incidence of symptomatic vertebral fractures in patients after percutaneous vertebroplasty. *Cardiovasc Interv Radiol*. 2008;31(6):1178–1183.
19. Li YA, Lin CL, Chang MC, Liu CL, Chen TH, Lai SC. Subsequent vertebral fracture after vertebroplasty: incidence and analysis of risk factors. *Spine (Phila Pa 1976)*. 2012;37(3):179–183.
20. Trout AT, Kallmes DF, Kaufmann TJ. New fractures after vertebroplasty: adjacent fractures occur significantly sooner. *AJNR Am J Neuroradiol*. 2006;27(1):217–223.
21. Tseng YY, Yang TC, Tu PH, Lo YL, Yang ST. Repeated and multiple new vertebral compression fractures after percutaneous transpedicular vertebroplasty. *Spine (Phila Pa 1976)*. 2009;34(18):1917–1922.
22. Fribourg D, Tang C, Sra P, Delamarter R, Bae H. Incidence of subsequent vertebral fracture after kyphoplasty. *Spine (Phila Pa 1976)*. 2004;29(20):2270–2276. discussion 2277.
23. Liebschner MA, Rosenberg WS, Keaveny TM. Effects of bone cement volume and distribution on vertebral stiffness after vertebroplasty. *Spine (Phila Pa 1976)*. 2001;26(14):1547–1554.
24. Belkoff SM, Mathis JM, Jasper LE, Deramond H. The biomechanics of vertebroplasty. The effect of cement volume on mechanical behavior. *Spine (Phila Pa 1976)*. 2001;26(14):1537–1541.
25. Boger A, Heini P, Windolf M, Schneider E. Adjacent vertebral failure after vertebroplasty: a biomechanical study of low-modulus PMMA cement. *Eur Spine J*. 2007;16(12):2118–2125.
26. Kinzl M, Benneker LM, Boger A, Zyssset PK, Pahr DH. The effect of standard and low-modulus cement augmentation on the stiffness, strength, and endplate pressure distribution in vertebroplasty. *Eur Spine J*. 2012;21(5):920–929.
27. Kobayashi N, Numaguchi Y, Fuwa S, et al. Prophylactic vertebroplasty: cement injection into non-fractured vertebral bodies during percutaneous vertebroplasty. *Acad Radiol*. 2009;16(2):136–143.
28. Chiang CK, Wang YH, Yang CY, Yang BD, Wang JL. Prophylactic vertebroplasty may reduce the risk of adjacent intact vertebra from fatigue injury: an ex vivo biomechanical study. *Spine (Phila Pa 1976)*. 2009;34(4):356–364.
29. Yen CH, Teng MM, Yuan WH, Sun YC, Chang CY. Preventive vertebroplasty for adjacent vertebral bodies: a good solution to reduce adjacent vertebral fracture after percutaneous vertebroplasty. *AJNR Am J Neuroradiol*. 2012;33(5):826–832.
30. Aquarius R, Homminga J, Hosman AJ, Verdonshot N, Tanck E. Prophylactic vertebroplasty can decrease the fracture risk of adjacent vertebrae: an in vitro cadaveric study. *Med Eng Phys*. 2014;36(7):944–948.
31. Nouda S, Tomita S, Kin A, Kawahara K, Kinoshita M. Adjacent vertebral body fracture following vertebroplasty with polymethylmethacrylate or calcium phosphate cement: biomechanical evaluation of the cadaveric spine. *Spine (Phila Pa 1976)*. 2009;34(24):2613–2618.
32. Hulme PA, Krebs J, Ferguson SJ, Berlemann U. Vertebroplasty and kyphoplasty: a systematic review of 69 clinical studies. *Spine (Phila Pa 1976)*. 2006;31(17):1983–2001.
33. Jensen ME, Evans AJ, Mathis JM, Kallmes DF, Cloft HJ, Dion JE. Percutaneous polymethylmethacrylate vertebroplasty in the treatment of osteoporotic vertebral body compression fractures: technical aspects. *AJNR Am J Neuroradiol*. 1997;18(10):1897–1904.

34. Cortet B, Cotten A, Boutry N, et al. Percutaneous vertebroplasty in the treatment of osteoporotic vertebral compression fractures: an open prospective study. *J Rheumatol*. 1999;26(10):2222–2228.
35. Ploeg WT, Veldhuizen AG, The B, Sietsma MS. Percutaneous vertebroplasty as a treatment for osteoporotic vertebral compression fractures: a systematic review. *Eur Spine J*. 2006;15(12):1749–1758.
36. Ryu KS, Park CK, Kim MC, Kang JK. Dose-dependent epidural leakage of polymethylmethacrylate after percutaneous vertebroplasty in patients with osteoporotic vertebral compression fractures. *J Neurosurg*. 2002;96(1 Suppl):56–61.
37. Venmans A, Lohle PN, van Rooij WJ, Verhaar HJ, Mali WP. Frequency and outcome of pulmonary polymethylmethacrylate embolism during percutaneous vertebroplasty. *AJNR Am J Neuroradiol*. 2008;29(10):1983–1985.