

OPEN

## Rapid Spontaneously Resolving Acute Subdural Hematoma

Qi Gan, MD,\* Hexiang Zhao, MD,† Hanmei Zhang, MD,‡  
and Chao You, MD, PhD\*

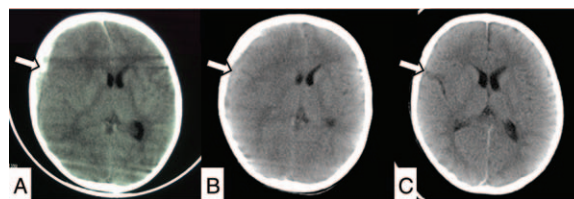
**Introduction:** This study reports a rare patient of a rapid spontaneously resolving acute subdural hematoma. In addition, an analysis of potential clues for the phenomenon is presented with a review of the literature.

**Patient Presentation:** A 1-year-and-2-month-old boy fell from a height of approximately 2 m. The patient was in a superficial coma with a Glasgow Coma Scale of 8 when he was transferred to the authors' hospital. Computed tomography revealed the presence of an acute subdural hematoma with a midline shift beyond 1 cm. His guardians refused invasive interventions and chose conservative treatment. Repeat imaging after 15 hours showed the evident resolution of the hematoma and midline reversion. Progressive magnetic resonance imaging demonstrated the complete resolution of the hematoma, without redistribution to a remote site.

**Conclusions:** Even though this phenomenon has a low incidence, the probability of a rapid spontaneously resolving acute subdural hematoma should be considered when patients present with the following characteristics: children or elderly individuals suffering from mild to moderate head trauma; stable or rapidly recovered consciousness; and simple acute subdural hematoma with a moderate thickness and a particularly low-density band in computed tomography scans.

**Key Words:** Acute subdural hematoma, rapid spontaneous resolution, traumatic brain injury

Acute subdural hematoma (ASDH) is associated with an overall mortality rate of 50% to 90%, the highest of all traumatic intracranial injuries.<sup>1</sup> To avoid further deterioration associated with a secondary injury, current guidelines recommend a craniotomy in patients in whom the ASDH thickness is larger than 10 mm or the midline shift is beyond 5 mm.<sup>2</sup> However, rapid spontaneous

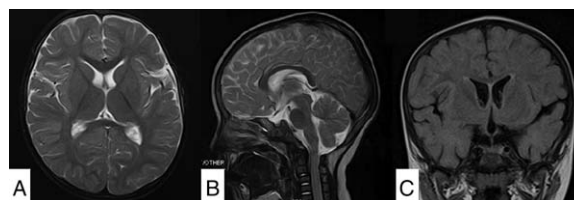

**FIGURE 1.** Acute subdural hematoma evolution in sequential CT scans. (A) Initial CT scan revealed right frontotemporal acute subdural hematoma (arrow to show), with SAH in anterior longitudinal fissure and midline shift exceeding 10 mm. (B) A second CT scan showed the decrease of hematoma (arrow to show) with obvious diffuse cerebral edema. (C) A third CT scan was taken after 24 hours of the injury revealed an evident resolution of hematoma (arrow to show) and midline revert with only SAH left in posterior longitudinal fissure. CT, computed tomography; SAH, subarachnoid hemorrhage.

resolution of ASDH has been observed in a few patients, some of whom even required a craniotomy. An unexpected good recovery was reported for patients who were treated with conservative treatment. Here, the authors present a patient of rapid resolving ASDH with an analysis of the literature.

### CLINICAL REPORT

A 1-year-and-2-month-old boy fell from a height of approximately 2 m and lost consciousness after he experienced head trauma. The patient was sent to a local hospital immediately. During the interval emergent computed tomography (CT), the patient vomited several times. The patient's Glasgow Coma Scale (GCS) score was E2V2M4. The CT scan (Fig. 1A) revealed a right frontotemporal ASDH that was approximately 9 mm in size with a subarachnoid hemorrhage in the longitudinal fissure and midline shift beyond 10 mm. Two hours after the injury the patient was transferred to West China Hospital. He was in a superficial coma with the same GCS score that was documented in previous medical records. Both of the patient's pupils were equal in size 2 mm but exhibited a blunted response to light. The second CT scan (Fig. 1B) showed a decrease in hematoma density and diffuse cerebral edema with obviously squeezed ventricles; the midline was still deviated compared with the first CT scan. Given his consciousness and imaging findings, intracranial pressure monitoring was preferred. Even though the laboratory features were not surgical contraindications, the boy's guardians refused the placement of an intracranial pressure probe or a craniotomy. Conservative treatment was agreed upon in the neurointensive care unit. General monitoring aimed to maintain SaO<sub>2</sub> at >95%, mean systolic blood pressure at >90 mm Hg, temperature at <37°C, and PaCO<sub>2</sub> at 35 to 40 mm Hg. Owing to the lack of an accurate intracranial pressure assessment, mannitol was administered empirically at 0.5 g/kg every 6 hours. The third CT scan (Fig. 1C) revealed evident resolution of the hematoma and midline shift improvement, with only a subarachnoid hemorrhage present in the posterior longitudinal fissure 24 hours after the trauma. After he had received 2 days of conservative management,



**FIGURE 2.** Magnetic resonance imaging on the fourth day of conservative management. Transverse (A), sagittal (B), and coronal (C) planes were performed which revealed acute subdural hematoma complete resolution without redistribution to upper cervical spinal cord.

From the \*Department of Neurosurgery, West China Hospital, Sichuan University, Chengdu; †Department of Neurosurgery, First Affiliated Hospital of Kunming Medical University, Kunming; and ‡Department of Radiology, West China Hospital, Sichuan University, Chengdu, China.

Received November 21, 2016.

Accepted for publication December 5, 2016.

Address correspondence and reprint requests to Dr Chao You, MD, PhD, Department of Neurosurgery, West China Hospital, Sichuan University, No. 37, Guo Xue Xiang, Chengdu, Sichuan 610041, China

QG and HZ contributed equally to this manuscript.

The authors report no conflicts of interest.

This is an open-access article distributed under the terms of the Creative Commons Attribution-Non Commercial-No Derivatives License 4.0 (CCBY-NC-ND), where it is permissible to download and share the work provided it is properly cited. The work cannot be changed in any way or used commercially without permission from the journal.

Copyright © 2017 The Author(s). Published by Wolters Kluwer Health, Inc. on behalf of Mutaz B. Habal, MD

ISSN: 1049-2275

DOI: 10.1097/SCS.0000000000003533

TABLE 1. Summary Literatures of Acute Subdural Hematoma With Rapid Resolution

Author	Age	Initial GCS	Consciousness Change	Resolution Time	ASDH Thickness	ASDH Region	Low-Density Band	Shift of Midline	SAH	Contusion	Edema	Redistribution
Polman et al <sup>13</sup>	26 y	15	Deteriorated	6 h	<15 mm	F+T+P	No	>10 mm	Yes	No	Yes	No
Nagao et al <sup>14</sup>	3 y	9	Improved	16 h	<15 mm	F+T+P	No	>10 mm	No	No	No	No
Matsuyama et al <sup>3</sup>	18 y	9	Improved	3 h	15 mm	F+T	Yes	>10 mm	Yes	No	No	No
Kato et al <sup>10</sup>	79 y	15	Stable	12 h	<15 mm	F+T	Yes	No	Yes	No	No	Yes
Kato et al <sup>10</sup>	41 y	11	Improved	12 h	<15 mm	F+T	Yes	>10 mm	Yes	No	No	Yes
Berker et al <sup>15</sup>	57 y	7	Improved	2 h	<15 mm	F+T	No	>10 mm	Yes	No	No	No
Erol et al <sup>7</sup>	1 y	15	Stable	36 h	<15 mm	F+T	Yes	No	No	Yes	No	No
Huang et al <sup>8</sup>	2 y	14	Stable	65 h	<15 mm	F+T	Yes	>10 mm	No	No	No	No
Kapsalaki et al <sup>9</sup>	29 y	8	Stable	6 h	>15 mm	F+T	Yes	>10 mm	Yes	No	No	No
Coşar et al <sup>6</sup>	8 y	15	Stable	9 h	<15 mm	F+P	Yes	No	No	No	No	No
Wong et al <sup>4</sup>	73 y	8	Improved	45 h	>15 mm	F+T+P	Yes	>10 mm	No	No	No	Yes
Yadav et al <sup>12</sup>	50 y	6	Improved	7 h	<15 mm	F+T	Yes	<10 mm	Yes	No	No	No
Shin et al <sup>11</sup>	40 y	6	Improved	72 h	<15 mm	F+T+P	Yes	>10 mm	No	No	No	No
Liu et al <sup>16</sup>	2 y	6	Stable	0.5 h	>15 mm	F+T	Yes	>10 mm	Yes	No	No	No
Park et al <sup>17</sup>	7 y	5	Stable	6 h	<15 mm	F+T+P	Yes	>10 mm	Yes	No	No	Yes
Liu et al <sup>5</sup>	48 y	7	Improved	24 h	<15 mm	F+T	Yes	<10 mm	Yes	No	No	No
Balik et al <sup>18</sup>	66 y	6	Deteriorated	16 h	<15 mm	F+T	Yes	<10 mm	Yes	No	No	Yes
Present patient	1y	8	Stable	15 h	<15 mm	F+T	Yes	>10 mm	Yes	No	Yes	No

ASDH, acute subdural hematoma; F, frontal; GCS, Glasgow Coma Scale; P, parietal; SAH, subarachnoid hemorrhage; T, temporal.

the boy regained consciousness. The magnetic resonance images (Fig. 2A–C) showed that the ASDH was almost completely resolved on the fourth day after admission, without redistribution to the upper cervical spinal cord. The patient was finally discharged on the seventh day without neurological function impairment.

## DISCUSSION

The following 2 possible explanations were proposed: the ASDH was diluted and washed out by cerebrospinal fluid (CSF) after the tearing of the arachnoid membrane and the hematoma was redistributed to the subdural space.<sup>3</sup> Wong et al<sup>4</sup> measured the Hounsfield units of the subarachnoid space, which was close to normal, and confirmed the redistribution of a hematoma to the subdural space then to the subarachnoid space. The theory was based on the flow of liquefied blood, which was thought to be driven by the change in intraparenchymal pressure.<sup>5</sup> In those patients without available definitive evidence of blood redistribution, CSF flushing seems more likely.

Age is a neglected aspect of the study of ASDH rapid resolution. Based on Table 1,<sup>3–18</sup> rapid resolution occurred more frequently in children, less frequently in elders, and least often in middle-age individuals. In children and elders, ASDH is often caused by mild or moderate injuries, such as falling or slipping. However, middle-aged people usually suffer from severe head trauma. The change in the arachnoid membrane related to age may play an important role. A thin and fragile arachnoid membrane can be torn easily in children. In elderly individuals, brain atrophy and a wide cavum of the subarachnoid space can cause an arachnoid membrane slit under external force. For middle-age individuals, well-developed brain tissue and narrow compensatory space results in an arachnoid membrane that is comparatively difficult to tear with a mild injury.

Wen et al<sup>19</sup> proposed that GCS was higher than 8 in patients who exhibited this phenomenon. However, in Table 1, 7 of 18 patients exhibited a GCS score of less than 8, and the minimum was 5. In the process of the clinical evaluation, the dynamic change in consciousness is a more heavily weighted factor to consider than the initial GCS score. According to a review of all patients (Table 1), most of those patients regained consciousness quickly.

Although some of those patients did not regain consciousness quickly, their conditions were stable. In our case, the patient's consciousness improvement was even slower than the time of resolution according to the CT scan. Thus, by comparing the initial GCS score after head trauma, we inferred that a rapid recovery or relative stabilization of consciousness is more persuasive in these patients.

The evaluation of images from CT scans that were performed during different phases of our patient clearly demonstrated the rapid transition of hematoma density from a high density to a mixed density. This finding indicated that CSF dilution probably occurred during this phenomenon. Some authors agreed that the potential sign in early CT of a rapid resolution was the presence of a low-density band.<sup>3,5–12</sup> In our patient's second CT scan (Fig. 1B), it was observed that remarkable cerebral edema could squeeze, in some way, the diluted hematoma. Kuroiwa et al<sup>20</sup> suggested that diffuse cerebral edema was necessary for the spontaneous resolution of a hematoma. We speculate that cerebral edema leads to resolution via both mechanisms, but it may not be the prerequisite for hematoma rapid resolution. Indeed, in most patients, the diffuse edema was not even observed (Table 1). We propose that the slice or middle thickness hematoma (<1.5 cm) would be suitable in the consideration of rapid resolution. Lee et al<sup>21</sup> reported a patient with a hematoma thickness that was larger than 2.5 cm, yet it finally converted to a chronic subdural hematoma. The presence of simple ASDH without contusion appears to be associated with rapid resolution. We suspect that this effect is due to the mass effect of the contusion, which impeded the flow of CSF in the limited space.

## CONCLUSION

This patient has been reported because of clear evidence of CSF dilution and a flush effect that led to resolution of the hematoma, and the finding that a distinctly swollen brain probably accelerated the process. There is no need for the deliberate evaluation of the phenomenon as a coincidence during treatment. We suggest that ASDH rapid resolution should be considered when patients present

with the following characteristics: children or elders suffering from mild to moderate head trauma; stable or rapidly recovered consciousness; and simple ASDH with moderate thickness and a particularly low-density band in CT scan images.

## REFERENCES

- Koç RK, Akdemir H, Oktem IS, et al. Acute subdural hematoma: outcome and outcome prediction. *Neurosurg Rev* 1997;20:239–244
- Bullock MR, Chesnut R, Ghajar J, et al. Surgical management of traumatic brain injury author group: surgical management of acute subdural hematomas. *Neurosurgery* 2006;58:S16–S24
- Matsuyama T, Shimomura T, Okumura Y, et al. Rapid resolution of symptomatic acute subdural hematoma: case report. *Surg Neurol* 1997;48:193–196
- Wong ST, Yuen MK, Fok KF, et al. Redistribution of hematoma to spinal subdural space as a mechanism for the rapid spontaneous resolution of posttraumatic intracranial acute subdural hematoma: case report. *Surg Neurol* 2009;71:99–102
- Liu B, Zhuang Z, Luo J. Fluctuation of intra-parenchymal cerebral pressure may drive the rapid spontaneous resolution of acute subdural hematoma. *Med Hypotheses* 2013;81:159–162
- Coşar M, Eser O, Aslan A, et al. Rapid resolution of acute subdural hematoma and effects on the size of existent subdural hygroma: a case report. *Turk Neurosurg* 2007;17:224–227
- Erol FS, Kaplan M, Topsakal C, et al. Coexistence of rapidly resolving acute subdural hematoma and delayed traumatic intracerebral hemorrhage. *Pediatr Neurosurg* 2004;40:238–240
- Huang SH, Lee HM, Lin CK, et al. Rapid resolution of infantile acute subdural hematoma: a case report. *Kaohsiung J Med Sci* 2005;21:291–294
- Kapsalaki EZ, Machinis TG, Robinson JS 3rd et al. Spontaneous resolution of acute cranial subdural hematomas. *Clin Neurol Neurosurg* 2007;109:287–291
- Kato N, Tsunoda T, Matsumura A, et al. Rapid spontaneous resolution of acute subdural hematoma occurs by redistribution—two case reports. *Neurol Med Chir (Tokyo)* 2001;41:140–143
- Shin DW, Choi CY, Lee CH. Spontaneously rapid resolution of acute subdural hemorrhage with severe midline shift. *J Korean Neurosurg Soc* 2013;54:431–433
- Yadav YR, Agarwal M, Namdev H, et al. Rapid resolution of acute subdural hematoma: a case report and review of literature. *Indian J Neurotrauma* 2011;8:45–48
- Polman CH, Gijsbers CJ, Heimans JJ, et al. Rapid spontaneous resolution of an acute subdural hematoma. *Neurosurgery* 1986;19:446–448
- Nagao T, Aoki N, Mizutani H, et al. Acute subdural hematoma with rapid resolution in infancy: case report. *Neurosurgery* 1986;19:465–467
- Berker M, Gulsen S, Ozcan OE. Ultra rapid spontaneous resolution of acute posttraumatic subdural hematomas in patient with temporal linear fracture. *Acta Neurochir* 2013;145:715–717
- Liu B, Zhuang Z. The cause and consequence of rapid spontaneous redistribution of acute subdural hematoma. *Clin Neurol Neurosurg* 2013;115:2310–2311
- Park JY, Moon KS, Lee JK, et al. Rapid resolution of acute subdural hematoma in child with severe head injury: a case report. *J Med Case Rep* 2013;7:67
- Balik V, Kolembus P, Svajdler M, et al. A case report of rapid spontaneous redistribution of acute supratentorial subdural hematoma to the entire spinal subdural space presenting as a Pourfour du Petit syndrome and review of the literature. *Clin Neurol Neurosurg* 2013;115:849–852
- Wen L, Liu WG, Ma L, et al. Spontaneous rapid resolution of acute subdural hematoma after head trauma: is it truly rare? Case report and relevant review of the literature. *Ir J Med Sci* 2009;178:367–371
- Kuroiwa T, Tanabe H, Takatsuka H, et al. Rapid spontaneous resolution of acute extradural and subdural hematomas. *Case report J Neurosurg* 1993;78:126–128
- Lee CH, Kang DH, Hwang SH, et al. Spontaneous rapid reduction of a large acute subdural hematoma. *J Korean Med Sci* 2009;24:1224–1226

## Open Reduction in Pediatric Condylar Fracture

Alexandre Agostini Barbosa, MS\*  
and Ronaldo Célio Mariano, PhD†

**Abstract:** Facial fractures in children are rare. Lack of pneumatization, fat pockets, mixed dentition, contribute to the elasticity and bone stability. When mandibular fractures occur in children, most often involve the condyle by indirect trauma. Such fractures are the center of discussion on the form of treatment if this should be performed conservatively, or held the reduction and fixation of the fracture with surgical exposure of the fragments. In condylar fractures in children, in most patients, the proposed treatment is closed reduction. Treatment with open reduction and fixation has its specific indications. In this case, the authors report a patient cycling accident victim, with cut-contusion injury in ment with limited mouth opening and left condylar fracture with medial rotation. The treatment was the reduction and fixation of fragments by open process.

**Key Words:** Condylar fracture, pediatric fracture, facial trauma

Facial trauma affecting children displays important features regarding the incidence, diagnosis, and treatment, which leads the child facial trauma to be object of special attention to the psychological and physiological conditions, own age. Pediatric fractures are unusual compared with fractures in adults. Most of the time children are in protected environments under the supervision of parents and therefore less exposed to major trauma.<sup>1</sup> Lack of jaw pneumatization, the considerable number of pockets of fat, bone developing, and mixed dentition contribute to the elasticity and bone stability, requiring more force to produce a facial fracture and reflecting its low incidence of facial skeleton.<sup>2</sup> The index of facial fractures in pediatric patients according to studies is around 15%, occurring mostly in the age group over 5 years. Mandibular fractures in children represent 32.7% of all facial fractures, followed by nasal fractures (30.2%) and midface and zygomatic bone (28.6%). Mandible fractures are rare in children under 5 years.<sup>1–3</sup> The condyle fracture, in most patients, incomplete type “green stick,” generally aged less than 6 years of age, where the bone is more flexible.<sup>4</sup>

The fractures of the mandibular condyle are in about 11% to 16% of facial fractures and 30% to 40% of all mandibular fractures. Most are not caused by direct trauma, but following indirect forces transmitted to the condyle by a blow elsewhere.<sup>3</sup> Boys are more commonly affected than girls in all age groups; this has been attributed to the most dangerous physical activity experienced by boys.<sup>1,5</sup> The fractures of the mandibular condyle in children can lead to serious problems such as malocclusion, temporomandibular dysfunction, TMJ ankylosis, interference in mandibular growth.<sup>3,6</sup>

From the \*Postgraduate Program in Dental Sciences; and †School of Dentistry, Federal University of Alfenas, Minas Gerais, Brazil.

Received September 30, 2016.

Accepted for publication December 8, 2016.

Address correspondence and reprint requests to Ronaldo Célio Mariano, PhD, Rua Gabriel Monteiro da Silva, 700 Centro, Alfenas, MG CEP:37.130-000, Brazil; E-mail: ronaldocmariano@gmail.com

The authors report no conflicts of interest.  
Copyright © 2017 by Mutaz B. Habal, MD  
ISSN: 1049-2275

DOI: 10.1097/SCS.0000000000003538