



Case report

Dramatic response to Laetrile and cannabidiol (CBD) oil in a patient with metastatic low grade serous ovarian carcinoma

Allison M. Barrie^a, Ariane C. Gushue^b, Ramez N. Eskander^{a,*}^a Division of Gynecologic Oncology, Department of Obstetrics, Gynecology and Reproductive Medicine, UC San Diego Moores Cancer Center, La Jolla, CA, United States of America^b UC San Diego School of Medicine, La Jolla, CA, United States of America

ARTICLE INFO

Keywords:

Cannabidiol

Laetrile

Low grade ovarian cancer

Complimentary alternative medicine

1. Introduction

Low grade serous ovarian cancer (LGSOC) is a rare subtype of serous epithelial ovarian cancer, comprising approximately 10% of all cases of serous carcinoma. The majority of women are diagnosed with advanced stage disease, despite its slow growth. Treatment options for advanced disease include neoadjuvant chemotherapy followed by interval surgical cytoreduction or primary surgical resection followed by adjuvant therapy as well as maintenance hormonal therapy (National Comprehensive Cancer Network, 2019). Adjuvant therapy traditionally consists of combination platinum and taxane based chemotherapy, although response rates are limited, and may include concurrent/maintenance hormonal therapy. Even with advanced stage at diagnosis, patients with LGSOC have an improved prognosis when compared to their high grade serous counterparts, with median overall survival of approximately 100 months reported, reflective of a protracted clinical course (Gershenson et al., 2015).

In an effort to improve oncologic outcomes, investigators have attempted to capitalize on molecular aberrations identified in LGSOC specimens. Most recently, the utilization of MEK inhibitors have been explored due to noted activation of the mitogen-activate protein kinase (MAPK) pathway in LGSOC. A phase II trial evaluating Selumetinib activity in women with recurrent LGSOC (GOG 0239) demonstrated a 15% overall response rate, catalyzing the development of phase III trials examining alternate agents in this setting (Farley et al., 2013). A phase III study evaluating Trametinib vs. physicians choice chemotherapy in patients with recurrent or progressive LGSOC (GOG-281) has closed to accrual and will help guide further management with these targeted

agents. Furthermore, efforts to identify appropriate patient subsets based on molecular profiling are ongoing. In context of the above, optimal management of these relatively chemotherapy-resistant tumors due to their low-grade nature remains an active area of investigation.

In addition to standard treatments, an increasing proportion of patients are exploring and incorporating complimentary alternative medicine (CAM) for the management of their cancers. Use of CAM is common among gynecologic cancer patients, although many patients may not disclose use to their treating physician. Women who are older are more likely to use CAM either in conjunction with standard treatment or alone, as compared to their younger or male counterparts (Gansler et al., 2008). These therapies may or may not be recommended by their primary oncologist, and many have not been evaluated in a clinical trial setting.

In this case report, we present a woman with LGSOC who declined primary systemic chemotherapy followed by interval surgical resection and opted for CAM therapy with Laetrile (amygdalin) and cannabidiol (CBD) oil. The patient has granted permission for this publication.

2. Case

An 81-year-old woman presented to her primary care physician with an umbilical mass that was suspected to be a hernia in March 2017. She was taken to the operating room in April 2017 for planned herniorrhaphy. The surgical findings were notable for a solid, peri-umbilical mass, as well as diffuse intra-abdominal nodularity. Final pathology of the resected umbilical lesion demonstrated a serous carcinoma, likely mullerian primary based on immunohistochemistry staining. Her Ca-

* Corresponding author at: 3885 Health Sciences Drive, La Jolla, California 92093, United States of America.

E-mail address: reskander@ucsd.edu (R.N. Eskander).<https://doi.org/10.1016/j.gore.2019.05.004>

Received 9 April 2019; Received in revised form 12 May 2019; Accepted 13 May 2019

Available online 17 May 2019

2352-5789/© 2019 The Authors. Published by Elsevier Inc. This is an open access article under the CC BY-NC-ND license

<http://creativecommons.org/licenses/by-nc-nd/4.0/>.

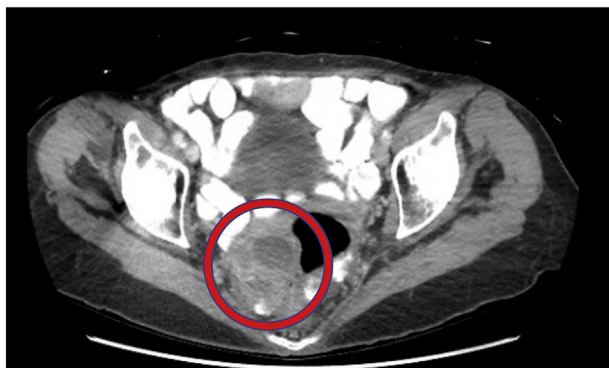

Fig. 1. CT scan May 2017, illustrating a right adnexal mass measuring 5.8 cm × 5.0 cm.

125 was found to be elevated at 77.

Following the above surgery, she underwent diagnostic imaging, with computed tomography (CT) scan of the chest, abdomen and pelvis demonstrating multiple mesenteric soft tissue masses ranging from 7 mm to 7 cm and omental carcinomatosis. A 5.8 cm solid right adnexal mass and 3.3 cm solid left adnexal mass were also identified (Fig. 1). Lymphadenopathy was noted along the left common iliac vessels and the left pelvic sidewall. She was subsequently referred to our practice for consultation and based on imaging and clinical examination, neoadjuvant carboplatin/paclitaxel with interval cytoreduction was recommended. She denied any known family history of cancer and BRCA 1 and 2 germline testing was negative. Her pathology was reviewed at our institution and confirmed to be LGSOC with low grade atypia and occasional psammoma bodies. The submitted tissue sample was estrogen and progesterone receptor positive.

After extensive counseling, the patient declined all interventions due to concerns regarding quality of life and treatment toxicity. She elected to pursue alternative therapy and started Laetrile tablets (500 mg orally four times per day) and cannabidiol (CBD) oil (1 drop sublingually each evening) in May 2017. Her Ca-125 level in May 2017 was 46, and after one month on the above regimen, her Ca-125 normalized to 22 (Fig. 2).

In July 2017, CT imaging was repeated and she was found to have a decrease in the size of the bilateral adnexal masses and mesenteric and pelvic lymphadenopathy, which was confirmed by clinical exam. Her mesenteric and omental carcinomatosis remained stable. Genomic profiling of her primary surgical specimen was ordered at this time and no molecular aberrations were identified. She was seen for follow up in September 2017, four months after starting initial treatment, and repeat

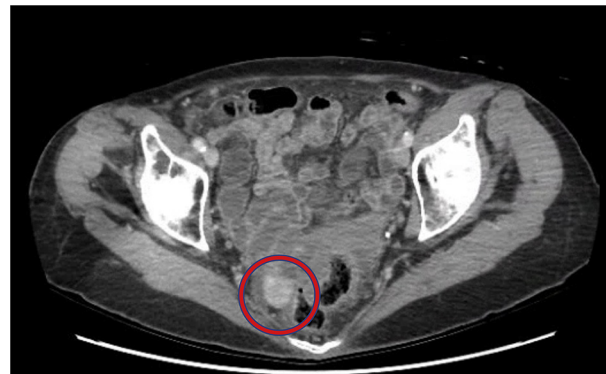


Fig. 3. CT scan November 2017, illustrating interval decrease in size of the right adnexal mass to 1.6 cm × 1.6 cm.

imaging in November 2017 continued to show a dramatic reduction in her disease burden, with near complete resolution of all previously identified lesions (Fig. 3). On her most recent interval assessment in December 2018 she continues to show a response to therapy. She is clinically asymptomatic with a performance status of 0, which is unchanged from her performance status at time of diagnosis.

3. Discussion

The management of patients with LGSOC remains a challenge, particularly in the advanced stage and recurrent setting. The current standard of care remains platinum and taxane based combination chemotherapy, followed by maintenance hormonal therapy. Unfortunately, patients who progress have limited therapeutic options and are encouraged to consider clinical trials if available, as response rates to chemotherapy in the recurrent setting are less than 5% (Grisham and Iyer, 2018).

In this case report, we highlight a dramatic response to combination Laetrile and CBD oil in a patient with widely metastatic LGSOC. Laetrile is a semi-synthetic version of amygdaline, a chemical compound found in plants and fruit seeds. Both Laetrile and amygdaline contain cyanide within a common structural component. Theoretically, Laetrile has anti-cancer effects when cyanide is released via enzymatic degradation. However, a Cochrane review published in 2015 found no randomized or quasi randomized control trials supporting the use of Laetrile in cancer patients (Milazzo, 2015). Further, they argued that due to the risk of cyanide poisoning, Laetrile use should be discouraged in patients seeking the compound for alternative cancer therapy. Concerns for toxicity in combination with inability to demonstrate clinical efficacy

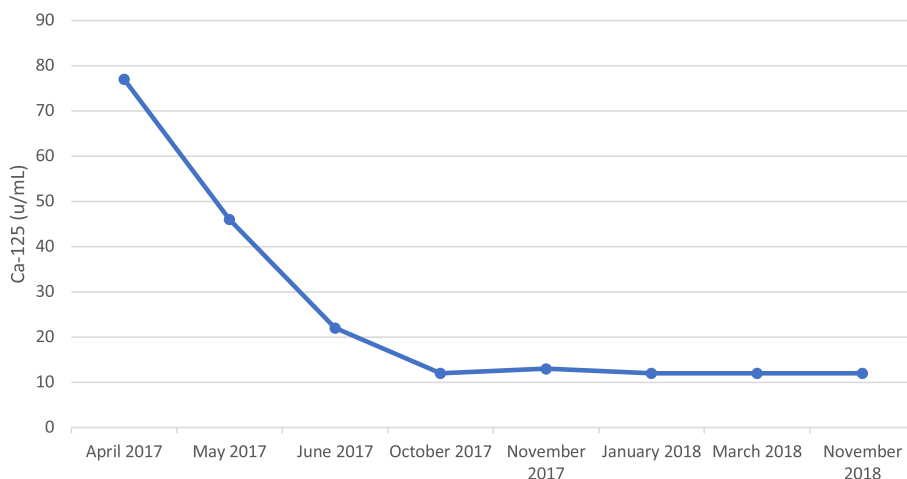


Fig. 2. Ca-125 trend on treatment.

led to an effective ban on the substance by the FDA in the 1980s. Nevertheless, the substance remains available for purchase in variable formulations commercially.

Cannabidiol (CBD) is a compound naturally derived from the cannabis plant. The anti-cancer effects of CBD have been evaluated predominantly in the laboratory setting. Interestingly, ovarian cancer cell lines express GPR55, a target that is inhibited indirectly by CBD and that plays a role in prostate and ovarian cancer cell proliferation (Piñeiro et al., 2011). Mouse model studies have also demonstrated cannabinoids inhibit tumor cell growth and induce apoptosis in gliomas, lymphomas, prostate, breast, lung, skin, and pancreatic cancer cells (Sarfaraz et al., 2008). Despite this theoretical benefit, there is not clear evidence that it has more or less activity than standard treatments in cancer patients.

Perhaps most provocative is the recent report that 40% of Americans believe that use of CAM is sufficient for the management of cancer (National Cancer Opinion Survey, 2019). In addition, 22% of Americans with a history of a cancer diagnosis and 38% of family caregivers share this belief. However, a recent study evaluated overall survival and adherence to treatment in patients receiving conventional cancer treatment with or without CAM for cancers considered curable. Patients who used CAM had significantly decreased overall survival when compared to those who did not, and also had higher rates of refusal of standard therapy (Johnson et al., 2018). Notably, this risk of death is linked to the refusal of therapy and not to the use of CAM itself. This demonstrates the importance and need for transparent, open discussions with patients regarding current available therapies, expected outcomes, and alternatives that patients may be seeking or have not yet disclosed.

Low grade serous ovarian cancer is a rare malignancy that is relatively resistant to chemotherapy in comparison to its high-grade counterpart. In this case report, we present the case of a female patient who demonstrated disease response after declining standard therapy and taking a combination of Laetrile and CBD oil. Previous clinical trials in humans have demonstrated no therapeutic effect in cancer patients taking Laetrile. However, basic science studies have identified cannabinoid receptors in ovarian cancer as potential therapeutic targets for cannabinoid use in treating malignancy. This area remains under study, and this case highlights the importance of communication between physicians and their patients regarding use of alternative therapies.

Conflicts of interest

The authors have no conflict of interest to report.

Author contributions

R.N.E. developed the concept for the manuscript, wrote, and edited the manuscript.

A.B. assisted with concept development for the manuscript, wrote, and edited the manuscript.

A.C.G. assisted with writing and editing of the manuscript.

References

- Farley, J., Brady, W.E., Vathipadiekal, V., Lankes, H.A., Coleman, R., Morgan, M.A., Mannel, R., Yamada, D., Mutch, D., Rodgers, W.H., Birrer, M., Gershenson, D.M., 2013. Articles Selumetinib in Women with Recurrent Low-Grade Serous Carcinoma of the Ovary or Peritoneum: an Open-Label, Single-Arm, Phase 2 Study. *Www. TheLancet.Com/Oncology* 14 [https://doi.org/10.1016/S1470-2045\(12\)70572-7](https://doi.org/10.1016/S1470-2045(12)70572-7).
- Gansler, T., Kaw, C., Crammer, C., Smith, T., 2008. A population-based study of prevalence of complementary methods use by cancer survivors: a report from the American Cancer Society's studies of cancer survivors. *Cancer* 113, 1048–1057. <https://doi.org/10.1002/cncr.23659>.
- Gershenson, D.M., Bodurka, D.C., Lu, K.H., Nathan, L.C., Milojevic, L., Wong, K.K., Malpica, A., Sun, C.C., 2015. Impact of age and primary disease site on outcome in women with low-grade serous carcinoma of the ovary or peritoneum: results of a large single-institution registry of a rare tumor. *J. Clin. Oncol.* 33, 2675–2682. <https://doi.org/10.1200/JCO.2015.61.0873>.
- Grisham, R.N., Iyer, G., 2018. Low-grade serous ovarian Cancer: current treatment paradigms and future directions. *Curr. Treat. Options in Oncol.* 19, 54. <https://doi.org/10.1007/s11864-018-0571-8>.
- Johnson, S.B., Park, H.S., Gross, C.P., Yu, J.B., 2018. Complementary medicine, refusal of conventional Cancer therapy, and survival among patients with curable cancers. *JAMA Oncol.* 4, 1375. <https://doi.org/10.1001/jamaoncol.2018.2487>.
- Milazzo, M., Ernst, S., Lejeune, E., Boehm, S., Horneber, K., 2015. Laetrile treatment for cancer (review). *Cochrane Libr* 2011. <https://doi.org/10.1002/14651858.CD005476.pub4>. www.cochranelibrary.com.
- National Cancer Opinion Survey, 2019. Harris Poll on behalf of ASCO, 2018. <https://www.asco.org/about-asco/press-center/news-releases/national-survey-reveals-surprising-number-americans-believe>, Accessed date: 10 February 2019.
- National Comprehensive Cancer Network, 2019. Ovarian Cancer (Version2.2018). https://www.nccn.org/professionals/physician_gls/pdf/ovarian.pdf, Accessed date: 2 July 2018.
- Piñeiro, R., Maffucci, T., Falasca, M., 2011. The putative cannabinoid receptor GPR55 defines a novel autocrine loop in cancer cell proliferation. *Oncogene* 30, 142–152. <https://doi.org/10.1038/onc.2010.417>.
- Sarfaraz, S., Adhami, V.M., Syed, D.N., Afaq, F., Mukhtar, H., 2008. Cannabinoids for Cancer treatment: progress and promise cannabinoid receptors: a brief overview. *Cancer Res.* 68, 339–342. <https://doi.org/10.1158/0008-5472.CAN-07-2785>.