

A case report: black oesophagus as a possible complication of transcatheter aortic valve implantation

Inês S. Gonçalves ^{1*}, Armando L. Bordalo e Sá¹, Narcisa Fatela², and Pedro Canas da Silva ¹

¹Cardiology Department, Hospital Universitário de Santa Maria, Centro Hospitalar Universitário de Lisboa Norte, CAML, CCUL, Lisbon School of Medicine of the Universidade de Lisboa, Avenida Professor Egas Moniz, 1649-035 Lisboa, Portugal; and ²Gastroenterology Department, Hospital Universitário de Santa Maria, Centro Hospitalar Universitário de Lisboa Norte, Lisbon School of Medicine of the Universidade de Lisboa, Avenida Professor Egas Moniz, 1649-035 Lisboa, Portugal

Received 10 August 2018; first decision 1 October 2018; accepted 23 May 2019; online publish-ahead-of-print 3 June 2019

Background

The increasing number of transcatheter aortic valve implantation (TAVI) in the last few years has unveiled a unique set of events and complications that need prompt recognition and management in order to improve patient outcomes, often involving a multidisciplinary team.

Case summary

We present a case of a 86-year-old woman with symptomatic severe aortic stenosis that underwent a TAVI and, in the post-procedure period, presented with acute abundant haematemesis, haemodynamic instability, and haemoglobin drop. The diagnosis of acute necrotizing oesophagitis (ANE) was made by upper gastrointestinal endoscopy.

Discussion

Acute necrotizing oesophagitis is a rare entity caused usually by an ischaemic insult in the presence of predisposing factors; it has a high rate of complications and mortality. To the best of our knowledge, this is the first clinical case report to describe the occurrence of ANE as a possible complication of TAVI and is also an example of the importance of the multidisciplinary approach of these complex patients, which extends even beyond the concept of Heart Team.

Keywords

Case report • Transcatheter aortic valve implantation • Acute necrotizing oesophagitis • Black oesophagus

Learning points

- As the number of transcatheter aortic valve implantation (TAVI) has increased in the last decade, a unique set of post-intervention events and complications have been identified.
- This is the first clinical case report to describe the occurrence of acute necrotizing oesophagitis (ANE) as a possible complication of TAVI.
- Transcatheter aortic valve implantation patients are prone to ANE due to their advanced age and frailty, comorbidities, ischaemic insult, and anti-platelet therapy.
- Acute necrotizing oesophagitis is a rare entity with high rate of acute and long-term complications and successful management requires early detection and multidisciplinary care.

* Corresponding author. Tel: +351 913951974, Email: inesgoncalves1@hotmail.com

Handling Editor: Timothy C. Tan

Peer-reviewers: Marcelo Haertel Miglioranza, Hatem Soliman Aboumarie, and Stefano Nistri

Compliance Editor: Mohammed Majid Akhtar

Supplementary Material Editor: Peysh A. Patel

© The Author(s) 2019. Published by Oxford University Press on behalf of the European Society of Cardiology.

This is an Open Access article distributed under the terms of the Creative Commons Attribution Non-Commercial License (<http://creativecommons.org/licenses/by-nc/4.0/>), which permits non-commercial re-use, distribution, and reproduction in any medium, provided the original work is properly cited. For commercial re-use, please contact journals.permissions@oup.com

Introduction

Transcatheter aortic valve implantation (TAVI) has revolutionized the management of aortic stenosis in the last decade.¹ However, as the number of TAVI has increased, a unique set of post-intervention events and complications have been identified. Bradyarrhythmias, vascular access complications, acute cerebral vascular accidents, acute renal failure, cardiac tamponade, aortic root rupture, and aortic regurgitation are some of the most common described complications.^{2–5} Their recognition is critical to improve patients' outcomes, often involving a multidisciplinary team. In the present article, we report the occurrence of acute necrotizing oesophagitis (ANE), an undescribed complication possibly associated with TAVI.

Timeline

Time	Description of relevant clinical information	Intervention required
December 2016	Evaluation in outpatient clinic: complains of fatigue on moderate exertion in the last 4 months.	Performing of diagnostic tests in ambulatory.
January 2017	Severe aortic valve stenosis diagnosis (mean gradient of 52 mmHg and valve area of 0.87 cm ²).	Discussion in Heart Team.
March 2017	Accepted to transcatheter aortic valve implantation (TAVI).	TAVI scheduling.
Day 0	TAVI procedure, transfemoral approach, without acute complications.	Admission to intensive care unit. Dual antiplatelet therapy (DAPT) initiation.
Day 1	Favourable evolution (without access complications or rhythm disturbances and with haemodynamic stability).	
Day 2	Acute abundant haematemesis, haemodynamic instability, and haemoglobin drop.	Endoscopy showed lesions compatible with acute necrotizing oesophagitis diagnosis. Fluid therapy and replacement of blood products. Proton-pump inhibitor (IBP) therapy, domperidone and sucralfat. DAPT suspended.
Day 3	Haematemesis in small quantity.	Therapeutic maintenance.
Day 4	Favourable evolution, with haemodynamic stabilization and without haematemesis.	Therapeutic maintenance.
Day 5	Endoscopy showing resolution of the previously described lesions.	Oral diet was progressively initiated.
Day 6		IBP was switched to oral formulation.
Day 7		DAPT was re-instituted.
Day 8	Patient was discharged clinically well and without any symptoms.	
August 2017	Follow-up in outpatient clinic, without symptoms or complications.	

Case presentation

We present the case of an 86-year-old woman with a past medical history of endometrial cancer, treated by hysterectomy, oophorectomy and radiotherapy, and with consequent radiation cystitis; she also had dyslipidaemia and osteoporosis, associated with thoracic kyphosis, chronic back pain and mobility impairment (need of walking stick support, help with daily activities and house-keeping). The patient presented with fatigue on moderate exertion with progressive

aggravation in the last 4 months. On cardiac auscultation, a mid-systolic murmur was audible along the upper right sternal border. The electrocardiogram revealed sinus rhythm with left axis deviation and repolarization abnormalities (Figure 1). Transthoracic echocardiography (TTE) revealed: left ventricular (LV) concentric hypertrophy (LV mass index of 123 g/m²; relative wall thickness of 0.49); non-dilated LV (end-diastolic volume of 45 mL/m²), normal ejection fraction (57%), and diastolic dysfunction (*e/a* ratio of 0.5; *e/e'* of 13; left atrium volume index of 44 mL/m²; and tricuspid regurgitation velocity of 2.9 m/s); ascending aorta dilatation (49 mm); tricuspid aortic valve, severely calcified, with severe stenosis (sAS)—mean gradient of 52 mmHg and valve area of 0.87 cm². Blood tests showed N-terminal pro-hormone of brain natriuretic peptide of 1302 pg/mL (0–300 pg/mL), without other significant abnormalities (Table 1). Coronary angiography was normal. Due to symptomatic sAS, the case was dis-

cussed in Heart Team, in order to decide the best approach to aortic valve replacement. Considering the advanced age, moderate frailty (Clinical Frailty Scale assessment of 6,⁵ normal body mass index of 22 kg/m²), restricted mobility, and intermediate surgical risk [Society of Thoracic Surgeons (STS) score: 4.2% risk of mortality], TAVI was considered the best option. Pre-TAVI computed tomography angiography was performed to determine the best vascular access and the appropriate dimensions of the aortic valve prosthesis. It confirmed dilatation of the ascending aorta (50 mm) and diffuse atherosclerotic

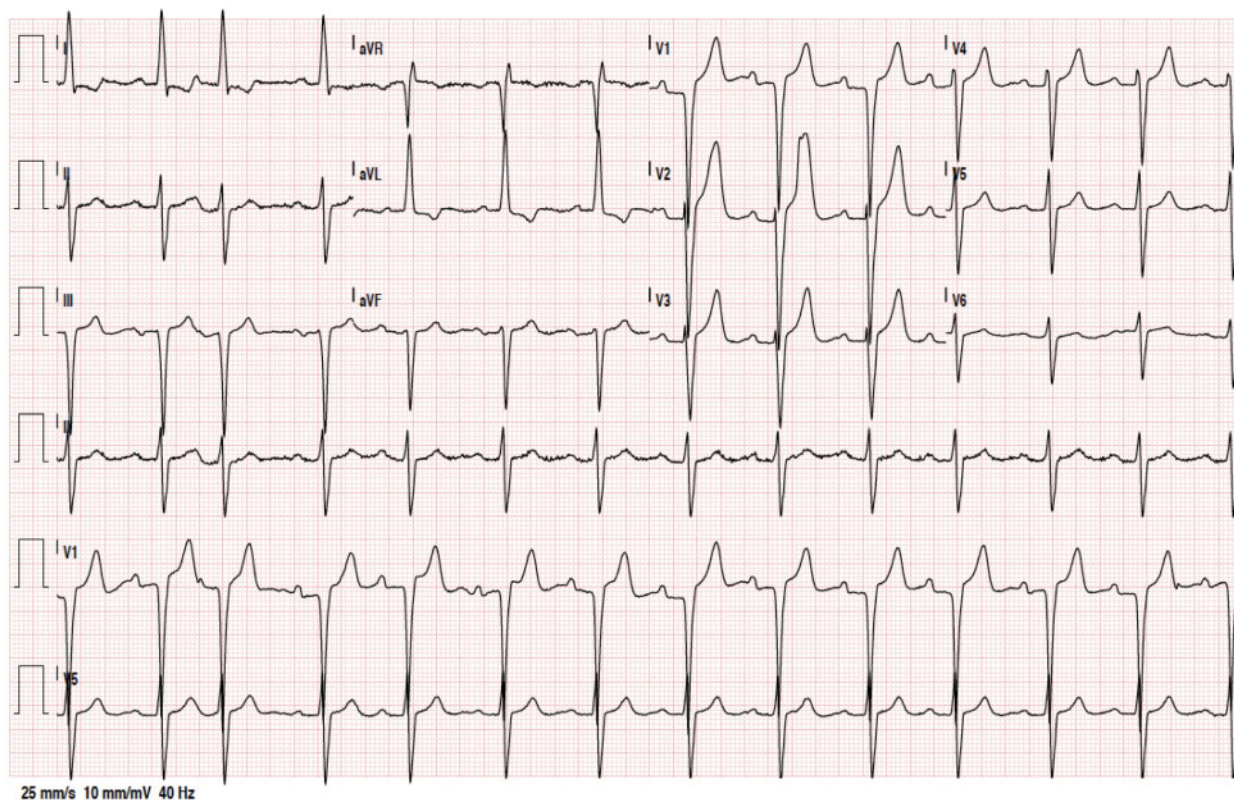


Figure 1 Patient's electrocardiogram on admission: sinus rhythm with left axis deviation and repolarization abnormalities.

Table 1 Blood tests results

Parameters (unit)	Pré-TAVI	First day Post-TAVI	Second day Post-TAVI	Fourth day Post-TAVI	At discharge	Normal range
Haemoglobin (g/dL)	12.7	11.4	9.6	9.9	10.4	12–15.3
Leucocytes ($\times 10^9/L$)	4.0	6.5	3.04	3.0	3.0	4.0–11.0
Platelets ($\times 10^9/L$)	181	115	119	146	170	150–450
Partial thromboplastin time (s)	27.3					31.0
Prothrombin time (s)	11.3					11.6
Urea (mg/dL)	52	48	36	22	21	16–49
Creatinine (mg/dL)	0.99	0.9	0.89	0.75	0.83	0.51–0.95
Sodium (mmol/L)	139	140	143	139	139	135–145
Potassium (mmol/L)	4.8	4.1	3.9	3.8	4.2	3.5–5.1
C-reactive protein (mg/dL)	0.09	7.49	7.55	2.4	1.51	<0.5
Aspartate aminotransferase (U/L)	18	16	13		15	0–32
Alanine aminotransferase (U/L)	6	6	5		5	0–33
Gamma glutamyl transferase (U/L)	12	9			9	0–40
Alkaline phosphatase (U/L)	99		63		65	35–105
Bilirubin (mg/dL)	0.32				0.32	<1.2
NTproBNP (pg/mL)	1302				580	<300

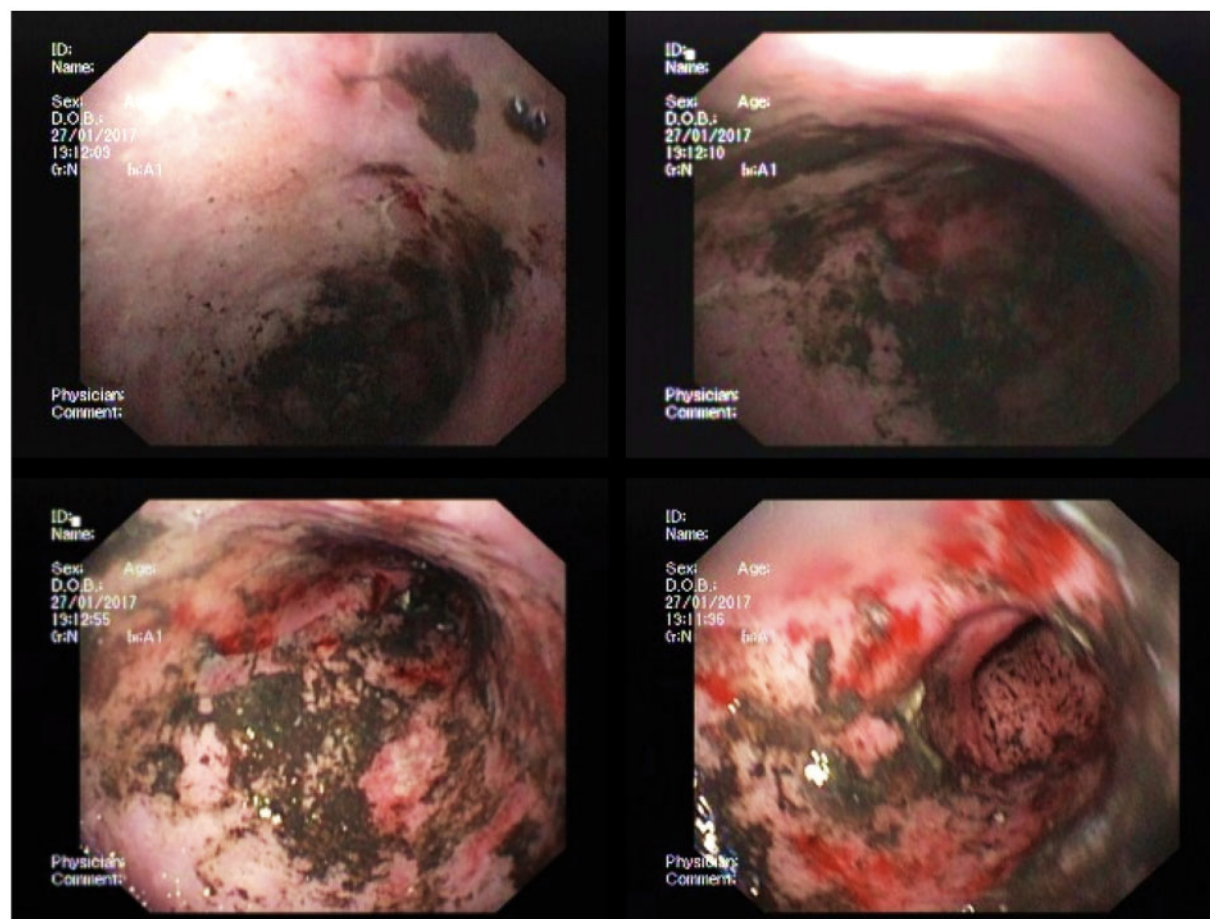


Figure 2 Endoscopy showing striking diffuse, circumferential, black-appearing oesophageal mucosa with signs of friability, involving the distal oesophagus. These findings are compatible with acute necrotising oesophagitis, also known as *black oesophagus*.

disease, without any obstructive lesions. Elective transfemoral TAVI was scheduled.

The procedure was performed under general anaesthesia and guided by transoesophageal echocardiogram (TOE), via the right femoral route. Balloon valvuloplasty (20 × 40 mm balloon) was performed prior to aortic valve prosthesis implantation (Edwards Sapiens 3™, 23 mm, through a NovaFlex™ delivery system). Valvuloplasty and prosthesis deployment were accomplished during a burst of rapid ventricular pacing, using a temporary pacemaker, with 30–40 s of intentional low cardiac output state—systolic blood pressure (SBP) of 40–50 mmHg. After valve deployment, the patient presented a short period of hypotension (SBP 60–70 mmHg and diastolic blood pressure ±20 mmHg; heart rate ±100 b.p.m.), with spontaneous recovery in less than 3 min. The final result was satisfactory, with a slight leak in relation to the native left coronary cusp, a maximum transvalvular gradient of 12 mmHg, and a mean gradient of 5.3 mmHg. The patient was extubated at the end of the procedure and was admitted to the intensive care unit, with maintained haemodynamic stability and on spontaneous ventilation. Dual antiplatelet therapy (DAPT)—acetylsalicylic acid 100 mg and clopidogrel 75 mg—was initiated, in addition to the patient's usual medication

(otilonium bromide, trospium chloride, nitrofurantoin, simvastatin, risedronate, calcium, and vitamin D).

Despite the favourable initial evolution, during the second day after TAVI the patient presented with acute abundant haematemesis (coffee ground colour vomitus) associated with hypotension (decrease of SBP from 130 mmHg to 90 mmHg) and haemoglobin drop from 12.7 g/dL to 9.6 g/dL (12–15.5 g/dL). C-reactive protein was slightly elevated (7.55 mg/dL; reference range 0–0.5 mg/dL), as usual following an invasive procedure (Table 1). Intravenous pantoprazole infusion was administered, the patient was kept nil by mouth, intensive crystalloid fluid therapy was initiated, and an emergency upper gastrointestinal endoscopy was performed. Endoscopy showed striking diffuse, circumferential, black-appearing oesophageal mucosa with signs of friability, and under-distension of the lumen, involving the distal oesophagus (Figure 2). These findings were compatible with ANE, also known as *black oesophagus*. Accordingly, haemodynamic stabilization measures (fluid therapy and replacement of blood products) and proton-pump inhibitor (PPI) therapy were maintained, domperidone and sucralfat were initiated, and DAPT was temporarily suspended. Haematemesis stopped and the patient was stabilized 48 h after the acute event. Computed tomography angiography was

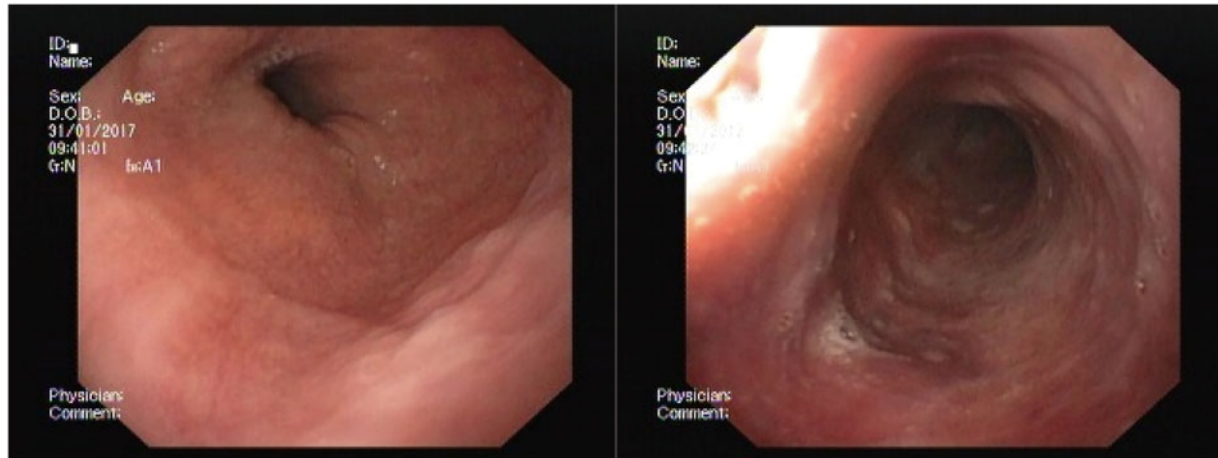


Figure 3 Endoscopy control study showing resolution of the previously described lesions.

performed to evaluate any abnormality in oesophageal vascularization or aortic lesion and to exclude complications: it showed wall thickness of lower oesophagus with mucosal enhancement and densification of perioesophageal fat, without other abnormalities. Upper endoscopy was repeated 72 h later, showing resolution of the previously described lesions (Figure 3). Afterwards, oral diet was progressively initiated, PPI was switched to oral formulation, and DAPT was re-instituted under surveillance, with good tolerance. Oral iron supplementation was initiated. The patient was discharged on the eighth day after TAVI, clinically well. She was referred for short-term outpatient clinic evaluation by Cardiology and Gastroenterology.

At follow-up, the patient remained without symptoms of heart failure or related to ANE complications. Transthoracic echocardiography evaluation 3 months after discharge showed maintenance of a very slight leak in relation to the native right coronary cusp, with no significant changes in all other parameters. Endoscopic reassessment was not performed, since the previous showed good evolution and the patient had no symptoms or signs of stenosis or relapsing necrosis.

Discussion and conclusions

To the best of our knowledge, this is the first clinical case report to describe the occurrence of ANE as a possible complication of TAVI. There is a single case of isolated proximal *black oesophagus* reported in a patient who underwent cardiac catheterization, an event that was possibly related to the procedure.⁶

The ANE is an entity first described in 1990 by Goldenberg *et al.*⁷ It is a very rare disease, affecting men four times more commonly than women, with undetermined incidence and is often underdiagnosed; in endoscopic studies the prevalence of ANE ranges from 0.01% to 0.2%.^{8–10} The most frequent clinical manifestations are the occurrence of upper gastrointestinal bleeding (90% of the cases), haematemesis or melaenas, and chest pain.^{11–13} The usual triggering factor is an episode of ischaemic insult—haemodynamic instability, shock and/or hypoxia.¹⁴ Aggression or fragilization of the

oesophageal mucosa by internal or external factors, and the existence of associated medical comorbidities are recognized predisposing factors.^{7–14} It has a typical endoscopic presentation, previously described in this case, primarily affecting the distal region of the oesophagus, which is related to the scarce vascularity of this region.¹⁴ Biopsy is usually unnecessary, but it can be performed specially when it is important to make a differential diagnosis with melanoma, acanthosis nigricans, and pseudo-melanosis of the oesophagus. Treatment of ANE should focus on supportive care to maximize organ perfusion, treatment of underlying medical conditions, and intravenous PPI. Adequate monitoring to detect and properly treat complications is also essential.¹⁵

The importance of recognition of this entity is related to the high rate of acute and long-term complications—occurrence of transmural necrosis with perforation, mediastinitis, mediastinal abscess, sepsis, and oesophageal stenosis (10–25% at long-term follow-up). Mortality depends on the underlying condition and it is variably reported in the literature, between 6% to as high as 36%, when associated with other comorbidities.^{10,12} There are limited data to guide the management of ANE, and it is largely based upon clinical experience. Repeat endoscopic evaluation should be done to assess mucosal healing. With supportive care, resolution of endoscopic findings occurs in most patients within 72 h to 2 weeks. Symptoms of oesophageal stenosis should be monitored in the long term.¹⁶


In this clinical case, the transient low output state during TAVI was probably the ischaemic insult that triggered ANE. The period of hypotension was short (<4 min), without evidence of other end-organ hypotensive damage. However, the insult of TOE during TAVI and DAPT may have led to oesophageal mucosa fragilization, making it especially vulnerable to the ischaemic injury. Patient's age, frailty and diffuse atherosclerotic disease are additional predisposing factors of ANE. The reason why this specific patient had this manifestation, when most TAVI patients share these risk factors, is not known. The use of conscious sedation, with local anaesthesia and TTE guidance, could minimize the risk of this complication, avoiding the additional aggression of the oesophageal mucosa by the TOE probe.

In addition to demonstrating, for the first time, the occurrence of a rare complication with a possible association with TAVI, this clinical case is also paradigmatic and exemplary of the importance of the multidisciplinary approach of these complex patients that extends even beyond the concept of the Heart Team.

Ethical disclosures

The authors declare that they have followed the protocols of their work centre on the publication of patient data. The authors have obtained the written informed consent of the subject mentioned in the article.

Lead author biography



Inês S. Gonçalves completed her Medical Degree in 2012, School of Medicine of the University of Minho, Portugal. She underwent general internship in 2013 and specific residency training in Cardiology between 2014 and 2018 at the Cardiology Department of Santa Maria University Hospital—CHULN E.P.E, Lisbon, where she is currently working. She is a researcher at Cardiovascular Centre of the University of Lisbon (CCUL) in the areas of *Cardiac Rhythm Abnormalities* and *Heart Failure and Cardiomyopathies*, her main areas of interest. She has taken part in several clinical trials as co-investigator and has 150 scientific communications at national and international meetings.

Supplementary material

[Supplementary material](#) is available at *European Heart Journal - Case Reports* online.

Slide sets: A fully edited slide set detailing this case and suitable for local presentation is available online as [Supplementary data](#).

Consent: The author/s confirm that written consent for submission and publication of this case report including image(s) and associated text has been obtained from the patient in line with COPE guidance.

Conflict of interest: none declared.

References

1. Cahill TJ, Chen M, Hayashida K, Latib A, Modine T, Piazza N, Redwood S, Søndergaard L, Prendergast BD. Transcatheter aortic valve implantation: current status and future perspectives. *Eur Heart J* 2018;**39**:2625–2634.
2. Walther T, Hamm CW, Schuler G, Berkowitsch A, Kötting J, Mangner N, Mudra H, Beckmann A, Cremer J, Welz A, Lange R, Kuck KH, Mohr FW, Möllmann H. Perioperative results and complications in 15,964 transcatheter aortic valve replacements: prospective data from the GARY registry. *J Am Coll Cardiol* 2015;**65**:2173–2180.
3. Carroll JD, Vemulapalli S, Dai D, Matsouaka R, Blackstone E, Edwards F, Masoudi FA, Mack M, Peterson ED, Holmes D, Rumsfeld JS, Tuzcu EM, Grover F. Procedural experience for transcatheter aortic valve replacement and relation to outcomes. *J Am Coll Cardiol* 2017;**70**:29.
4. Auffret V, Lefevre T, Van Belle E, Eltchaninoff H, Iung B, Koning R, Motreff P, LePrince P, Verhoye JP, Manigold T, Souteyrand G, Boulmier D, Joly P, Pinaud F, Himbert D, Collet JP, Rioufol G, Ghostine S, Bar O, Dibie A, Champagnac D, Leroux L, Collet F, Teiger E, Darremont O, Folliguet T, Leclercq F, Lhermusier T, Olhmann P, Huret B, Lorgis L, Drogoul L, Bertrand B, Spaulding C, Quiliet L, Cuisset T, Delomez M, Beygui F, Claudel J-P, Hepp A, Jegou A, Gommeaux A, Mirode A, Christiaens L, Christophe C, Cassat C, Metz D, Mangin L, Isaaz K, Jacquemin L, Guyon P, Pouillot C, Makowski S, Bataille V, Rodés-Cabau J, Gilard M, Le Breton H. Temporal trends in transcatheter aortic valve replacement in France: FRANCE 2 to FRANCE TAVI. *J Am Coll Cardiol* 2017;**70**:42–55.
5. Shimura T, Yamamoto M, Kano S, Kagase A, Kodama A, Koyama Y, Tsuchikane E, Suzuki T, Otsuka T, Kohsaka S, Tada N, Yamanaka F, Naganuma T, Araki M, Shirai S, Watanabe Y, Hayashida K, Yashima F, Inohara T, Kakefuda Y, Arai T, Yanagisawa R, Tanaka M, Kawakami T, Maekawa Y, Takashi K, Yoshitake A, Iida Y, Yamazaki M, Shimizu H, Yamada Y, Jinzaki M, Tsuruta H, Itabashi Y, Murata M, Kawakami M, Fukui S, Sano M, Fukuda K, Hosoba S, Sato H, Teramoto T, Kimura M, Sago M, Tsunaki T, Watarai S, Tsuzuki M, Irokawa K, Shimizu K, Kobayashi T, Okawa Y, Miyasaka M, Enta Y, Shishido K, Ochiai T, Yamabe T, Noguchi K, Saito S, Kawamoto H, Onishi H, Yabushita H, Mitomo S, Nakamura S, Yamawaki M, Akatsu Y, Honda Y, Takama T, Isotani A, Hayashi M, Kamioka N, Miura M, Morinaga T, Kawaguchi T, Yano M, Hanyu M, Arai Y, Tsubota H, Kudo M, Kuroda Y, Kataoka A, Hioki H, Nara Y, Kawashima H, Nagura F, Nakashima M, Sasaki K, Nishikawa J, Shimokawa T, Harada T, Kozuma K. Impact of the clinical frailty scale on outcomes after transcatheter aortic valve replacement. *Circulation* 2017;**135**:2013.
6. Kwon HJ, Park SH, Ahn JH, Lee TH, Lee CK. Acute esophageal necrosis occurring in a patient undergoing percutaneous coronary intervention. *Korean J Intern Med* 2014;**29**:379–382.
7. Goldenberg SP, Wain SL, Marignani P. Acute necrotizing esophagitis. *Gastroenterology* 1990;**98**:493–496.
8. Moretó M, Ojembarrena E, Zaballa M, Tánago JG, Ibáñez S. Idiopathic acute esophageal necrosis: not necessarily a terminal event. *Endoscopy* 1993;**25**:534–538.
9. Shafa S, Sharma N, Keshishian J, Dellon ES. The black esophagus: a rare but deadly disease. *ACG Case Rep J* 2016;**3**:88–91.
10. Worrell SG, Oh DS, Greene CL, DeMeester SR, Hagen JA. Acute esophageal necrosis: a case series and long-term follow-up. *Ann Thorac Surg* 2014;**98**:341–342.
11. Kimura Y, Seno H, Yamashita Y. A case of acute necrotizing esophagitis. *Gastrointest Endosc* 2014;**80**:525–526.
12. Gurvits GE, Cherian K, Shami MN, Korabathina R, El-Nader EMA, Rayapudi K, Gandolfo FJ, Alshumrany M, Patel H, Chowdhury DN, Tsiakos A. Black esophagus: new insights and multicenter international experience in 2014. *Dig Dis Sci* 2015;**60**:444–453.
13. Grudell AB, Mueller PS, Viggiano TR. Black esophagus: report of six cases and review of the literature, 1963–2003. *Dis Esophagus* 2006;**19**:105–110.
14. Marcos C, Manuel L, Luiza R. Acute esophageal necrosis. *Dig Endosc* 2005;**17**:89–92.
15. Gurvits GE, Shapsis A, Lau N, Gualtieri N, Robilotti JG. Acute esophageal necrosis: a rare syndrome. *J Gastroenterol* 2007;**42**:29–38.
16. Gurvits GE. Black esophagus: acute esophageal necrosis syndrome. *World J Gastroenterol* 2010;**14**:3219–3225.